

## Influence of irradiation on collagen content during wound healing in diabetic rats

## Influência da irradiação sobre o conteúdo de colágeno, durante a cicatrização, em ratos diabéticos

Solange Maria de Almeida\*  
Rívea Inês Ferreira\*\*  
Frab Norberto Bóscolo\*\*\*

**ABSTRACT:** The aim of the present experimental research was to investigate the effects of electron irradiation on the collagen content and on the organization of the granulation tissue of skin, in diabetic rats. In this study, 48 Wistar rats were assigned to 4 groups: control, irradiated, diabetic and irradiated diabetic. First, diabetes *mellitus* was induced in the last two groups, by means of a single intravenous injection of streptozotocin. Fifteen days later, all animals underwent a surgery in order to create an excisional wound on their anterior dorsal skin. On the third post-operative day, only an approximately 1-cm-wide area around the wounds was exposed to 1 Gy of 6 MeV electron beam radiation, which was delivered in a single dose. Wound healing was examined by means of polarized light microscopy at 4-, 7-, 13- and 21-day time intervals after wounding. Based upon an essentially qualitative evaluation, it was possible to conclude that local electron irradiation and diabetes' associated dysfunctions caused a decrease in the collagen content of newly-formed tissue, which was more pronounced in irradiated diabetic animals. The macromolecular organization of granulation tissue was delayed in irradiated, diabetic and irradiated diabetic animals, in relation to what was observed in control animals.

**DESCRIPTORS:** Radiation; Diabetes *mellitus*; Collagen; Wound healing.

**RESUMO:** O objetivo desta pesquisa experimental foi estudar os efeitos da irradiação por elétrons sobre o conteúdo de colágeno e a organização macromolecular do tecido de granulação, na pele de ratos diabéticos. Para tanto, 48 ratos da linhagem Wistar foram separados em 4 grupos: controle; irradiado; diabético e diabético irradiado. Inicialmente, a diabetes melito foi induzida, nos dois últimos grupos, por meio da administração intravenosa de estreptozotocina. Após quinze dias da indução, todos os animais foram submetidos a uma cirurgia para a produção de uma ferida excisional, na região dorsal anterior. No terceiro dia pós-operatório, aplicou-se uma dose única de 1 Gy, de feixes de elétrons com 6 MeV de energia, em uma área externa que compreendia cerca de 1 cm lateralmente às bordas das feridas. Amostras teciduais dos 4 grupos foram examinadas por microscopia de luz polarizada aos 4, 7, 13 e 21 dias pós-operatórios. Por meio de uma avaliação essencialmente qualitativa, foi possível concluir que a irradiação local por elétrons e as disfunções associadas à diabetes determinaram um decréscimo no conteúdo de colágeno do tecido neoformado, que foi mais pronunciado nos animais diabéticos irradiados. A organização macromolecular do tecido de granulação apresentou-se retardada nos animais irradiados, diabéticos e diabéticos irradiados, em comparação com os animais do grupo controle.

**DESCRITORES:** Radiação; Diabetes *mellitus*; Colágeno; Cicatrização de feridas.

### INTRODUCTION

Although ionizing radiation is unquestionably one of the medicine's most useful tools for diagnostic and therapeutic purposes, its clinical applications often result in deleterious effects. The significant radiobiological damages, in the form of poor wound healing, are influenced by the patient's systemic health conditions<sup>8</sup>.

Fibroblasts are involved in the synthesis of collagen, glycosaminoglycans (GAGs), proteoglycans and

adhesive glycoproteins, and are recognized as having essential importance in wound healing<sup>17</sup>. Wound contraction has been ascribed to fibroblastic activity<sup>4,20</sup>. Regarding certain physical agents which have major impact on the success or failure of wound healing, several scientific investigations suggest that ionizing radiations inhibit fibroblasts proliferation through a direct mechanism<sup>9,15,20</sup>. Bernstein *et al.*<sup>2</sup> (1994) stated that local irradiation may induce morphological and physiological alterations in fibro-

\*Assistant Professor; \*\*PhD Student; \*\*\*Professor and Chairman – Department of Oral Diagnosis, School of Dentistry, State University of Campinas.

blasts, which may appear as large, unusual stellate cells, the so-called "radiation fibroblasts".

Diabetes *mellitus* has been clinically and experimentally associated with impaired wound healing<sup>5,7,18,23</sup>. Previous studies have indeed found data to support evidence of dysfunctions in polymorphonuclear leukocytes, macrophages and fibroblasts, with a prolonged inflammatory phase, decreased biosynthesis of collagen and GAGs, which result in significant delay in the formation of granulation tissue<sup>3,5,12,16,22,23</sup>.

Despite the great number of currently available experimental researches in radiobiology, few investigations have focused on the synergistic relationship between pre-existing diabetes and local electron irradiation. Therefore, the aim of the present work was to study the combined effects of diabetes *mellitus* and a low dose of electron radiation on skin collagen content and on the organization of the granulation tissue.

## MATERIAL AND METHODS

The experiment was carried out with 48 male *Rattus norvegicus Albinus*, Wistar strain, weighing 200-250 g. The animals were randomly divided into 4 groups: control, irradiated, diabetic and irradiated diabetic. The experimental protocols were approved by the Ethical Committee for Animal Research, Institute of Biology, State University of Campinas (CEEA).

After 16 hours of fasting, diabetes *mellitus* was induced by injecting streptozotocin dissolved in citrate buffer (0.01M, pH 4.5), in a single dose of 35 mg/kg of body weight, into the penis vein, under ether anesthesia. The control rats received an injection of saline solution at the same volume. The progress of the disease was monitored weekly, with the utilization of *Glico-fita*<sup>®</sup> (Lilly - Brazil). Other parameters used to characterize the diabetic state of the animals were polydipsia and weight loss. Polyuria was also observed, but not quantitatively measured.

Fifteen days after induction, all animals were anesthetized with 3% pentobarbital sodium, in a single dose of 40 mg/kg of body weight, administered intraperitoneally, and underwent a surgical procedure in order to make a standardized excisional rectangular skin wound measuring 2.5 x 1.5 cm on the anterior dorsal region. On the third post-operative day, only an approximately 1-cm-wide area around the wounds was locally exposed to 6 MeV electron beam irradiation with

a single dose of 1 Gy. The electron beams had uniform penetration to a depth of 1 cm in the skin<sup>11</sup>. The wound and the rest of the animal's body were otherwise shielded by 4 mm of lead.

Wound healing was examined at 4, 7, 13, and 21-day time intervals after wounding. Under 3% pentobarbital sodium anesthesia, the entire wound region, with liberal margins of surrounding skin, was excised in depth to include underlying connective tissues above the external fascia of the dorsal muscles. The excised skin was fixed in 10% formalin, dehydrated in graded alcohol solutions, embedded in *Paraplast plus* (Oxford Labware) and cut in 5- $\mu$ m-thick serial sections. Tissue sections were examined by means of polarized light microscopy.

For specific identification and evaluation of the maturation of collagen fibers, some tissue sections were stained with picrosirius red (PSR). The sections were deparaffinized, hydrated, and stained for 1 h in a 0.1% solution of Sirius Red dissolved in saturated picric acid. By means of histochemical reaction with collagen molecules, PSR enhances the normal birefringence of collagen types I, II, III, and IV<sup>14</sup>. Under polarized light, the color of PSR-stained collagen varies as a function of the structural and biochemical properties of the collagen fibers. The spectrum of colors includes green, yellow, orange, and red, in a progressive way according to the packing of collagen molecules<sup>14</sup>.

In order to detect linear dichroism, other processed sections were stained with 0.025% toluidine-blue aqueous solution, at pH 4.0. Linear dichroism is related to the macromolecular association between GAGs and collagen fibers. When staining is carried out, toluidine-blue molecules arrange themselves along the collagen fibers, according to the disposition of GAGs molecules. This produces linear dichroism, when tissue is examined under polarized light. Dichroism only appears when oriented association between GAGs and collagen fibers is settled, which, on the other hand, indicates the macromolecular organization of the granulation tissue.

## RESULTS

### PSR histochemical reaction

#### 4<sup>th</sup> post-operative day

In control animals, although the first population of collagen fibers exhibited polarization colors in the red-orange range, collagen was sparse and immature. In the granulation tissue from the irradiated animals, the predominant polarization co-

lors were in the orange-yellow range, implying even more sparse and immature collagen fibers, in comparison to control animals. Specimens from diabetic animals exhibited intense yellow-green birefringence, which suggests that the collagen content was reduced and collagen fibers were very loosely packed. Irradiated diabetic animals' specimens presented significantly higher frequency of greenish-yellow polarization colors than the diabetic specimens, consistent with weakly birefringent fibers. Comparing the latter group to the irradiated animals' specimens, one would infer that contrasting reduction in collagen content was markedly evident.

#### **7<sup>th</sup> post-operative day**

As a consequence of the evolution of granulation tissue, the pattern of polarization colors changed. Collagen fibers exhibited gradual increase in the wavelengths of polarization colors, from control to irradiated diabetic specimens. Collagen fibers from control specimens appeared more packed and presumably, better aligned, which suggests the beginning of macromolecular organization of granulation tissue. The granulation tissue of irradiated animals exhibited polarization colors from red to orange, which indicates an increase in collagen content, even though fibers were still immature. Comparing the diabetic and irradiated diabetic groups with the group of irradiated animals, it was possible to notice an increase in the frequency of orange and yellow collagen fibers in both diabetic groups, whereas a very low amount of red fibers were observed. In irradiated diabetic animals, however, collagen appeared more sparse and immature in relation to diabetic animals.

#### **13<sup>th</sup> post-operative day**

In the specimens from control animals, it was possible to observe an intense red birefringence, indicating the concentration of more tightly-packed matured collagen. The granulation tissue from irradiated animals exhibited less packed intermediate collagen fibers in comparison to the control group, as expressed by some foci of orange-yellow birefringence. In relation to the 7<sup>th</sup> post-operative day, both diabetic and irradiated diabetic groups indeed had an increase in orange and red birefringence. On the other hand, comparing these two groups to the irradiated group, it was possible to infer that, in spite of the increase in collagen content, collagen fibers were not so packed as in the

irradiated specimens. In fact, in the granulation tissue of irradiated diabetic animals, collagen fibers were even more loosely packed.

#### **21<sup>st</sup> post-operative day**

The granulation tissue of control animals presented the most elevated pattern of red birefringence, in relation to the specimens from the other groups studied in this research (Figure 1A). In this phase, the granulation tissue from irradiated animals also exhibited a significant increase in red birefringence, however, not with the same intensity observed in the control specimens (Figure 1B). In comparison with the histological findings of the 13<sup>th</sup> post-operative day, granulation tissue from diabetic animals presented a significant increase in red birefringence, which was not only consistent with an increase in collagen content, but also with the beginning of macromolecular organization of granulation tissue (Figure 1C). Concerning the irradiated diabetic group, red birefringence was clearly evident. However, comparing these specimens with those from irradiated and diabetic animals, it was possible to observe that granulation tissue had a progressively lower amount of packed collagen fibers (Figure 1D).

### **Examination of linear dichroism**

#### **Control and irradiated animals**

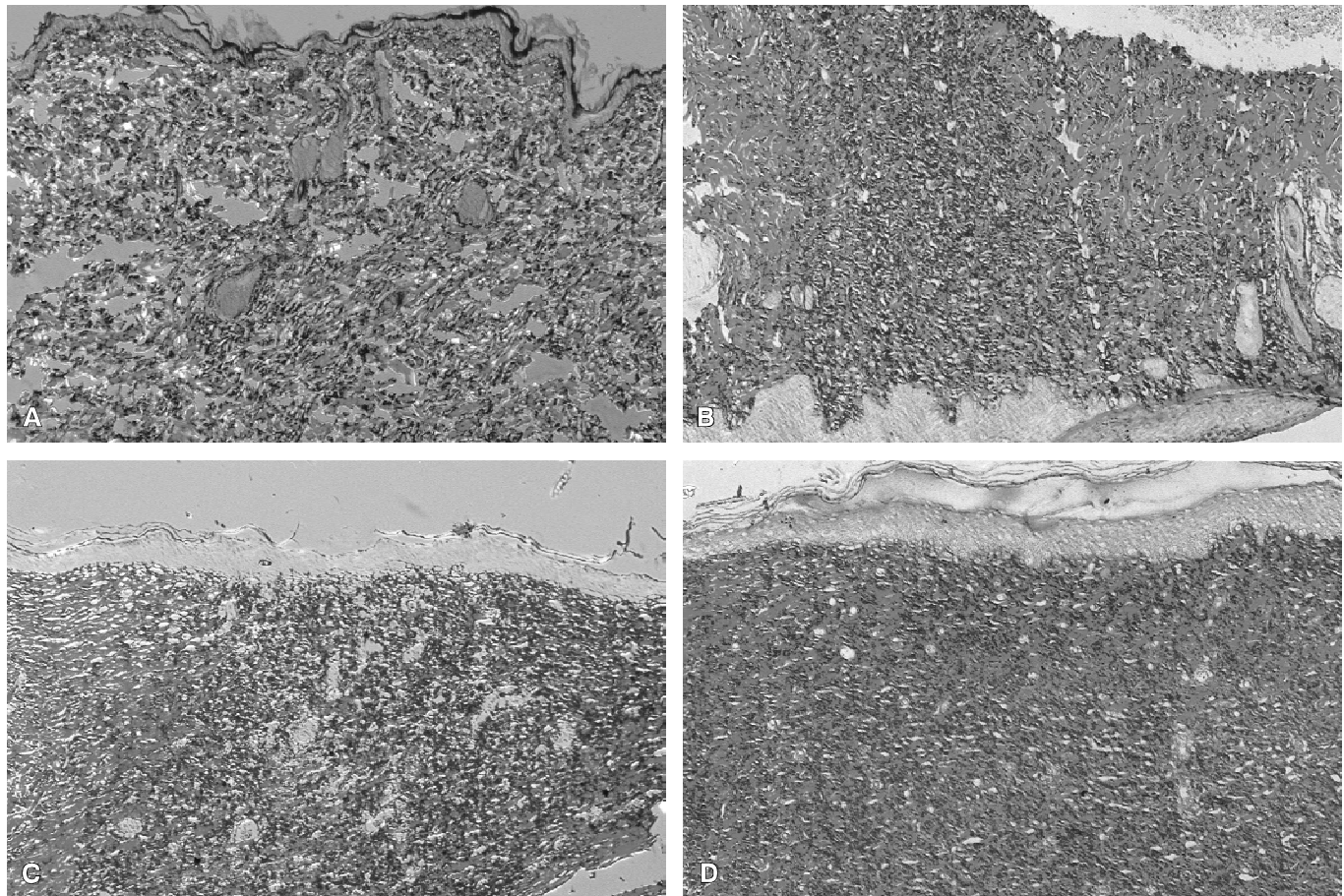
On the 4<sup>th</sup> post-operative day, there was no dichroism in both control and irradiated groups. On the 7<sup>th</sup> post-operative day, dichroism was evident in the control, but it was still not present in the irradiated group. On the 13<sup>th</sup> and 21<sup>st</sup> post-operative days, dichroism was clearly evident in the control and irradiated groups.

#### **Diabetic and irradiated diabetic animals**

On the 4<sup>th</sup>, 7<sup>th</sup> and 13<sup>th</sup> post-operative days, there was no dichroism in the diabetic and irradiated diabetic groups. On the 21<sup>st</sup> post-operative day, the granulation tissue presented a very clear dichroism in both diabetic and irradiated diabetic groups.

## **DISCUSSION**

Concerning fibroplasia, the appearance of granulation tissue following PSR staining corroborates the suspected delay in this event, for irradiated, diabetic and irradiated diabetic animals. On the 4<sup>th</sup> post-operative day, it was possible to notice a considerable difference in birefringence intensity, which was more pronounced in control ani-



**FIGURE 1** - Photomicrographs of the granulation tissue on the 21<sup>st</sup> post-operative day. A: control animal; B: irradiated animal; C: diabetic animal; D: irradiated diabetic animal. (picosirius red staining - original magnification: 6.3 x 1.25 x 10).

mals. However, this characteristic was very subtle in the specimens from irradiated diabetic animals. In spite of the progressive increase in birefringence, considering the evolution of the granulation tissue, on the 21<sup>st</sup> post-operative day, the granulation tissue from control animals presented a higher amount of collagen fibers, which were more tightly packed than those of the irradiated, diabetic and irradiated diabetic animals. The characteristics observed in the specimens from irradiated diabetic animals, which were more severe in comparison with those from irradiated and diabetic animals, suggested that 1 Gy of 6 MeV electron irradiation, delivered in a single dose, has potentiated the deleterious effects of diabetes *mellitus* on fibroplasia. These results highlight two hypothesis: 1) a decrease in the biosynthesis of collagen might have occurred; and 2) during the organization process, the newly-formed collagen fibrils did not become as closely packed as those in the granulation tis-

sue from control animals. That could be attributed to structural damages in collagen or alterations in the metabolism of GAGs.

A significant reduction in collagen fibers content in the granulation tissue from diabetic animals was observed by Devlin *et al.*<sup>5</sup> (1996), Tengrup *et al.*<sup>18</sup> (1988), Spanheimer *et al.*<sup>16</sup> (1988) and Weringer, Arquilla<sup>21</sup>(1981). Tengrup *et al.*<sup>18</sup> (1988) mentioned that a persistent inflammatory reaction with accumulation of polymorphonuclear leukocytes might partly account for the low collagen content in granulation tissue, since these cells contain collagen degrading enzymes, e.g. collagenase. On the other hand, Weringer, Arquilla<sup>21</sup> (1981) observed that fibroblasts from healing wounds of diabetic hamsters contained irregularities in their cytoplasm, which were indicative of internal degeneration. They proposed that this occurred probably in response to an altered extracellular environment, for example, high glucose, edema, and low insulin.

Vizioli<sup>19</sup> (1971) stated that the organization of the granulation tissue is only established when the synthesis of GAGs reaches its maximum. In this study, it was possible to observe linear dichroism in control and irradiated specimens on the 7<sup>th</sup> and 13<sup>th</sup> post-operative days, respectively, which evidenced that granulation tissue was beginning its macromolecular organization. These histological features are in agreement with those described by Monteiro<sup>13</sup> (1999). With respect to both diabetic groups, linear dichroism was detectable only on the 21<sup>st</sup> post-operative day. The delayed macromolecular organization of the granulation tissue in irradiated animals allowed us to suppose that irradiation might not only have negatively influenced fibroplasia, but has also retarded the synthesis of GAGs. The longer delay in detecting dichroism in the specimens from diabetic and irradiated diabetic groups suggests that diabetes might also have negatively influenced the metabolism of GAGs. Taking into account that linear dichroism was detectable on the 13<sup>th</sup> post-operative day in the specimens from irradiated animals, we may infer that the deleterious effects of diabetes *mellitus* are more intense than the radiobiological damage caused by local electron irradiation.

Drózd *et al.*<sup>6</sup> (1981) suggested that the influence of irradiation on connective tissue leads to the degradation of ground substance and observed that irradiation produced severe disturbances in the metabolism of GAGs. The direct mechanism of these changes, however, is still unknown. Hugenberg *et al.*<sup>10</sup> (1989) observed that x-irradiation with doses of 10, 100 and 500 Gy determined a reduction in the synthesis of sulfated GAGs. Almeida<sup>1</sup> (1997) found lower quantities of GAGs in the granulation tissue from irradiated animals and proposed three explanations: 1) a reduction in the biosynthesis of GAGs; 2) a delay in the synthesis

GAGs; and 3) structural damages in GAGs molecules. Since GAGs are synthesized by fibroblasts, which in turn are vulnerable to the effects of ionizing radiations, we might suppose that the decrease in reactive GAGs content may be related to a reduction in the population of fibroblasts in the irradiated tissue, as well as to functional alterations in these cells.

According to Cechowska-Pasko *et al.*<sup>3</sup> (1999), insulin is the main hormone regulating the metabolism of carbohydrates. GAGs are composed of aminohexoses and uronic acids. Both substances are products of the metabolism of glucose, so it seems reasonable to infer that insulin deficiency may also cause disturbances in the metabolism of GAGs. They observed a significant reduction of GAGs in the skin of diabetic rats as a result of a decrease in the biosynthesis of GAGs, especially the sulfated ones. Clark<sup>4</sup> (1988) mentioned that granulation tissue contains predominantly a nonsulfated GAG, consistent with hyaluronic acid, during the initial 4 days of healing, but later on it consists mainly of sulfated GAGs. These macromolecules aggregate with a central protein forming proteoglycans, which, in turn, increase tissue resilience. Therefore, a decrease in skin resilience is another consequence of the diabetic state.

## CONCLUSION

During the period in which wound healing was evaluated, it was possible to observe that local electron irradiation and diabetes *mellitus* caused a decrease in the collagen content of the granulation tissue, which was more accentuated in irradiated diabetic animals. With regard to the macromolecular organization of the granulation tissue, the initial stage of this process was delayed in the specimens from irradiated, diabetic and irradiated diabetic animals, in relation to control animals.

## REFERENCES

1. Almeida SM. Efeito da radiação de elétrons na reparação tecidual [Tese de Doutorado]. Piracicaba: Universidade Estadual de Campinas, Faculdade de Odontologia de Piracicaba; 1997.
2. Bernstein EF, Harisiadis L, Salomon GD, Harrington F, Mitchell JB, Uitto J *et al.* Healing impairment of open wounds by skin irradiation. *J Dermatol Surg Oncol* 1994;20(11):757-60.
3. Cechowska-Pasko M, Palka J, Bankowski E. Decreased biosynthesis of glycosaminoglycans in the skin of rats with chronic diabetes *mellitus*. *Exp Toxicol Pathol* 1999;51(3):239-43.
4. Clark RAF. Overview and general considerations of wound repair. In: Clark RAF, Henson PM. The molecular and cellular biology of wound repair. New York: Plenum Press; 1988. p. 3-33.
5. Devlin H, Garland H, Sloan P. Healing of tooth extraction sockets in experimental diabetes *mellitus*. *J Oral Maxillofac Surg* 1996;54(9):1087-91.
6. Drózd M, Kucharz E, Glowacki A, Zylka J. Effect of irradiation on glycosaminoglycans content in rat tissue. *Arch Immunol Ther Exp (Warsz)* 1981;29(4):514-9.
7. Franzén LE, Roberg K. Impaired connective tissue repair in streptozotocin-induced diabetes shows ultrastructural

- signs of impaired contraction. *J Surg Res* 1995;58(4):407-14.
8. Gardiner TA, Amoaku WMK, Archer, DB. The combined effect of diabetes and ionizing radiation on the retinal vasculature of the rat. *Curr Eye Res* 1993;12(11):1009-14.
  9. Gorodetsky R, McBride WH, Withers HR. Assay of radiation effects in mouse skin as expressed in wound healing. *Radiat Res* 1988;116(1):135-44.
  10. Hugenberg ST, Myers SL, Brandt KD. Suppression of glycosaminoglycan synthesis by articular cartilage, but not of hyaluronic acid synthesis by synovium, after exposure to radiation. *Arthritis Rheum* 1989;32(4):468-74.
  11. Karzmark CJ, Nunan CS, Tanabe E. Medical electron accelerators. New York: McGraw-Hill; 1993. p. 1-31, 33-47.
  12. Loots MAM, Lamme EN, Mekkes JR, Bos JD, Middelkoop E. Cultured fibroblasts from chronic diabetic wounds on the lower extremity (non-insulin-dependent diabetes *mellitus*) show disturbed proliferation. *Arch Dermatol Res* 1999;291(2/3):93-9.
  13. Monteiro SAC. Efeitos da irradiação por elétrons em feridas e em tecidos de granulação [Tese de Doutorado]. Piracicaba: Universidade Estadual de Campinas, Faculdade de Odontologia de Piracicaba; 1999.
  14. Montes GS, Junqueira LCU. The use of the picrosirius-polarization method for the study of the biopathology of collagen. *Mem Inst Oswaldo Cruz* 1991;86 (3 Suppl):1-11.
  15. Rudolph R, Berg JV, Schneider JA, Fisher JC, Poolman WL. Slowed growth of cultured fibroblasts from human radiation wounds. *Plast Reconstr Surg* 1988;82(4):669-75.
  16. Spanheimer RG, Umpierrez GE, Stumpf V. Decreased collagen production in diabetic rats. *Diabetes* 1988;37(4):371-6.
  17. Stajić J, Milovanović A. Radiation and wound healing: evolution of tensile strength in excised skin-wound of irradiated rats. *Strahlentherapie* 1970;139(1):87-90.
  18. Tengrup I, Hallmans G, Ågren MS. Granulation tissue formation and metabolism of zinc and copper in alloxan-diabetic rats. *Scand J Plast Reconstr Surg Hand Surg* 1988;22(1):41-5.
  19. Vizioli MR. Macromolecular organization of rat sponge-induced granulation tissue as revealed by dichroism. *Acta Anat (Basel)* 1971;80(1):73-81.
  20. Wang Q, Dickson GR, Abram WP, Carr KE. Electron irradiation slows down wound repair in rat skin: a morphological investigation. *Br J Dermatol* 1994;130(5):551-60.
  21. Weringer EJ, Arquilla ER. Wound healing in normal and diabetic chinese hamsters. *Diabetologia* 1981;21(4):394-401.
  22. Wetzler C, Kämpfer H, Stallmeyer B, Pfeilschifter J, Frank S. Large and sustained induction of chemokines during impaired wound healing in the genetically diabetic mouse: prolonged persistence of neutrophils and macrophages during the late phase of repair. *J Invest Dermatol* 2000;115(2):245-53.
  23. Zykova SN, Jenssen TG, Berdal M, Olsen R, Myklebust R, Seljelid R. Altered cytokine and nitric oxide secretion *in vitro* by macrophages from diabetic type II-like *db/db* mice. *Diabetes* 2000;49(9):1451-8.

Recebido para publicação em 14/12/01  
Enviado para reformulação em 22/07/02  
Aceito para publicação em 12/09/02