

## Complement activation-related pseudoallergy in dogs following intravenous administration of a liposomal formulation of meglumine antimoniate<sup>1</sup>

Raul R. Ribeiro<sup>2\*</sup>, Eliane P. Moura<sup>3</sup>, Weverton M. Sampaio<sup>3†</sup>, Sydnei M. Silva<sup>4</sup>, Gustavo O. Fulgêncio<sup>5</sup>, Wagner L. Tafuri<sup>3</sup>, Marilene S.M. Michalick<sup>4</sup> and Frédéric Frézard<sup>6</sup>

**ABSTRACT-** Ribeiro R.R., Moura E.P., Sampaio W.M., Silva S.M., Fulgêncio G.O., Tafuri W.L., Michalick M.S.M. & Frézard F. 2013. **Complement activation-related pseudoallergy in dogs following intravenous administration of a liposomal formulation of meglumine antimoniate.** *Pesquisa Veterinária Brasileira* 33(8):1016-1020. Centro de Ciências Agrárias, Ambientais e Biológicas, Universidade Federal do Recôncavo da Bahia, Campus Universitário Cruz das Almas s/n, Cruz das Almas, BA 44380-000, Brazil. E-mail: [raul@ufrb.edu.br](mailto:raul@ufrb.edu.br)

The increasing use of nanotechnologies in advanced therapies has allowed the observation of specific adverse reactions related to nanostructures. The toxicity of a novel liposome formulation of meglumine antimoniate in dogs with visceral leishmaniasis after single dose has been investigated. Groups of 12 animals received by the intravenous route a single dose of liposomal meglumine antimoniate (group I [GI], 6.5 mg Sb/kg), empty liposomes (GII) or isotonic saline (GIII). Evaluation of hematological and biochemical parameters showed no significant changes 4 days after administration. No undesired effects were registered in the GIII. However, adverse reactions were observed in 67.7% of dogs from both groups that received liposomal formulations. The side effects began moments after bolus administration and disappeared during the first 15 minutes after treatment. Prostration, sialorrhoea and defecation were the most frequent clinical signs, registered in 33.3% and 41.6 % of animals from the groups GI and GII, respectively. Tachypnea, mydriasis, miosis, vomiting and cyanosis were also registered in both groups. The adverse reactions observed in this study were attributed to the activation of the complement system by lipid vesicles in a phenomenon known as Complement Activation-Related Pseudoallergy (CARPA). The influence of the physical-chemical characteristics of liposomal formulation in the triggering of CARPA is discussed.

**INDEX TERMS:** Hypersensitivity reactions, Complement Activation-Related Pseudoallergy (CARPA), liposomes, complement activation, canine leishmaniasis.

<sup>1</sup> Received on October 12, 2012.

Accepted for publication on February 15, 2013.

<sup>2</sup> Centro de Ciências Agrárias, Ambientais e Biológicas, Universidade Federal do Recôncavo da Bahia. Campus Universitário Cruz das Almas s/n, Cruz das Almas, BA 44380-000, Brazil. \*Corresponding author: [raul@ufrb.edu.br](mailto:raul@ufrb.edu.br)

<sup>3</sup> Departamento de Patologia, Instituto de Ciências Biológicas, Universidade Federal de Minas Gerais (UFMG), Av. Antônio Carlos 6627, Belo Horizonte, MG 31270-901, Brazil.

<sup>4</sup> Departamento de Parasitologia, Instituto de Ciências Biológicas, UFMG, Belo Horizonte, MG.

<sup>5</sup> Departamento de Clínica e Cirurgia Veterinárias, Escola de Veterinária, UFMG, Belo Horizonte, MG.

<sup>6</sup> Departamento de Fisiologia e Biofísica, Instituto de Ciências Biológicas, UFMG, Belo Horizonte, MG.

**RESUMO.- [Pseudoalergia relacionada à ativação do complemento em cães após administração intravenosa de uma formulação lipossomal de antimoniato de meglumina.]** O crescente uso das nanotecnologias nas terapias avançadas tem permitido a observação de reações adversas específicas relacionadas às nanoestruturas. A toxicidade de uma nova formulação lipossomal de antimoniato de meglumina após dose única foi avaliada em cães com leishmaniose visceral. Grupos de 12 animais receberam por via intravenosa uma dose única de antimoniato de meglumina lipossomal (grupo I [GI], 6,5 mg Sb/kg), lipossomas vazios (GII) ou solução salina isotônica (GIII). A avaliação de parâmetros hematológicos e bioquímicos não revelou

alterações significativas quatro dias após a administração. Nenhum efeito indesejável foi registrado no GIII. No entanto, reações adversas foram observadas em 67,7% dos cães de ambos os grupos que receberam formulações lipossomais. Os efeitos colaterais iniciaram momentos após a administração em “bolus” e desapareceram no decurso dos primeiros 15 minutos após o tratamento. Prostração, sialorréia e defecação foram os sinais clínicos mais frequentes, registrados em 33,3% e 41,6% dos animais dos grupos GI e GII, respectivamente. Taquipnéia, midríase, miose, vômitos e cianose também foram registrados em ambos os grupos. As reações adversas observadas neste trabalho foram atribuídas à ativação do sistema complemento pelas vesículas lipídicas em fenômeno conhecido como Pseudoalergia Relacionada à Ativação do Complemento (PARAC). A influência das características físico-químicas da formulação lipossomal no desencadeamento de PARAC é abordada.

**TERMOS DE INDEXAÇÃO:** Reações de hipersensibilidade, Pseudoalergia Relacionada à Ativação do Complemento (PARAC), lipossomas, ativação do complemento, leishmaniose canina.

## INTRODUCTION

Conventional therapies for numerous diseases in human and animals may be further improved through the innovative strategies of nanomedicine. According to the United States' National Institutes of Health, this new area can be defined as “an offshoot of nanotechnology, which refers to highly specific medical interventions at the molecular scale for curing disease or repairing damaged tissues, such as bone, muscle, or nerve” (Webster 2006). In this context, the development of various types of drug-carrier nanodevices offers new strategies for targeted drug delivery, minimizing the secondary effects and the toxicity associated to drug widespread to healthy organs or cells (Irache et al. 2011).

The therapeutic approach for intracellular diseases is a real example of the benefits that can provide the nanotechnology revolution in the pharmaceutical area. The intracellular nature of some pathogens often requires long-term therapy and combination of drugs, since the host cell membranes may protect them from a variety of drugs and host immune responses (Armstead & Li 2011). In that sense, the use of drug delivers, e.g. liposomes, provides satisfactory therapeutic responses in canine visceral leishmaniasis (CVL) (Valladares et al. 2001, Frézard & Demicheli 2010). The properties of drug sustained release and targeting promote high concentrations of the encapsulated drug in the major sites of parasite infection, improving the drug effectiveness. When compared to conventional antimonial drugs such as meglumine antimoniate (MA), liposomal formulations were hundreds of times more effective against visceral leishmaniasis in mice, hamsters and dogs (Chapman et al. 1984, Alving 1986, Croft 1986). Despite the increased leishmanicidal activity of antimonial drugs, no liposomal formulation of Sb has reached the market so far. Furthermore, some experimental formulations produced acute toxicity in dogs, including chills and diarrhea, which cleared by 24 h postdosing, and hepatic dysfunction at 24 h postdosing (Nieto et al. 2003).

Although the biocompatibility is an important feature of any drug delivery system, the nanodevices carry an increased risk for hypersensitivity reactions. Acute immune toxicity was reported after administration of liposomal drugs (Ambisome®, Doxil® and Dauno Xome®), radiocontrast media and micellar solvents containing amphiphilic lipids (Szebeni 2005). There is substantial evidence suggesting that these acute allergic reactions are not mediated by pre-existing IgE antibodies (Hypersensitivity Type I), but by complement activation (Szebeni 2005), in a phenomenon aptly called Complement Activation-Related Pseudoallergy (CARPA). It was also established that vesicle structural factors of liposomes (e.g. phospholipid composition, vesicle size and surface charge) could modulate complement activation and CARPA (Szebeni et al. 2000, Szebeni et al. 2012).

As part of our continuous efforts to characterization and development of a novel liposomal formulation (Brazilian Patent Pending INPI/2640), this study determined the profile of adverse reactions in dogs naturally infected with *Leishmania infantum* after single dose of liposomal MA and discussed its possible mechanism taking into account the physico-chemical characteristics of therapeutic formulation.

## MATERIALS AND METHODS

### Animals

Thirty-six mongrel dogs (weighing 8-15 kg) naturally infected with *L. infantum*, exhibiting different clinical forms of CVL, were identified and captured during an epidemiological survey carried out by Control Zoonosis Center in Santa Luzia City Hall (Minas Gerais state, Brazil Southeast). The serological diagnosis was established by the Serology Laboratory of the Institute of Biological Sciences, Federal University of Minas Gerais (UFMG) by indirect immunofluorescence assay (IFAT) and enzyme-linked immunosorbent assay (ELISA). All animals were found to be positive by IFAT ( $\geq 1:40$  dilutions) and ELISA (optical density  $>0.100$ ;  $\geq 1:400$  dilutions). In addition, parasitological diagnosis was performed by observation of parasite forms in both cytological examinations and/or cultures of bone marrow aspirates in Novy-Nicolle-McNeal (NNN) enriched with minimum essential medium ( $\alpha$ -MEM). Prior to treatment, the animals were maintained in quarantine in kennels and were treated for intestinal helminthic infections (Canex composto®, Vetbrands Health Animal), ectoparasites infestations (Front Line®, Merial) and immunized against viral infections (Defensor® and Vanguard® HTLP 5/CV-L, vaccine Pfizer, Brazil). During the whole experimental period, the dogs were housed in a screened kennel and received drinking water and a balanced feed *ad libitum* (Pedigree Champ®, Effem). The present research adhered to the Principles of Laboratory Animal Care (NIH publication #85-23, revised in 1985) and received approval from the Ethical Committee for the use of Experimental Animals (CETEA) of the UFMG (Brazil) protocol n° 123/05.

### Materials

Cholesterol (CHOL) and dicetylphosphate (DCP) were purchased from Sigma Co. (St. Louis, MO, USA). Distearoylphosphatidylcholine (DSPC) was obtained from Avanti Polar Lipids Inc. (Alabaster, AL, USA). N-methyl-D-glucamine and antimony pentachloride ( $SbCl_5$ , 99%) were obtained from Aldrich Chemical Co. (Milwaukee, Wis, USA).

### Preparation of meglumine antimoniate

MA was synthesized as previously described (Demicheli et al. 2003) from an equimolar mixture of N-methyl-D-glucamine

and pentavalent antimony oxyhydrated in water. The resulting product contained approximately 29% of antimony by weight, as determined by plasma emission spectroscopy (ICP-OES) using a Perkin-Elmer Optima 3000 plasma emission spectrometer.

### Preparation and characterization of meglumine antimoniate-containing liposomes

MA-containing liposomes with reduced size were prepared as described previously (Schettini et al. 2006). Briefly, small unilamellar vesicles (SUVs) were obtained by ultrasonication of a suspension of multilamellar vesicles in de-ionized water, made from DSPC, CHOL and DCP (molar ratio of 5:4:1) at the final lipid concentration of 55 g/L. After filtration through sterile 0.22 µm membrane, the SUVs suspension was mixed with sucrose at a sugar/lipid mass ratio of 3:1 and a final sugar concentration of 0.3 M. The resulting mixture was immediately frozen in liquid nitrogen and subsequently dried (freeze-dryer, 4.5 L, Labconco, UK). Rehydration of the dried powder was performed with a MA aqueous solution (antimony concentration of 0.65 M) and phosphate-buffered saline (PBS: 0.15 M NaCl, 0.01 M phosphate, pH 7.2) as follows: 40 percent of the original SUVs volume of MA solution was added to the lyophilized powder and the mixture was vortexed and incubated for 30 min at 55°C; the same volume of PBS was then added and the mixture was vortexed and incubated for 30 min at 55°C. Drug-containing liposomes were separated from non-encapsulated drug by centrifugation (14,000Xg, 30 min). The liposome pellet was then washed twice and finally resuspended in isotonic saline at a final antimony concentration of about 10 g/L. The concentration of encapsulated antimony and the phospholipid concentration were determined in the resulting liposome suspension, using previously described colorimetric assays (Schettini et al. 2006). The mean hydrodynamic diameter of the vesicles was 400 nm, with a mean polydispersity factor of 0.3. Empty liposomes with a comparable mean hydrodynamic diameter were obtained using the same method as that described above, except that the meglumine antimoniate solution was replaced by a 0.65 M N-methyl-D-glucamine aqueous solution at pH 7.2.

### Treatment protocol

Thirty-six dogs were stratified by weight, sex and clinical forms and randomly distributed into three groups, each group containing initially four asymptomatic, four oligosymptomatic and four symptomatic dogs (Mancianti et al. 1988). Group I was treated with a single dose of liposomal MA at 6.5 mg Sb/kg/dose. Group II received a single dose of antimony-free liposomes given at the same lipid dose as in group I. Group III received a single dose of isotonic saline given at the same volume as in group I.

### Toxicity studies

The animals from groups I, II, and III were evaluated for clinical and behavioral changes as well as for changes in some hematological and biochemical markers of hematopoietic, hepatic, and renal functions before and 4 days after treatment. Temperature and food and water intake were registered, and heart and respiratory frequencies were measured. Blood samples were taken from the cephalic vein contralateral to that used for infusion for analysis of hemogram (red blood cells, packed cell volume, hemoglobin, white blood cells, neutrophils, lymphocytes, monocytes, eosinophils, and platelets), renal profile (urea and creatinine), and hepatic profile (aspartate aminotransferase, alanine aminotransferase, alkaline phosphatase, and total bilirubins).

## RESULTS

Table 1 shows the frequency of adverse reactions in dogs with leishmaniasis after treatment with different liposomal

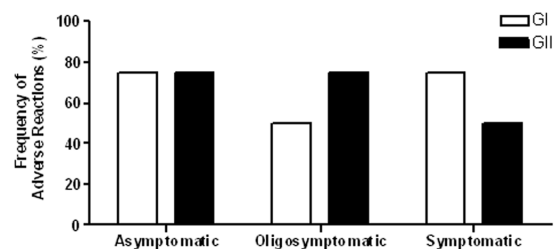
**Table 1. Frequency of adverse reactions observed in dogs naturally infected with *Leishmania infantum* after intravenous administration of single dose of different liposomal formulations**

Adverse reactions	Experimental groups			
	GI (n=12) %	GII (n=12) %	GIII (n=12) %	Liposomal formulations (n=24) %
None reactions	33,3	33,3	100	33,3
Prostration	41,6	33,3	0	37,3
Sialorrhea	33,3	33,3	0	33,3
Defecation	33,3	33,3	0	33,3
Tachypnea	16,6	25	0	20,8
Mydriasis	25	16,6	0	20,8
Miosis	25	25	0	25
Vomiting	8,3	8,3	0	8,3
Cyanosis	8,3	8,3	0	8,3
Tachycardia	0	8,3	0	4,1
Tremor muscle	0	8,3	0	4,1
Urination	0	8,3	0	4,1
Xerostomia	8,3	0	0	4,1
Hypotension	8,3	0	0	4,1

Data are given as percentage of the dogs that showed different adverse reactions in accordance with each experimental group. GI: single intravenous dose of liposomal meglumine antimoniate (400nm) at 6.5mg de Sb/kg; GII: single dose of empty liposomes at the same lipid dose as in GI; GIII: single dose of isotonic saline at the same volume as GI and GII; Liposomal Formulations: considering the animals from de group GI and GII, that is dogs who received treatment with liposomal formulation.

formulations. In general, a single intravenous dose of liposomal formulations, either containing MA (n=12) or empty, resulted in similar profiles and intensities of adverse reactions. The clinical reactions began moments after bolus administration and disappeared during the first 15 minutes, involving 67.7% of dogs from both groups that received liposomal formulations. No adverse effect was observed in the control group (saline).

Prostration, sialorrhea, and defecation were the most frequent signs, affecting between 33.3 and 41.6 % of animals from GI and GII groups (Table 1). Tachypnea, mydriasis and miosis were observed in three (16.6 %) or four (25 %) animals per group. Tremor muscle, tachycardia, urination and cyanosis were observed once (8.3%) only in GII. On the other hand, two dogs from GI only each showed xerostomia (8.3%) and hypotension (8.3%). Vomiting was registered in one animal of each group, resulting in 8.3% of frequency. The clinical condition of infected animals apparently did not influence the toxicity of liposomal formulations (Fig.1).



**Fig. 1.** Frequency of adverse reactions observed in dogs classified according to clinical forms of leishmaniasis, after administration of single dose of liposomal formulations. GI: liposomal meglumine antimoniate (400nm) by i.v. route at 6.5mg Sb/kg/dose; GII: antimony-free liposomes by i.v. route at the same lipid dose as in GI; n=4 for each clinical condition.

No hematologic, hepatic and renal laboratory toxicity were registered (data not shown).

## DISCUSSION

One of the main objectives of the Brazilian Group for Research and Development of Leishmanicidal Drugs has been the design and development of liposomal formulations of MA (Brazilian Patent Pending INPI/2640). Since the first assays of liposomal formulations in canine model, our group has registered side effects (Costa Val 2004, Ribeiro et al. 2008). However, the assessment of the specific profile of reactions after single dose in dogs with different clinical forms of leishmaniasis and the discussion of the triggered mechanism and its relation with the vesicle characteristics have not been made.

The equal participation of different clinical conditions in the groups was important, not only because it involves the diverse realities that are encountered in clinical veterinary practice, but also because the development of the disease may enhance the acute toxicity of formulations (Amusatogui 1998). Interestingly, the clinical forms of leishmaniasis have no significant influence on the profile and intensity of side effects.

The side effects registered in this study could not be attributed to Sb, because there was no difference between the groups treated with liposomal MA (GI) and empty liposomes (GII). Furthermore, the toxic effects of the metal, including arthralgia, myalgia, diarrhea, anorexia and inflammation at the site of inoculation (Alvar et al. 2004), are expected only upon chronic treatment and should not disappear spontaneously.

The increasing use of advanced therapies based on nanotechnology have allowed the observation of signs of acute immune toxicity with distinct characteristics of hypersensitivity reactions groups traditionally accepted and described by Coombs and Gell in 1968 (Szebeni 2005). In these cases, the allergen led to activation of the complement system, a phenomenon that has been named CARPA. Thus, it is likely that the acute clinical adverse reactions observed in this work were consequence of the action of anaphylatoxins (C3a and C5a) released after activation of the complement cascade by the lipid vesicles. There is extensive literature on complement system activation by liposomes (Devine et al. 1994, Liu et al. 1995, Szebeni 2005). Natural antibodies against phospholipids and cholesterol are present in all animal species (Wassef et al. 1989) and the binding of these proteins to lipids of liposomes would allow the activation of complement through the classic route (Liu et al. 1995). There is also the possibility of activating the complement cascade by the alternative route (Funato et al. 1992). Probably, the increase of the pulmonary arterial pressure, the reduction of the cardiac debit (Szebeni et al. 2000) and the increase of pulmonary and peripheral vascular resistance, generated by the products of the complement, provided a transitional circulatory collapse that resulted in tissue hypoxia. Consequently the sympathetic nervous system was stimulated and resulted in some the clinical signs observed: tachycardia, tachypnea, mydriasis

and xerostomia. As a compensatory mechanism, the parasympathetic nervous system was also stimulated providing the reactions of miosis, sialorrhea, vomiting, urination and defecation.

The occurrence of clinical effects just after the contact with allergen is a common symptom between CARPA and classical hypersensitivity type I (IgE-mediated), but the high reaction rate (66.6% of animals) and spontaneous resolution of adverse reactions are features exclusive of the activation of complement (Szebeni 2005). In CARPA, the toxicity reaches a peak between one and five minutes after the administration of the formulation (Szebeni 2005) and, in the present study, the side effects have always been included in the first fifteen minutes after treatment. Indeed, the presence of DCP in the lipid composition of liposomes is probably critical, since it ensures anionic character of the vesicles, which is expected to accelerate protein binding onto the surface of the vesicles (Szebeni et al. 2000).

Costa Val (2004) described occurrence of similar adverse reactions in dogs treated with empty liposome. However, no effect was observed in the groups that received saline, free MA and liposomal MA. Although the lipid composition used was the same, the mean hydrodynamic diameter of the vesicles (1200 nm) was greater than that used in this study (400 nm). In theory, the binding of antibodies to liposomes and subsequent activation of the complement system should be proportional to the total vesicular surface area exposed to plasma (Szebeni et al. 2000). Comparing the results of Costa Val (2004) and ours, it is likely that the smaller surface area of contact in micrometric vesicles and the lowest dose of lipid applied provided a less effective activation of the complement system.

No hematologic, hepatic and renal laboratory toxicity were observed 96 hours after administration of formulations. Although the activation of complement appears to be an intrinsic property of lipid bilayers formed by cholesterol and electrically charged phospholipids (Devine et al. 1994), laboratory changes associated of systems carriers of drugs can be observed in the absence of clinical effects (Valladares et al. 2001).

Since the speed of entry of liposomes in the vascular system is considered critical factor for activation of the complement (Szebeni et al. 2000), the intravenous administration of this formulation by continuous infusion in fluid therapy should reduce or eliminate some or all of the side effects observed, without changing the characteristics of the product. Another proposal for reducing the frequency of CARPA would be the premedication of patients with antihistamines and corticosteroids.

In future studies, *in vitro* and *in vivo* tests for complement activation may be useful to determine the mechanism of the immunotoxicity of the formulation, in accordance with the US Food and Drug Administration (FDA) recommendations.

**Acknowledgements.** - This research was supported by Laboratório de Sorologia/ICB/UFMG and the Brazilian agencies: CNPq/MCT (477003/2004-4, 303046/2009-0, 473534/2010-0), Fapemig (CBB 165/07, Rede 221/08, Pronex 2009, APQ-01935-09, PPM-00382-11) and Fapebio/UFMG.

## REFERENCES

- Alvar J, Cañavate C., Molina R., Moreno J. & Nieto J. 2004. Canine leishmaniasis. *Adv. Parasitol.* 57:1-88.
- Alving C.R. 1986. Liposomes as drug carriers in leishmaniasis and malaria. *Parasitol. Today* 2:101-107.
- Amusatogui I. 1998. Tratamiento de la leishmaniosis canina: valoración, caracterización y comparación de la respuesta a distintos protocolos a base de antimonio de meglumina asociado o no al alopurinol. Tesis de Doctorado en patología y clínica equina, Facultad de Veterinaria, Universidad Complutense de Madrid, Madrid. 315p.
- Armstead A.L. & Li B. 2011. Nanomedicine as an emerging approach against intracellular pathogens. *Int. J. Nanomed.* 6:3281-3293.
- Brazilian Patent Pending INPI/2640 - Frézard F., Demicheli C., Schettini D.A., Ribeiro R.R., Melo M.N. & Michalick M.S.M. November 2004.
- Chapman W.L., Hanson W.L., Alving C.R. & Hendricks L.D. 1984. Antileishmanial activity of liposome-encapsulated meglumine antimonate in the dog. *Am. J. Vet. Res.* 45:1028-1032.
- Costa Val A.P. 2004. Tratamento da leishmaniose visceral canina com antimonial pentavalente encapsulado em lipossomas. Tese de Doutorado em Ciência Animal, Escola de Veterinária, Universidade Federal de Minas Gerais, Belo Horizonte, MG. 125p.
- Croft S.L. 1986. Liposomes in the treatment of parasitic diseases. *Pharm. Int.* 7:229-233.
- Demicheli C., Ochoa R., Lula I.S., Gozzo F.C., Eberlin M.N. & Frézard F. 2003. Pentavalent organoantimonial derivatives: two simple and efficient synthetic methods for meglumine antimonate. *Appl. Organomet. Chem.* 17:226-231.
- Devine D.V., Wong K., Serrano K., Chonn A. & Cullis P.R. 1994. Liposome-complement interactions in rat serum: implications for liposome survival studies. *Biochem. Biophys. Acta* 1191:43-51.
- Frézard F. & Demicheli C. 2010. New delivery strategies for the old pentavalent antimonial drugs. *Expert. Opin. Drug Deliv.* 12:1343-1358.
- Funato K., Yoda R. & Kiwada H. 1992. Contribution of complement system on destabilization of liposomes composed hydrogenated egg phosphatidylcholine in rat fresh plasma. *Biochim. Biophys. Acta* 1103:198-204.
- Irache J.M., Esparza I., Gamazo C., Agüeros M. & Espuelas S. 2011. Nanomedicine: Novel approaches in human and veterinary therapeutics. *Vet. Parasitol.* 180:47-71.
- Liu D., Song Y.K. & Liu F. 1995. Antibody dependent complement mediated liver uptake of liposomes containing GM<sub>1</sub>. *Pharm. Res.* 12:1775-1780.
- Mancianti F., Gramiccia M., Gradoni L. & Pieri S. 1988. Studies on canine leishmaniasis control. I. Evolution of infection of different clinical forms of canine leishmaniasis following antimonial treatment. *Trans. R. Soc. Trop. Med. Hyg.* 82:566-567.
- Nieto J., Alvar J., Mullen A.B., Carter K.C., Rodríguez C., San Andrés M.I., San Andrés M.D., Baillie A.J. & González F. 2003. Pharmacokinetics, toxicities, and efficacies of sodium stibogluconate formulations after intravenous administration in animals. *Antimicrob. Agentes Chemother.* 47:2781-2787.
- Ribeiro R.R., Moura E.P., Pimentel V.M., Sampaio W.M., Silva S.M., Schettini D.A., Alves C.F., Melo F.A., Tafuri W.L., Demicheli C., Melo M.N., Frézard F. & Michalick M.S. 2008. Reduced tissue parasitic load and infectivity to sand flies in dogs naturally infected by *Leishmania (Leishmania) chagasi* following treatment with a liposome formulation of meglumine antimonate. *Antimicrob. Agentes Chemother.* 57:2564-2572.
- Schettini D.A., Ribeiro R.R., Demicheli C., Rocha O.G.F., Melo M.N., Michalick M.S.M. & Frézard F. 2006. Improved targeting of antimony to the bone marrow of dogs using liposomes of reduced size. *Int. J. Pharm.* 315:140-147.
- Szebeni J. 2005. Complement activation-related pseudoallergy: A new class of drug-induced acute immune toxicity. *Toxicology* 216:106-121.
- Szebeni J., Baranyi L., Savay S., Bodo M., Morse D.S., Basta M., Stahl G.L., Bunger R. & Alving C.R. 2000. Liposome-induced pulmonary hypertension: properties and mechanism of a complement-mediated pseudoallergic reaction. *Am. J. Physiol. Heart Circ. Physiol.* 279:1319-1328.
- Szebeni J., Bedőcs P., Rozsnyay Z., Weiszhar Z., Urbanics R., Rosivall L., Cohen R., Garbuzenko O., Báthori G., Tóth M., Bünger R. & Barenholz Y. 2012. Liposome-induced complement activation and related cardiopulmonary distress in pigs: factors promoting reactogenicity of Doxil and AmBisome. *Nanomedicine* 8:176-184.
- Valladares J.E., Riera C., González-Ensenyat P., Diaz-Cascon A., Ramos G., Solano-Gallego L., Gállego M., Portús M., Arboix M. & Albertola J. 2001. Long term improvement in the treatment of canine leishmaniasis using an antimony liposomal formulation. *Vet. Parasitol.* 97:15-20.
- Wassef N.M., Johnson S.H., Graeber G.M., Swartz G.M., Schultz C.L., Hailey J.R., Johnson A.J., Taylor D.G., Ridway R.L. & Alving C.R. 1989. Anaphylactoid reactions mediated by autoantibodies to cholesterol in miniature pigs. *J. Immunol.* 143:2990-2995.
- Webster T.J. 2006. Nanomedicine: What's in a definition? *Int. J. Nanomed.* 1:115-116.