

Celioscopic liver biopsy in silver catfish (*Rhamdia quelen*)¹

João P.S. Feranti², Luciana D. Guimarães³, Marília T. de Oliveira², Hellen F. Hartmann², Fernando W. de Souza², Luís F.D. Corrêa², Marco A.M. Silva⁴ and Maurício V. Brun^{2*}

ABSTRACT. Feranti J.P.S., Guimarães L.D., Oliveira M.T., Hartmann H.F., Souza F.W., Corrêa L.F.D., Silva M.A.M. & Brun M.V. 2015. **Celioscopic hepatic biopsy in silver catfish (*Rhamdia quelen*).** *Pesquisa Veterinária Brasileira* 35(1):19-22. Departamento de Clínica de Pequenos Animais, Centro de Ciências Rurais, Universidade Federal de Santa Maria, Camobi, Santa Maria, RS 97105-900, Brazil. E-mail: mauriciovelosobrun@hotmail.com

Endosurgery has been used for assessment of fish celomatic cavity, as well as for obtaining biopsies for organic analysis. Such minimally invasive access may also be used for the analysis of environmental impact on biomarkers of pollution. In Brazil, studies and literature regarding the use of celioscopy in fish are sparse. The purpose of the current study was to develop a two-port celioscopy technique to obtain liver biopsy in silver catfish (*Rhamdia quelen*). Six adult female silver catfish were used. The animals were anesthetized and the inspection of the celomatic cavity were performed using a telescope and celioscopic-guided liver biopsy were taken using laparoscopic Kelly forceps. On the early postoperative period, the animals were released in a confined water reservoir where mortality could be checked. The liver samples were sent for histological assessment. There were no complications during surgery on early postoperative period. It was possible to visualize meticulously several organs (liver, spleen, stomach, pancreas, swim bladder, ovaries, bowel and transverse septum). In conclusion, the surgical technique and the anesthetic protocol proposed were suitable to perform liver biopsies in silver catfish and provided low morbidity.

INDEX TERMS: Liver biopsy, silver catfish, *Rhamdia quelen*, surgery, laparoscopy, celomatic cavity.

RESUMO. [Biópsia hepática celioscópica em jundiás (*Rhamdia quelen*)] A videocirurgia vem sendo utilizada em avaliações da cavidade celomática de diferentes peixes, bem como na obtenção de biopsias para análises de órgãos. Esse acesso, minimamente invasivo, pode ainda ser empregado no estudo de impactos ambientais, a partir do uso desses animais como bioindicadores de poluentes. No

Brasil, poucos são os estudos envolvendo a realização de celioscopia de peixes. Este trabalho teve como objetivo, desenvolver uma técnica de videocelioscopia, a partir da utilização de dois portais, na obtenção de biópsia hepática em jundiás (*Rhamdia quelen*). Para o estudo, foram utilizadas seis fêmeas adultas. Após os animais serem anestesiados, realizou-se a inspeção da cavidade celomática com endoscópio de 10mm e 0° para na sequência, realizar a coleta de tecido hepático com pinça de Kelly. Após a recuperação anestésica/cirúrgica, os animais foram liberados em aqüedro que permitia o controle de possíveis óbitos. Todas as amostras de tecido hepático foram encaminhadas a exame histopatológico. Os procedimentos foram realizados sem a ocorrência de complicações trans ou pós-operatórias. Visualizou-se detalhadamente diferentes órgãos e estruturas intracavitárias (fígado, baço, estômago, pâncreas, bexiga natatória, ovários, intestino grosso e septo transverso. Concluiu-se que a técnica cirúrgica e o protocolo anestésico proposto são adequadas para a realização de biópsias hepáticas em jundiás e estão associados a diminuta morbidade.

¹ Received on November 27, 2014.

Accepted for publication on December 12, 2014.

² Laboratório de Cirurgia Experimental, Departamento de Clínica de Pequenos Animais (DCPA), Centro de Ciências Rurais (CCR), Universidade Federal de Santa Maria (UFSM), Av. Roraima 1000, Santa Maria, RS 97105-900, Brazil. Fellow of CNPq/Brazil. *Corresponding author: mauriciovelosobrun@hotmail.com

³ Departamento de Clínica Médica, FAMEV, Universidade Federal do Mato Grosso (UFMT), Av. Fernando Correa da Costa s/n, Cuiabá, MT 78080-900, Brazil.

⁴ Departamento de Cirurgia de Pequenos Animais, Faculdade de Agronomia e Medicina Veterinária, Curso de Medicina Veterinária, Universidade de Passo Fundo (UPF), BR-285, São José, Passo Fundo, RS 99052-900, Brazil.

TERMOS DE INDEXAÇÃO: Biópsia hepática, jundiás, *Rhamdia quelen*, cirurgia, videolaparoscopia, cavidade celomática.

INTRODUCTION

Endosurgery has been used for assessing the celomatic cavity in fish, as well as for obtaining liver biopsy for organic assessment (Murray 1998). Such minimally invasive access may also be used for the analysis of environmental impact on biomarkers of pollution. In Brazil, studies and literature regarding the use of celioscopy in fish are sparse (Brun et al. 2004).

The silver catfish (*Rhamdia quelen*), which is also known in Brazil as jundiá, presents several desirable characteristics for breeding, such as roughness, fast growth, good adaptation to elaborate diets and environmental changes (Carneiro et al. 2002, Carneiro & Mikos 2005, Correia et al. 2009, Fracalossi et al. 2004, Pedron et al. 2008,). It is also a promising specie for intensive systems of breeding, as well as for its good acceptance by fish consumers and increased commercial value (Fracalossi et al. 2007, Silva et al. 2008), which is considered such an important specie for aquiculture in Southern Brazil.

Systematization of a minimally invasive surgical technique for sampling tissues of animal species that are considered economically relevant may provide further information concerning the assessment of contamination of fish with pollutants, besides other issues on physiology and reproductive maturity.

The purpose of this study was to develop a technique for two-port celioscopic liver biopsy in silver catfish (*Rhamdia quelen*).

MATERIALS AND METHODS

Six adult female silver catfish (*Rhamdia quelen*), weighting 1505.00 ± 551.68 g were assessed in this study. Prior to surgery, the fish were kept in a chloride-free water containers, with quinaldine (1gt/l) (Fig.1A). Following decrease of the operculum movements, ketamine (Dopalen®, Vetbrands, Cotia/SP, Brazil) (50mg kg^{-1}) and xylazine (Xilazin®, Syntec, São Paulo/SP, Brazil) (3mg kg^{-1}) were administered intramuscularly in the lumbar area (Fig.1B). the patients were subsequently placed in dorsal recumbence on a small dog surgical chute, in a water recirculation system, supplemented with 100% oxygen (Fig.1C).

Aseptic prepare of the surgical field was carried out using chlorhexidine 1% water solution, followed by placement of plastic surgical fields. A skin incision was performed between the pectoral fin and the genital orifice (Fig.1D), followed by the insertion of a 10-mm laparoscopic trocar, which provided passage for a 10mm, 0° telescope (Karl Storz™, distributed by H. Strattner, São Paulo, SP, Brazil). A 8-mmHg pneumoperitoneum was created using a 1-l/min flow rate, followed by insertion of a second 5-mm trocar under celioscopic guidance, on the left muscular wall. The celomatic cavity was inspected and, subsequently, a liver specimen was taken using 5-mm a laparoscopic Kelly forceps (Fig.1E). The excision of the hepatic tissue was carried out by twisting the tip of the forceps on its axis (Fig.1F), which was triggered on the handle of the instrument. Such modified technique was used as no laparoscopic biopsy forceps was available. The specimen was pulled within the trocar, which was withdrawn from the celomatic cavity along with the forceps. The 10-mm cannula was also retrieved and the celomatic cavity was deflated. Wounds were sutu-

red using polyglactin 910 3-0 USP thread in two layers: muscular layer was closed using the cruciate mattress suture and skin was sutured using the interrupted horizontal mattress suture.

Postoperative care included flunixin meglumine (Banamine®, Schering-Plough, São Paulo, SP, Brazil), (1mg kg^{-1} , IM, SID, for 3 days), and chloramphenicol (10mg l^{-1} of water, for 5 days). Following the medication period, the animals were released in a confined reservoir, which allowed for the assessment in case of death. The samples were stored in formaldehyde 10% buffered solution and sent to histological assessment.

The study was approved by the Committee for Ethics on Animal Use of the University of Passo Fundo (protocol no. 14/2006).

RESULTS AND DISCUSSION

The procedures were carried out uneventfully and no complications occurred. Anesthesia and overall surgical time were 30.83 ± 11.68 min and 16 ± 4.51 min, respectively. Regarding the anesthesia regimen, quinaldine sulphate provided good sedation for subsequent anesthesia induction, acting as a depressant of the medullar centers and thus leading to loss of equilibrium (Stoskopf 1993). The number and positioning of the ports, as well as induction and maintenance of the pneumoperitoneum, provided both adequate liver tissue sampling and inspection of the celomatic cavity.

The following organs were clearly inspected under image magnification: liver, spleen, stomach, pancreas, swim bladder, ovaries, bowels and transverse septum. By the transverse septum, it was possible to assess cardiac frequency, which is hard to evaluate using monitors, such as pulse oximeters. Moreover, the importance of cardiac assessment provided good anesthesia depth control following suppression of the movements of the operculum and alterations on the oral mucosa, which occurred in all fish due to the anesthesia regimen employed.

Histologic assessment of the liver samples revealed lipoidosis in 66% of the animals and absence of lesions on the remaining ones. Such finding was justified by the high protein-based diet that was provided prior to the beginning of the study.

The two-port surgical technique used in the current study was different from the one described by Brun et al. (2004). Those authors used a third trocar for insertion of an additional Kelly forceps, for application of Roeder's knot ligature, if required, for complementary hemostasis of the liver parenchyma. The following procedures have shown that grasping and rotating the tip of the liver was enough to provide adequate sample for diagnosis in carp. Such maneuver was not associated to hemorrhage, while providing quick and non-technically demanding biopsy. Thus, it was shown that two ports are sufficient in order to perform celioscopic liver biopsy in silver catfish, even though in those small ones.

Another interesting technical aspect of celioscopy was the ability to accomplish complete exam of the celomatic cavity, with no need for changing positioning of the animal on the surgical table, which was indicated by others (Murray et al. 1998). One can hypothesize that such maneuver could be time consuming. If improved tissue exposition

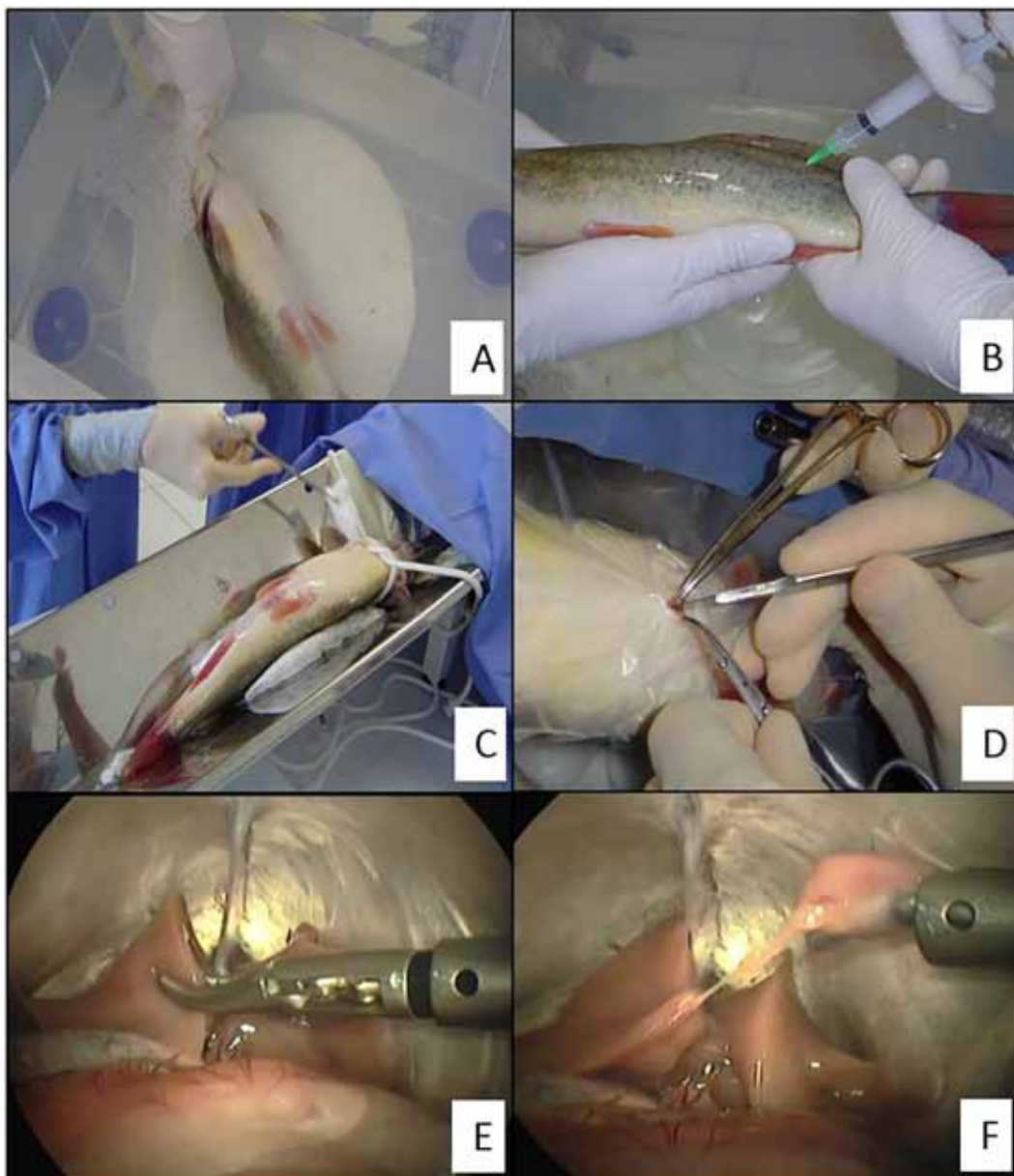


Fig.1. Image sequence of the anesthesia (A,B,C) and surgical technique of celioscopic liver biopsy in silver catfish (*Rhamdia quelen*) (D,E,F). (A) Na adult female silver catfish kept in a chloride-free water container with quinaldine (1gt/l). (B) Administration of a ketamine-xylazine association in the lumbar muscles. (C) Aseptic prepare of the ventral skin using a chlorhexidine water-based 1% solution. The animal is positioned in dorsal recumbence on a surgical chute for dogs, in a water recirculation system. (D) Access to the celomatic cavity, using the open technique, following skin incision using a no. 24 scalpel blade, between the pectoral fin and the genital orifice. (E) The liver tissue is grasped with the Kelly forceps. (F) excision of the liver specimen following rotation of the tip of the forceps on its axis.

was required, the forceps inserted through the second port could be used for grasping and raising the organ.

CONCLUSION

The surgical technique and anesthetic protocol proposed in the current study were adequate for achieving liver biopsy in silver catfish and provided low morbidity.

Acknowledgements.- The authors are grateful for the assistance and contribution of Dr. Leonardo José Gil Barcellos, Pisciculture Laboratory, University of Passo Fundo, Passo Fundo/RS, Brazil.

REFERENCES

- Brun M.V., Barcellos L.J.G., Barcellos H.H.A., Guimarães L.D., Silva L.B., Rither F., Pereira C.R., Quevedo R.M., Gonçalves H.R., Thomazi G. & Kramer R.B. 2004. Biópsia hepática videoendoscópica em carpa capim (*Ctenopharingodon idella*). Anais Congresso Estadual de Medicina Veterinária, Porto Alegre, RS, p.16. (Resumo)
- Carneiro P.C.F. 2002. Jundiá: um grande peixe para a região sul. Panorama Aquicul. 12(69):41-46.
- Carneiro P.C.F. & Mikos J.D. 2005. Frequência alimentar e crescimento de alevinos de jundiá *Rhamdia quelen*. Ciência Rural 35:187-191.
- Correia V., Neto J.R., Lazzari R., Veiverberg C.A., Bergamin G.T., Pedron F.A., Ferreira C.C., Emanuelli T. & Ribeiro C.P. 2009. Crescimento de jundiá e

- carpa húngara criados em sistema de recirculação de água. *Ciência Rural* 39(5):1533-1539.
- Fracalossi D.M., Meyer G., Santamaria F.M., Weingartner M. & Filho E.V. 2004. Criação do jundiá, *Rhamdia quelen*, e dourado, *Salminus brasiliensis* em viveiros de terra na região Sul do Brasil. *Acta Scient.* 26(3):345-352.
- Fracalossi D.M., Borba M.R., Oliveira-Filho P.R.C., Girão P.J.M. & Canton R. 2007. O mito da onivoria do Jundiá. *Panorama Aquicult.* 17(100):36-40.
- Murray M.J. 1998. Endoscopy in birds, reptiles, amphibians and fish. Endopress, Tuttingen, p.57-75.
- Pedron F.A., Neto J.R., Emanuelli T., Silva L.P., Lazzari R., Corrêia V., Bergamin G.T. & Veiverberg C.A. 2008. Cultivo de jundiás alimentados com dietas com casca de soja ou de algodão. *Pesq. Agropec. Bras.* 43(1):93-98.
- Silva L.B., Barcellos L.J.G., Quevedo R.M., Souza S.M.G., Kessler A.M., Kreutz L.C., Ritter F., Finco J.A. & Bedin A.C. 2008. Introduction of jundia *Rhamdia quelen* (Quoy et Gaimard) and Nile tilapia *Oreochromis niloticus* (Linnaeus) increases the productivity of carp polyculture in southern Brazil. *Aquacult. Res.* 1:1-10.
- Stoskopf M.K. 1993. *Fish Medicine*. W.B. Saunders, Philadelphia. 85p.