

Eimerid coccidia from capybaras (*Hydrochoerus hydrochaeris*) in southern Bahia, Brazil¹

George R. Albuquerque^{2*}, Bruno P. Berto³, Lilian S. Catenacci⁴, Selene S. da C. Nogueira², Sérgio Luiz G. Nogueira-Filho² and Carlos Wilson G. Lopes⁵

ABSTRACT.- Albuquerque G.R., Berto B.P., Catenacci L., Cunha Nogueira S.S., Nogueira-Filho S.L.G. & Lopes C.W.G. 2008. **Eimerid coccidia from capybaras (*Hydrochoerus hydrochaeris*) in southern Bahia, Brazil.** *Pesquisa Veterinária Brasileira* 28(7):323-328. Departamento de Ciências Agrárias e Ambientais, Universidade Estadual de Santa Cruz, BR415 Km 16, Salobrinho, Ilhéus, BA 45662-000, Brazil. E-mail: gralbu@uesc.br

Two eimerid coccidia are reported in a capybara (*Hydrochoerus hydrochaeris*) population kept in captivity in the south of Bahia, northeastern Brazil (14° 47' 57.89" S and 39° 10' 10.58" W). Oocysts of *Eimeria ichiloensis* are subspheroidal to ellipsoidal, 26.2 x 21.7mm with bi-layered wall, the outer yellow and sculptured and the inner, dark and smooth. Residuum is absent, but usually 2-3 polar granules are present. Sporocysts are ovoid, 12.0 x 7.6mm. Stieda body and sporocyst residuum are present. Oocysts of *Eimeria trinidadensis* are subspheroidal to ellipsoidal, 22.2 x 19.6mm with bi-layered wall, the outer yellow and smooth, and the inner dark and smooth. Residuum is absent, but one polar granule is present. Sporocysts are ovoid, 11.0 x 6.9mm. Stieda body and sporocyst residuum are present. Based on these descriptions and previous ones it can be concluded that these coccidia species are widely dispersed in capybaras in South America.

INDEX TERMS: *Eimeria ichiloensis*, *Eimeria trinidadensis*, *Hydrochoerus hydrochaeris*, capybara, South America.

RESUMO.- [Coccídios eimerídios em capivaras (*Hydrochoerus hydrochaeris*) no sul da Bahia.] Duas espécies de *Eimeria* foram relatadas em capivaras *Hydrochaeris hydrochaeris* cativas no sul da Bahia, nordeste do Brasil (14° 47' 57.89" S and 39° 10' 10.58" W). Os oocistos de *Eimeria ichiloensis* são sub-esferoidais a elipsoidais, 26,2 x 21,7mm. Apresentam parede dupla, sendo a externa amarela e esculpida e a interna, escura e lisa. Resíduo

está ausente, mas usualmente 2-3 grânulos polares estão presentes. Os esporocistos são ovóides, 12,0 x 7,6mm. Corpo de Stieda e resíduo do esporocisto estão presentes. Oocistos de *Eimeria trinidadensis* são sub-esferoidais a elipsoidais, 22,2 x 19,6mm. Apresentam parede dupla, sendo a externa amarela e lisa e a interna, escura e lisa. Resíduo está ausente, mas um grânulo polar está presente. Os esporocistos são ovóides, 11,0 x 6,9mm. Corpo de Stieda e resíduo do esporocisto estão presentes. Baseado nestas descrições e em descrições prévias foi possível concluir que estas espécies estão amplamente dispersas em capivaras na América do Sul.

TERMS DE INDEXAÇÃO: *Eimeria ichiloensis*, *Eimeria trinidadensis*, *Hydrochoerus hydrochaeris*, capivara, América do Sul.

INTRODUCTION

The capybara, *Hydrochoerus hydrochaeris* (Linnaeus, 1766) is the largest rodent in the world: its total body length ranges from 1.0 to 1.3m, average shoulder height around 0.5m and adult weight reaching 60kg or more. It is a grazing

¹ Received on April 29, 2008.

Accepted for publication on June 3, 2008.

² Departamento de Ciências Agrárias e Ambientais, Universidade Estadual de Santa Cruz (UESC), Campus Soane Nazaré de Andrade, Rodovia Ilhéus-Itabuna Km 16, Ilhéus, BA 45662-000, Brazil. *Corresponding author: gralbu@uesc.br

³ Curso de Pós-Graduação em Ciências Veterinárias, Universidade Federal Rural do Rio de Janeiro (UFRRJ), Seropédica, RJ 23890-000, Brazil.

⁴ Instituto de Estudos Sócioambientais do Sul da Bahia (IESB), Rua Major Homem Del Rey 147, Ilhéus, BA 45650-180, Brazil.

⁵ Departamento de Parasitologia Animal, Instituto de Veterinária, UFRRJ, Seropédica, RJ. Bolsista do CNPq.

herbivore that inhabits a great variety of semiaquatic habitats (Ojasti 1973).

Among these animal health issues, coccidiosis is known to cause intestinal lesions and economic losses in farm animals (Fitzgerald 1980). Most infections of the genus *Eimeria* Schneider, 1875, are asymptomatic or subclinical. Eventually infection with pathogenic species would induce clinical coccidiosis and diarrhea with blood and fibrin (Busato et al. 1998). Parasitized animals may have fever, abdominal pain, sometimes tenesmus and anemia, dehydration, weakness, anorexia, weight loss and eventually even die (Stockdale et al 1981).

Coccidiosis in capybaras can be associated with the genus *Cryptosporidium* Tyzzer, 1907, and *Eimeria*. Meireles et al. (2007) described natural infections with zoonotic subtypes of *C. parvum* Tyzzer, 1912, and Carini (1937) previously described *E. capibarae* Carini, 1937, and *E. hydrochoeri* Carini, 1937 in capybaras from the state of São Paulo, southeastern Brazil. *Eimeria trinidadensis* Casas, Duszynski and Zalles, 1995, *E. ichiloensis* Casas, Duszynski and Zalles, 1995, and *E. boliviensis* Casas, Duszynski and Zalles, 1995, were described in capybaras from eastern Bolivia and southern Venezuela. Recently, *E. araside* Gurgel, Sartori and Araújo, 2007 was described from the state of Rio Grande do Sul, southern Brazil.

In this context, the purpose of the present study was to investigate the presence of coccidian parasites infecting capybaras, *H. hydrochaeris* from southern Bahia.

MATERIALS AND METHODS

Samples of feces were collected from 13 capybaras, four with diarrhea, from a community of 26 animals maintained in an experimental farm at Universidade Estadual de Santa Cruz, Ilhéus, Bahia, Brazil (14° 47' 57.89" S and 39° 10' 10.58" W). In this farm the animals are raised under semi-confinement conditions: two paddocks of 5000m² each, surrounded by a mesh wire fence. In September 2007, one male and three females were captured with signs of diarrhea, using a 20 m² curral-trap. They were individually immobilized in a restriction-cage, feces were then collected immediately after defecation. Fecal samples were placed into plastic vials containing 2.5% potassium dichromate solution (K₂Cr₂O₇) 1:6v/v. Collected material was analyzed at the Laboratório de Coccídios e Coccidioses, Projeto Sanidade Animal Embrapa/UFRRJ, Departamento de Parasitologia Animal, Universidade Federal Rural do Rio de Janeiro. To allow sporulation, samples were placed on Petri dishes forming a thin layer of liquid (~5mm) at laboratory environmental temperature (23-28°C) for 10 days, according to the methodology described by Duszynski & Wilber (1997). Oocysts were recovered by flotation in Sheatter's sugar solution (sp.g. 1.20) and were examined under a light microscope comparing the description of Duszynski & Wilber (1997).

For morphological observations a binocular microscope (Carl Zeiss, Germany), with apochromatic oil immersion objective and ocular micrometer K-15x PZO (Poland), was used. As for the drawings, a binocular microscope (Carl Zeiss, Germany), with apochromatic oil immersion objective and ocular micrometer Line, was used. Photographs were taken with a digital camera (CD Mavica MVC-CD250 Sony®). Size ranges are presented

between parenthesis followed by means and shape index (length/width).

RESULTS

From the 13 capybaras, 9 shed oocysts of two distinct species. The oocysts were initially unsporulated and 70% of them were sporulated at 7 days. From these oocysts, two eimerian species were identified, which were previously described by Casas et al. (1995) in capybaras from eastern Bolivia and southern Venezuela in 1993-1994: *Eimeria ichiloensis* and *E. trinidadensis*.

Eimeria ichiloensis Casas, Duszynski and Zalles, 1995

Description. Oocysts (Fig.1a, 2a,b) subspheroidal to ellipsoidal, 26.2mm (22.3-33.5) x 21.7mm (19.9-26.6). Shape-index of 1.2mm (1.1-1.4). Bi-layered wall ~1.6mm, being the outer yellow and sculptured and the inner, darkness and smooth. Micropyle and residuum are absent,

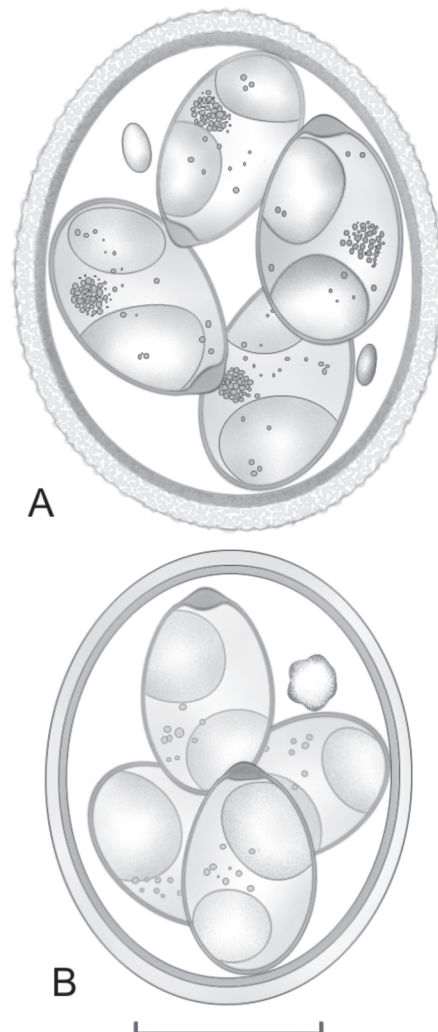


Fig.1. Line drawings of sporulated oocysts of eimerid coccidia recovered from the capybaras, *Hydrochoerus hydrochaeris*. (A) *Eimeria ichiloensis*, (B) *E. trinidadensis*. Scale bar: 10µm.

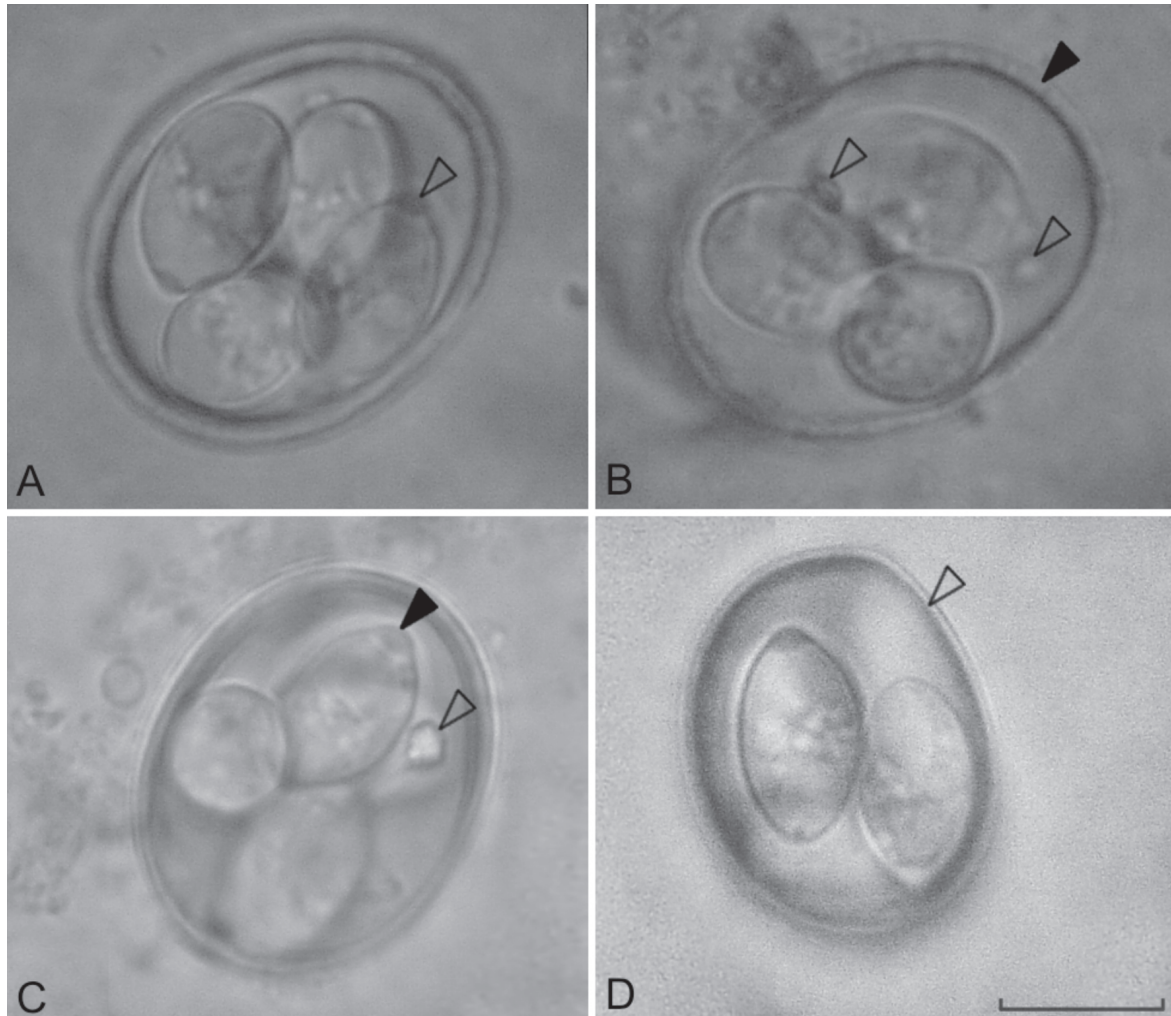


Fig.2. Photographs of oocysts of *Eimeria ichiloensis* and *E. trinidadensis*, using the same scale bar: 10 μ m. (A) *E. ichiloensis* presents Stieda body nipplelike (empty arrowhead). (B) *E. ichiloensis* presents bi-layered wall, being the outer yellow and sculptured and the inner, dark and smooth (solid arrowhead) and usually 2-3 polar granules (empty arrowheads). (C) *E. trinidadensis* presents polar granule highly refractile (empty arrowhead) and Stieda body nipplelike (filled arrowhead). (D) *E. trinidadensis* presents bi-layered wall, being the outer yellow and smooth and the inner, darkness and smooth (empty arrowhead).

but usually 2-3 polar granules are present. Sporocysts ovoid, 12.0mm (10.7-14.7) x 7.6mm (6.4-8.8). Shape-index of 1.6mm (1.3-1.7). Stieda body nipplelike, ~1.3-1.6mm high x 2.2-2.8mm wide. Substieda and parastieda body absent. Sporocyst residuum centered and composed of granular material. Sporozoites with a subspheroidal, robust, posterior refractile body at the posterior end.

Type Host: *Hydrochoerus hydrochaeris* Linnaeus, 1766 (Rodentia: Hydrochaeridae).

Type Locality: Bahia, Brazil.

Site of infection: Unknown, oocysts recovered from feces.

Prevalence: Nine examined capybaras shed oocysts in feces.

Type material: Oocysts in 10% aqueous (v/v) buffered formalin deposited at the Parasitology Collection, in the

Department of Animal Parasitology, UFRRJ, Seropédica, Rio de Janeiro, Brazil. Repository number is 1/2008, including phototypes and line drawings.

***Eimeria trinidadensis* Casas, Duszynski and Zalles, 1995**

Description: Oocysts (Fig.1b, 2c,d) subspheroidal to ellipsoidal, 22.2mm (19.3-24.7) x 19.6mm (17.3-21.0). Shape-index of 1.1mm (1.0-1.3). Bi-layered wall ~1.2mm, being the outer yellow and smooth and the inner, darkness and smooth. Micropyle and residuum are absent, but 1 polar granule, 2.2x2.9mm, highly refractile is present. Sporocysts ovoid, 11.0mm (9.8-12.8) x 6.9mm (5.9-7.7). Shape-index of 1.6 (1.5-2.0). Stieda body nipplelike, ~0.8-1.2mm high x 2.0-2.4mm wide. Substieda and parastieda body absent. Sporocyst residuum composed of few granules dispersed. Sporozoites with a sub-spherical, robust, posterior refractile body at the posterior end.

Table 1. Comparative morphology of the eimerian oocysts described in capybaras

Species	Oocysts				Sporocysts				References				
	Shape	Length (µm)	Width (µm)	Shape index (µm)	Wall	Polar granule	Residuuum	Shape		Length (µm)	Width (µm)	Shape index (µm)	Stieda body (µm)
<i>Eimeria capibarae</i> <i>E. hidrochoeri</i>	Ovoidal	30 (25-33)	26 (20-28)	0.8-0.9	Bi-layered, ~2.0, striated	Absent	Absent	Ovoidal	14-15	8	?	Present, prominent	Granulated and refringent
	Ovoidal	20-22	16-18	0.8-0.9	Bi-layered, ~0.8, smooth	Absent	Absent	Ovoidal	10-11	6-7	?	Present, discrete	Granulated
<i>E. trinidadensis</i>	Subspheroidal to ellipsoidal	20.9 (18-23)	18.1 (16.5-21)	1.2 (1.0-1.35)	Bi-layered, ~1.5; outer smooth and yellow, ~1/2-2/3 total thickness; inner smooth and blue	Present, highly refractile, (2.5 x 4)	Absent	Ovoidal	9.8 (9-12)	6.6 (5-8)	1.5 (1.3-2.0)	Present	Few small granules
	?	20.79 ± 1.57	20.79 ± 1.57	1.15 ± 0.1	?	?	?	?	?	?	?	?	?
<i>E. ichiloensis</i>	Subspheroidal to ellipsoidal	22.2 (19.3-24.7)	19.6 (17.3-21.0)	1.1 (1.0-1.3)	Bi-layered, ~1.2; outer smooth and yellow; inner smooth and darkness	Present, highly refractile, (2.2 x 2.9)	Absent	Ovoidal	11.0 (9.8-12.8)	6.9 (5.9-7.7)	1.6 (1.5-2.0)	Present, nipplelike, ~0.8-1.2 high x 2.0-2.4 wide	Composed of few granules Dispersed
	Ellipsoidal	26.2 (24-30)	21.0 (18-23)	1.3 (1.1-1.4)	Bi-layered, ~2.0; outer sculptured and yellow, ~3/4 total thickness; inner smooth and green	Present, 1 (usually) or 2-3, highly refractile	Absent	Ovoidal	11.6 (9-14)	7.4 (7-9)	1.6 (1.2-1.85)	Large, nipplelike	Compact massof tightly packed granules
<i>E. boliviensis</i>	?	25.08 ± 1.88	25.08 ± 1.88	1.26 ± 0.1	?	?	?	?	?	?	?	?	?
	Subspheroidal to ellipsoidal	26.2 (22.3-33.5)	21.7 (19.9-26.6)	1.2 (1.1-1.4)	Bi-layered, ~1.6; outer sculptured and yellow; inner smooth and darkness	Absent	Present, usually 2-3	Ovoidal	12.0 (10.7-14.7)	7.6 (6.4-8.8)	1.6 (1.3-1.7)	Present, nipplelike, ~1.3-1.6 high x 2.2-2.8 wide	Centered and composed of granules
<i>E. araside</i>	Ellipsoidal	35.9 (29-45)	25.7 (20-30)	1.4 (1.3-1.8)	Bi-layered, ~3.0; outer highly sculptured and brown, ~4/5 total thickness; inner smooth	Present, ~3, rounded, highly refractile	Absent	Elongated ovoidal	16.0 (12-20)	10.4 (8-12)	1.55 (1.4-2.0)	Present	Composed of scattered coarse granules
	?	32.42 ± 2.91	24.87 ± 2.08	1.31 ± 0.17	?	?	?	?	?	?	?	?	?
<i>E. araside</i>	Ellipsoidal	18.56 ± 2.51	15.3 ± 0.92	1.22 ± 0.19	Bi-layered; outer smooth, well-delineated and brown; inner homogeneous	?	Absent	?	?	?	?	?	?
	?	?	?	?	?	?	?	?	?	?	?	?	?

? = Not informed.

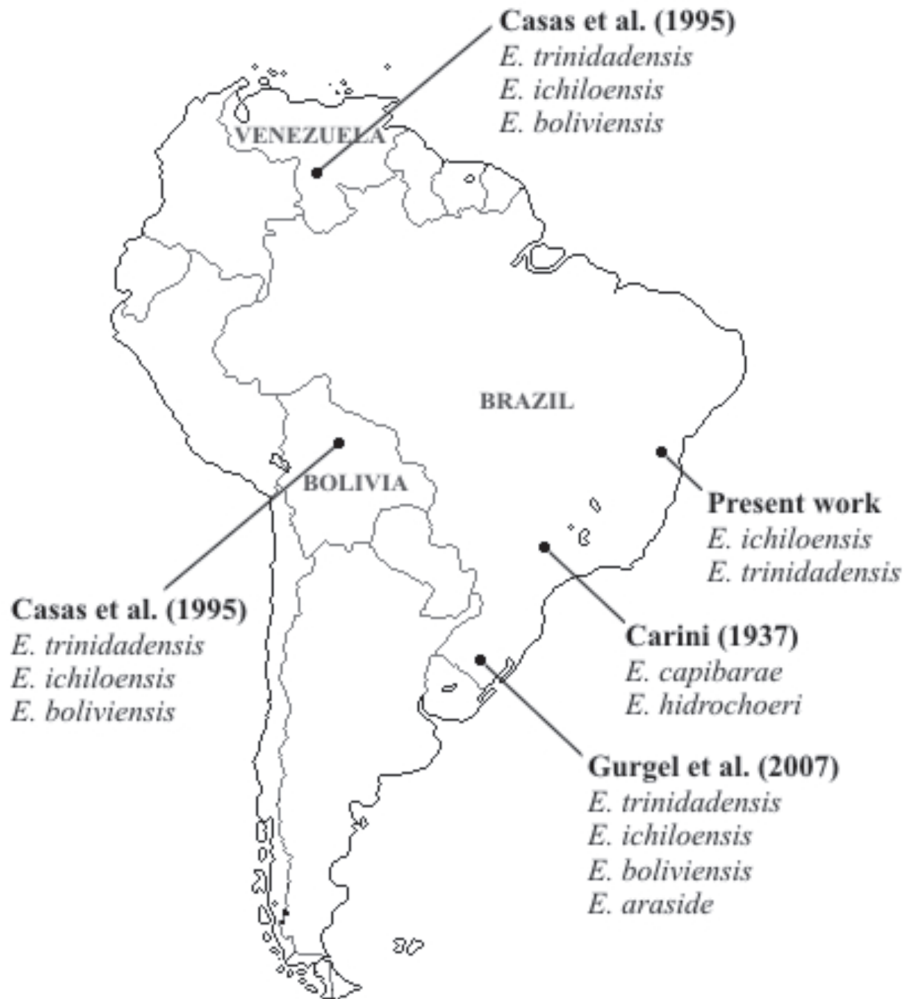

Fig.3. Map of South America, showing 5 localities where eimerid coccidia recovered from capybaras, *Hydrochoerus hydrochaeris* were described. In each locality references of each coccidian species previously reported are indicated.

Type Host: *Hydrochoerus hydrochaeris* Linnaeus, 1766 (Rodentia: Hydrochaeridae).

Type Locality: Bahia, Brazil.

Site of infection: Unknown, oocysts recovered from feces.

Prevalence: Nine examined capybaras shed oocysts in the feces.

Type material: Oocysts in 10% aqueous (v/v) buffered formalin deposited at the Parasitology Collection, in the Department of Animal Parasitology, UFRRJ, Seropédica, Rio de Janeiro, Brazil. Repository number is 02/2008, including phototypes and line drawings.

DISCUSSION

Considering all morphological characteristics and comparative analyses of the eimerian oocysts (Table1) the species described in the present study are being considered *Eimeria trinidadensis* and *E. ichiloensis*, previously described by Casas et al. (1995) in capybaras from eastern Bolivia and southern Venezuela. Oocysts of

these species were also recovered in capybaras from Rio Grande do Sul, southern Brazil (Gurgel et al. 2007). Thus, it is possible to conclude that these two species are widely dispersed in South America (Fig.3). The large range of capybara, *Hydrochoerus hydrochaeris*, from northern Argentina until the Panama channel in the Central America (Eisenberg & Redford 1999) and its dispersion pattern (Ojasti 1973), probably explain these eimerid coccidia dispersion. On the other hand, *E. capibarae* and *E. hydrochoeri* recovered in capybaras from the State of São Paulo, southeastern Brazil (Carini 1937), are not cited in any other work.

In Brazil commercial hunting is illegal. However, wildlife farming is allowed and encouraged by the Brazilian Government Environmental Agency (IBAMA) and, as a consequence; number of capybara farms in different Brazilian regions are increasing (Nogueira-Filho & Nogueira 2004). These farms occasionally trade live animals with each other. The arrival of a new animal in a given population can cause disease outbreaks. Thus, coccidiosis

may be an important disease for commercial breeding of capybaras.

REFERENCES

- Busato A., Lentze T., Hofer D., Burnens A., Hentrich B. & Gaillard C. 1998. A case control study of potential enteric pathogens for calves raised in cow-calf herds. *J. Vet. Med. B* 45:519-528.
- Carini A. 1937 Sur deux nouvelles Eimeria d'*Hydrochoerus capibara*. *Annales de Parasitologie Humaine et Comparee* 15(4):367-369.
- Casas M.C., Duszynski D.W. & Zalles L.M. 1995. Three new Eimerians in capybara (*Hydrochaeris hydrochaeris*) populations from eastern Bolivia and southern Venezuela. *J. Parasitol.* 81(2):247-251,
- Duszynski D.W. & Wilber P.G. 1997. A guideline for the preparation of species descriptions in the Eimeriidae. *J. Parasitol.* 83(2):333-336.
- Eisenberg J.F. & Redford K.H. 1999. *Mammals of the Neotropics - The Central Neotropics*. University of Chicago Press, Chicago. 609p.
- Fitzgerald P.R., 1980. The economic impact of coccidiosis in domestic animals. *Adv. Vet. Sci. Comp. Med.* 24:121-143.
- Gurgel A.P.F., Sartori A.S. & Araújo F.A.P. 2007. Eimeriosis in capybaras (*Hydrochaeris hydrochaeris*) in the State of Rio Grande do Sul, Brazil. *Parasitol. Latinoam.* 62(1):76-78.
- Meireles M.V., Soares R.M., Bonello F. & Gennari S.M. 2007. Natural infection with zoonotic subtype of *Cryptosporidium parvum* in Capybara (*Hydrochoerus hydrochaeris*) from Brazil. *Vet. Parasitol.* 147(1/2):166-170.
- Nogueira-Filho S.L.G. & Nogueira S.C.C. 2004. Captive breeding programs as an alternative for wildlife conservation in Brazil, p.171-190. In: Kirsten S., Fragoso J.M.V. & Bodmer E.R. (ed.), *People in Nature: Wildlife management and conservation in Latin America*. Columbia University Press, New York.
- Ojasti J. 1973. Estudio del Chigüire o Capibara. Fondo Nacional de Investigaciones Agropecuarias, Caracas. 275p.
- Stockdale P.H.G., Bainborough A.R. Bailey C.B. & Niilo L. 1981. Some pathophysiological changes associated with infection of *Eimeria zuernii* in calves. *Can. J. Comp. Med.* 45:34-37.