

Chorion biopsy in mongrel dogs¹

Guilherme J. Ferreira², Ana F. Carvalho³, Érika Branco^{4*}, Rosa Cabral⁵,
Guilherme B. Gregores⁵, Emerson T. Fioretto⁵, Ana Rita de Lima⁵, Carlos
Alberto P. Sarmiento⁵ and Maria Angelica Miglino⁵

ABSTRACT.- Ferreira G.J., Carvalho A.F., Branco E., Cabral R., Gregores G.B., Fioretto E.T., Lima A.R., Sarmiento C.A.P. & Miglino M.A. 2009. **Chorion biopsy in mongrel dogs.** *Pesquisa Veterinária Brasileira* 29(10):793-796. Universidade Federal Rural da Amazônia (UFRA), Avenida Pte Tancredo Neves 2501, Montese, Belém, PA 66077-530, Brazil. E-mail: erika.branco@ufra.edu.br

With the great development of the gestational studies in all of the species, we noticed the necessity of adaptations of these techniques for prenatal diagnosis in dogs. Based on this, we studied the feasibility of chorion biopsy guided by ultrasound. Our results demonstrated accuracy on the sex determination being 2 males and 12 females, as well as it would be possible to identify chromosome alteration due to the quality of samplings. Sex determination was accomplished with the identification of Y gene chromosomes in PCR technique. After the collection, fragments were prepared for light microscopy studies and revealed fetal chorion tissue, blood colloid and erythrocyte. In the whole material we found hemosiderin impregnations due to the hemolysis and to the residue of blood of the placental marginal hematomas. The submitted female dogs to this technique demonstrated normal puppy births without death.

INDEX TERMS: Chorion, biopsy, placenta, dog.

RESUMO.- [Biopsia do cório fetal em cães.] Com o grande desenvolvimento dos estudos gestacionais em todas as espécies, percebemos a necessidade de adaptarmos técnicas para diagnóstico pré-natal para cães. Assim, buscamos bases nas técnicas já existentes empregadas em humanos, e através destas, conseguimos estabelecer um método para coleta em cães, utilizando PCR para garantirmos a integridade das amostras. O procedimento foi realizado através de punção da cinta placentária com agulha de biopsia guiada por ultra-som. De todas as 14

amostras coletadas, duas apresentaram-se positivas para o cromossomo Y, presente apenas em machos, confirmando assim a viabilidade das amostras demonstrando com isso que através desta técnica podemos coletar material fetal para diagnóstico de alterações gênicas ou cromossômicas presentes nos cães antes mesmo destes virem a termo. A microscopia de material revelou fragmentos de cório fetal, colóide sanguíneo e eritrócitos. Em todo o material encontramos impregnações de hemosiderina devido à hemólise e ao resíduo de sangue dos hematomas marginais placentários. As cadelas submetidas a esta técnica tiveram partos normais sem óbito de nenhum filhote.

TERMO DE INDEXAÇÃO: Cório, biopsia, placenta, cão.

INTRODUCTION

Pregnancy is a physiological process passive of vulnerability according to primary health care. The significant changes in pregnant woman's body associated to risk factors could lead the pregnancy state into a pathological state with considerable risk for the mother and the fetus (Trevisan et al. 2002).

¹ Received on January 3, 2009.

Accepted for publication on May 16, 2009.

² Universidade Federal do Piauí (UFPI), Campus Universitário Profª Cinobelina Elvas, BR 135 Km 3, Bom Jesus, PI 64900-000, Brazil.

³ Centro Universitário, Fundação de Ensino Octávio Bastos-Unifeob, Av. Dr. Octávio Bastos s/n, Jardim Nova São João, São João da Boa Vista, SP 13870-000, Brazil.

⁴ Universidade Federal Rural da Amazônia (UFRA), Av. Pte Tancredo Neves 2501, Montese, Belém, PA 66077-530, Brazil. *Corresponding author: erika.branco@ufra.edu.br

⁵ Faculdade de Medicina Veterinária e Zootecnia (FMVZ), Universidade de São Paulo (USP), Av. Prof. Dr. Orlando Marques de Paiva 87, Cidade Universitária, São Paulo, SP 05508-270, Brazil.

Gestation development produces in man and other animal great alterations on the feminine reproductive system, since the embryo's formation to its maturation. The evolution of prenatal clinics characterized by a detailed observation of all gestational phases allows the possibility of introducing emergent therapeutics. The ultrasound exam is adopted for diagnosis and fetal evaluation due to the high precision and harmless characteristics, providing gestational age, ovaries and uterus condition, fetal-maternal structures observations and fetal vital signs informations (Yeager et al. 1992).

Although pregnancy is a general state for mammals, in dogs it presents uncommon aspects, being necessary the development of new specific technologies to access fetal and placental samples in order to develop the prenatal investigation (Concannon et al. 1989, Sadovsky et al. 2006, Rizzo & Capponi 2007, Rueangchainikhom et al. 2008).

In humans the invasive procedures like cordocentesis, amniocentesis or biopsies of chorionic villous are used for confirmative tests from different diseases based in biochemical analysis, fetal gene typing or PCR techniques (polymerase chain reaction) using fetal cells collection (Verma et al. 1998). These procedures are indicated in cases of possible chromosomal anomalies due to familiar historic of genetic disturb, risk of defects on neural tube and triage of maternal serum or suggestive ultra sound. These methods are painful for the mother e presents risk of abortus in 1% (Júnior 2002) or minimum intra amniotic infections. The diagnostic is clinic, and related to insufficient antiseptis during chorioamnionitis (Gray et al. 1992).

This study aimed to describe the experimental adaptation of biological sampling technique of fetal liquids and membranes in dogs guided by ultrasound, promoting amniocentesis and fetal chorion sampling, contributing to the advance of the reproduction area in all veterinary fields.

MATERIALS AND METHODS

Ten pregnant mongrel dogs, originated from the Zoonosis Control Center of São Paulo were investigated. The animals were clinical evaluated and submitted to ultrasound exam to determine the gestational period based on Evan-Sack's and Noden-La Hunta's growth curvatures (Evans & Sack 1973, Noden & Lahunta 1990). For detailed of placenta and embryo/fetal development see Miglino et al. (2006).

Six animals, from 35 to 52 pregnancy days, were submitted to the experimental sampling technique adaptation, based on the described technique applied in human, constituting the fetal sates evaluation (viability, vital signs), fetal position and placental evaluations to determining the needle point access guided by ultrasound, therefore, choose the better place for punction, preventing the transfixation of placenta, because transplacental punction are associated to increase on risk of abortions and contamination of material with maternal cells. In amniocentesis we chose the better place with free umbilical cord, fetal part or placenta in accordance to Kappel et al. (1987).

Like in humans, choose of needle depends of characteristics of maternal abdomen (needles more long in presence of obesity), volume of amniotic liquid (needles more long if exists polidramnion), localization of placental insertion of umbilical cord

(needles more long if the insertion is posterior) and quantities of removed material needles more thick if the volume is bigger). We used needles Gauge number 20 to 22, length 8.9cm. Longer needles are related to increase the difficulties on the technique application, and thicker needles to increase the risk of abortions (Hanson et al. 1992).

The biopsy was preceded under anesthesia. The animals were pre-medicated with an association of 0.2% acepromazine (0.05mg/kg) and meperidine cloridrato (2mg/kg) IM, and maintenance promoted with the aid of propofol continuous infusion (5mg/kg).

The allantois was punctured with the aid of a puncture needle 22G (BD®), when reaching the trophoblast (Fig.1), the mandrill was separated and the needle was connected to a 10ml syringe containing 2-5ml of transportation medium (Culture medium 199, Adolf Lutz Institute) in order to maintain the cell viability, aspirating a volume of 5-10ml (Zugaib 1997).

The samples (14 animals) were submitted to classic protocol

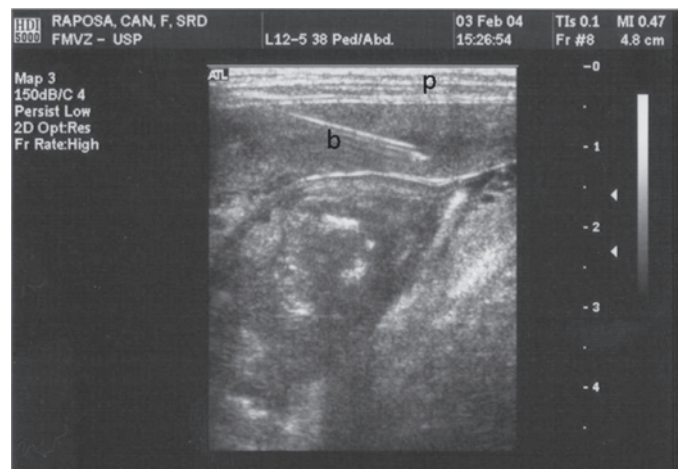


Fig.1. Ultrasonographic image: Puncture of allantois with the aid of a puncture needle 22G (b). Placental ring (p).

of DNA extraction and PCR (Polimerase Chain Reaction) analysis, aiming to determine the fetuses sex and to confirm the material viability. The DNA samples were prepared in a mix containing Y-detection primers and submitted to PTC-100 program (Programmable Thermal Controller - MJ Research, Inc.), following its inclusion in agarose gel and submitted to eletroforesis.

RESULTS AND DISCUSSION

Chorion biopsy, sex determination

The PCR technique of 14 samples of DNA obtained two positive for the Y chromosomes, confirming the observation of the fetuses. We believe that chorion biopsy guided by ultrasound in dogs would be one of the possible applications of the technique for sex determination; in addition, it would be possible to investigate genetic alterations or initial diseases in these animals.

Chorion biopsy, histological investigation

The analysis of the biopsy revealed to be related to corium fetal fragments, blood colloid and erythrocytes. All the material was impregnated with hemosiderin due to the

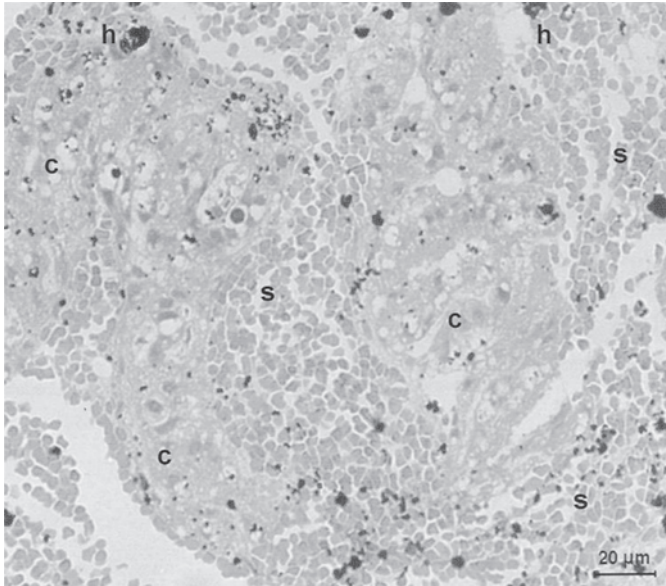


Fig.2. Chorion sample demonstrating capillaries (c), blood colloid (s) and hemosiderin (h). HE stain. Scale: 20µm.

hemolysis and the residue of marginal hematomas. Form and shape were undetermined due to alterations caused by the aspirate biopsy, although, it was possible to identify the blood vessels of the canine chorion (Fig.2).

Chorion biopsy, the examining

The period of accomplishing the corium fetal biopsy in human is restrained to the first trimester (Zugaib 1997, Hahnemann & Mohr 1968) while in dogs, the period for most success is related to the gestational final trimester, because it is possible to identify the placenta, the fetal growth and characterization (Phemister 1974).

The first biopsies in humans were accomplished by stems guided to the uterus through cervix (Stone & Lockwood 1993). This method was totally discarded for dogs due to the multiparous characteristic and bicornate uterus. These facts would unfeasible the technique in accessing the fetuses away from the cervix. Besides, due to the placenta formation and blind guidance, it would be possible to harm the placenta or other fetal membranes. The late biopsies of chorion villi in human do not present significant differences in relation to the early biopsies (D'alprà et al. 1993). Late biopsies in dogs are elected due to the placenta characteristics described above.

Experimental studies applying invasive procedures in animal show a decrease in number of alveoli and fetal lung volume, increasing respiratory disturbs and pneumonia in neonatal period which is more evident in precocious amniocentesis (Hislop & Fairweather 1982, Tabor et al. 1986).

A discrete bleed at the puncture area is common, but hemorrhage is a rare complication. Hemorrhage would be common in cases of fetus' platelets disease (Hanson et al. 1992).

Due to the lackness of reports about the application of uterine biopsies for genetic investigation and diseases

diagnostics in dogs makes difficult to establish what would be the best gestational phase to apply the technique for complete examination and minimal risk of abortion. However, similar studies in human reports 0.3% to 2.8% abortions after aminocentesis made in the two first trimesters; earlier procedures, before the 12th week of gestation, related rates of 0.7% to 2.2% of abortions (Kappel et al. 1987).

CONCLUSION

Based on the success application of uterine biopsies in human, in order to diagnose and early-treatment of illnesses which would compromise the quality of life of the newborns, we believe that the same understanding can be applied for chorion biopsies in dogs. The technique is considered to be safeness, and low costs, although requiring sedation of the animal and well-training of the technique. This procedure provides samplings with good cell viability to be submitted for gene anomalies or diseases investigation. We would infer that the application of chorion biopsy in association to the early-diagnoses of fetal alterations would improve clinics therapeutics and reproductive rates in dogs.

Acknowledgments.- To FAPESP for funding this study.

REFERENCES

- Concannon D.M. & Weir B. 1989. Dog and cat reproduction, contraception and artificial insemination. Proc. 1st Int. Symp. Canine and Feline Reproduction. J. Reprod. Fert. 39(Suppl.):3-25.
- D'alprà L., Nocera G., Tibiletti M.G., Martinoli E. & Oldrini A. 1993. "Late" chorionic villus sampling: Cytogenetic aspects. Prenat. Diagn. 13:239.
- Evans H.E. & Sack W.O. 1973. Prenatal development of domestic and laboratory mammals: Growth curves, external features and selected references. Anat. Histol. Embryol. 2:1-45.
- Gray D.J., Robinson H., Malone J. & Thomson R.B. 1992. Adverse outcome in pregnancy following amniotic fluid isolation of *Ureaplasma urealyticum*. Prenatal Diagn. 12:111-117.
- Hahnemann M. & Mohr J. 1968. Genetic diagnosis in the embryo by means of biopsy from extra-embryonic membranes. Bull. E. R. Hum. Genet. 2:23.
- Hanson F.W., Tennant F., Hune S. & Brookhyser D. 1992. Early amniocentesis: Outcome, risks, and technical problems at ≤12.8 weeks. Am. J. Obstet. Gynecol. 166:1707-1711.
- Hislop A. & Fairweather D.V.I. 1982. Amniocentesis and lung growth: An animal experiment with clinical implications. Lancet ii:1271.
- Junior W.P. 2002. Diagnóstico pré-natal. Revta Ciênc. Saúde Colet. 7(1):139-57.
- Kappel B., Nielsen J., Hansen B.K., Mikkelsen M. & Therkelsen A.A.J. 1987. Spontaneous abortion following mid-trimester amniocentesis: Clinical significance of placental perforation and blood-stained amniotic fluid. Brit. J. Obstet. Gynaecol. 94:50.
- Miglino M.A., Ambrósio C.E., Martins D.S., Wenceslau C.V., Pfarer C. & Leiser R. 2006. The carnivore pregnancy: The development of the embryo and fetal membranes. Theriogenology 6(7):1699-1702.
- Noden D.M. & De Lahunta A. 1990. Estadios iniciales del desarrollo en aves y mamíferos, p.45-47. In: Noden D.M. & De Lahunta A. (Eds), Embriología de los Animales Domésticos. Acribia, Zaragoza.
- Phemister R.D. 1974. Nonneurogenic reproductive failure in the bitch. Vet. Clin. North Am. 4:573-586.

- Rueangchainikhom W., Sarapak S. & Orungrote N. 2008. Chorionic Villus Sampling for early prenatal diagnosis at Bhumibol Adulyadej Hospital. *J. Med. Assoc. Thai.* 91(1):1-6.
- Sadovsky Y., Wyatt S.M., Collins L., Elchalal U., Kraus F.T. & Michael D.N. 2006. The use of needle biopsy for assessment of placental gene expression. *Am. J. Obst. Gynecol.* 194(4):1137-1142.
- Stone J.L. & Lockwood C.J. 1993. Amniocentesis and chorionic villus sampling. *Curr. Opinion Obstet. Gynecol.* 5:211.
- Tabor A., Philip J., Madsen M., Bang J., Obel E.B. & Nørgaard-Pedersen B. 1986. Randomized controlled trial of genetic amniocentesis in 4606 low-risk women. *Lancet* i:1287.
- Tasleem S., Tasleem H., Siddiqui M.A., Adil M.M. & Rashid Y. 2007. Prenatal diagnosis of beta-thalassaemia by chorionic villous sampling. *J. Pak. Med. Assoc.* 57(11):528-531.
- Trevisan M.R., De Lorenzi D.R.S. & Araújo N.M. 2002. Perfil da assistência pré-natal entre usuárias do Sistema Único de Saúde em Caxias do Sul. *Revta Bras. Ginecol. Obstet.* 24(5):293-299.
- Verma L., MacDonald F., Leedham P., McConachie M., Dhanjal S. & Hultén M. 1998. Rapid and simple prenatal DNA diagnosis of Down's syndrome. *Lancet* 352(9121):9-12.
- Weiner C.P. & Okamura K. 1996. Diagnostic fetal blood sampling-technique related losses. *Fetal Diagn. Ther.* 11:169-175.
- Yeager A.E., Mohammed H.O., Meyers-Wallen V.N., Vannerson L. & Concannon P.W. 1992. Ultrasonographic appearance of the uterus, placenta, fetus, and fetal membranes throughout accurately timed pregnancy in beagles. *Am. J. Vet. Res.* 53:342-351.
- Zugaib M. 1997. Biópsia do vilo corial, p.441-452. In: Zugaib M. (Ed.), *Medicina Fetal*. 2ª ed. Atheneu, São Paulo.