

## Sheep abortion associated with *Neospora caninum* in Mato Grosso do Sul, Brazil<sup>1</sup>

Ana Paula Pinto<sup>2</sup>, Flávia B. Bacha<sup>2</sup>, Bethania S. Santos<sup>2</sup>, David Driemeier<sup>3</sup>, Nadia A.B. Antoniassi<sup>3</sup>, Nickolly L.K. de Sá Ribas<sup>2</sup> and Ricardo A.A. Lemos<sup>4\*</sup>

**ABSTRACT.**- Pinto A.P., Bacha F.B., Santos B.S., Driemeier D., Antoniassi N.A.B., Ribas N.L.K.S. & Lemos R.A.A. 2012. **Sheep abortion associated with *Neospora caninum* in Mato Grosso do Sul, Brazil.** *Pesquisa Veterinária Brasileira* 32(8):739-742. Departamento de Patologia, Universidade Federal de Mato Grosso do Sul, Campo Grande, MS 79074-460, Brazil. E-mail: [lap.famez@ufms.br](mailto:lap.famez@ufms.br)

Canids are the main hosts of *Neospora caninum*, but cattle, (sheep, goats and horses may serve as intermediary hosts. *N. caninum* infection of pregnant intermediary hosts may provoke abortion and neonatal infections. This study is the first to report lamb abortion associated with *N. caninum* in Mato Grosso do Sul. Epidemiological data were obtained from interviews with sheep producers. For microscopic examination, fragments of different organs removed from 4 sheep fetuses, aborted and necropsied, were fixed in 10% formaldehyde, embedded in paraffin and subjected to the hematoxylin-eosin staining protocol and immunohistochemistry (IHC) to test for *N. caninum* and *Toxoplasma gondii*. The abortion outbreak studied was reported from a herd of 268 *Santa Inês* sheep (including 186 pregnant ewes), with 10 abortion cases in the last third of gestation. Four fetuses were examined, 3 from a same ewe. At necropsy, one fetus exhibited crackling in the lung and all its organs were reddish. Histological findings detected mononuclear cell infiltrates among myocardium fibers and around blood vessels, in addition to circular structures with basophilic points resembling protozoans. IHC tests revealed strongly positive staining for *N. caninum* and weakly positive for *T. gondii*, characterizing *N. caninum* infection.

INDEX TERMS: Abortion, sheep, *Neospora caninum*.

**RESUMO.**- [Abortos por *Neospora caninum* em ovinos em Mato Grosso do Sul.] *Neospora caninum* é um protozoário que tem o cão como hospedeiro definitivo e, bovinos, ovinos, caprinos e equinos como hospedeiros intermediários. Nestas últimas espécies pode provocar abortos e infecções neonatais. Este trabalho é o primeiro relato de aborto em ovinos associado com *N. caninum* no Mato Grosso do Sul. Os dados epidemiológicos foram obtidos através

de entrevistas com o proprietário dos animais. Quatro fetos foram necropsiados, dos quais foram colhidos fragmentos de diversos órgãos fixados em formol a 10%, incluídos em parafina, processados pela técnica usual de hematoxilina e eosina e também foi realizada imuno-histoquímica para *N. caninum* e *Toxoplasma gondii*. O surto ocorreu em um rebanho constituído por 268 ovinos da raça Santa Inês, destes 186 eram fêmeas prenhes, no terço final de gestação e 10 abortaram. Dos quatro fetos analisados, três eram da mesma fêmea, sendo um de menor tamanho. À necropsia o pulmão de um dos fetos estava crepitante e todos os órgãos estavam avermelhados. Os achados histológicos foi infiltrado mononuclear entre as fibras do miocárdio e ao redor dos vasos, além de estruturas circulares compostas por pontilhados basofílicos semelhantes a protozoários. A IHQ revelou marcação fortemente positiva para *N. caninum* e fracamente positiva para *T. gondii*, caracterizando infecção por *N. caninum*.

TERMOS DE INDEXAÇÃO: Abortos, ovinos, *Neospora caninum*.

<sup>1</sup> Received on March 30, 2012.

Accepted for publication on April 17, 2012.

<sup>2</sup> Programa de Pós-Graduação em Ciência Animal, Faculdade de Medicina Veterinária e Zootecnia (FAMEZ), Universidade Federal de Mato Grosso do Sul (UFMS), Av. Senador Felinto Müller 2443, Campo Grande, MS 79070-900, Brazil.

<sup>3</sup> Departamento de Patologia Clínica Veterinária, Universidade Federal do Rio Grande do Sul (UFRGS), Av. Bento Gonçalves 9090, Bairro Agronomia, Porto Alegre, RS 91500-000, Brazil.

<sup>4</sup> Faculdade de Medicina Veterinária e Zootecnia, UFMS, Campo Grande, MS. \*Corresponding author: [lap.famez@ufms.br](mailto:lap.famez@ufms.br)

## INTRODUCTION

*Neospora caninum* is an obligatory intracellular protozoan from the phylum Apicomplexa, family Sarcocystidae and subfamily Toxoplasmatinae that causes neosporosis. This subfamily includes 3 other genera: *Toxoplasma*, *Hammondia* and *Besnoitia* (Mugridge et al. 1999). Dogs (McAllister et al. 1998) and coyotes (Gondim et al. 2004) are definite hosts of *N. caninum*, but other animals such as cattle, sheep, goats, horses and cervids may serve as intermediary hosts (Barr et al. 1992). This protozoan can be transmitted by the transplacental route or by ingestion of oocysts eliminated by the definite hosts (Dubey et al. 1996, McAllister et al. 1996).

Canine neosporosis is characterized by encephalitis and myositis (Dubey et al. 1988). In cattle, sheep and goats, *N. caninum* is known to cause abortion and premature birth (Anderson et al. 1991, Barber et al. 1997, Morales et al. 2001, Garcia-Vazquez et al. 2002, Dubey 2003). These abortions are likely caused by parasite migration to the fetal chorionic epithelium and placental blood vessels, which develop vasculitis, thrombosis and necrosis in the placenta (Buxton et al. 1998).

Spontaneous neosporosis in sheep, confirmed by immunohistochemistry, was first recorded in the United Kingdom in 1990 and resulted in the death of the infected lamb one week after birth (Dubey et al. 1990). In fact, according to the stage of gestation at infection time, neosporosis in sheep can cause abortion, fetal mummification, embryo resorption, stillbirth, and the birth of weak or apparently healthy but congenitally infected offspring (McAllister et al. 1996, Buxton et al. 1997, 1998, Hässig et al. 2003). In contrast to that observed in lambs sheep with toxoplasmosis, abortions caused by neosporosis occur repeatedly, showing that immunity is not achieved after primo-infection (Jolley et al. 1999).

Neosporosis diagnosis can be obtained by combining herd history data (especially reproductive failures), clinical signals and laboratory tests such as histopathology (Otter et al. 1995), immunohistochemistry (Lindsay & Dubey 1989) and polymerase chain reaction (PCR). Parasite detection in the tissues can be difficult because of its distribution, and serological tests are therefore a good alternative for diagnosis purposes. The main serological tests used are RIFI (Indirect Immunofluorescence Reaction) and ELISA (Andreotti et al. 2002), but they are indicated to assess previous exposure to the pathogen and herd infection risk rather than to diagnose *N. caninum* as the cause of abortion (Munhoz 2009). In histological examinations, neosporosis can be characterized in the different animal species by mononuclear cell infiltrates, especially in the heart, skeletal muscles and liver (Anderson et al. 1991, Dubey & Lindsay 1996). In the brain, cysts and tachyzoites of *N. caninum* can be observed in addition to multifocal nonsuppurative encephalitis with small foci of necrosis (Dubey & Lindsay 1996). Because of the similar symptoms, neosporosis diagnosis can be confused with that of toxoplasmosis.

The losses provoked by neosporosis in sheep farming have yet to be assessed. However, as in cattle farming, they may be related to abortion, reduction in animal value, increase in interparturition interval, infertility and decrease in milk production (Trees et al. 1999). Neosporosis in Brazil was de-

tected in many animal species (Toscan et al. 2010, Teixeira et al. 2010, Silva et al. 2010, Camillo et al. 2011, Varaschin et al. 2011), but its association to abortion was found only for cattle (Gondim et al. 1999, Corbellini et al. 2000, Corbellini 2001, Pescador et al. 2007). In an attempt at filling this gap, the present study aims to describe sheep abortions caused by *N. caninum* in the state of Mato Grosso do Sul, Brazil.

## MATERIALS AND METHODS

The study investigated *Neospora caninum* occurrence in sheep fetuses from a sheep herd in Aquidauana (-20°04'47.9" S, -55°21'42.8" W), MS, Brazil, where an abortion outbreak was recorded. Along with clinical examination of the sheep fetuses, epidemiological data were provided by the sheep farmer. Four fetuses were necropsied at the Laboratory of Pathological Anatomy (LAP) of the Federal University of Mato Grosso do Sul (UFMS). Fragments of fetus organs were fixed in 10% formaldehyde, embedded in paraffin and stained with hematoxylin-eosin protocol.

Heart and brain fragments of two fetuses were prepared to be examined by immunohistochemical (IHC) procedures for *N. caninum* and for *Toxoplasma gondii* determination (for differential diagnosis) at the Sector of Veterinary Pathology of the Federal University of Rio Grande do Sul. The same protocols were used to detect *N. caninum* and *T. gondii*, except for the primary polyclonal antibodies used, which were anti-*N. caninum* (VRMD) and anti-*T. gondii* (VRMD), respectively, both diluted at 1:1000. After the fragments were subjected to decreasing concentrations of xylene and alcohol, they were kept in 3% hydroperoxide for 15 min, at room temperature. Antigen retrieval was obtained with fragment immersion in 0.1% trypsin for 10 min at 37°C, followed by incubation in citrate buffer solution for 2 min in a microwave oven (maximum power). Unspecific reactions were blocked with fragment immersion in 5% defatted milk (Molico®) for 15 min. The primary antibody was incubated at 37°C for 60 min using the avidin-biotin peroxidase protocol modified with the LSAB-HRP Kit (Dako). For visualization, the fragments were kept in 3,3'-diaminobenzidine (DAB) chromogen for 10 min. The cuts were counterstained with hematoxylin.

## RESULTS

The abortion outbreak occurred in a *Santa Inês* herd of 268 sheep (186 of these pregnant ewes in the last third of gestation), resulting in 10 abortions. The farmer also reared 23 dairy cows, but they did not show any reproductive failures. The sheep had contact with two dogs.

From the four fetuses evaluated in this study, three were produced by a same ewe (one individual smaller than the other two). At necropsy, two fetuses (from a same ewe) were in the advanced autolysis stage, which precluded macroscopic and histological examinations. One of the fetuses evaluated macroscopically did not exhibit significant alterations, and the other exhibited crackling in the lung and all its organs were reddish.

Histological findings were similar in the two fetuses evaluated. They showed slight to moderate mononuclear cell infiltrates among the myocardium fibers and around blood vessels, in addition to basophilic rings or spots resembling protozoans. The brain fragments had diffuse gliosis associated to mononuclear cell foci. One of the samples had brain cysts similar to those of *N. caninum* or *T. gondii*. In the brain and heart fragments of the two fetuses,

IHC tests revealed strongly positive staining for *N. caninum* and weakly positive for *T. gondii*, characterizing *N. caninum* infection (Fig.1).

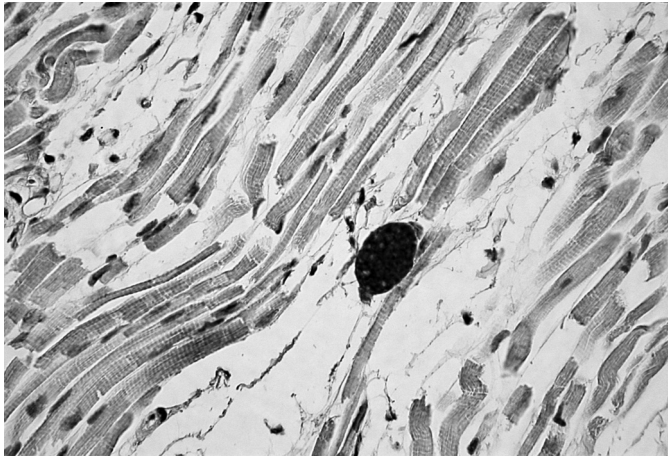


Fig.1. Sheep abortion caused by *Neospora caninum*. Strongly positive staining for *N. caninum* in a myocardium fragment. Immunohistochemistry with avidin-biotin peroxidase and hematoxylin counterstaining, magnification 20x.

## DISCUSSION

The present study diagnosed neosporosis in aborted sheep fetuses on the basis of histopathological detection of parasite cysts in fetus tissues and confirmation by IHC tests. As reported for goats (Eleni et al. 2004), clinical cases associated to natural infection of sheep by *Neospora caninum* are uncommon, with a few abortion cases (Dubey & Lindsay 1990, Jolley et al. 1999) and congenital disorders (Pena et al. 2007) described. However, several serological surveys conducted in different countries, including Brazil, showed that the infection is disseminated in this species (Figliuolo et al. 2004, Salaberry et al. 2010), as well as in other animal species (Silva et al. 2010, Teixeira et al. 2010, Toscan et al. 2010, Camillo et al. 2011, Varaschin et al. 2011). In cattle, abortions caused by *N. caninum* are common (Corbelliniet al. 2000, Pescadore et al. 2005, Oliveira et al. 2010).

The abortion rate was 5.38% in the outbreak studied. A few reports on sheep abortion by neosporosis are available. In Switzerland, four abortions were reported over six years in a herd of 117 ewes. These were attributed to *N. caninum* infection based on PCR tests, and one of the cases revealed myositis, meningitis and microgranulomas in the brain detected by histological tests (Hässig et al. 2003). Spilovská et al. (2009) observed that 3.7% of lamb abortions in Slovakia were seropositive for *N. caninum*.

The heart lesions found in the histological observations of the two fetuses evaluated, nonsuppurative myocarditis associated to parasites, are similar to those found in cattle (McAllister et al. 1996, Corbelliniet al. 2000) and goat fetuses. In goats, degeneration and muscle fiber necrosis is also observed (Eleni et al. 2004). In an experimental study on sheep, Dubey & Lindsay (1990) observed mononuclear myosites associated to necrotic foci in leg muscle in three of four fetuses aborted.

Diffuse gliosis associated to mononuclear cell foci found in the brain fragments was not as severe as described by Bishop et al. (2010), who observed, in addition to these lesions, necrosis and edema at the rostral colliculi in the midbrain of sheep fetuses infected by *N. caninum*. Dubey & Lindsay (1990) described brain hemorrhage. In goat fetuses, Eleni et al. (2004) observed nonsuppurative meningoencephalitis and multifocal necrosis associated with *N. caninum* cysts in the cortex area. Histological consequences of *N. caninum* infection in heart and brain of cattle fetuses are similar to those described for the sheep fetuses investigated in present study (Corbelliniet al. 2000, Pescador et al. 2007, Cabral et al. 2009).

The main differential diagnosis of neosporosis is toxoplasmosis. Brain lesions caused by toxoplasmosis are congestion, malacic areas, occurrence of cysts and tachyzoites, microgliosis and moderate lymphoplasmocitary infiltrate, *fibrinous microthrombosis* and moderate diffuse lymphocytic meningitis. Another consequence of toxoplasmosis for sheep is a high abortion rate (Motta et al. 2008).

Other minor pathogens that cause sheep abortion are *Listeria monocytogenes*, *Chlamydothryx abortus*, *Campylobacter fetus*, *Brucella ovis*, *Salmonella abortus*, Parainfluenza 3 and mucosal disease virus (Riet-Correa et al. 2007).

IHC is a specific and sensitive technique that, combined with histological examination, considerably improves diagnostic accuracy. In the case of infections by protozoans such as *N. caninum*, IHC assays are particularly useful because histological examinations may fail to detect cysts and tachyzoites. In addition, histological lesions caused by *N. caninum* are difficult to differentiate from those caused by *T. gondii*, and IHC is therefore necessary to confirm diagnosis. One disadvantage of IHC is that polyclonal antibodies such as those used here can cross-react with nontarget antigens. Nevertheless, in the present study, diagnosis of *N. caninum* infection was based on the staining intensity of IHC tests, which was strongly positive for this protozoan and weakly positive for *T. gondii*.

This is the first description of neosporosis in sheep fetuses as the primary cause of abortion in Brazil. Although the data obtained are insufficient to assess the magnitude of reproductive losses caused by this pathology and its impact on sheep farming in Brazil, *Neospora caninum* must be considered a potential agent of sheep abortion.

**Acknowledgements.** - To the National Council for Scientific and Technological Development (CNPq, Proc.480671/2009-5) and *Fundação de Apoio ao Desenvolvimento do Ensino, Ciência e Tecnologia do Estado de Mato Grosso do Sul* (Fundect, Proc.23/200.226/2010) for awarding a fellowship to Ana Paula Pinto.

## REFERÊNCIAS

- Anderson M.L., Blanchard P.C., Barr B.C., Dubey J.P., Hoffman R.L. & Conrad P.A. 1991. *Neospora*-like protozoan infection as a major cause of abortion in California dairy cattle. *J. Am. Vet. Med. Assoc.* 198:241-244.
- Andreotti R., Pinckney R., Gomes A., Pires P.P. & Silva E.A. 2002. Sorologia anti-*Neospora caninum* em gado de corte e em cães no estado de Mato Grosso do Sul, Brasil Central. Anais 12º Congresso Brasileiro de Parasitologia Veterinária, Rio de Janeiro. Colégio Brasileiro de Parasitologia Veterinária. (CD-ROM)
- Barber J.S., Gasser R.B., Ellis J., Reichel M.P., McMillan D. & Trees A.J. 1997.

- Prevalence of antibodies to *Neospora caninum* in different canid populations. *J. Parasitol.* 83:1056-1058.
- Barr B.C., Anderson M.L., Woods L.W., Dubey J.P. & Conrad P.A. 1992. *Neospora*-like protozoal infections associated with abortion in goats. *J. Vet. Diagn. Invest.* 4:365-367.
- Bishop S., King J., Windsor P., Reichel M.P., Ellis J. & Šlapeta J. 2010. The first report of ovine cerebral neosporosis and evaluation of *Neospora caninum* prevalence in sheep in New South Wales. *Vet. Parasitol.* 170:137-142.
- Buxton D., Maley S.W., Thomson K.M., Trees A.J. & Innes E.A. 1997. Experimental infection of non-pregnant and pregnant sheep with *Neospora caninum*. *J. Comp. Pathol.* 117(1):1-16.
- Buxton D., Maley S.W., Wright S., Thomson K.M., Rae A.G. & Innes E.A. 1998. The pathogenesis of experimental neosporosis in pregnant sheep. *J. Comp. Pathol.* 118(4):267-279.
- Cabral A.D., Camargo C.N., Galletti N.T.C., Okuda L.H., Pituco E.M. & Del Fava C. 2009. Diagnosis of *Neospora caninum* in bovine fetuses by histology, immunohistochemistry, and nested-PCR. *Revta Bras. Parasitol. Vet.* 18(4):14-19.
- Camillo G., Cezar A.S., Antonello A.M., Sangioni L.A., Flores E.F., Pereira G.R., Gonçalves P.B.D. & Vogel F.S.F. 2011. Detecção de anticorpos anti-*Neospora caninum* em amostras individuais e coletivas de leite de bovinos pela reação de imunofluorescência indireta. *Pesq. Vet. Bras.* 31(6):482-486.
- Corbellini L.G. 2001. Infecção por *Neospora caninum* em bovinos leiteiros no Estado do Rio Grande do Sul: diagnóstico, avaliação sorológica e aspectos epidemiológicos. Dissertação de Mestrado em Ciências Veterinárias, Universidade Federal do Rio Grande do Sul, Porto Alegre.
- Corbellini L.G., Driemeier D., Cruz C. & Dias M.M. 2000. Aborto bovino por *Neospora caninum* no Rio Grande do Sul. *Ciência Rural* 30(5):863-868.
- Dubey J.P. & Lindsay D.S., 1990. *Neospora caninum* induced abortion in sheep. *J. Vet. Diagn. Invest.* 3:230-233.
- Dubey J.P. & Lindsay D.S. 1996. A review of *Neospora caninum* and neosporosis. *Vet. Parasitol.* 67:1-59.
- Dubey J.P. 2003. Review of *Neospora caninum* and neosporosis in animals. *Korean J. Parasitol.* 41:1-16.
- Dubey J.P., Carpenter J.L., Speer C.A., Topper M.J. & Uggla A. 1988. Newly recognized fatal protozoan disease of dogs. *J. Am. Vet. Med. Assoc.* 192:1269-1285.
- Dubey J.P., Lindsay D.S. & Lipscomb T.P. 1990. Neosporosis in cats. *Vet. Pathol.* 27(5):335-339.
- Dubey J.P., Morales J.A., Villalobos P., Lindsay D.S., Blagburn B.L. & Topper M.J. 1996. Neosporosis associated abortion in a dairy goat. *J. Am. Vet. Med. Assoc.* 208:263-265.
- Eleni C., Crotti S., Manuali E., Costarelli S., Filippini G., Moscati L. & Magrino S. 2004. Detection of *Neospora caninum* in an aborted goat foetus. *Vet. Parasitol.* 123:271-274.
- Figliuolo L.P.C., Kasai N., Ragozo A.M.A., Paula V.S.O., Dias R.A., Souza S.L.P. & Gennari S.M. 2004. Prevalence of anti-*Toxoplasma gondii* and anti-*Neospora caninum* antibodies in ovine from São Paulo State, Brazil. *Vet. Parasitol.* 123(3/4):161-166.
- García-Vázquez Z., Cruz-Vázquez C., Medina E.L., García T.D. & Chavarría M.B. 2002. Serological survey of *Neospora caninum* infection in dairy cattle herds in Aguascalientes, Mexico. *Vet. Parasitol.* 106:115-120.
- Gondim L.F.P., Sartor I.F., Hesagawa M. & Yamane I. 1999. Seroprevalence of *Neospora caninum* in dairy cattle in Bahia, Brazil. *Vet. Parasitol.* 86:71-75.
- Gondim L.F.P., McAllister M.M., Pitt W.C. & Zemlicka D.E. 2004. Coyotes (*Canis latrans*) are definitive hosts of *Neospora caninum*. *Intern. J. for Parasitol.* 34(2):159-161.
- Hässig M., Sager H., Reitt K., Ziegler D., Strabel D. & Gottstein B. 2003. *Neospora caninum* in sheep: A herd case report. *Vet. Parasitol.* 117:213-220.
- Jolley W.R., McAllister M.M., McGuire A.M., Wills R.A. 1999. Repetitive abortion in *Neospora*-infected ewes. *Vet. Parasitol.* 82:251-257.
- Lindsay D.S. & Dubey J.P. 1989. Immunohistochemical diagnosis of *Neospora caninum* tissue sections. *Am. J. Vet. Res.* 50:1981-1983.
- McAllister M.M., McGuire A.M., Jolley W.R., Lindsay D.S., Trees A.J. & Stobart R.H. 1996. Experimental neosporosis in pregnant ewes and their offspring. *Vet. Pathol.* 33(6):647-655.
- McAllister M.M., Dubey J.P., Lindsay D.S., Jolley W.R., Wills R.A. & McGuire A.M. 1998. Dogs are definitive hosts of *Neospora caninum*. *Int. J. Parasitol.* 28:1473-1478.
- Morales E., Trigo F.J., Ibarra F., Puente E. & Santacruz M. 2001. Neosporosis in Mexican dairy herds: Lesions and immunohistochemical detection of *Neospora caninum* in fetuses. *J. Comp. Pathol.* 125:58-63.
- Motta A.C., Vieira M.I.B., Bondan C., Edelweiss M.I.A., Dametto M.A. & Gomes A. 2008. Aborto em ovinos associado à toxoplasmose: caracterização sorológica, anatomopatológica e imuno-histoquímica. *Revta Bras. Parasitol. Vet.* 17(1):204-208.
- Mugridge N.B., Morrison D.A., Heckerath A.R., Johnson A.M. & Tender A.M. 1999. Phylogenetic analysis based on full-length large subunit ribosomal RNA gene sequence comparison reveals that *Neospora caninum* is more closely related to *Hammondia heydorni* than to *Toxoplasma gondii*. *Int. J. Parasitol.* 29:1545-1556.
- Munhoz K.F. 2009. Soro-ocorrência de anticorpos contra *Neospora caninum* em ovinos de propriedades rurais localizadas no norte do Paraná, Brasil. Dissertação de Mestrado em Ciência Animal, Programa de Pós-Graduação em Ciência Animal, Centro de Ciências Agrárias, Universidade Estadual de Londrina, Londrina, PR. 66p.
- Oliveira V.S.F., Álvarez-García G., Ortega-Mora L.M., Borges L.M.F. & Silva A.C. 2010. Abortions in bovines and *Neospora caninum* transmission in an embryo transfer center. *Vet. Parasitol.* 173:206-210.
- Otter A., Jeffrey M., Griffiths I.B. & Dubey J.P. 1995. A survey of the incidence of *Neospora caninum* infection in aborted and stillborn bovine fetuses in England and Wales. *Vet. Rec.* 136:602-606.
- Pena H.F.J., Soares R.M., Ragozo A.M.A., Monteiro R.M., Yai L.E.O., Nishi S.M. & Gennari S.M. 2007. Isolation and molecular detection of *Neospora caninum* from naturally infected sheep from Brazil. *Vet. Parasitol.* 147(1/2):61-66.
- Pescador C.A., Corbellini L.G., Corrêa A., Schmitz M., Raymundo D.L. & Driemeier D. 2005. Aborto bovino por *Neospora caninum*: fatores associados ao resultado positivo da imunistoquímica. Anais I Fórum Brasileiro de Estudos sobre *Neospora caninum*, Universidade de São Paulo (USP), São Paulo. 19p.
- Pescador C.A., Corbellini L.G., Oliveira E.C., Raymundo D.L. & Driemeier D. 2007. Histopathological and immunohistochemical aspects of *Neospora caninum* diagnosis in bovine aborted fetuses. *Vet. Parasitol.* 150(1/2):159-163.
- Riet-Correa F. & Méndez M.C. 2007. Intoxicação por plantas e micotoxinas, p.114-122. In: Riet-Correa F., Schild A.L., Lemos R.A.A. & Borges J.R.J. (Eds), *Doenças de Ruminantes e Equídeos*. Vol.2. 3ª ed. Pallotti, Santa Maria.
- Salaberry S.R.S., Okuda L.H., Nassar A.F.C., Castro J.R. & Lima-Ribeiro A.M.C. 2010. Prevalence of *Neospora caninum* antibodies in sheep flocks of Uberlândia county, MG. *Revta Bras. Parasitol. Vet.* 19(3):148-151.
- Silva S.P., Mota R.A., Faria E.B., Fernandes E.F.T.S., Neto O.L.S., Albuquerque P.P.F. & Dias H.L.T. 2010. Anticorpos IgG anti-*Neospora caninum* e *Toxoplasma gondii* em búfalas (*Bubalus bubalis*) criadas no Estado do Pará. *Pesq. Vet. Bras.* 30(5):443-446.
- Špilovská S., Reiterova K., Kovačová D., Bobaková M. & Dubinský P. 2009. The first finding of *Neospora caninum* and the occurrence of other abortifacient agents in sheep in Slovakia. *Vet. Parasitol.* 164:320-323.
- Teixeira W.C., Uzêda R.S., Gondim L.F.P., Silva I.S., Pereira H.M., Alves L.C. & Faustino M.A.G. 2010. Prevalência de anticorpos anti-*Neospora caninum* (Apicomplexa: Sarcocystidae) em bovinos leiteiros de propriedades rurais em três microrregiões no estado do Maranhão. *Pesq. Vet. Bras.* 30(9):729-734.
- Toscan G., Cadore G.C., Pereira R.C.F., Silva G.B., Cezar A.S., Sangioni L.A., Oliveira L.S.S. & Vogel F.S.F. 2010. Neosporose equina: ocorrência de anticorpos anti-*Neospora* spp. e associação entre *status* sorológico de éguas e de suas crias. *Pesq. Vet. Bras.* 30(8):641-645.
- Trees A.J., Davison H.C., Innes E.A. & Wastling J.M. 1999. Towards evaluating the economic impact of bovine neosporosis. *Intern. J. for Parasitol.* 29(8):1195-1200.
- Varaschin M.S., Guimarães A.M., Hirsch C., Mesquita L.P., Abreu C.C., Rocha C.M.B.M., Wouters F. & Moreira M.C. 2011. Fatores associados a soroprevalência de *Neospora caninum* e *Toxoplasma gondii* em rebanhos caprinos na região de Minas Gerais. *Pesq. Vet. Bras.* 31(1):53-58.