

Postweaning multisystemic wasting syndrome in farmed wild boars (*Sus scrofa*) in Rio Grande do Sul¹

André Mendes Ribeiro Corrêa², Priscila Zlotowski², Daniela Bernadete Rozza², Mauro Riegert Borba², Juliano de Souza Leal², Cláudio Estêvão Farias da Cruz² and David Driemeier^{2*}

ABSTRACT.- Corrêa A.M.R., Zlotowski P., Rozza D.B., Borba M.R., Leal J.S., Cruz C.E.F. & Driemeier D. 2006. **Postweaning multisystemic wasting syndrome in farmed wild boars (*Sus scrofa*) in Rio Grande do Sul.** *Pesquisa Veterinária Brasileira* 26(3):154-156. Department of Veterinary Pathology, Faculty of Veterinary Medicine, Federal University of Rio Grande do Sul (UFRGS), Av. Bento Gonçalves 9090, Porto Alegre, RS 91540-000, Brazil. E-mail: davetpath@ufrgs.br

This report concerns an outbreak of postweaning multisystemic wasting syndrome in wild boars from commercial herds in Rio Grande do Sul, Brazil. The main clinical signs were progressive wasting, respiratory distress, diarrhea, and ocular discharges. Enhanced lymph nodes and spleens, ascites, hydrothorax, and non collapsed lungs were the principal gross lesions. Varying degrees of lymphohistiocytic infiltrates in lymph nodes, spleen, and intestines were the most significant microscopic changes. Although a total of 26 animals had showed clinical and pathological findings consistent with the disease, only in 11 of them it was possible to confirm a PMWS diagnosis through the association of specific lesions in lymphoid tissues with the presence of the viral antigen detected by immunohistochemistry. These findings were similar to those reported in the swine disease.

INDEX TERMS: Circovirus, PCV2, PMWS, immunohistochemistry, wild boar, *Sus scrofa*.

RESUMO.- [Síndrome multissistêmica do definhamento suíno em javalis (*Sus scrofa*) de criações comerciais no Rio Grande do Sul.] Descreve-se a ocorrência da síndrome multissistêmica do definhamento suíno em javalis de dois rebanhos comerciais no estado do Rio Grande do Sul. Os principais sinais observados foram definhamento progressivo, tosse, espirros, diarreia e descarga ocular. Linfonodos e baços aumentados, ascite, hidrotórax e pulmões não colapsados foram os principais achados macroscópicos. Infiltrados linfo-histiocitários de graus variáveis em linfonodos, baços e intestinos foram as lesões microscópicas mais relevantes. Embora 26 animais tenham apresentado achados clínicos e patológicos compatíveis com a enfermidade, apenas em 11 desses foi possível confirmar o diagnóstico através da associação de lesões histológicas específicas nos tecidos linfóides com a presença do antígeno viral, detectado pela técnica de imunistoquímica. Tanto os achados clínicos como patológicos foram semelhantes aos descritos na doença suína.

TERMOS DE INDEXAÇÃO: Circovírus, PCV2, SMDLD, imunistoquímica, javali, *Sus scrofa*.

INTRODUCTION

Postweaning multisystemic wasting syndrome (PMWS) was firstly described in Canada (Harding 1997) and since then has been reported as a worldwide cause of economic losses in the pig industry (Segalés & Domingo 2002). PMWS, porcine dermatitis and nephropathy syndrome (PDNS), and reproductive disorders have all been associated with porcine circovirus type 2 (PCV2) infections (Allan & Ellis 2000, Segalés & Domingo 2002, Clark et al. 2004). Clinical disease has been associated with coinfection, activation of the immune system, and immunosuppression and may include wasting, lymphadenopathy, diarrhea, paleness and dyspnea (Allan & Ellis 2000, Krakowka et al. 2005). While enlarged lymph nodes, non-collapsed lungs, and kidneys with multiple pale foci are the most common gross lesions, lymphocyte depletion and granulomatous inflammation have been the principal histopathological findings associated with the disease (Clark et al. 2004, Segalés et al. 2004). The diagnosis of PMWS has been based on the clinical signs, the presence of lymphocyte depletion and granulomatous inflammation in lymphoid tissues associated with the presence of PCV2 (Sorden 2000). PCV2 antigens and nucleic acids have been demonstrated by

¹ Received on April 28, 2006.

Accepted for publication on May 2, 2006.

² Depto Patologia Clínica Veterinária, Universidade Federal do Rio Grande do Sul (UFRGS), Av. Bento Gonçalves 9090, Porto Alegre, RS 91540-000, Brasil. * Corresponding author: davetpat@ufrgs.br

immunohistochemistry or *in-situ*-hybridization (Rosell et al. 1999).

After the first description of PMWS in Brazil (Zanella 2001), outbreaks of the disease have been reported (Corrêa et al. 2005, França et al. 2005) and associated with important economic losses. Besides being highly prevalent in swine (Segalés & Domingo 2002, Larochelle et al. 2003), PMWS has lately also been demonstrated in wild boars (*Sus scrofa*) in Canada (Ellis et al. 2003) and in Europe (Schulze et al. 2004, Toplak et al. 2004, Vicente et al. 2004). In Brazil, the disease has already been detected in wild boars (Zanella et al. 2005), which are almost exclusively restricted to commercial herds and the consumption of this exotic meat has not reached higher levels just because its high price. This communication describes the occurrence of the PMWS in southern Brazilian commercial herds of wild boars.

MATERIALS AND METHODS

A total of 26 wild boars (*Sus scrofa*) that were affected by a clinical condition consistent with PMWS were necropsied. Fragments of skin, spleen, intestines, liver, stomach, kidneys, lungs, heart, and central nervous system were collected, fixed in 10% buffered formalin, and routinely processed for histology. Haematoxylin and eosin (HE), Ziehl-Neelsen, and Periodic Acid Schiff (PAS) were the staining methods (Prophet et al. 1992) used. Samples of lungs (6), intestines (4) and ocular discharges (3) were submitted for bacteriology. Immunohistochemical procedures were performed on formalin fixed, paraffin-embedded sections of mesenteric lymph nodes, kidneys, lungs and intestines. Polyclonal rabbit antibody to PCV2 (Sorden et al. 1999) at 1/1000 dilution was incubated for 1h and sections were stained by the streptavidin-biotin immunoperoxidase technique using diaminobenzidine as chromogen.

RESULTS

The disease occurred in two farms located in the state of Rio Grande do Sul, Brazil. Herds were composed of approximately 1,250 animals, and farmers noticed a 50-percent mortality rate from birth to slaughter, at 9-month-old. A total of 26 non-thriving 4 to 5-month-old wild boars that had been showing progressive wasting (Fig. 1) and at least one of the following signs: respiratory distress, ocular discharge, and diarrhea were euthanized and necropsied. Animals



Fig.1. A 4-month-old wild boar affected by the postweaning multisystemic wasting syndrome (PMWS).

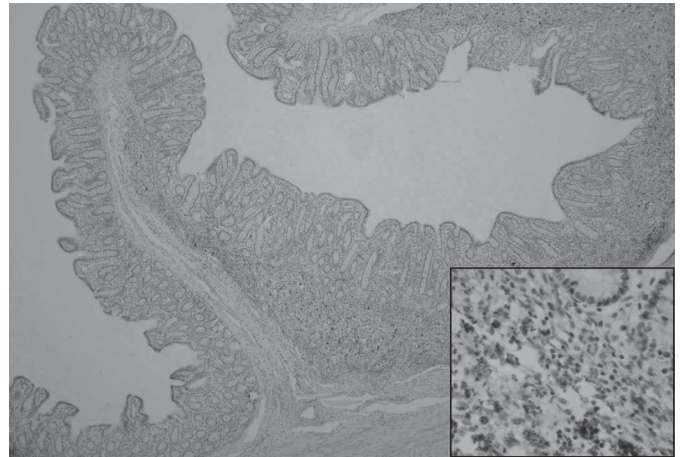


Fig.2. Fusion of the intestinal villi in a wild boar affected by PMWS due to lymphohistiocytic infiltration and edema. Positive immunostaining by polyclonal anti-PCV2 serum in histiocytes from Peyer's patches. Streptavidin-biotin, obj.4. [Inset: There are numerous viral inclusions in histiocytes. Streptavidin-biotin, obj.40.]

had been receiving valnemulin mixed in their diet. Gross lesions included mildly to moderately enlarged lymph nodes and spleens, ascites, hydrothorax, and non collapsed lungs. Lung cranioventral consolidations and interlobular edema, serosal atrophy of the cardiac fat, and gastric ulcers were observed in some cases. Mesenteric lymph nodes were greatly enlarged in two animals.

Main histological findings were moderate to severe lymphohistiocytic infiltrates with giant cells in lymph nodes, spleen, and intestines; and lymphoid depletion in lymph nodes and spleen. Further microscopic findings included hyperplasia of lymphoid aggregates and dilatation of lymphatic vessels in the intestines. In addition, lesions indicative of a bacterial infection, such as multifocal fibrin-necrotizing enteritis, necrotizing lymphadenitis, multiple foci of purulent broncho-

Table 1. Microscopic findings in 26 wild boars from the outbreak of PMWS

Microscopic findings	Number of cases
Lymphohistiocytic infiltrates	
Lymph nodes	23
Spleen	9
Intestines	16
Giant cells	
Lymph nodes	9
Spleen	5
Intestines	4
Lymphoid depletion	
Lymph nodes	12
Spleen	8
Bronchopneumonia	10
Interstitial pneumonia	7
Dilatation intestinal lymphatic vessels	9
Fibrin-necrotizing enteritis	5
Necrotizing lymphadenitis	1
Purulent conjunctivitis	5
Positive IHQ	
Lymph nodes	11
Intestines	8
Lungs	6

pneumonia, interstitial pneumonia, and purulent conjunctivitis were observed in some animals.

Pasteurella multocida was isolated from lesions of broncho-pneumonia in three animals, *E. coli* was present in the intestinal sample from one animal, and *Staphylococcus hyicus* and *Streptococcus equisimilis* were detected in the ocular discharges from two wild pigs. Histiocytes and giant cells from lymph nodes, intestines (Fig.2), and lungs stained positively in the immunohistochemical probing. Except for one animal that showed positive IHQ staining only in the intestines, the IHQ reactions corresponded to different organs from the remaining 10 animals. The main microscopic findings are summarized in Table 1. In PAS stained sections, characteristic pseudo-hyphae consistent with *Candida* sp were seen infiltrating in the gastric mucosa from two wild pigs.

DISCUSSION

Clinical and pathological findings were consistent with those extensively reported in porcine PMWS; however the enlargement of lymph nodes was milder and no renal lesions were observed. Markedly positive staining under immunohistochemical probing were observed only in 11 (42.3%) of the 26 animals examined. However, the amount of PCV2 detected in the tissues and the severity of the lesions were consistent with the diagnosis of PMWS (Krakowka et al. 2005). Both, initial or terminal stages of the disease may be associated with mild or even absence of PCV2 antigen (Segalés et al. 2004), which may have complicated the diagnosis of some cases.

The average age of the affected wild boars was approximately 18 weeks; therefore animals were older than domestic pig suffering from PMWS (Segalés & Domingo 2002), as already observed (Schulze et al. 2004). It may probably be linked to the latter age (75-days-old) in which wild boars have usually been weaned at these farms. Although we were not able to determine if the PCV2 strains have been the same affecting domestic and wild pigs in southern Brazil, the antibody has reacted quite well for both strains, suggesting that they may extensively share common antigens, and this is in agreement with previous report, in which strains were almost identical (Schulze et al. 2004).

Bacterial infections were demonstrated in some animals, supporting the hypothesis previously proposed that concurrent infections may serve as significant factors in the triggering of PMWS (Segalés & Domingo 2002, Schulze et al. 2004). The involvement of a *Mycobacterium* specie was excluded by the Ziehl-Neelsen staining. *Candida albicans* infection has already been associated with PMWS infected pigs (Zlotowski et al. 2006). It is possible that antibiotic therapy and/or immunosuppression may have predisposed fungal infection in these wild pigs. The occurrence of PMWS in domestic and wild pigs highlights the possibility of transmission, which probably occurs most commonly from domestic pigs to wild boars.

Acknowledgements.- This investigation was supported by grants from CAPES and CNPq, Brazil.

REFERENCES

Allan G.M. & Ellis J.A. 2000. Porcine circoviruses: a review. J. Vet. Diag. Invest. 12(1):3-14.

Clark E.G., Ellis J.A., Allan G.M. & Krakowka S. 2004. Post-weaning multisystemic wasting syndrome in swine, p.1374-1386. In: Coetzer J.A.W. & Tustin R.C. (ed.) Infectious Diseases of Livestock. 2nd ed. Oxford University Press, Oxford.

Corrêa A.M.R., Pescador C.A., Schmitz M., Zlotowski P., Rozza D.B., Oliveira E.C., Barcellos D.E. & Driemeier D. 2006. Clinical and pathological aspects of swine circovirus in Rio Grande do Sul, southern Brazil. Pesq. Vet. Bras. 26(1):9-13.

Ellis J., Spinato M., Yong C., West K., McNeilly F., Meehan B., Kennedy S., Clark E., Krakowka S. & Allan G. 2003. Porcine circovirus 2 associated disease in Eurasian wild boar. J. Vet. Diag. Invest. 15(4):364-368.

França T.N., Peixoto P.V., Zanella J. & Driemeier D. 2005. Surto de circovirose (Síndrome do Definhamento Multissistêmico de Suínos Desmamados) no estado do Rio de Janeiro. Pesq. Vet. Bras. 25(1):39-53.

Harding J.C. 1997. Post-weaning multisystemic wasting syndrome (PMWS): Preliminary epidemiology and clinical findings. Proc. Am. Assoc. Swine Practit., p.503.

Krakowka S., Ellis J., McNeilly F., Waldner C. & Allan G. 2005. Features of porcine circovirus-2 disease: correlations between lesions, amount and distribution of virus, and clinical outcome. J. Vet. Diag. Invest. 17(3):213-222.

Larochelle R., Magar R. & D'Allaire S. 2003. Comparative serologic and virologic study of commercial herds with and without postweaning multisystemic wasting syndrome. Can. J. Vet. Res. 67(2):114-120.

Prophet E.B., Mills B., Arrington J.B. & Sobin L.H. 1992. Laboratory Methods in Histotechnology. Armed Forces Institute of Pathology, American Registry of Pathology, Washington, DC. 279p.

Rosell C., Segalés J., Plana-Durán J., Balasch M., Rodriguez-Arrijo G.M., Kennedy S., Allan G.M., McNeilly F., Latimer K.S. & Domingo M. 1999. Pathological, immunohistochemical, and in-situ hybridization studies of natural cases of postweaning multisystemic wasting syndrome (PMWS) in pigs. J. Comp. Pathol. 120(1):59-78.

Segalés J. & Domingo M. 2002. Postweaning multisystemic wasting syndrome (PMWS) in pigs. A review. Vet. Quart. 24(3):109-124.

Segalés J., Rosell C. & Domingo M. 2004. Pathological findings associated with naturally acquired porcine circovirus type 2 associated disease. Vet. Microbiol. 98(2):137-149.

Schulze C., Segalés J., Neumann G., Hlinak A., Calsamiglia M. & Domingo M. 2004. Identification of postweaning multisystemic wasting syndrome in European wild boar (*Sus scrofa*). Vet. Rec. 154(22):694-696.

Sorden S.D., Harms P.A., Nawagitgul P., Cavanaugh D. & Paul P.S. 1999. Development of a polyclonal-antibody-based immunohistochemical method for the detection of type 2 porcine circovirus in formalin-fixed, paraffin-embedded tissue. J. Vet. Diag. Invest. 11(6):528-530.

Sorden S.D. 2000. Update on porcine circovirus and postweaning multisystemic wasting syndrome (PMWS). Swine Health Prod. 8(3):133-136.

Toplak I., Grom J., Hostnik P. & Barlic-Maganja D. 2004. Phylogenetic analysis of type 2 porcine circoviruses identified in wild boar in Slovenia. Vet. Rec. 155(6):178-180.

Vicente J., Segalés J., Höfle U., Balasch M., Plana-Durán J., Domingo M. & Gortázar C. 2004. Epidemiological study on porcine circovirus type 2 (PCV2) infection in the European wild boars (*Sus scrofa*). Vet. Res. 35(2):243-253.

Zanella J.R. & Mores N. 2001. Diagnóstico da síndrome multissistêmica do definhamento do leitão desmamado (SMDLD) no Brasil causada pelo circovírus suíno tipo 2. Circular Técnica 270, Embrapa-CNPQA, Concórdia, p.1-3.

Zanella J.R.C., Bordin L.C., Mores N., Felício R.P., Furlan F.H. & Simon N.L. 2005. Detecção do Circovírus suíno tipo 2 (PCV2) em javalis (*Sus scrofa*) com sintomatologia de definhamento. Anais do XII Congresso Brasileiro de Veterinários Especialistas em Suínos (Abraves), Fortaleza, v.2, p. 105-106.

Zlotowski P., Rozza D.B., Pescador C.A., Barcellos D.E., Ferreira L., Sanches E.M., Driemeier D. 2006. Muco-cutaneous candidiasis in two pigs with postweaning multisystemic wasting syndrome. Vet. J. 171(3):566-569.