

Experimental poisoning in broiler chickens by *Senecio vernonioides*, *Senecio conyzaeifolius* and *Senecio paulensis*¹

Claudia Pies Biffi², Thaiza Savaris³, Leíse Hermann Parizoto³, Daiane Ogliari³,
Vanessa Boreli³, Tiffany Emmerich³, Dale Gardner⁴ and Aldo Gava^{3*}

ABSTRACT.- Biffi C.P., Savaris T., Parizoto L.H., Ogliari D., Boreli V., Emmerich T., Gardner D. & Gava A. 2018. **Experimental poisoning in broiler chickens by *Senecio vernonioides*, *Senecio conyzaeifolius* and *Senecio paulensis*.** *Pesquisa Veterinária Brasileira* 38(11):2065-2069. Laboratório de Patologia Animal, Centro de Ciências Agroveterinárias, Universidade do Estado de Santa Catarina, Av. Luiz de Camões 2090, Conta Dinheiro, Lages, SC 88520-000, Brazil. E-mail: aldo.gava@udesc.br

Plants of the genus *Senecio* sp. are known to produce hepatic lesions in different animal species, including man. To evaluate the toxicity of three species of *Senecio* found in regions where cattle are bred in the state of Santa Catarina, experiments were conducted on broiler chickens (*Gallus domesticus*). Green leaves of *S. conyzaeifolius*, *S. vernonioides* and *S. paulensis* were collected and dried in the shade. After drying, the leaves were ground, mixed into the feed and fed to the chickens divided into 3 groups. Group 1 and Group 2 received single doses of 5g/kg and 20g/kg, respectively. Group 3 was given daily doses of 1g/kg for 20 days (values corresponding to green plant) and Group 4 (control) received free feed of the plant. For each group, five chickens were submitted to necropsy at 30 days and five to 60 days after planting, and five chickens that consumed *S. vernonioides* and *S. conyzaeifolius* at the dose of 1g/kg for 20 days were necropsied at 90 days after the beginning of the experiment. Macroscopic lesions were observed in chickens that consumed *S. vernonioides* at a dose of 1 g/kg for 20 days in birds necropsied at 30, 60 and 90 days and were characterized mainly by liver of firm consistency, diminished in size with yellowish coloration and evident lobular pattern, ascites and hydropericardium. In microscopy the main lesions observed were megalocytosis, hepatocyte swelling, fibrosis and biliary hyperplasia and were more intense at the dosage of 1 g/kg for 20 days for *S. vernonioides* and less severe in the chickens that ingested *S. conyzaeifolius*. The chickens that received *S. paulensis* showed no macroscopic and microscopic lesions.

INDEX TERMS: Poisonous plants, broiler chickens, poisoning plants, *Senecio conyzaeifolius*, *S. vernonioides*, *S. paulensis*, toxicoses.

RESUMO.- [Intoxicação experimental em frangos de corte por *Senecio vernonioides*, *Senecio conyzaeifolius* e *Senecio paulensis*.] As plantas do gênero *Senecio* sp. são conhecidas

por produzirem lesões hepáticas em diferentes espécies de animais, inclusive no homem. Para avaliar a toxicidade de três espécies de *Senecio* encontradas em regiões onde são criados bovinos no estado de Santa Catarina, foram conduzidos experimentos em frangos de corte (*Gallus domesticus*). Folhas verdes de *S. conyzaeifolius*, *S. vernonioides* e *S. paulensis* foram coletadas e secadas a sombra. Após a secagem, as folhas foram trituradas, misturadas na ração e fornecidas aos frangos divididos em 3 grupos. O Grupo 1 e o Grupo 2 receberam doses únicas de 5g/kg e 20g/kg, respectivamente. Ao Grupo 3 foram fornecidas doses diárias de 1g/kg por 20 dias (valores correspondentes a planta verde) e o Grupo 4 (Controle) recebeu ração livre da planta. Para cada grupo, cinco frangos

¹ Received on July 23, 2018.

Accepted for publication on August 8, 2018.

Part of the PhD Thesis of first author, Universidade do Estado de Santa Catarina.

² Post-Graduation Course, Universidade do Estado de Santa Catarina (UDESC), Av. Luiz de Camões 2090, Conta Dinheiro, Lages, SC 88520-000, Brazil.

³ Laboratório de Patologia Animal, Centro de Ciências Agroveterinárias (CAV), Universidade do Estado de Santa Catarina (UDESC), Av. Luiz de Camões 2090, Conta Dinheiro, Lages, SC 88520-000. *Corresponding author: aldo.gava@udesc.br

⁴ Poisonous Plant Research Laboratory, Agricultural Research Service (ARS), United States Department of Agriculture (USDA), Logan, Utah, USA.

foram submetidos à necropsia aos 30 dias e cinco aos 60 dias após o início do fornecimento da planta e cinco frangos que consumiram *S. vernonioides* e *S. conyzaefolius* na dosagem de 1g/kg por 20 dias foram necropsiados aos 90 dias após início do experimento. Lesões macroscópicas foram observadas nos frangos que consumiram *S. vernonioides* na dose de 1g/kg por 20 dias nas aves necropsiadas aos 30, 60 e 90 dias e se caracterizaram principalmente por fígado de consistência firme, diminuído de tamanho com coloração amarelada e padrão lobular evidente, ascite e hidropericárdio. Na microscopia as principais lesões observadas foram megalocitose, tumefação de hepatócitos, fibrose e hiperplasia biliar e foram mais intensas na dosagem de 1g/kg por 20 dias para *S. vernonioides* e menos graves nos frangos que ingeriram *S. conyzaefolius*. Os frangos que receberam *S. paulensis* não mostraram lesões macroscópicas e microscópicas.

TERMOS DE INDEXAÇÃO: Plantas tóxicas, frangos de corte, intoxicação por plantas, *Senecio conyzaefolius*, *S. vernonioides*, *S. paulensis*, toxicoses.

INTRODUCTION

Plants of the genus *Senecio* are responsible for the death of cattle in Brazil, mainly in the Southern region (Riet-Correa & Medeiros 2001). However, since they are not very palatable plants, they are only consumed when cattle undergo periods of food restriction, whether due to drought, winter or prolonged transport (Riet-Correa et al. 1993, Pessoa et al. 2013). Another form of plant ingestion is its presence in silages, or, hay (Méndez et al. 1987, Barros et al. 2007). In the State of Rio Grande do Sul, the main species involved in cases of natural and experimental poisoning in production animals include: *Senecio brasiliensis* (Barros et al. 1987b, Driemeier et al. 1991, Barros et al. 1992, 2007, Karam et al. 2004), *S. madagascariensis* (Cruz et al. 2010), *S. oxyphyllus*, *S. cisplatinus*, *S. leptolobus*, *S. heterotrichus*, *S. seloi*, *S. tweediei* (Méndez 1993). In the State of Santa Catarina, although several *Senecio* species occur, only *Senecio brasiliensis* poisoning outbreaks have been reported.

Experimentally, broilers are sensitive to pyrrolizidine alkaloids (PAs) present in plants of the genus *Senecio* and develop lesions similar to those found in cattle (Cheeke & Pierson-Goeger 1983, Mendéz et al. 1987, 1990, Huan et al. 1992), and for being of low economic value, they are used as experimental model.

Due to the high availability of *Senecio vernonioides*, *S. conyzaefolius* and *S. paulensis* in the Highland and Midwestern regions of the State of Santa Catarina, and due to the lack of reports of poisoning in animals with these species, this study aims to verify the effect of the plant on broilers and its toxic potential for cattle.

MATERIALS AND METHODS

During the months from June to August 2014, *Senecio vernonioides* (Água Doce/SC), *S. conyzaefolius* (Lages/SC) and *S. paulensis* green leaves (Matos Costa/SC) were collected. After collection, leaves were dried in the shade and later crushed in a grinder. For each *Senecio* species, 100 grams were separated and dried separately for weight loss evaluation after drying. Values corresponding to the weight

Table 1. *Senecio* species, group and doses corresponding to green plant and dry plant respectively

Plant used	Group	Dose Green plant (g/kg)	Dose corresponding to dry plant (g/kg)
<i>Senecio vernonioides</i>	1	5 s.d.	2 s.d.
	2	20 s.d.	8 s.d.
	3	1/ 20 days	0.4/20 days
<i>Senecio conyzaefolius</i>	1	5 s.d.	1.75 s.d.
	2	20 s.d.	7 s.d.
	3	1/ 20 days	0.35/20 days
<i>Senecio paulensis</i>	1	5 s.d.	1.75 s.d.
	2	20 s.d.	7 s.d.
	3	1/ 20 days	0.35/20 days

s.d. = Single dose.

loss of each species are described in Table 1. The doses used in the experiment correspond to the green plant.

For the experiment, 110 one-day-old chicks of the Coob lineage were housed in experimental aviary located in the Poultry Sector of the Agroveterinary Sciences Center of the State University of Santa Catarina (CAV-UDESC). Birds were kept in boxes where they received feed and water ad libitum. For the *S. vernonioides* and *S. conyzaefolius* species, groups of 35 birds were subdivided into lots of 10 chickens for single doses of 5g/kg/LW and 20g/kg/LW and of 15 birds for the dose of 1g/kg/LW for twenty days. For the *S. paulensis* species, 10 birds were used for each dose evaluated. In total, 100 chickens received *Senecio* in the feed plus control group with 10 birds.

From the 12 days of age, the groups of birds received the different types of *Senecio* mixed in the feed, except for the Control group that received only feed. The formation of groups, as well as the *Senecio* species tested and their respective doses are shown in Table 1.

During the experiment, birds were daily inspected and behavior and feed consumption were evaluated. Weekly, birds from Groups 1, 2 and Control were weighted. For Group 3, weighing was performed twice a week, during the first 20 days to readjust the daily *Senecio* dose to the increasing weight of birds.

For euthanasia, the cervical dislocation method, approved by Normative 1000 of the Federal Veterinary Medicine Council (CFMV) and by the ethics committee of animal experimentation of CAV-UDESC (Protocol 01.07.14) was used. All birds were necropsied to observe lesions and central nervous system, heart, kidney and liver samples were collected, which were fixed in 10% buffered formalin, routinely processed and stained with hematoxylin and eosin (HE). Selected sections were stained by Masson's trichomic histochemistry technique for the detection of fibrous connective tissue. Material processing and histological analysis were performed at the Laboratory of Animal Pathology of CAV/UDESC.

Samples of collected plants were sent to the Department of Botany of the State University of Santa Catarina for identification and classification. Dry plants were sent to USDA, ARS, Poisonous Plant Research Laboratory, Logan, Utah, USA, for analysis and quantification of pyrrolizidine alkaloid doses.

RESULTS

Analysis of APs of *Senecio* spp. samples used in this study revealed the presence of toxic alkaloids dehydrate pyrrolizidine ester (DHPA) and their quantification was performed with the dry weight of samples. *Senecio vernonioides* presented dose of 19,599µg/g, *S. conyzaefolius* 2,500µg/g and *S. paulensis*

157µg/g. For the three *Senecio* species tested, no clinical changes were observed.

For each group formed, five chickens were submitted to necropsy at 30 days and five at 60 days after the onset of plant consumption, five chickens that consumed *Senecio vernonioides* and *S. conyzaefolius* at the dose of 1g/kg for 20 days were also necropsied at 90 days after the start of the experiment. Necropsy showed lesions only in *S. vernonioides* poisoning, which are described in Table 2. The main macroscopic alterations occurred in the liver and were characterized by

decreased size, firm consistency and whitish striations and/or reddish spots on the surface (Fig.1).

Microscopically, hepatic lesions were observed that varied from mild to severe in birds that received *S. vernonioides* (Table 3) and were demonstrated in Figure 2 and mild or absent in birds that received *S. conyzaefolius* (Table 4). In birds that received *S. paulensis*, no significant histological lesions were observed.

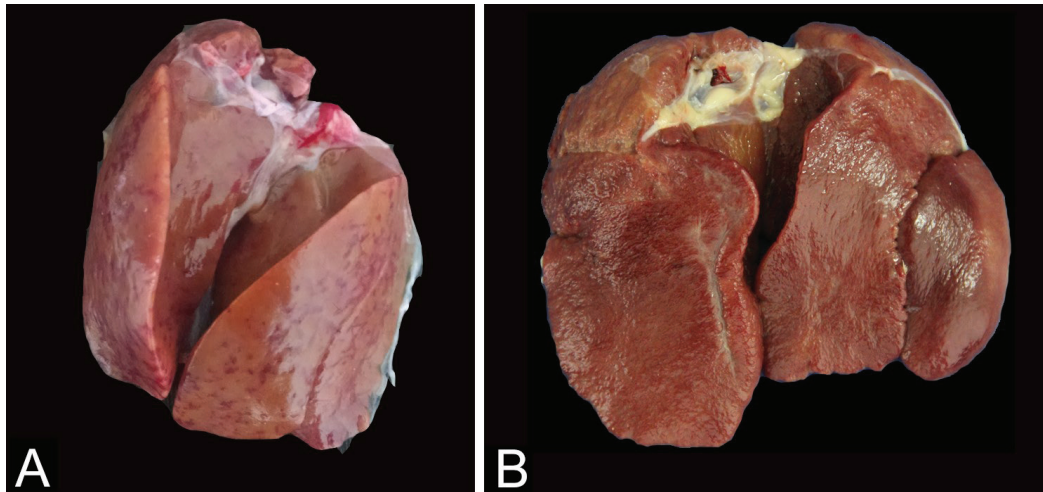


Fig.1. Livers of chicken from Group 3 (1g/kg for 20 days) necropsied at (A) 60 days and (B) 90 days after onset of the consumption of *Senecio vernonioides*. (A) Liver reduced in size and with reddish spots and (B) with whitish striations.

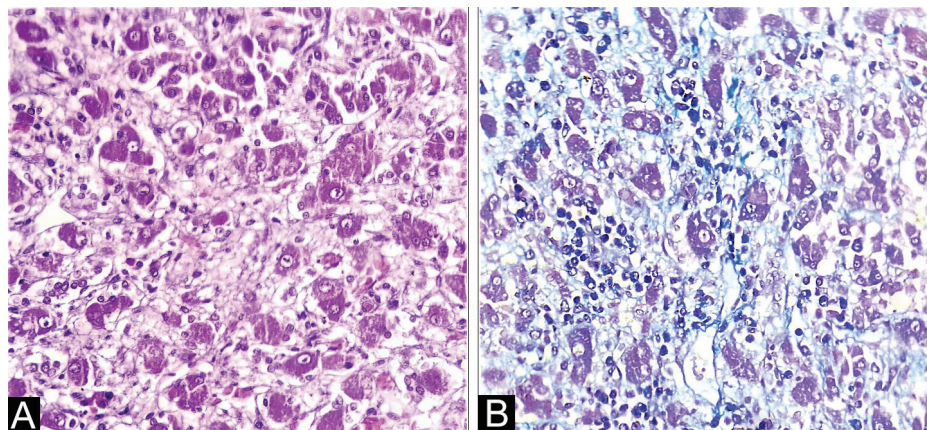


Fig.2. Histology of the liver of one of chickens from Group 3 (1g/kg for 20 days) necropsied 90 days after the onset of consumption of *Senecio vernonioides*. (A) Megalocytosis and fibrosis, which dissect the hepatocyte cords. HE, obj.40x. (B) Fibrous connective tissue. Masson's trichomic histochemistry staining, obj.40x.

Table 2. Macroscopic lesions found in chickens that received *Senecio vernonioides* at dose of 1g/kg for 20 days and sacrificed at 30, 60 and 90 days after consumption

Lesion	30 days	60 days	90 days
Ascite	1/5	1/5	1/5
Hydropericardium	1/5	3/5	3/5
Gallbladder with increased volume	-	1/5	-
Hepatic atrophy	2/5	3/5	5/5
Liver with evident lobular pattern	1/5	2/5	5/5
Yellowish liver	1/5	2/5	0/5

Table 3. Microscopic lesions observed in birds consuming *Senecio vernonioides* at single doses of 5g/kg (Group 1), 20g/kg (Group 2) and continuous dose of 1g/kg for 20 days (Group 3) at 30, 60 and 90 days after onset of plant consumption

Lesion	Group 1		Group 2		Group 3		
	30 days	60 days	30 days	60 days	30 days	60 days	90 days
Hepatocyte swelling	+	+	+	-	++	++	+++
Megalocytosis	-	-	-	-	+	++	++
Fibrosis	-	+	-	-	+	+	++
Vacuolation hepatocytes	-	-	-	-	-	+	+
Biliary proliferation	-	-	-	-	-	+	+

+ Mild, ++ moderate, +++ severe, - absent.

Table 4. Microscopic lesions observed in birds consuming *Senecio conyzaeifolius* at single doses of 5g/kg (Group 1), 20g/kg (Group 2) and continuous dose of 1g/kg for 20 days (Group 3) at 30, 60 and 90 days after onset of plant consumption

Lesion	Group 1		Group 2		Group 3		
	30 days	60 days	30 days	60 days	30 days	60 days	90 days
Hepatocyte swelling	+	+	+	+	+	+	+
Megalocytosis	+	+	+	+	+	+	+
Fibrosis	-	-	-	-	-	+	+
Vacuolation hepatocytes	+	+	+	+	+	+	+
Biliary proliferation	-	-	-	-	-	-	-

DISCUSSION

Macroscopic lesions characterized by ascites, hydropericardium, yellowish liver, firm consistency, evident lobular pattern and decreased size were observed at necropsy of chickens that received *Senecio vernonioides* at dose of 1g/kg for 20 days and are compatible with those reported by Méndez et al. (1990) in experimental poisoning with *S. brasiliensis*, *Senecio heterotrichius* and *S. cisplatinus*. In addition to birds, these lesions are also described in cattle (Tokarnia & Döbereiner 1984, Méndez et al. 1987, Barros et al. 1989), horses (Gava & Barros 1997, Pilati & Barros 2007) and sheep (Ilha et al. 2001, Schild et al. 2007, Grecco et al. 2011). The occurrence of lesions in other organs such as CNS (central nervous system) in cattle (Tokarnia & Döbereiner 1984, Méndez et al. 1987, 1990, Barros et al. 1987a), horses (Gava & Barros 1997, Pilati & Barros 2007) and sheep (Ilha et al. 2001, Grecco et al. 2011) was not observed in this study. These data are in agreement with Cheeke & Pierson-Goeger (1983) and Méndez et al. (1990).

S. conyzaeifolius and *S. paulensis* species did not develop macroscopic lesions at the dose and consumption periods evaluated. This may be related to the time chickens consumed the plant and the PA concentration. In experiments performed by Méndez et al. (1990) with other *Senecio* species, birds received the plant for a longer period of time (60 consecutive days) and according to Tokarnia & Döbereiner (1984), lesions caused by PAs are progressive. Another factor involved could be the variation in the number of PAs present in these species when compared to *S. vernonioides*, which presented DPHA dose of 19,599µg/g, with *S. conyzaeifolius* presenting 2,500µg/g and *S. paulensis* 157µg/g. Stigger et al. (2014) observed macroscopic lesions in bovines naturally poisoned by *S. madagascariensis* with PA doses of 500µg/g, lower than that found in *S. conyzaeifolius*. The appearance of these lesions could be related to the period and amount of plant consumed, because in that case, animals were food restricted.

Lesions were also experimentally observed in birds and cattle that consumed different *Senecio* species with PA doses ranging from 50 to 3,100µg/g (Méndez et al. 1990). A small

individual variation in the intensity of lesions within the same *Senecio* species evaluated was observed. This demonstrates the individual susceptibility to PAs (Hooper 1978). The administration of single and high doses is responsible for causing acute manifestations of the disease, with clinical signs and death of cattle (Tokarnia & Döbereiner 1984, Méndez et al. 1987, Riet-Correa et al. 2007). In this experiment, it was not possible to observe this result. A similar description is made by Tokarnia et al. (1990), with single *S. desiderabilis* doses of 20 and 40g/kg also failed to reproduce the acute disease, but with smaller and continuous doses, two cattle died. However, acute manifestation was experimentally demonstrated by Tokarnia & Döbereiner (1984) with a single *S. brasiliensis* dose of 20g/kg to a bovine that developed clinical symptoms and death 20 days after ingestion. Pilati & Barros (2007) also provided a single *S. brasiliensis* dose of 15g/kg to an equine that demonstrated neurological symptoms. Grecco et al. (2012) provided *S. brasiliensis* at a single dose of 60g/kg to sheep that showed no clinical signs or microscopic changes, demonstrating the resistance of this species to the single dose of the plant.

Regarding the dosages tested, the most evident lesions were at dose of 1g/kg for 20 consecutive days. Small doses over an extended period produced more significant lesions than high and single doses. This result corroborates Tokarnia & Döbereiner (1984) and Riet-Correa et al. (2007), who described lesions caused by PAs as progressive and irreversible. This progressive effect described by the authors may explain the lack of manifestations of clinical signs and death. However, the lesions found indicate liver function impairment, suggesting that if these animals remained alive, they could develop more serious lesions with the appearance of clinical signs and mortality. Histological lesions ranged from mild to moderate megalocytosis, fibrosis, biliary proliferation and hepatocyte swelling, and lesions were most evident in necropsied birds at 60 and 90 days after plant consumption, corroborating Tokarnia & Döbereiner (1984) and Riet Correa et al. (2007). Méndez et al. (1990) describe, megalocytosis lesions,

disorganization of the hepatic parenchyma, proliferation of biliary epithelium, necrosis for birds that consumed the plant for a period of 60 days and proliferation of connective tissue into the parenchyma from Glisson's capsule for birds experimentally poisoned by *S. heterotrichius*.

Regarding the single doses administered, the dose of 20g/kg was more toxic than the dose of 5g/kg, but this difference was not significant, as well as variations in lesion intensity among *Senecio* species. However, lesions were more significant in the necropsied chickens 60 days after plant consumption, which again proves the relationship between the period after plant consumption and the development of lesions (Tokarnia & Döbereiner 1984, Riet-Correa et al. 2007).

S. vernonioides and *S. conyzaeifolius* species are possible sources of poisoning for cattle, as they have demonstrated toxic effect on broilers and are present in the in the Highland and Midwestern regions of the State of Santa Catarina.

CONCLUSIONS

Senecio vernonioides and *S. conyzaeifolius* were toxic to chickens and morphological lesions varied according to the dose tested and PA concentration.

Senecio paulensis did not demonstrate toxicity to broilers at the doses tested.

REFERENCES

- Barros C.S.L., Metzendorf L.L. & Peixoto P.V. 1987a. Intoxicação por *Senecio* spp. em bovinos. Pesq. Vet. Bras. 7(4):101-107.
- Barros C.S.L., Metzendorf L.L. & Peixoto P.V. 1987b. Ocorrência de surtos de intoxicação por *Senecio* spp. (Compositae) em bovinos no Rio Grande do Sul. Pesq. Vet. Bras. 7(1):101-107.
- Barros C.S.L., Metzendorf L.L., Santos M.N., Barros S.S. & Peixoto P.V. 1989. Intoxicação experimental por *Senecio brasiliensis* (compositae) em ovinos. Pesq. Vet. Bras. 9(3/4):55-67.
- Barros C.S.L., Driemeier D., Pilati C., Barros S.S. & Castilhos L.M. 1992. *Senecio* spp. poisoning in cattle in southern Brazil. Vet. Human Toxicol. 34(3):241-246. <PMid:1609498>
- Barros C.S.L., Castilhos L.M.L., Rissi D.R., Kommers G.D. & Rech R.R. 2007. Biópsia hepática no diagnóstico da intoxicação por *Senecio brasiliensis* (Asteraceae) em bovinos. Pesq. Vet. Bras. 27(1):53-60. <http://dx.doi.org/10.1590/S0100-736X2007000100010>
- Cheeke P.R. & Pierson-Goeger M.L. 1983. Comparative toxicity and metabolism of pyrrolizidine alkaloids in various laboratory animals and avian species. Toxicol. Lett. 18(3):343-349. <http://dx.doi.org/10.1016/0378-4274(83)90116-9> <PMid:6665808>
- Cruz C.E.F., Karam F.C., Dalto A.C., Pavarini S.P., Bandarra P.M. & Driemeier D. 2010. Fireweed (*Senecio madagascariensis*) poisoning in cattle. Pesq. Vet. Bras. 30(1):10-12. <http://dx.doi.org/10.1590/S0100-736X2010000100002>
- Driemeier D., Barros C.S.L. & Pilati C. 1991. Seneciose em bovinos. Hora Vet. 10:23-30.
- Gava A. & Barros C.S.L. 1997. *Senecio* spp. poisoning in horses in southern Brazil. Pesq. Vet. Bras. 17(1):36-40. <http://dx.doi.org/10.1590/S0100-736X1997000100006>
- Grecco F.B., Estima-Silva P., Marcolongo-Pereira C., Soares M.P., Collares G. & Schild A.L. 2011. Seneciose crônica em ovinos no sul do Rio Grande do Sul. Pesq. Vet. Bras. 31(4):326-330. <http://dx.doi.org/10.1590/S0100-736X2011000400009>
- Grecco F.B., Estima-Silva P., Marcolongo-Pereira C., Soares M.P., Raffi M.B., Sallis E.S.V. & Schild A.L. 2012. Intoxicação experimental aguda por *Senecio brasiliensis* em ovinos e indução de resistência à intoxicação. Pesq. Vet. Bras. 32(9):912-916. <http://dx.doi.org/10.1590/S0100-736X2012000900015>
- Hooper P.T. 1978. Pyrrolizidine alkaloid poisoning-pathology with particular reference to differences in animal and plant species, p.162-176. In: Keeler R.F., Van Kampen K.R. & James L.F. (Eds), Effects of Poisonous Plants on Livestock. Academic Press, New York. <http://dx.doi.org/10.1016/B978-0-12-403250-7.50022-4>
- Huan J., Cheeke P.R., Lowry R.R., Nakae H.S., Snyder S.P. & Whanger P.D. 1992. Dietary pyrrolizidine (*Senecio*) alkaloids and tissue distribution of copper and vitamin A in broiler chickens. Toxicol. Letters 62(2/3):139-153. <http://dx.doi.org/10.1016/0378-4274(92)90017-E> <PMid:1412500>
- Ilha M.R., Loretto A.P., Barros S.S. & Barros C.L.S. 2001. Intoxicação espontânea por *Senecio brasiliensis* (Asteraceae) em ovinos no Rio Grande do Sul. Pesq. Vet. Bras. 21(3):123-138. <http://dx.doi.org/10.1590/S0100-736X2001000300005>
- Karam F.S.C., Soares M.P., Haraguchi M., Riet-Correa F., Méndez M.C. & Jarenkow J.A. 2004. Aspectos epidemiológicos da seneciose na região sul do Rio Grande do Sul. Pesq. Vet. Bras. 24(4):191-198. <http://dx.doi.org/10.1590/S0100-736X2004000400004>
- Méndez M.C. 1993. Intoxicação por *Senecio* spp., p.43-57. In: Riet-Correa F., Méndez M.C. & Schild A.L. (Eds), Intoxicações por Plantas e Micotoxícoses em Animais Domésticos. Agropecuaria Hemisferio Sur, Montevideo.
- Méndez M.C., Riet-Correa F. & Schild A.L. 1987. Intoxicação por *Senecio* spp. (Compositae) em bovinos no Rio Grande do Sul. Pesq. Vet. Bras. 7(2):51-56.
- Méndez M.C., Riet-Correa F., Schild A.L. & Mart W. 1990. Intoxicação experimental por cinco espécies de *Senecio* em bovinos e aves. Pesq. Vet. Bras. 10(3/4):63-69.
- Pessoa C.R.M., Medeiros R.M.T. & Riet-Correa F. 2013. Importância econômica, epidemiologia e controle das intoxicações por plantas no Brasil. Pesq. Vet. Bras. 33(6):752-758. <http://dx.doi.org/10.1590/S0100-736X2013000600011>
- Pilati C. & Barros C.S.L. 2007. Intoxicação experimental por *Senecio brasiliensis* (Compositae) em equinos. Pesq. Vet. Bras. 27(7):287-296. <http://dx.doi.org/10.1590/S0100-736X2007000700006>
- Riet-Correa F. & Medeiros R.M.T. 2001. Intoxicação por plantas em ruminantes no Brasil e no Uruguai: importância econômica, controle e riscos para a saúde pública. Pesq. Vet. Bras. 21(1):38-42. <http://dx.doi.org/10.1590/S0100-736X2001000100008>
- Riet-Correa F., Méndez M.C. & Schild A.L. 1993. Intoxicações por Plantas e Micotoxícoses em Animais Domésticos. Hemisfério Sur, Montevideo. 340p.
- Riet-Correa F., Schild A.L., Lemos R.A.A. & Borges J.R. 2007. Doenças de Ruminantes e Equinos. 3ª ed. Palotti, Santa Maria, p.106-112.
- Schild A.L., Ferreira J.L., Ladeira S.R.L., Soares M.P., Grecco F.B. & Guim T.N. 2007. Doenças diagnosticadas pelo Laboratório regional de Diagnóstico no ano 2006. Boletim do Laboratório Regional de Diagnóstico, Ed. Universitária, Pelotas, RS. 56p.
- Stigger A.L., Estima-Silva P., Fiss L., Coelho A.C.B., Santos B.L., Gardner D.R., Marcolongo-Pereira C. & Schild A.L. 2014. *Senecio madagascariensis* Poir. (Asteraceae): uma nova causa de seneciose em bovinos no Sul do Rio Grande do Sul. Pesq. Vet. Bras. 34(9):851-855. <http://dx.doi.org/10.1590/S0100-736X2014000900008>
- Tokarnia C.H. & Döbereiner J. 1984. Intoxicação experimental por *Senecio brasiliensis* (Compositae) em bovinos. Pesq. Vet. Bras. 4:39-65.
- Tokarnia C.H., Gava A., Peixoto P.V., Stolf L., Consorte L.B. & Döbereiner J. 1990. Intoxicação experimental por *Senecio desiderabilis* (Compositae) em bovinos. Pesq. Vet. Bras. 10:35-42.