

Evaluation of estrogen receptor expression in low-grade and high-grade astrocytomas

 Cléciton Braga Tavares^{1,2}

Francisca das Chagas Sheyla Gomes-Braga¹

Emerson Brandão Sousa²

Umbelina Soares Borges¹

Carla Solange Escórcio-Dourado³

João Paulo da Silva-Sampaio¹

Benedito Borges da Silva^{1,3}

1. Federal University of Piauí, Teresina, PI, Brasil

2. Department of Oncology, Sao Marcos Hospital, Teresina, PI, Brasil

3. Northeast Network of Biotechnology (RENORBIO), Teresina, PI, Brasil

<http://dx.doi.org/10.1590/1806-9282.64.12.1129>

SUMMARY

OBJECTIVE: This study aims to compare estrogen receptor expression between low and high-grade astrocytomas.

METHOD: A study using paraffin blocks of glial tumors from the Anatomy Pathology archives of São Marcos Hospital was carried out and began after approval by the Review Board of the Federal University of Piauí. Specimens were histochemically marked with an anti-ER alpha antibody. Brown-stained nuclei were considered positive, regardless of reaction intensity. Data were statistically analyzed using the Mann-Whitney test and Spearman's correlation. Statistical significance was established at $p < 0.05$.

RESULTS: The mean percentage of nuclei stained with anti-ER alpha in low- and high-grade astrocytomas was 0.04 and zero, respectively, while Spearman's correlation showed a strong negative association between low and high-grade tumors ($p < 0.001$) and ($r = -0.67$), respectively.

CONCLUSION: In the current study, estrogen receptor expression was positive only in low-grade astrocytomas and nil in high-grade astrocytomas, showing that ER expression declines with the grade of tumor malignancy.

KEYWORDS: Astrocytoma. Glioma. Glioblastoma. Estrogen receptor beta. Estrogen receptor alpha.

INTRODUCTION

Gliomas are the most common primary tumors of the central nervous system. These tumors have four histologic subtypes, and astrocytoma is the most prevalent type¹. According to the World Health Organization (WHO), astrocytomas may be classified as grades 1 and 2 (low-grade or benign) and grades 3 and 4 (high-grade or malignant). High-grade astrocytomas are highly aggressive tumors. Despite adequate

surgical resection, chemotherapy, and radiotherapy, high-grade tumors have a poor prognosis¹⁻⁴.

Nevertheless, high-grade gliomas may have a less poor prognosis that seems to be dependent on the understanding and manipulation of pathways that regulate aberrant tumor growth. There is a need for further diagnostic methods and new prognostic biomarkers⁵⁻⁷.

DATE OF SUBMISSION: 04-Mar-2018

DATE OF ACCEPTANCE: 03-Apr-2018

CORRESPONDING AUTHOR: Cléciton Braga Tavares

Rua Acre, 251, Teresina, PI, Brasil – CEP 64001-625

Phone: +55 86 99925-9772

E-mail: bragatavares@yahoo.com.br

Estrogen exerts essential effects on the reproductive and gastrointestinal tracts, mammary glands, skeleton, immune system and even on the central nervous system. The majority of its effects are mainly mediated by its interaction with estrogen receptors alpha and beta (ER α and ER β)^{8,9}. However, although the primary mechanism of action of estrogen occurs through the interaction with the estrogen receptor, evidence from an *in vitro* study showed that substances with anti-estrogenic activity, such as tamoxifen, reduced cell proliferation through protein kinase C (PKC)^{6,8-10}.

The presence of estrogen receptors alpha and beta in gliomas is related to tumor aggressiveness, according to some authors^{8,9}. These receptors are present in healthy brain tissue, and its expression decreases significantly with increasing histologic malignancy¹¹. In contrast, a study showed an inverse result regarding ER beta expression. The study described that ER beta expression was higher in high-grade malignant neoplasms than in normal tissues and benign gliomas¹². Therefore, the existing controversy and paucity of studies comparing estrogen receptor expression among benign and malignant astrocytomas, motivated the current study design.

METHODS

Study Design

This study used paraffin blocks of gliomas obtained from Pathology archives of São Marcos Hospital, Teresina, Brazil and began after approval by the Review Board of the Federal University of Piauí. Only astrocytomas were selected that were not submitted to any treatment before the primary surgery and stored for a maximum of five years (histopathological exams were collected between June 2012 and June 2017).

Forty cases were histologically divided into two groups (low-grade and high-grade astrocytomas). Each group had 20 cases and were chosen in a simple random manner among tumors that met the inclusion criteria.

Immunohistochemical Method

Samples of tumor tissue were fixed in buffered formalin for a period of 12-24 h and cut into 3- μ m-thick sections. Tissue sections were then processed and stained with hematoxylin and eosin. Slides

were deparaffinized with xylene for 15 minutes at a temperature of 60°C, dehydrated with graded ethanol concentration 100, 95, 80 and 70% for 30 seconds each and rinsed with distilled water. For the performance of antigen retrieval, the slides were immersed in citrate buffer solution and heated in a microwave for 15 minutes at maximum power. Then, the slides were treated with 3% hydrogen peroxide in buffer solution for 10 minutes in each immersion. Slides were washed with distilled water and phosphate buffer saline solution. The slides were then placed in a BenchMark Ultra staining instrument (Ventana Medical Systems®), which used NCL-ER-6F11 monoclonal antibody (Novocastra Laboratories Ltd.) as immunohistochemical markers for estrogen receptors. Cells that displayed brown-stained nuclei, whether intensely brown or not, were considered positive.

Quantitative Method

A microscope (Nikon Eclipse E-400, optical microscope, Tokyo, Japan) attached to a color video camera (Samsung digital camera CHC-370N, Seoul, Korea) was used to capture an image and transmit it to a computer equipped with the Imagemlab software, version 2.3, developed by Softium Informática Ltda. (São Paulo, Brazil) for image analysis.

For estrogen receptor expression, 600 stained or non-stained cells were counted, using a magnification of 400x, starting with areas that had a higher expression of marked cells. In each slide, the percentage of cells was obtained from the ratio between the number of cells with stained nuclei and the total number of cells, multiplied by 100.

Statistical Analysis

The results were stored in Excel spreadsheets, and statistical analysis was performed by the SPSS 20.0 program. Data obtained were previously submitted to the Kolmogorov-Smirnov normality test. The mean percentage of nuclei stained for estrogen receptors between low-grade and high-grade gliomas was compared using the Mann-Whitney test. The significance level was established at $p < 0.05$. The correlation between the percentage of nuclei stained for estrogen receptors and grade of astrocytic malignancy, according to WHO criteria, was performed by Spearman correlation coefficient (r). The level of significance was set at $p < 0.05$.

RESULTS

Light microscopy showed a greater concentration of stained nuclei for estrogen receptors in the low-grade astrocytomas group compared to the group of high-grade astrocytomas (Fig. 1). The mean percentage of nuclei stained for estrogen receptors was 0.04 and zero in low-grade and high-grade astrocytomas, respectively (Table 1 and Fig. 2), while there was a strong negative correlation between high-grade tumors and estrogen nuclear receptor expression ($r=-0.67$) that was statistically significant ($p<0.01$) (Fig. 3).

DISCUSSION

Estrogen is a steroid hormone that exerts essential effects on various organs and tissues, including the central nervous system. It acts mainly by interaction with estrogen receptors. Estrogen may even influence the development and control of the growth of brain tumors, such as astrocytomas^{4,8,13}.

Estrogen receptors are intracellular proteins with two different subtypes (alpha and beta). Despite being produced by separate genes, these highly homologous receptors are located in chromosome 6q25.1 and 14q22-24, respectively. Although these two receptors share 97% homology in their DNA binding

domains, they exhibit contradictory biological functions. ER α gene is generally believed to be an oncogene and promotes cell proliferation, whereas ER β gene is anti-proliferative and acts as a putative tumor suppressor^{9,14}. It is very well-known that ER exists and has a function in various tissues and neoplasms. However, the pathophysiology of ER is not fully understood, since few studies have shown its expression in breast, ovarian, prostate, colon cancers and astrocytic tumors¹⁴.

The current study showed estrogen receptor alpha expression only in low-grade astrocytomas. In contrast, the majority of studies demonstrate the presence of estrogen receptor expression in low-grade and high-grade astrocytomas, although there is a lower proportion in high-grade astrocytoma^{8,9,11,15}. Although nuclear ER expression was evaluated, the result of this study was similar to findings by Fujimoto et al.¹³ which showed the presence of cytosolic estrogen receptor only in benign astrocytomas.

Despite few studies in the literature concerning ER expression in brain tissue, it is known that ER is present in hippocampal neurons, pituitary tumors, glial cells, and astrocytomas. ER expression declines with increasing malignancy, as observed in the findings of the current study. However, its specific func-

FIGURE 1: PHOTOMICROGRAPH OF THE HISTOLOGIC SECTION OF GLIOMAS, SHOWING SOME NUCLEI STAINED BROWN FOR ESTROGEN RECEPTORS IN LOW-GRADE ASTROCYTOMAS (A) AND ABSENCE OF NUCLEI STAINED IN HIGH-GRADE ASTROCYTOMAS (B).

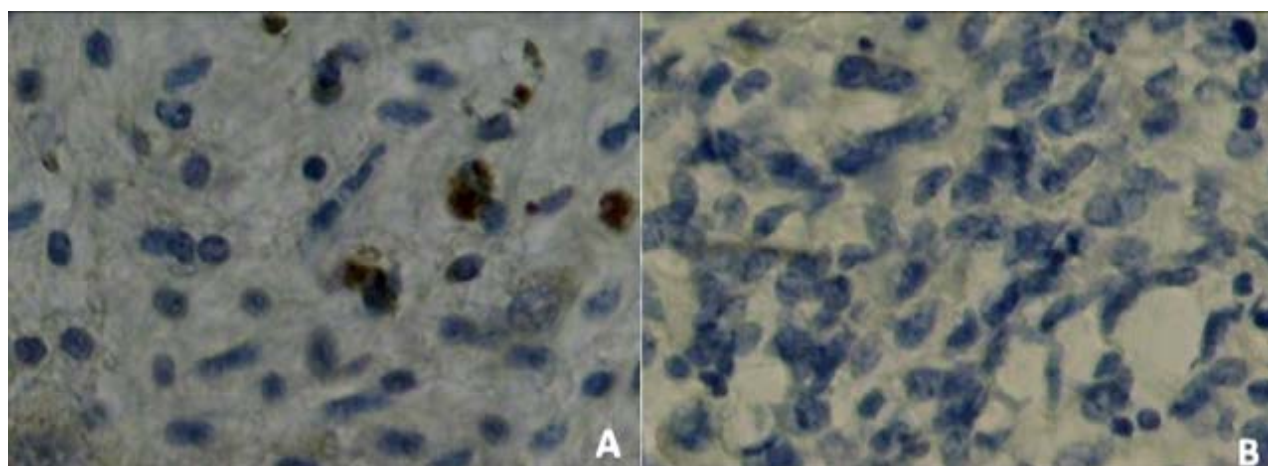


TABLE 1: MEAN PERCENTAGE OF STAINED NUCLEI OF ESTROGEN RECEPTOR PER GROUP.

Groups	N	Mean	SE Mean	Minimum	Maximum	Median
High Grade	20	0	0	0	0	0
Low Grade	20	0.04*	0.0536	0	0.1894	0.0164

* $p<0.001$

FIGURE 2: MEAN PERCENTAGE OF NUCLEI STAINED WITH ESTROGEN RECEPTORS IN HIGH-GRADE AND LOW-GRADE GLIOMAS.

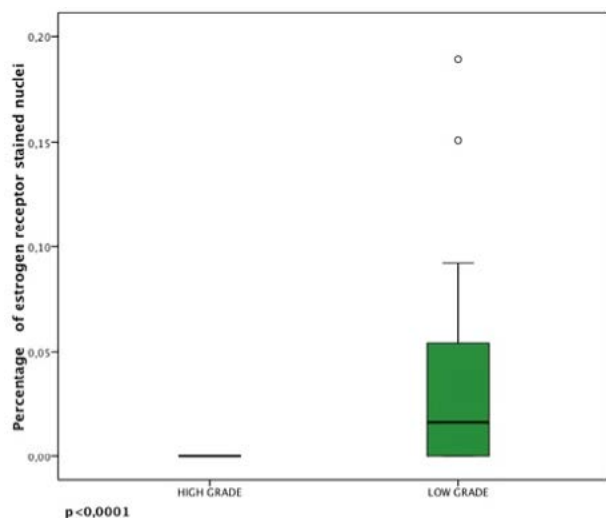
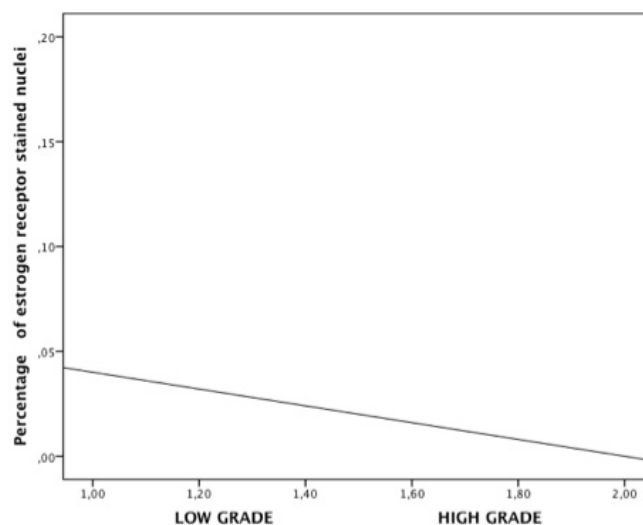


FIGURE 3: DISPERSION GRAPH BETWEEN THE EXPRESSION OF ESTROGEN RECEPTORS AND GRADE OF TUMOR MALIGNANCY IN ASTROCYTOMAS.



tion in the pathogenesis, progression, and prognosis of these neoplasms remains unknown^{8,9,16}.

A negative correlation was shown between ER expression and grade of astrocytoma malignancy, which is in agreement with the literature. ER is mainly expressed in normal astrocytic cells and low-grade gliomas, promoting neuroprotective role^{8,9,11,16-18}.

Estrogen receptors may also be used as prognostic biomarkers since a positive correlation between ER α and survival time of glioma patients has been shown⁸. Nevertheless, regression models, using the Kaplan-Meier curve have demonstrated a better prognosis and longer survival in patients with ER β positive tumors^{12,17}.

Therefore, findings in the current study showed that estrogen receptor expression was positive only in low-grade and zero astrocytomas in high-grade as-

trocytomas, consistent with the benign glial tumor marker. However, due to the limitations of our work such as the number of paraffin blocks used and the non-assessment of estrogen receptor subtypes, further research involving a larger sample size and with immunohistochemical markers for ER α and ER β are required.

CONCLUSIONS

In the current study, estrogen receptor expression was positive only in low-grade astrocytomas and nil in high-grade astrocytomas, showing that expression declines with increasing grade of tumor malignancy.

Conflict of interest statement

There is no conflict of interest of any of the authors with this work.

RESUMO

OBJETIVO: O objetivo deste estudo é comparar a expressão do receptor de estrogênio entre astrocitomas de baixo e alto grau.

MÉTODO: Foi realizado um estudo usando blocos de parafina de tumores gliais dos arquivos de Anatomia Patológica do Hospital São Marcos e iniciado após aprovação pelo Comitê de Ética da Universidade Federal do Piauí. Os espécimes foram marcados histoquimicamente com anticorpo anti-ER alfa. Os núcleos corados em marrom foram considerados positivos, independentemente da intensidade da reação. Os dados foram analisados estatisticamente utilizando o teste de Mann-Whitney e a correlação de Spearman. A significância estatística foi estabelecida em $p < 0,05$.

RESULTADOS: A porcentagem média de núcleos corados com anti-ER alfa em astrocitomas de baixo e alto grau foi de 0,04 e zero, respectivamente, enquanto a correlação de Spearman mostrou uma forte correlação negativa entre tumores de baixa e alta qualidade ($p < 0,001$) e ($r = -0,67$), respectivamente.

CONCLUSÕES: No presente estudo, a expressão do receptor de estrogênio foi positiva apenas em astrocitomas de baixo grau e nula em astrocitomas de alto grau, mostrando que a expressão de ER diminui com o grau de malignidade tumoral.

PALAVRAS-CHAVE: Astrocitoma. Glioma. Glioblastoma. Receptor de estrogênio. Receptor alfa de estrogênio.

REFERENCES

- Pollack IF, Randall MS, Kristofik MP, Kelly RH, Selker RG, Vertosick FT Jr. Effect of tamoxifen on DNA synthesis and proliferation of human malignant glioma lines in vitro. *Cancer Res.* 1990;50(22):7134-8.
- Uematsu M, Ohsawa I, Aokage T, Nishimaki K, Matsumoto K, Takahashi H, et al. Prognostic significance of the immunohistochemical index of survivin in glioma: a comparative study with the MIB-1 index. *J Neurooncol.* 2005;72(3):231-8.
- Tang P, Roldan G, Brasher PM, Fulton D, Roa W, Murtha A, et al. A phase II study of carboplatin and chronic high-dose tamoxifen in patients with recurrent malignant glioma. *J Neurooncol.* 2006;78(3):311-6.
- Patel S, DiBiase S, Meisenberg B, Flannery T, Patel A, Dhople A. Phase I clinical trial assessing temozolomide and tamoxifen with concomitant radiotherapy for treatment of high-grade glioma. *Int J Radiat Oncol Biol Phys.* 2012;82(2):739-42.
- Gerdes J, Schwab U, Lemke H, Stein H. Production of a mouse monoclonal antibody reactive with a human nuclear antigen associated with cell proliferation. *Int J Cancer.* 1983;31(1):13-20.
- Hsu DW, Louis DN, Efrid JT, Hedley-White ET. Use of MIB-1 (Ki-67) Immunoreactivity in differentiating grade II and grade III gliomas. *J Neuro-pathol Exp Neurol.* 1994;56(8):857-65.
- Johannessen AL, Torp SH. The clinical value of Ki-67/MIB-1 labeling index in human astrocytomas. *Pathol Oncol Res.* 2006;12(3):143-7.
- Batistatou A, Stefanou D, Goussia A, Arkoumani E, Papavassiliou AG, Agnantis NJ. Estrogen receptor beta (ERbeta) is expressed in brain astrocytic tumors and declines with dedifferentiation of the neoplasm. *J Cancer Res Clin Oncol.* 2004;130(7):405-10.
- Batistatou A, Kyzas PA, Goussia A, Arkoumani E, Voulgaris S, Polyzoidis K, et al. Estrogen receptor beta (ERβ) protein expression correlates with BAG-1 and prognosis in brain glial tumours. *J Neuro-Oncol.* 2006;77(1):17-23.
- Robins HI, Won M, Seiferheld WF, Schultz CJ, Choucair AK, Brachman DG, et al. Phase 2 trial of radiation plus high-dose tamoxifen for glioblastoma multiforme: RTOG protocol BR-0021. *Neuro Oncol.* 2006;8(1):47-52.
- Liu C, Zhang Y, Zhang K, Bian C, Zhao Y, Zhang J. Expression of estrogen receptors, androgen receptor and steroid receptor coactivator-3, is negatively correlated to the differentiation of astrocytic tumors. *Cancer Epidemiol.* 2014;38(3):291-7.
- Li W, Winters A, Poteet E, Ryou MG, Lin S, Hao S, et al. Involvement of estrogen receptor b5 in the progression of glioma. *Brain Research.* 2013;1503:97-107.
- Fujimoto M, Yoshino E, Hirakawa K, Fujimoto J, Tamaya T. Estrogen receptors in brain tumors. *Clin Neuropharmacol.* 1984;7(4):357-62.
- Cao L, Qu D, Wang H, Zhang S, Jia C, Shi Z, et al. Toosendanin exerts an anti-cancer effect in glioblastoma by inducing estrogen receptor β and p53-mediated apoptosis. *Int J Mol Sci.* 2016;17(11). Pii: E1928.
- Lan YL, Zou S, Wang X, Lou JC, Xing JS, Yu M, et al. Update on the therapeutic significance of estrogen receptor beta in malignant gliomas. *Oncotarget.* 2017;8(46):81686-96.
- Sareddy GR, Nair BC, Gonugunta VK, Zhang QG, Brenner A, Brann DW, et al. Therapeutic significance of estrogen receptor β agonists in gliomas. *Mol Cancer Ther.* 2012;11(5):1174-82.
- Dueñas Jiménez JM, Candanedo Arellano A, Santerre A, Orozco Suárez S, Sandoval Sánchez H, Fera Romero I, et al. Aromatase and estrogen receptor alpha mRNA expression as prognostic biomarkers in patients with astrocytomas. *J Neurooncol.* 2014;119(2):275-84.
- Tavares CB, Gomes-Braga F, Costa-Silva DR, Escórcio-Dourado CS, Borges US, Conde-Junior AM, et al. Expression of estrogen and progesterone receptors in astrocytomas: a literature review. *Clinics.* 2016;71(8):481-6.

