


# Cobalt chromium-Titanium rods versus Titanium-Titanium rods for treatment of adolescent idiopathic scoliosis; which type of rod has better postoperative outcomes?

Mohammad Reza Etemadifar<sup>1</sup>

Ali Andalib<sup>1</sup>

 Abbas Rahimian<sup>2</sup>

Seyed Mohamad Hossein Tabatabaei Nodushan<sup>1</sup>

1. Department of Orthopaedic Surgery, Isfahan University of Medical Sciences, Isfahan, Iran

2. Department of Orthopaedic Surgery, Surgery Spine Fellowship, Isfahan University of Medical Sciences, Isfahan, Iran

<http://dx.doi.org/10.1590/1806-9282.64.12.1085>

## SUMMARY

**OBJECTIVE;** Compare the outcome of spinal deformity correction between Ti-Ti and CrCo-Ti rods for the treatment of spinal Adolescent Idiopathic Scoliosis (AIS) using rods mentioned with all pedicle screws and translation technique.

**METHOD;** 59 patients operated for spinal deformity (Lenke 1 or 2) AIS. The patients were divided into two groups by random allocation using Ti-Ti rods (n = 29) and CrCo-Ti rods (n = 30) and the alone difference among them in the surgical procedure was rod material (Ti-Ti or CrCo-Ti rods) and finally, radiological outcomes were compared preoperatively, postoperatively and at last follow-up for 12 months.

**RESULTS;** Patients' main curve correction after surgical procedure regardless type of rod was  $48.95 \pm 11.04$  (13-75) degree. Success rate of spinal deformity correction following surgical procedure regardless of type of administered rod was  $86.76 \pm 11.30$  percent (62.5-100%). Mean of deformity correction rate was  $91.49 \pm 10.67\%$  using CrCo-Ti rods versus  $81.86 \pm 9.88\%$  using Ti-Ti rods (P-value=0.01). Angle change was  $3.29 \pm 6.60$  for kyphosis angle and  $0.59 \pm 7.76$  for lordosis angle. Rate of main curve correction was not significantly different considering patients' gender (P-value 0.657). Main curve correction success rate was in association with patients' age and type of rod (P-value=0.054,  $r=-1.863$  and P-value=0.001,  $r=8.865$  respectively).

**CONCLUSION;** CrCo-Ti rods have the ability to produce higher correction rates in AIS compared to Ti-Ti rod of the same diameter. CrCo-Ti rods provide significant and stable spinal correction, especially in correction of main curve. This rate was associated with patients' age and type of rod administered but not gender.

**KEYWORDS:** Adolescent. Scoliosis. Chromium Alloys. Titanium. Treatment Outcome.

## INTRODUCTION

Commonly, adolescent idiopathic scoliosis (AIS) is a three-dimensional (3D) spinal deformity with hypokyphosis in sagittal plane and major curve in obligatory rotation (coronal plane) causing various complications<sup>1</sup> as well as in different countries, AIS prevalence is estimated between 0.47-5.2%. Genetic factors, gender and age of onset are major features determining prevalence and curve pattern in patients.<sup>2,3</sup>

The customary treatment of AIS is spinal fusion with instrumentation using rigid rods. In parallel, agents such as, curve magnitude, points of fixation, level instrument selection, curve flexibility, kind of anchor rods used for patients and post-operative care are the main factors affecting the outcome of surgery<sup>4</sup>. Furthermore, correcting and preserving the ability of the rod is one of the most important factor

DATE OF SUBMISSION: 01-Apr-2018

DATE OF ACCEPTANCE: 06-Apr-2018

CORRESPONDING AUTHOR: Abbas Rahimian

Department of Orthopaedic Surgery, Surgery Spine Fellowship, Isfahan University of Medical Sciences, Isfahan, Iran, Tel+00989123093440

E-mail: Abbasrahimianmd@yahoo.com

in choosing the best alloy for this surgery. Titanium Ti6Al4V(Ti), Stainless steel A316L (SS), and CrCoMoC (CrCo) are the most commonly used alloys of this surgery, each of them with different properties such as stiffness, radiologic features, postoperative complications, and effectiveness<sup>5,6</sup>. Ti rods, due to lower risk of infection after surgery and fewer artefacts in radiographic imaging are better than the SS rods previously used. However, Ti rods are more flexible and cannot modify the deformation as much as SS rods. Recently, the CrCo rods used have lower risk of postoperative infection and less artefacts in radiographic imaging than SS rods. Moreover, CrCo rods effectively correct the scoliosis and preserve better correction toward the mentioned alloys<sup>5-7</sup>. Therefore, in this study, we have aimed to compare the outcomes of spinal deformity correction using different alloys of Ti-Ti and CrCo-Ti rods for the treatment of spinal AIS using translation technique.

## METHOD

### Ethical Committee

All procedures performed in studies involving human participants were in accordance with the ethical standards of the institutional and/or national research committee and with the 1964 Helsinki Declaration and its later amendments or comparable ethical standards. The study protocol was approved by the Ethics Committee of Isfahan University of Medical Sciences.

### Design and participants

This randomized clinical trial study was conducted between April 2012 and August 2107 in Alzahra Hospital-Isfahan, Iran. Patients were randomized in

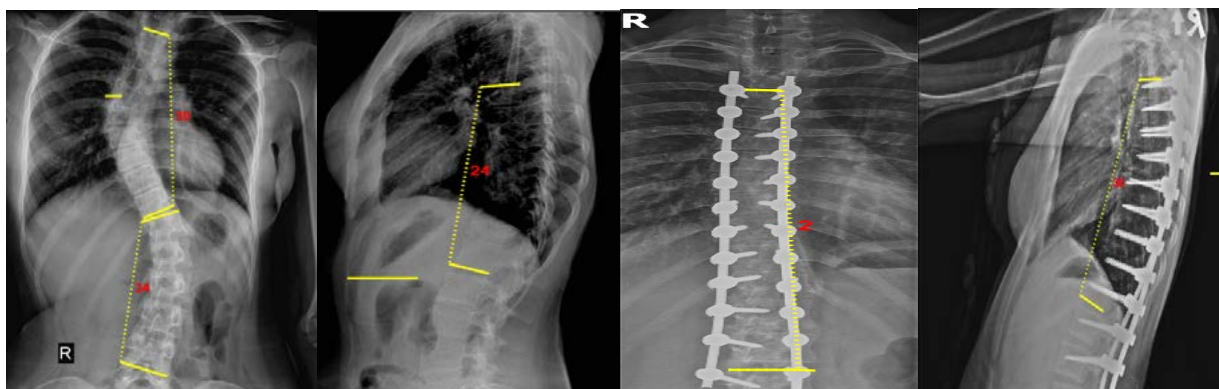
2 groups, in 1:1 ratio, undergoing posterior spinal fusion surgery using CrCo-Ti rod and Ti-Ti rod in both sides, using all pedicle screw fixation technique. Patients with AIS with Lenke classification type I or II, indicated for posterior spinal fusion surgery with instrumentation that have not had spinal surgery previously, were included in this study after obtaining informed written consent. Patients who had not been followed up for 12 months or underwent further surgery were excluded from study.

### Surgery procedure and management

The surgery in all patients has been done by a single surgeon and in the same institution. The procedure was done in prone position with the trunk supported at the upper thorax and thighs, while, abdomen was left free. Patients were put in a general anaesthesia and neuromonitoring control for every patient was done. Pedicles were fixed with polyaxial pedicle screws (Zimmer, Inc USA) with 4.5 or 5.5 mm diameter and between 25-45 mm in length, in both sides (Fig1). In the beginning, the uppermost and lowermost vertebrae's pedicles were screwed, and then vertebrae between them were screwed as well. Afterwards, the pre-bend rods were placed in these screws. At last, pre-bend rods were straightened up by pulling them from the sides through translation technique. Rods specifications were Ti or CrCo-Ti (Zimmer, Inc USA) with 5.5mm diameter.

In the intervention group, CoCr-Ti rod was placed in the working side (concave side) and Ti rod was placed in the resting side (convex side). In the control group, Ti rods were placed in both sides. All patients were operated under sensory evoked potential monitoring. Patients have used bracing for 3 months after surgery. First post-up radiography was done before

**FIGURE 1:** PREOPERATIVE AND POSTOPERATIVE RADIOGRAPHS OF AIS PATIENTS CORRECTED BY TRANSLATION TECHNIQUE WITH ALL PEDICLE SCREW AND TITANIUM -COCR RODS



**TABLE 1:** DEMOGRAPHIC INFORMATION OF PARTICIPANTS

Variables	Mean ± SD		P-value	
	CrCo-Ti	Ti-Ti		
Sex	Female*	18 (60.0%)	19 (65.5%)	0.661**
	male*	12 (40.0%)	10 (34.5%)	
Age (year)	13.93 ± 1.26	14.34 ± 1.54	0.265 \$	
Risser	3.93 ± 0.70	4.28 ± 0.65	0.055 \$	
Level of Fusion	9.77 ± 1.98	10.28 ± 1.91	0.318 \$	
Main Curve (grade)	55.17 ± 10.91	57.69 ± 11.56	0.392 \$	
Kyphosis Angle (grade)	38.63 ± 7.48	37.07 ± 6.40	0.392 \$	
Lordosis Angle (grade)	53.53 ± 8.64	51.17 ± 8.90	0.305 \$	
Flexibility (%)	31.80 ± 20.80	34.44 ± 20.40	0.624 \$	

\* n (%). \*\* Chi-square test. \$ T\_independent samples

**TABLE 2:** MAIN CURVE, KYPHOSIS AND LORDOSIS CHANGES REGARDLESS OF THE TECHNIQUE OF SURGERY

Variables	Mean ± SD		P-value*
	Before Surgery	After Surgery	
Main Curve	56.41 ± 11.21	7.46 ± 6.66	< 0.001
Kyphosis	37.86 ± 6.95	34.58 ± 3.70	< 0.001
Lordosis	52.37 ± 8.77	51.78 ± 5.98	0.559

\* paired t-test

discharge of patient. Regular post-up visit for every patient according to standard program was done.

**Data collection and imaging analysis**

On admission, patient’s demographic information including age, gender, curve flexibility and curve class according to Lenke classification, was recorded. Coronal and sagittal imaging of thoracic and lumbar region of spine were obtained in full-standing x-ray and bending supine PA radiography was done for each patient to evaluate curve specifications, respectively. After analysis of images using surgical map software (Surgimap®, a Nemaris Inc.), Cobb angle of main curve and secondary curves were calculated. Iliac crest X-ray images were obtained due to estimate skeletal maturity according to Risser system

of grading. Patients were visited again after surgery (1.5, 3, 6, 12, 24 months) in order to evaluate surgery efficiency and stability results, clinically and radiographically, as mentioned, again. Postoperative correction was calculated with the following formula:

POC%= ((preoperative full-standing Cobb angle-postoperative full-standing Cobb angle)/ postoperative full-standing Cobb angle). All measurements and assessments were done by a single experienced person and by surgical map software (Surgimap®, a Nemaris Inc.).

**Statistical analysis**

Collected data was analysed with independent t-test, paired t-test and univariate analysis of variance (ANOVA) in IBM SPSS20 - United States software. Results with significant P<0.05 were reported.

**RESULTS**

In the current study, 59 patients including 37 (62.7%) females and 22 (37.3%) males with diagnosis of AIS participated. Included patients had the mean age of 14.14±1.41 years old with the range of 12-17 years. Mean age of participating females was 14.03±1.24 and for males, it was 14.32±1.76 years (P-value=0.477). Patients’ Risser grading was 4.10±0.70 with the range of 3-5. In addition, their fusion level was 10.02±1.94 (Range of 4-13). Flexibility of main curve was 33.10 ± 20.47 percent with range of 11-55 degree.

In order of deformity correction, patients were randomly divided into two groups using CrCo-Ti rod for 30 patients of first group and Ti-Ti rod for the remaining 29 patients of second group. Table-1 is showing the demographic variables of patients. Based on findings of Table-1, patients’ distribution based on age and gender was not statistically different in both groups (P-value= 0.256 and 0.661, respectively). Success rate of spinal deformity correction follow-

**TABLE 3:** MAIN CURVE, KYPHOSIS, AND LORDOSIS ANGLES BEFORE AND AFTER SURGERY REGARDING ROD TYPE

Variables	Mean ± SD		P-value*	Mean ± SD		P-value*
	CrCo-Ti			Ti-Ti		
	Before Surgery	After Surgery		Before Surgery	After Surgery	
Main Curve	55.17 ± 10.91	4.76 ± 5.80	< 0.001	57.69 ± 11.56	10.34 ± 6.34	< 0.001
Kyphosis	38.63 ± 7.48	33.67 ± 3.31	< 0.001	37.07 ± 6.40	35.52 ± 3.90	0.177
Lordosis	53.53 ± 8.64	51.30 ± 6.10	0.117	51.17 ± 8.90	52.28 ± 5.90	0.447

\* paired t-test

ing surgical procedure regardless of type of administered rod was  $86.76 \pm 11.30$  percent ( $48.95 \pm 11.04$  degree). Mean of deformity correction rate was  $91.49 \pm 10.67\%$ , using CrCo-Ti rods versus  $81.86 \pm 9.88\%$  using Ti-Ti rods (P-value=0.01). Mean deformity correction percentage was  $86.30 \pm 12.82$  in females and  $87.53 \pm 8.36$  for males (P-value=0.657). For kyphotic change, mean angle was  $3.29$  ( $3.29 \pm 6.60$ ) degrees, regardless of type of rod used. Table-2 is showing effects of spinal deformity correction surgery regardless of type of rod used for the surgical procedure. According to these results, the main curve and kyphosis had statistically changed after surgery in comparison to its status prior to surgical procedure. Table-3 and Table-4 are showing mean changes of angles prior to and after surgical procedure and final detected curves of both groups respectively.

On the other hand, Univariate test showed that patients' age and type of rod are predicting factors for deformity correction success. By controlling the type of rod and age, prediction of successes of main curve correction is the following: P-value=0.054,  $r=-1.863$ . And by controlling age, use of CrCo-Ti rod is superior to Ti-Ti rods as follows: P-value=0.001,  $r=8.865$ .

## DISCUSSION

In this study, our data showed that using CrCo-Ti and Ti-Ti rods for treatment of AIS, the success rate of spinal deformity correction was higher with CrCo-Ti rods and also, these findings suggest that the rate mentioned was related to age and type of patients, but not to gender.

On the other hand, for many years, CoCr has an extremely high particular strength and rigidity and it is generally used in gas turbines, dental implants and orthopaedic implants<sup>8,9</sup>. CoCr rods have the ability to exert high corrective forces on the spine with relatively small amounts of rod deformation. This material also has the highest potential of plastic deformation in a highly rigid spine<sup>10,11</sup>. In our experience, the group using CoCr-Ti rods revealed a notably greater increase in spinal kyphosis than Ti-Ti group.

A study by Hwang et al.<sup>12</sup> showed maintenance of coronal and sagittal plane correction between 2- and 5-year follow up using screw constructs in AIS. Our data confirms the capability of the whole-pedicle screw construct to prevent deformity improvement while maintaining balance in kyphotic patients. Furthermore, different studies in recent years have

shown that efficiency of pedicle screws for achieving acceptable sagittal alignment in translation technique. In this correction technique, the importance of rod mechanical property should be steeply considered. In this term, by pedicle screw, the spine should be brought to the pre-contoured rods. It has been presented that CrCo rods have the ability of main curve correction and preventing sagittal change from deviations due to its balance between stiffness and flexibility<sup>13-15</sup>.

Lamerain *et al.*<sup>10</sup>, with study on 90 patients, suggested CoCr rods have the ability to produce higher correction rates in frontal plane compared to SS rods of the same diameter as well as Lamerain *et al.*<sup>16</sup> with another study on 61 patients treated by posterior spinal fusion and instrumentation, using all-pedicle screw constructs have indicated CoCr rods can produce sagittal corrections in hypokyphotic adolescent idiopathic scoliosis patients and they confirm the benefit of combining all-pedicle screw constructs

On the other hand, we have also revealed that main curve correction percentage was over 86% ( $86.76 \pm 11.30\%$ ) and plus, we observed notable correction of main curve angle in groups treated with CrCo-Ti rods and Ti-Ti rods. This rate was significantly higher with CrCo-Ti rod. The final main curve was significantly higher in the CrCo-Ti rods than Ti-Ti rod. This difference shows higher main curve angle correction using CrCo-Ti rods. In addition, in the other perspective of the findings of this study, for kyphotic change, the average angle was  $3.29$  ( $3.29 \pm 6.60$ ) degrees, regardless of the type of rod used. Patients treated with CrCo-Ti rods exhibited significant postoperative kyphotic changes but these postoperative changes with Ti-Ti rods were not significant. These kyphotic changes resulted from CrCo-Ti rod and they can be attributed to higher stiffness of CrCo rod added to acceptable flexibility of Ti rod. A study by Angelliaume *et al.*<sup>11</sup> reported the success rate of 71% in sagittal correction of AIS patients. This success rate was similar

**TABLE 4:** COMPARISON OF ANGLE CHANGES USING TI-C-CR OR TI-TI ROD

Variables	Mean $\pm$ SD		P-value*
	CrCo-Ti	Ti-Ti	
Main Curve	$4.67 \pm 5.80$	$10.34 \pm 6.34$	0.001
Kyphosis	$33.67 \pm 3.31$	$35.52 \pm 3.90$	0.054
Lordosis	$51.30 \pm 6.10$	$52.28 \pm 5.90$	0.535

\* t\_independent samples

to those described earlier of over 65%<sup>14,17</sup>. In contrast to our findings, Angelliaume *et al.*<sup>11</sup> found no differences between CrCo-Ti rods in comparison to Ti-Ti rods. In addition, kyphotic angle change was not statistically different comparing the two types of rods. Another research by Han *et al.* compared operated adults with main complaint of spinal deformity comparing CrCo rods with Ti rods. They did not observe statistical differences between the two types of rods in terms of sagittal vertical axis, thoracic kyphosis, lumbar lordosis and pelvic incidence. Another point in this remarkable study is the change in lumbar lordosis, which was over 35 degrees in the participants regardless of the type of rod.<sup>18</sup>

In conclusion, our findings showed that CrCo-Ti and Ti-Ti rods provide similar significant main curve correc-

tion in flexible spinal AIS, but the success rate of CrCo-Ti rods was significantly superior on spinal deformity correction. Moreover, our data also revealed that the use of CrCo-Ti and Ti-Ti rods associated with all-pedicle screw construct is the best association to provide the highest correction rate in idiopathic scoliosis correction procedures. This is the first study in Iran to describe the clinical use of CrCo-Ti rod that shows marked radiographic improvement in coronal and sagittal alignment. Furthermore, we found better restoration of kyphotic angle change with the use of CrCo-Ti rods compared with Ti-Ti rods. In the CrCo-Ti group, the rate of postoperative kyphotic angle change was significantly higher than in the Ti-Ti group.

Study conducted at Isfahan University of Medical Sciences, Isfahan, Iran

## RESUMO

**OBJETIVO:** Comparar o resultado da correção da deformidade da coluna vertebral com ligas de Ti-Ti e CrCo-Ti para o tratamento da Escoliose Idiopática do Adolescente (EIA) na coluna usando as ligas mencionadas com todos os parafusos pediculares e técnica de tradução.

**MÉTODO:** 59 pacientes operados por EIA com deformidade da coluna vertebral (Lenke 1 ou 2). Os pacientes foram divididos em dois grupos por alocação aleatória usando ligas de Ti-Ti (n = 29) e ligas de CrCo-Ti (n = 30) e a única diferença entre eles no procedimento cirúrgico foi o material da liga (ligas de Ti-Ti ou CrCo-Ti) e, finalmente, resultados radiológicos foram comparados no pré-operatório, pós-operatório e no último retorno por 12 meses.

**RESULTADOS:** A correção da curva principal do paciente após o procedimento cirúrgico, independentemente do tipo de liga, foi de 48,95±11,04 (13-75) graus. A taxa de sucesso da correção da deformidade da coluna vertebral após o procedimento cirúrgico, independentemente do tipo de liga administrada, foi de 86,76 ± 11,30% (62,5-100%). A média da taxa de correção da deformidade foi de 91,49±10,67% usando ligas de CrCo-Ti e 81,86±9,88% usando ligas de Ti-Ti (valor de P = 0,01). A mudança de ângulo foi de 3,29±6,60 para o ângulo de cifose e de 0,59±7,76 para o ângulo de lordose. A taxa de correção da curva principal não foi significativamente diferente considerando o sexo dos pacientes (Valor de P 0,657). A taxa de sucesso da correção da curva principal foi associada à idade do paciente e ao tipo de liga (valor de P=0,054, r=-1,863 e valor de P=0,001, r=8,865, respectivamente).

**CONCLUSÃO:** As ligas de CrCo-Ti têm a capacidade de produzir taxas de correção mais altas em EIA em comparação com a liga de Ti-Ti do mesmo diâmetro. As ligas de CrCo-Ti fornecem uma correção espinhal significativa e estável, especialmente na correção da curva principal. Essa taxa foi associada à idade e ao tipo de liga administrada, mas não ao sexo.

**PALAVRAS-CHAVE:** Adolescente. Escoliose. Ligas de Cromo. Titânio. Resultado do Tratamento.

## REFERENCES

1. Delorme S, Labelle H, Aubin CE, Guise JA, Rivard CH, Poitras B, et al. A three-dimensional radiographic comparison of Cotrel-Dubousset and Colorado instrumentations for the correction of idiopathic scoliosis. *Spine (Phila Pa 1976)*. 2000;25(2):205-10.
2. Weinstein SL, Dolan LA, Cheng JC, Danielsson A, Morcuende JA. Adolescent idiopathic scoliosis. *Lancet*. 2008;371(9623):1527-37.
3. Miller N. The role of genetic factors in the etiology of idiopathic scoliosis. *Spine*. 2000;14(2):313-8.
4. Asher MA, Burton DC. Adolescent idiopathic scoliosis: natural history and long term treatment effects. *Scoliosis*. 2006;1(1):2.
5. Riedel MD. What's the evidence? Systematic literature review of risk factors and preventive strategies for surgical site infections following pediatric spine surgery. 2012 AAP National Conference and Exhibition; 2012: American Academy of Pediatrics.
6. Serhan H, Mhatre D, Newton P, Giorgio P, Sturm P. Would CoCr rods provide better correctional forces than stainless steel or titanium for rigid scoliosis curves? *J Spinal Disord Tech*. 2013;26(2):E70-4.
7. Sales de Gauzy J, Jouve JL, Ilharreborde B, Blondel B, Accadbled F, Mazda K. Use of the Universal Clamp in adolescent idiopathic scoliosis. *Eur Spine J*. 2014;23(Suppl 4):S446-51.
8. Al Jabbari YS. Physico-mechanical properties and prosthodontic applications of Co-Cr dental alloys: a review of the literature. *J Adv Prosthodont*. 2014;6(2):138-45.
9. Miller A, Islam K, Grannum S, Morris S, Hutchinson J, Nelson I, et al. Cobalt chromium versus titanium alloy: has the change in scoliosis implant material improved deformity correction? *Orthopaedic Proceedings* 2018;96(Suppl 6):20.
10. Lamerain M, Bachy M, Delpont M, Kabbaj R, Mary P, Vialle R. CoCr rods

- provide better frontal correction of adolescent idiopathic scoliosis treated by all-pedicle screw fixation. *Eur Spine J.* 2014;23(6):1190-6.
11. Angelliaume A, Ferrero E, Mazda K, Le Hanneur M, Accabled F, Gauzy JS. Titanium vs cobalt chromium: what is the best rod material to enhance adolescent idiopathic scoliosis correction with sublaminar bands? *Eur Spine J.* 2017;26(6):1732-8.
  12. Hwang CJ, Lee CK, Chang BS, Kim MS, Yeom JS, Choi JM. Minimum 5-year follow-up results of skipped pedicle screw fixation for flexible idiopathic scoliosis. *J Neurosurg Spine.* 2011;15(2):146-50.
  13. Abul-Kasim K, Karlsson MK, Ohlin A. Increased rod stiffness improves the degree of deformity correction by segmental pedicle screw fixation in adolescent idiopathic scoliosis. *Scoliosis.* 2011;6:13.
  14. Mazda K, Ilharreborde B, Even J, Lefevre Y, Fitoussi F, Penneçot GF. Efficacy and safety of posteromedial translation for correction of thoracic curves in adolescent idiopathic scoliosis using a new connection to the spine: the Universal Clamp. *Eur Spine J.* 2009;18(2):158-69.
  15. Acar N, Karakasli A, Karaarslan AA, Ozcanhan MH, Ertem F, Erduran M. The mechanical effect of rod contouring on rod-screw system strength in spine fixation. *J Korean Neurosurg Soc.* 2016;59(5):425-9.
  16. Lamerain M, Bachy M, Dubory A, Kabbaj R, Scemama C, Vialle R. All-pedicle screw fixation with 6-mm-diameter cobalt-chromium rods provides optimized sagittal correction of adolescent idiopathic scoliosis. *Clin Spine Surg.* 2017;30(7):E857-63.
  17. Bridwell KH, Hanson DS, Rhee JM, Lenke LG, Baldus C, Blanke K. Correction of thoracic adolescent idiopathic scoliosis with segmental hooks, rods, and Wisconsin wires posteriorly: it's bad and obsolete, correct? *Spine (Phila Pa 1976).* 2002;27(18):2059-66.
  18. Han S, Hyun SJ, Kim KJ, Jahng TA, Lee S, Rhim SC. Rod stiffness as a risk factor of proximal junctional kyphosis after adult spinal deformity surgery: comparative study between cobalt chrome multiple-rod constructs and titanium alloy two-rod constructs. *Spine J.* 2017;17(7):962-8.

