

DIAGNOSIS OF OVARIAN DYSGERMINOMA DURING PREGNANCY

José Eduardo Gauza^{1*}, Ademir Garcia Reberti², Jean Carl Silva³, Leonora Zozula Blind Pope⁴, João Cesar da Rocha dos Santos⁵, Silvana Maria Quintana⁶

Study conducted at the Hospital Dona Helena, Joinville, SC, Brazil

INTRODUCTION

Dysgerminomas are tumors originating within the primordial ovarian germ cells. They are very rare, frequently malignant, and are responsible for around 1% of all germ cell tumors.^{1,2} Around 20 to 25% of ovarian tumors originate in the germ cells and just 3% are malignant.³ Germ cell tumors account for around 70% of ovarian neoplasm cases, during the first decades of life, manifest malignant characteristics in 1/3 of cases and are rarely found after this period.^{3,4} Dysgerminoma has a classic correlation with seminoma of the testis, having an identical histological structure.^{1,2,5,6} It affects young females, usually during childhood, and patients generally respond well to chemotherapy.¹ They are generally considered to have low malignant potential, but may spread if there is invasion through metastasis or capsule, or lymph node or blood cell involvement.^{2,8,9}

CASE

A white, 25-year-old female sought medical services for prenatal care.

Previous 4-years' history was healthy with no occurrences. Patient claimed no family history of neoplasm and reported menarche at 12 and regular menstrual cycles. Patient reports no previous surgeries or cervical cauterization. Pregnancies 1 Births 0; prenatal tests all normal, pregnancy progressed with no intercurrent clinical conditions. Obstetric US at 14 weeks showed an enlarged left ovary with a corpus luteum cyst. US at 19w2d normal. US at 31 weeks showed a solid mass in the left adnexa, contiguous with the uterus, measuring 179x152 mm = 1915 cm³, compatible with a myomatous node with central necrosis; fetus free from abnormalities. From this point on, the patient began to complain of mild pain focused in the left hypochondrium and radiating out to the iliac fossa on the same side and improving with non-opiate analgesics and with no other complaints. At 39 weeks the patient went into labor and elected to deliver by caesarian via mid-line infraumbilical laparotomy. The infant weighed 2700g with a 1-minute Apgar of 9 and a 5-minute Apgar of 10. On investigation of the abdominal cavity, a solid mass was found originating in the ovary, corresponding to the left adnexal volume. Other structures adjacent to the uterus were apparently unchanged macroscopically. The pathology report described Pure dysgerminoma; weighing

2855g and measuring 23.0x18.0x11.0cm; tumor limited to the ovary; capsule infiltrated, but intact; free from neoplasm on the external surface.

Mitosis rate of 5/HPF, few stroma and discrete lymphocytic infiltrate. Angiolymphatic invasion was not detected. An oncological investigation was conducted and found no signs of intracavity expansion. The patient was later subjected to surgery to stage the tumor, with biopsy samples taken from the left and right (L/R) iliac fossa (L/R), L/R diaphragmatic peritoneum, L/R paracolic gutter, total excision of the omentum and peritoneal lavage, in which no neoplastic tissue was found. The patient was referred for supplementary chemotherapy treatment and the final staging, according to FIGO (1985) was Stage 1 A. This study was approved by the Research Ethics Committee at the Hospital Dona Helena, Joinville, SC, Brazil, in accordance with National Health Council (Conselho Nacional de Saúde) Resolution 196/96 on research involving human beings, and written consent was obtained from the patient.

DISCUSSION

Non-epithelial ovarian tumors, originating from germ cells, are rare when compared with epithelial tumors and account for 10% of ovarian cancer cases.^{1,2,4,5,10} Since this is an uncommon tumor, a diagnosis of dysgerminoma is suspected at the point that a surgeon encounters it, for the first time and predicting prognosis demands certainty that metastasis has not occurred, which will undoubtedly improve the chances of better and longer survival.^{2,9,11} In the case described here, giant left-side uterine leiomyoma was diagnosed during prenatal tests and neither adnexal tumor nor ovarian neoplasm were considered. Although the 14-week obstetric US showed a corpus luteum cyst in an enlarged left ovary, to a certain extent, this corresponds to what takes place in around 70% to 80% of cases, when the US operator does not routinely measure the diameter^{8,11,12}. Furthermore, the fact that the US at 19 weeks and 2 days did not identify structural abnormalities, either in the fetus or the ovary, raises the question of whether or not there was a mass in the ovary at that point, since the US operator reported nothing. The specialist literature indicates that certain neoplasms may undergo geometric growth of up to around 20% of their original size in a very short period of time (1 - 2 months)^{12,14,26}. When the 31-week US identified a solid mass in the left adnexa, its

1. Mestrado em Saúde e Meio Ambiente - Médico obstetra do Hospital Dona Helena, Joinville, SC

2. Mestre em Saúde e Meio Ambiente - Professor do Curso de Medicina da Universidade da Região de Joinville - UNIVILLE, Joinville, SC

3. Doutor em Ciências Médicas - Professor do Curso de Medicina da Universidade da Região de Joinville - UNIVILLE, Joinville, SC

4. Mestre em Saúde e Meio Ambiente - Professora do Curso de Medicina da Universidade da Região de Joinville - UNIVILLE-SC, Joinville, SC

5. Médico oncologista do Hospital Dona Helena, Joinville, SC

6. Doutora em Tocoginecologia - Professora do Curso de Medicina da Universidade de São Paulo - USP-Ribeirão Preto, São Paulo, SP

Figure 1 - Image of the tumor (Dysgerminoma) during surgery (full term caesarian, midline infraumbilical laparotomy

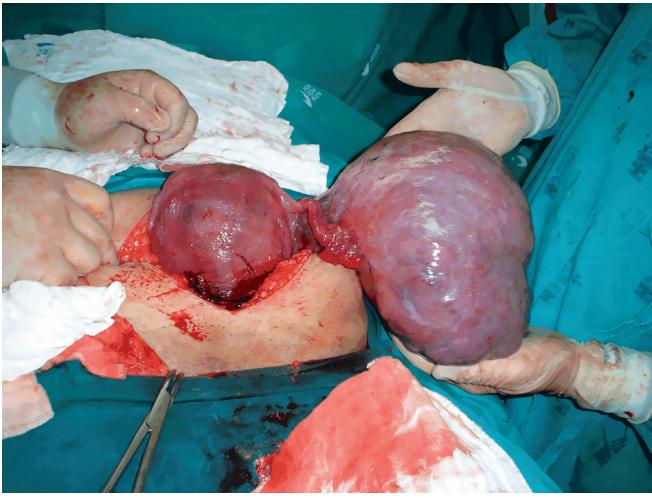
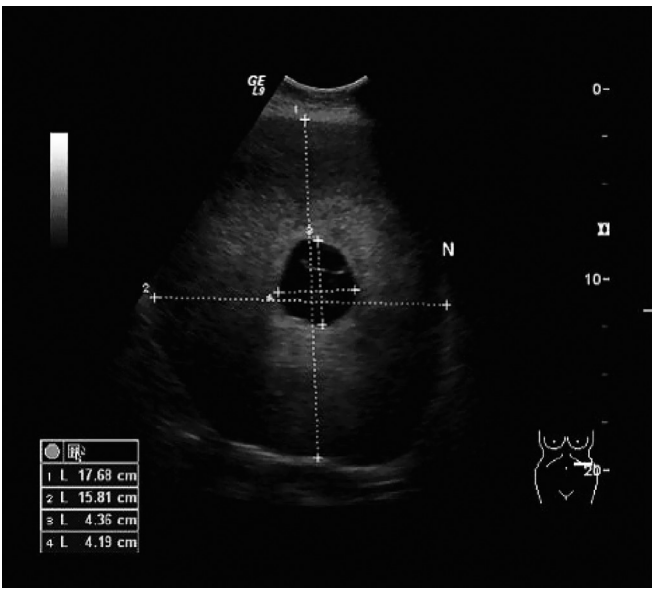
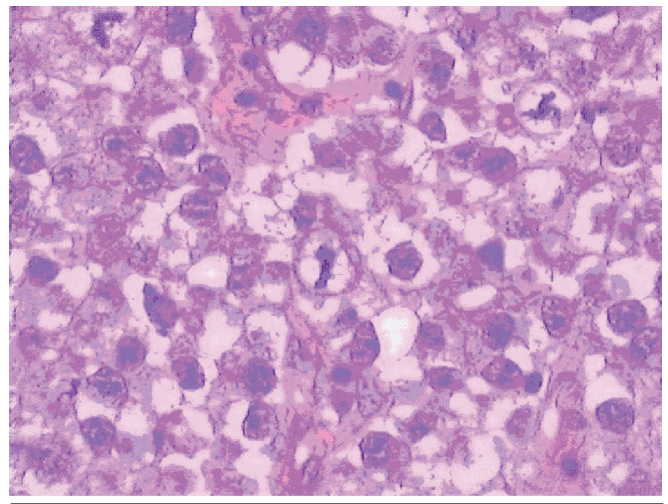


Figure 2 - Ultrasound scan at full term, showing the tumor (pure dysgerminoma), prior to the caesarian. Central necrosis area



morphological characteristics were not recorded, in terms of its structure, consistency and exact location, only its contiguity with the uterus was demonstrated. This is the reason why uterine myomatosis was suspected and when the suspicion is uterine myomatosis during pregnancy, workup is not of the same order as would be ordered if the suspicion were a malignant ovarian tumor, such as testing for tumor markers, pelvic magnetic resonance imaging and others.^{2,3,4,26} Zganjer et al. suggested a hypothesis of an association between dysgerminoma and an abdominal trauma in a patient of 12 years of age involved in a traffic accident⁶. It is also known that the clinical courses of some

Figure 3 - Histopathology of tumor (pure dysgerminoma)



syndromes have associations with dysgerminoma, as is the case with Cowden's syndrome¹², ataxia telangiectasia syndrome¹³, Swyer syndrome (pure gonadal dysgenesis associated with the XY 46 karyotype)^{14,15}, Apert syndrome (an autosomal dominant disorder)¹⁶ and Down Syndrome¹⁷. Since the patient described here was pregnant and had no phenotypical signs that would suggest relevant syndromic data, she was not asked about, or assessed for, this possibility. An association between dysgerminoma and malignant hypercalcemia^{10,18,19} has been described by some authors, but in this case tests showed that the patient was within normal limits. Another peculiarity that attracts attention is the association with dysgerminoma described in some varieties of animals^{20,21}. This was a very large ovarian tumor, weighed at 3160 g in the operating theater, with a firm consistency, mobile, with an intact capsule and no ascites. Everything would indicate poor prognosis, but this did not turn out to be the case and the histopathological diagnosis was Stage 1 A dysgerminoma. Although the literature consulted suggests the possibility of adjuvant chemotherapy, the decision was taken not to use chemotherapy with this patient in favor of clinical follow-up because of the favorable results of the surgery conducted for tumor staging 45 days after the caesarian and because the patient's clinical status was considered stable, as it still is today, in line with reports by some authors,^{22,23} which describe some unsuccessful attempts with chemotherapy, such as Ishibashi et al¹¹, who described a case of a 14 year-old refractory to a first chemotherapy session.

The objective of publicizing this case was to raise awareness of adnexal tumors which can affect females, even during an uneventful pregnancy, and which can exhibit shockingly rapid increases in volume in a very short time.

REFERENCES

1. Ladis SH, Murray T, Bolden S, Wingo PA. Cancer statistics. CA Cancer J Clin. 1998;48:6-25.
2. Duska L, Bicher A. Câncer de ovário. In: Lambrou NC, Morse AN, Wallach E. Manual de ginecologia e obstetrícia do Johns Hopkins. Porto Alegre: Artmed; 1999. p.431-50.

3. Thimble EL. The NIH Consensus Conference on ovarian cancer: screening, treatment and follow-up. *Gynecol Oncol.* 1994;55:51-3.
4. Palenzuela G, Martin E, Meunier A, Beuzeboc P, Laurence V, Orbach D, et al. Comprehensive staging allows for excellent outcome in patients with localized malignant germ cell tumor of the ovary. *Ann.Surg.* 2008;248:836-41.
5. Nguyen HN, Averette HE, Janicek M. Ovarian carcinoma: a review of the significance of familial risk factors and the role of prophylactic oophorectomy in cancer prevention. *Cancer.* 1994;74:545-55.
6. Zganjer M, Cizmic A, Stepan J, Butkovic D, Zupancic B, Bartolek F. Ovarian dysgerminoma and acute abdomen. *Bratisl.Lek.Listy.* 2006;107:253-5.
7. Topuz S, Iyibozkurt AC, Akhan SE, Keskin N, Yavuz E, Salihoglu Y, et al. Malignant germ cell tumors of the ovary: a review of 41 cases and risk factors for recurrence. *Eur.J.Gynaecol.Oncol.* 2008;29:635-7.
8. Desirotte G, Pintiaux A, Foidart JM, Nisolle M. Four clinical cases of dysgerminoma. *Rev Med Liege.* 2008;63:523-7.
9. Guillem V, Poveda A. Germ cell tumours of the ovary. *Clin Transl Oncol.* 2007;9:237-43.
10. Hibi M, Hara F, Tomishige H, Nishida Y, Kato T, Okumura N, et al. 1,25-dihydroxyvitamin D-mediated hypercalcemia in ovarian dysgerminoma. *Pediatr Hematol Oncol.* 2008;25:73-8.
11. Ishibashi M, Nakayama K, Oride A, Yeasmin S, Katagiri A, Iida K, Nakayama N, Miyazaki K. [A case of PEP(BEP)-resistant ovarian dysgerminoma successfully treated by VeLP therapy]. *Gan To Kagaku Ryoho.* 2009;36:513-7.
12. Cho MY, Kim HS, Eng C, Kim DS, Kang SJ, Eom M, Yi SY, Bronner MP. First report of ovarian dysgerminoma in Cowden syndrome with germline PTEN mutation and PTEN-related 10q loss of tumor heterozygosity. *Am J Surg Pathol.* 2008;32:1258-64.
13. Koksall Y, Caliskan U, Ucar C, Yurtcu M, Artac H, Ilerisoy-Yakut Z, et al. Dysgerminoma in a child with ataxia-telangiectasia. *Pediatr Hematol Oncol.* 2007;24:431-6.
14. Nisolle M, Kridelka F, Fridman V, Claudot A, Lorquet S, Foidart JM. A bilateral dysgerminoma: a rare presentation of the Swyer syndrome. *Rev Med Liege.* 2005;60:703-6.
15. Namavar-Jahromi B, Mohit M, Kumar PV. Familial dysgerminoma associated with 46, XX pure gonadal dysgenesis. *Saudi Med J.* 2005 ;26:872-4.
16. Rouzier C, Soler C, Hofman P, Brennetot C, Bieth E, Pedeutour F. Ovarian dysgerminoma and Apert syndrome. *Pediatr Blood Cancer.* 2008;50:696-8.
17. Satge D, Honore L, Sasco AJ, Vekemans M, Chompret A, Rethore MO. An ovarian dysgerminoma in Down syndrome. Hypothesis about the association. *Int J Gynecol Cancer.* 2006;16(Suppl 1):375-9.
18. Evans KN, Taylor H, Zehnder D, Kilby MD, Bulmer JN, Shah F, et al. Increased expression of 25-hydroxyvitamin D-1alpha-hydroxylase in dysgerminomas: a novel form of humoral hypercalcemia of malignancy. *Am J Pathol.* 2004;165:807-13.
19. Matthew R, Christopher O, Philippa S. Severe malignancy-associated hypercalcemia in dysgerminoma. *Pediatr Blood Cancer.* 2006;47:621-3.
20. Fitzgerald SD, Duncan AE, Tabaka C, Garner MM, Dieter A, Kiupel M. Ovarian dysgerminomas in two mountain chicken frogs (*Leptodactylus fallax*). *J Zoo Wildl Med.* 2007;38:150-3.
21. Harland S, Smith C, Mogg T, Horadagoda N, Dart A. Surgical resection of a dysgerminoma in a mare. *Aust Vet J.* 2009;87:110-2.
22. Pauls K, Wardelmann E, Merkelbach-Bruse S, Buttner R, Zhou H. c-KIT codon 816 mutation in a recurrent and metastatic dysgerminoma of a 14-year-old girl: case study. *Virchows Arch.* 2004;445:651-4.
23. Ramirez TN, Basavilvazo Rodriguez MA, Tellez MA, Robles RG, Lemus RR, et al. Clinical experience with chemotherapy of the malignant tumor of germinal cells (dysgerminoma) of the ovary. *Ginecol Obstet Mex.* 2004;72:500-7.
24. Patterson DM, Murugaesu N, Holden L, Seckl MJ, Rustin GJ. A review of the close surveillance policy for stage I female germ cell tumors of the ovary and other sites. *Int J Gynecol Cancer.* 2008;18:43-50.
25. Roth LM, Talerma A. Recent advances in the pathology and classification of ovarian germ cell tumors. *Int J Gynecol Pathol.* 2006;25:305-20.
26. Cunningham FG, Leveno KJ, Bloom SL, Hauth JC, Rouse DJ, Spong CY, editors. *Williams obstetrics.* 22nd ed. New York (NY): Mc Graw-Hill; 2005.

***Correspondence:**

Rua Blumenau, 178 , 8º andar , 802 – Centro
Joinville-SC, Brazil
CEP: 89204.250
Fone: (47) 34336630
gauza@terra.com.br