


Secondary osteoarthritis to ochronotic arthropathy - a diagnostic challenge

 Priscila Evangelista¹
 José Sávio Parente²
 Romano Brasileiro¹
 José Gerardo Paiva¹
 Max Victor Freitas¹
 Aline Moreira¹
 Ana Paula Alves³
 Igor Costa⁴

1. Rheumatology, General Hospital Geral César Cals, Fortaleza, Ceará, Brasil
 2. University of Sao Paulo, Campus of Ribeirao Preto, Ribeirão Preto, São Paulo, Brasil
 3. Ophthalmology, General Hospital Geral César Cals, Fortaleza, Ceará, Brasil
 4. Pathology, General Hospital Geral César Cals, Fortaleza, Ceará, Brasil

<http://dx.doi.org/10.1590/1806-9282.64.07.583>

KEYWORDS: Osteoarthritis. Ochronosis/complications. Alkaptonuria.

Alkaptonuria is a genetic disorder of the tyrosine metabolism with autosomal recessive transmission, characterized by deficiency of the enzyme homogentisic acid oxidase.¹⁻⁴ The disease presents an estimated prevalence of 1:250,000, data being rare in Brazil.^{1,5} It predominates in males and usually occurs after the fourth decade of life. The disease may be asymptomatic or lead to ochronosis, characterized by the accumulation of homogentisic acid metabolites in the connective tissues. This deposition leads to several clinical manifestations, such as cutaneous and ocular pigmentation, dark urine, arthropathy and cardiovascular manifestations. A severe form of arthropathy is the most common clinical presentation; however, patients often suffer from cardiovascular disease as well.² In this report, we describe the case of a patient with ochronosis presenting with cutaneous, ocular and joint manifestations of the disease.

A 54-year-old stay-at-home female, born in Umari, Ceará, was admitted with chronic weakness and chronic arthralgia in the knees, hip and lumbar region, with

a progressive character, with limitation of daily activities. Walking was limited by pain in hip and knee joint, bilaterally, which was worse at the end of the day, and by mobilization. She also presented with diuresis and skin alterations. Family history included consanguineous marriage between the parents, and a daughter with congenital deafness. Over the years, she presented progressive worsening of the joint in the knees, hips and shoulders, evolving ten years ago, with loss of routine daily activities, worsening of locomotion difficulty and reduction of lumbar mobility. She sought medical attention, in which anti-inflammatories and painkillers were prescribed, which she started to use daily. Two years ago, she presented with progressive asthenia, worse at the end of the day, seeking specialized medical attention in January 2015. In view of this situation, the patient was admitted for diagnostic investigation through laboratory tests, imaging and cutaneous biopsy of the lesions pigmented. At physical examination, there were bluish patches on the auricle, the sclera, and the palmar side of the hands.

DATE OF SUBMISSION: 09-Nov-2017
 DATE OF ACCEPTANCE: 05-Dec-2017
 CORRESPONDING AUTHOR: Priscila Evangelista,
 Avenida Imperador, 545 – Centro – Fortaleza
 Ceará – Brasil 60015-152
 E-mail: prisciladouradoe@gmail.com

jsaviomp@yahoo.com.br
 romanobrasileiro@gmail.com
 jgapaiva@gmail.com
 maxvcf@gmail.com
 linearaujo_m@hotmail.com
 apxalves@gmail.com
 igorscosta@me.com

Difficulty to walk and reduced lumbar mobility (Schöber test of 1.6 cm) was observed, as well as pain in the mobilization of the right shoulder, hip and knees. Lumbar radiography showed diffuse reduction of intervertebral spaces with disc calcifications in multiple planes. In biopsy of left upper limb skin under microscopy, several degenerate, comma or banana-shaped enlarged collagen beams of golden/brownish colour, present in the superficial and intermediate dermis, with a suggestive aspect of ochronosis, were evidenced. The homogentisic acid test was negative in the urine by the ammonia silver nitrate reduction method, the ferric chloride test and the Benedict reagent reduction test. These methods are not very sensitive. The most sensitive method would be by gas chromatography, but this research was limited due to the unavailability of the test. Anti-inflammatory medications were administered during hospitalization and the patient presented a good response, being discharged in good clinical condition, with improvement of joint pain, and being referred to the Rheumatology outpatient clinic.

DISCUSSION

Patients with alkaptonuria are usually asymptomatic in childhood and as young adults. When the affected individuals age, pigmentation of the sclera and auricular pavilion begins^{4,6}. Joint symptoms typically begin in the third and fourth decade of life.⁷ Ochronotic arthropathy is characterized by involvement of the spine and large joints and is a rare cause of secondary osteoarthritis. The lumbar spine is generally the most affected anatomical location,¹² and the spinal involvement resembles the pattern found in ankylosing spondylitis, but differs from this because it spares the sacroiliac joints. Calcifications of intervertebral discs are the characteristic findings in the spine. In the case reported, the patient presented alterations in the radiographs consistent with the expected for the disease in question. Symptomatic treatment is recommended in the early stages of the disease; in more advanced stages, surgical interventions, such as arthroplasty, may be necessary.^{5,6}

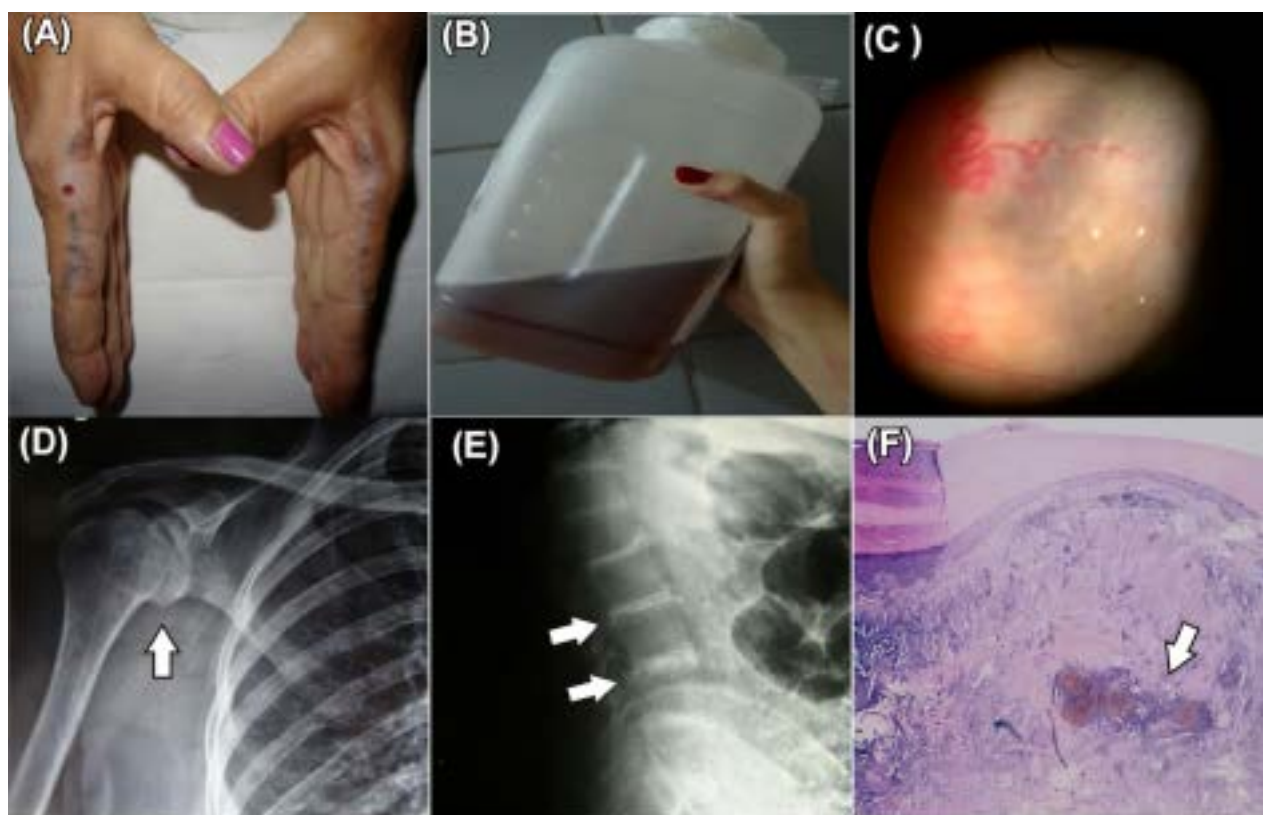


FIGURE 1. (A) Woman, 54 years old, presenting chronic joint pain in knees, hips and lumbar region. She presents ochronotic pigmentation deposit in the blue-blackish colour on hand skin. (B) Dark urine. (C) Dark pigments in the sclera. (D) AP radiography of shoulder evidencing reduction of joint space, sclerosis of subchondral bone. (E) Radiography of lumbar spine in profile evidencing diffuse reduction of intervertebral spaces, with disk calcifications in multiple planes. (F) Biopsy of hand acral region skin (10x Optic microscopy) evidencing degeneration of collagen beams and thick fibres – classic golden-brown colour in comma or banana shape. Ochronosis.

PALAVRAS-CHAVE: Osteoartrite. Ocronose/complicações. Alcaptonúria.

REFERENCES

1. Hochberg MC, Silman AJ, Smolen JS, Weinblatt ME, Weisman MH. Rheumatology. 6th ed. Philadelphia: Elsevier; 2015. p.1606-10.
2. Millucci L, Ghezzi L, Paccagnini E, Giorgetti G, Viti C, Braconi D, et al. Amyloidosis, inflammation, and oxidative stress in the heart of an alkaptonuric patient. *Mediators Inflamm*. 2014;2014:258471.
3. Ferreira AMSM, Santos FL, Costa AMC, Barbosa BMP, Rocha RMR, Fontes Lebre JF. Knee osteoarthritis secondary to ochronosis: clinical case. *Rev Bras Ortop*. 2014;49(6):675-80.
4. Craide FH, Fonseca JSBM, Mariano PC, Fernandez NM, Castro CGC, Mene YSL. Alkaptonuria: case report. *An Bras Dermatol*. 2014;89(5):799-801.
5. Zhao BH, Chen BC, Shao de C, Zhang Q. Osteoarthritis? Ochronotic arthritis! A case study and review of the literature. *Knee Surg Sports Traumatol Arthrosc*. 2009;17(7):778-81.
6. Pratibha K1, Seenappa T, Ranganath K. Alkaptonuric ochronosis: report of a case and brief review. *Indian J Clin Biochem*. 2007;22(2):158-61.
7. Al-Mahfoudh R1, Clark S, Buxton N. Alkaptonuria presenting with ochronotic spondyloarthropathy. *Br J Neurosurg*. 2008;22(6):805-7.

