



Revista da
ASSOCIAÇÃO MÉDICA BRASILEIRA

www.ramb.org.br



Image em medicine

Burning sensation and rupture of a totally implantable venous catheter[☆]

Cristiane Maria Mártires de Lima*, José Henrique da Silva, Vivian Marques Miguel Suen, Selma Freire de Carvalho da Cunha, Júlio Sérgio Marchini

Clinical Nutrition Division, Department of Internal Medicine, Faculty of Medicine of Ribeirão Preto, Universidade de São Paulo (USP), Ribeirão Preto, SP, Brazil

Introduction

The use of totally implantable venous catheters is necessary for drug and chemotherapy delivery, blood infusion, hemoderivatives, and parenteral nutrition (PN). However, its use is not free from complications.¹ Among these, the rupture of the device is a rare and dreaded complication that can result either from improper handling or instrumentation as the inappropriate choice of the insertion site.² Although there have been few reports of broken catheters that showed decreased elasticity, the rupture of the device, until now, cannot be attributed to the substance infused.³

Case report

The case of a male patient, aged 46 years, with a history of thrombophilia who had mesenteric infarction in May 2011, is described. He suffered extensive bowel resection and terminal jejunostomy, with four inches of jejunum remaining after Treitz. The patient received PN through a totally implanted catheter in the left internal jugular vein for three weeks. After 21 days of PN infusion, during alcohol 70% infusion through the catheter,⁴ a procedure performed to prevent catheter-related infection, the patient complained of burning sensation in the left internal jugular vein topography. Due to the initial difficulty of aspirating blood from the catheter, it was decided to stop PN infusion until an image confirming proper catheter

position was obtained. The anteroposterior chest radiograph obtained in supine position showed an almost complete rupture of the catheter (Fig. 1).

The removal of the device in the operating room was uneventful.

Discussion

Totally implantable catheters are vascular devices placed in the central veins. A connected reservoir lies under the skin, and must be punctured by a specialized angled needle or Huber needle. This catheter is used for long term procedures, mainly in oncologic patients. At the Hospital das Clínicas de Ribeirão Preto, in the Clinical Nutrition Division, it has been used for several decades to deliver PN to short bowel syndrome patients. There are several possible complications of the central venous catheter insertion, which may occur early or late. Infectious and mechanical complications, such as pneumothorax, hemothorax, hydrothorax,¹ catheter migration, thrombosis, vascular erosion, and others have been described. The present case report, emphasizes catheter rupture, a rare, although feared complication. It is usually related to incorrect manipulation or misplaced insertion.²

The Centers for Disease Control and Prevention's 2011 guidelines for the prevention of intravascular catheter-related infections⁵ describe the use of 70% ethanol lock solution as prophylactic means to avoid this complication,

[☆]Study conducted at the Hospital das Clínicas de Ribeirão Preto, Faculty of Medicine of Ribeirão Preto, Universidade de São Paulo, Ribeirão Preto, SP, Brazil

*Corresponding author at: Departamento de Clínica Médica, 6º andar do HCRP, Avenida Bandeirantes, 3900, Ribeirão Preto, SP, 14049-900, Brazil
E-mail address: cris_martires@hotmail.com (C.M.M. Lima)

0104-4230/\$ - see front matter © 2013 Elsevier Editora Ltda. All rights reserved.

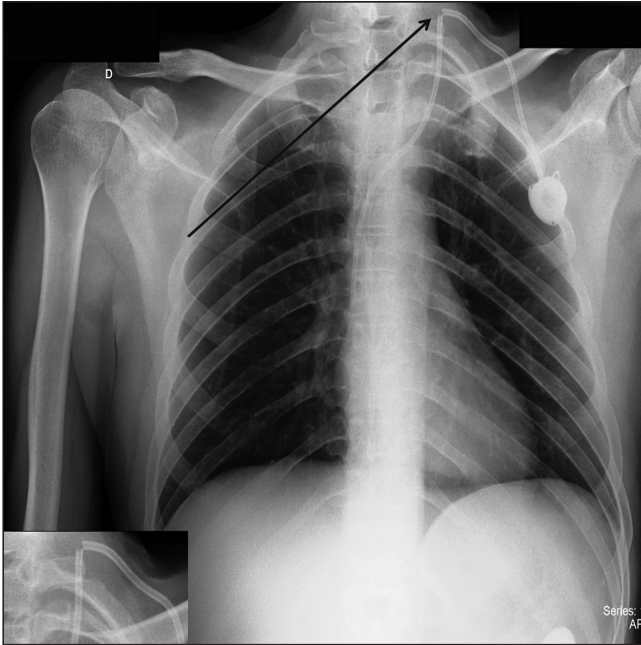


Fig. 1 – Anteroposterior chest radiograph showing a ruptured catheter in the right upper corner, left side of the patient (black arrow). In the lower left corner of the figure the rupture is highlighted.

including in totally implantable devices. A double-blinded randomized study has compared 70% ethanol versus heparin lock solution, and has found no strength and durability changes in the catheters.

The side effects related to the ethanol solution in most studies were mild or absent. However, other reactions described are central nervous system depression, cardiac arrhythmia, flushing, and local venous injury.⁴ Symptoms

such as palpitation and chest discomfort have been reported by patients with broken catheters. In this case, the patient complained about a burning sensation in the left cervical topography, corresponding to the catheter insertion site. Difficulty to infuse solutions through the device was also observed.

This publication is important because it alerts that the burning sensation symptom could mean catheter rupture, rather than a side effect of ethanol infusion; this complication should be ruled out, since this would avoid other problems such as catheter migration.

Conflict of interest

All authors declare to have no conflict of interest.

REFERENCES

1. Silvah JH, Lima CMM, Chagas-Neto FA, Araújo GT, Chueire FB, Cunha SFC, et al. Hydrothorax due to parenteral nutrition: a case report. *J Vasc Bras.* 2011;10:239-42.
2. Askegard-Giesmann JR, Caniano DA, Kenney BD. Rare but serious complications of central line insertion. *Semin Pediatr Surg.* 2009;18:73-83.
3. Filippou DK, Tsikkinis C, Filippou GK, Nissiotis A, Rizos S. Rupture of totally implantable central venous access devices (Intraports) in patients with cancer: report of four cases. *World J Surg Oncol.* 2004, 2:36.
4. Maiefski M, Rupp ME, Hermsen ED. Ethanol lock technique: review of the literature. *Infection control and hospital epidemiology. J Soc Hosp Epidemiol Am.* 2009;30:1096-108.
5. O'Grady NP, Alexander M, Burns LA, Dellinger EP, Garland J, Heard SO, et al. Healthcare Infection Control Practices Advisory Committee (HICPAC). Guidelines for the prevention of intravascular catheter-related infections. *Clin Infect Dis.* 2011;52:e162-93.