

cyclophosphamide, adriamycin, vincristine, and prednisone. Another PET/CT study, conducted six months later, showed no evidence of disease (Figure 1D).

Hepatic lymphomas are classified as primary or secondary<sup>(1)</sup>. Secondary lymphomas are due to disseminated lymphoproliferative disease, and the reported incidence of secondary non-Hodgkin lymphoma is 16–22%. Primary lymphomas are rare, accounting for only 0.01% of all cases of non-Hodgkin lymphoma<sup>(1,2)</sup>.

The diagnostic criteria for primary hepatic lymphoma vary in the literature, the most widely used criteria being those proposed by Lei et al.<sup>(1)</sup>: absence of distal lymphadenopathy; absence of bone marrow infiltration or peripheral blood leukocytosis; and laboratory abnormalities related to liver involvement. Caccamo et al.<sup>(2)</sup> included the absence of extrahepatic disease for at least six months after diagnosis. However, some authors have also classified patients with associated regional lymph node disease, splenomegaly, and bone marrow infiltration as having primary hepatic lymphoma, those features being considered indicative of regional extrahepatic evolution<sup>(3–5)</sup>. The etiology is poorly understood, and there have been reports of cases related to viral infections, such as HIV infection, Epstein-Barr virus infection, and hepatitis, as well as to cirrhosis, prior chemotherapy, and primary biliary cirrhosis<sup>(1,6)</sup>. The usual symptoms are those associated with involvement of the liver parenchyma, such as jaundice, abdominal pain, and hepatomegaly<sup>(1)</sup>, similar to those of primary lymphoma described in the literature<sup>(1,3,7)</sup> and well characterized in our patient due to a common bile duct obstruction. Fever, weight loss, and night sweats, also known as “B symptoms”, may be present but are not the rule<sup>(1)</sup>. Elevated levels of canalicular enzymes is a common laboratory finding<sup>(1)</sup>.

The imaging features of primary lymphomas are nonspecific and may be similar to those of other more common liver tumors, such as cholangiocarcinoma<sup>(8)</sup>. High-grade lymphomas usually show restricted diffusion on MRI, similar to what was observed in our patient but also seen in some infectious processes, such as abscess and fungal infections, in patients who are immunocompromised<sup>(8)</sup>, which our patient was not.

According to the current criteria in the literature, our patient had aspects indicative of primary and secondary hepatic lymphoma. Although the biopsy of an enlarged retroperitoneal lymph node was negative for malignancy, the PET/CT scan showed retroperitoneal fluorodeoxyglucose uptake. Although the diagnosis can be made through needle biopsy, it is often made after surgical resection. The standard treatment is systemic chemotherapy<sup>(6,8)</sup>.

## REFERENCES

1. Lei KI, Chow JH, Johnson PJ. Aggressive primary hepatic lymphoma in Chinese patients. Presentation, pathologic features, and outcome. *Cancer*. 1995;76:1336–43.
2. Caccamo D, Pervez NK, Marchevsky A. Primary lymphoma of the liver in the acquired immunodeficiency syndrome. *Arch Pathol Lab Med*. 1986;110:553–5.
3. Osborne BM, Butler JJ, Guarda LA. Primary lymphoma of the liver. Ten cases and a review of the literature. *Cancer*. 1985;56:2902–10.
4. Anthony PP, Sarsfield P, Clarke T. Primary lymphoma of the liver: clinical and pathological features of 10 patients. *J Clin Pathol*. 1990;43:1007–13.
5. Scoazec JY, Degott C, Brousse N, et al. Non-Hodgkin's lymphoma presenting as a primary tumor of the liver: presentation, diagnosis and outcome in eight patients. *Hepatology*. 1991;13:870–5.
6. Ugurluer G, Miller RC, Li Y, et al. Primary hepatic lymphoma: a retrospective, multicenter rare cancer network study. *Rare Tumors*. 2016;8:6502.
7. Steller EJ, van Leeuwen MS, van Hillegersberg R, et al. Primary lymphoma of the liver – a complex diagnosis. *World J Radiol*. 2012;4:53–7.
8. Tomasian A, Sandrasegaran K, Elsayes KM, et al. Hematologic malignancies of the liver: spectrum of disease. *Radiographics*. 2015;35:71–86.

**Gustavo Gomes Mendes<sup>1,a</sup>, Leonardo Verza<sup>1,b</sup>, Tércia Neves<sup>1,c</sup>, Eduardo Nóbrega Pereira Lima<sup>1,d</sup>, Rubens Chojniak<sup>1,e</sup>**

1. A.C.Camargo Cancer Center, São Paulo, SP, Brazil.

Correspondence: Dr. Leonardo Verza. A.C.Camargo Cancer Center – Departamento de Imagem. Rua Professor Antônio Prudente, 211, Liberdade. São Paulo, SP, Brazil, 01509-010. Email: leoverza9@gmail.com.

a. <https://orcid.org/0000-0001-5630-7966>; b. <https://orcid.org/0000-0002-1287-6056>; c. <https://orcid.org/0000-0002-9209-0300>; d. <https://orcid.org/0000-0003-1608-6964>; e. <https://orcid.org/0000-0002-8096-252X>.

Received 10 August 2017. Accepted after revision 9 October 2017.

<http://dx.doi.org/10.1590/0100-3984.2017.0134>



## Mounier-Kuhn syndrome: an unusual cause of bronchiectasis

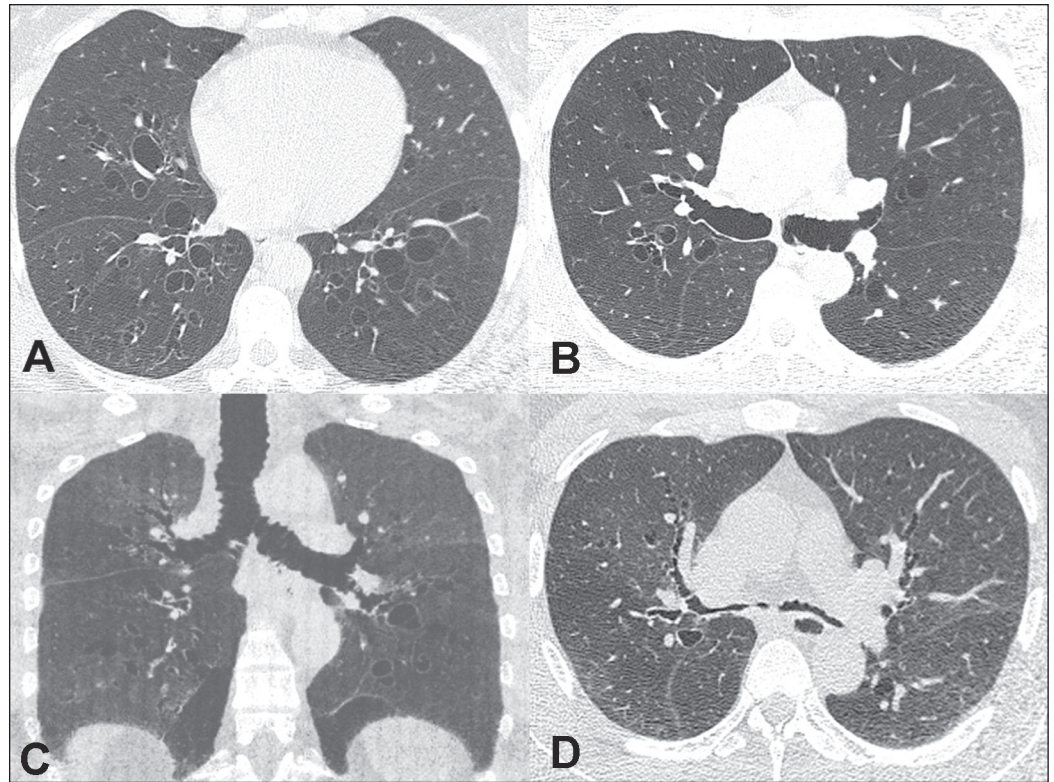
Dear Editor,

A 49-year-old nonsmoking man presented with a six-year history of recurrent infections of the lower respiratory tract, having been asymptomatic between the episodes. The initial physical examination showed that the patient was in good general health, with a blood pressure of 120/80 mmHg, normal cardiac auscultation findings, a heart rate of 77 bpm, pulmonary auscultation showing sparse rales, a respiratory rate of 18 breaths/min, oxygen saturation of 93% on room air, and a normal abdomen. A computed tomography (CT) scan of the chest, acquired during inspiration (Figures 1A, 1B, and 1C), showed dilatation of the trachea and main bronchi (transverse diameter of 3.5 cm and 1.8 cm, respectively), as well as bronchiectasis in the middle and lower regions of both lungs. A slice acquired during expiration (Figure 1D) demonstrated partial collapse of the trachea and main bronchi. The pattern seen on CT was considered to be diagnostic of tracheobronchomegaly. Spirometry produced the following results before and after bronchodilator administration, respectively: FVC, 87% and 88%; FEV<sub>1</sub>, 69% and 75%; FEV<sub>1</sub>/FVC ratio, 64% and 69%; and FEF, 44% and 52%. The

patient was treated with corticosteroids and bronchodilators. At this writing, he is in outpatient follow-up.

The importance of tracheobronchial diseases has been emphasized in recent studies<sup>(1–4)</sup>. Tracheobronchomegaly, or Mounier-Kuhn syndrome, is a rare disease, observed mainly in middle-aged men before the fifth decade of life<sup>(5)</sup>, that is characterized by atrophy or the absence of elastic fibers or smooth muscle in the wall of the trachea and the main bronchi, resulting in dilatation of those structures<sup>(6–8)</sup>. It is believed that the weakness of connective tissue, associated with the inhalation of air pollutants and smoking, is the main factor in the development of this condition<sup>(6)</sup>. Because of those anatomical and physiological changes, the flaccid airways widen during inspiration and collapse during expiration<sup>(6)</sup>; in addition to that dynamic change, bronchial or tracheal diverticulosis and bronchiectasis are common<sup>(7,8)</sup>.

The clinical presentation of Mounier-Kuhn syndrome is nonspecific, including the accumulation of secretions, with productive cough, dyspnea, and recurrent infections of the lower respiratory tract. In rare cases, there can be hemoptysis or pneumothorax<sup>(6–8)</sup>. The diagnosis is made on the basis of imaging findings. The most sensitive examination is CT of the trachea and main bronchi, with images acquired during inspiration and



**Figure 1.** A,B: CT scan of the chest, acquired during inspiration, showing bilateral bronchiectasis, together with marked dilatation of the main bronchi. C: Coronal reconstruction showing, in addition to the bronchiectasis, dilatation of the main bronchi and the trachea. D: Slice acquired during expiration, showing near-total collapse of the bronchial tree.

expiration<sup>(7,8)</sup>. The treatment is generally supportive, including respiratory therapy, appropriate antibiotic therapy for the recurrent infections, and smoking cessation<sup>(9,10)</sup>.

In conclusion, Mounier-Kuhn syndrome should be considered in patients who present with bronchiectasis accompanied by abnormal dilatation of the trachea and the main bronchi. The preferred diagnostic imaging method is CT of the chest.

**REFERENCES**

1. Togni Filho PH, Casagrande JLM, Lederman HM. Utility of the inspiratory phase in high-resolution computed tomography evaluations of pediatric patients with bronchiolitis obliterans after allogeneic bone marrow transplant: reducing patient radiation exposure. *Radiol Bras.* 2017;50:90–6.
2. Duarte ML, Brito MCB, Traple FAL, et al. Plasmacytoma of the trachea: a surprising diagnosis. *Radiol Bras.* 2017;50:66–7.
3. Torres PPTS, Rabahi M, Pinto AS, et al. Primary tracheobronchial amyloidosis. *Radiol Bras.* 2017;50:267–8.
4. Brito MCB, Ota MK, Leitão Filho FSS, et al. Radiologist agreement on the quantification of bronchiectasis by high-resolution computed tomography *Radiol Bras.* 2017;50:26–31.
5. Woodring JH, Howard RS 2nd, Rehm SR. Congenital tracheobronchomegaly (Mounier-Kuhn syndrome): a report of 10 cases and review of the literature. *J Thorac Imaging.* 1991;6:1–10.

6. Menon B, Aggarwal B, Iqbal A. Mounier-Kuhn syndrome: report of 8 cases of tracheobronchomegaly with associated complications. *South Med J.* 2008;101:83–7.
7. Shin MS, Jackson RM, Ho KJ. Tracheobronchomegaly (Mounier-Kuhn syndrome): CT diagnosis. *AJR Am J Roentgenol.* 1988;150:777–9.
8. Marchiori E, Sousa AS Jr, Zanetti G, et al. Mounier-Kuhn syndrome: the role of bronchiectasis in clinical presentation. *Ann Thorac Med.* 2012;7:51.
9. Collard L, Freitag L, Reynaert MS, et al. Respiratory failure due to tracheobronchomalacia. *Thorax.* 1996;51:224–6.
10. Falconer M, Collins DR, Feeney J, et al. Mounier-Kuhn syndrome in an older patient. *Age Ageing.* 2008;37:115–6.

**Rômulo Florêncio Tristão Santos<sup>1,a</sup>, Tiago Kojun Tibana<sup>1,b</sup>, Isa Félix Adôrnio<sup>1,c</sup>, Edson Marchiori<sup>2,d</sup>, Thiago Franchi Nunes<sup>1,e</sup>**

1. Universidade Federal de Mato Grosso do Sul (UFMS), Campo Grande, MS, Brazil. 2. Universidade Federal do Rio de Janeiro (UFRJ), Rio de Janeiro, RJ, Brazil.

Correspondence: Dr. Edson Marchiori. Rua Thomaz Cameron, 438, Valparaíso. Petrópolis, RJ, Brazil, 25685-120. Email: edmarchiori@gmail.com.

a. 0000-0002-8679-7369; b. 0000-0001-5930-1383; c. 0000-0002-2106-1211; d. 0000-0001-8797-7380; e. 0000-0003-0006-3725.

Received 19 September 2017. Accepted after revision 9 October 2017.

<http://dx.doi.org/10.1590/0100-3984.2017.0167>



**Gorham-Stout syndrome: the radiologic-pathologic correlation as a diagnostic pathway when bone is vanishing**

Dear Editor,

A 34-year-old previously healthy man presented with a 12-month history of progressive polyarthralgia and edema of the hips, right ankle, and intercostal spaces. He reported no history of trauma. Conventional radiography revealed several mixed lesions (predominantly osteolytic lesions) in the pelvic ring,

proximal femur, distal femur, distal tibia, both tali, and lumbar vertebral bodies, as well as unconsolidated fractures of the costal arches, with no periosteal reaction or associated soft tissue changes (Figure 1). The initial hypotheses of multifocal osteolysis were secondary osteolytic conditions such as infection, cancer (primary or metastatic), inflammatory disorders, and endocrine disorders. The results of laboratory tests (complete blood count, protein profiles, parathyroid hormone level, ionic calcium level, and phosphate level) were normal, as were those