



REVISTA BRASILEIRA DE ANESTESIOLOGIA

Official Publication of the Brazilian Society of Anesthesiology
www.sba.com.br



CLINICAL INFORMATION

The development of ventricular fibrillation due to etomidate for anesthetic induction: a very rare side effect, case report

Murat Karcioğlu^{a,*}, Isil Davarci^a, Nuray Kirecci^a, Adnan Burak Akcay^b,
Selim Turhanoglu^a, Kasim Tuzcu^a, Sedat Hakimoglu^a, Seckin Akkucuk^c, Akin Aydogan^c

^a Department of Anesthesiology and Reanimation, Faculty of Medicine, Mustafa Kemal University, Hatay, Turkey

^b Department of Cardiology, Faculty of Medicine, Mustafa Kemal University, Hatay, Turkey

^c Department of General Surgery, Faculty of Medicine, Mustafa Kemal University, Hatay, Turkey

Received 28 February 2013; accepted 10 June 2013

Available online 16 October 2013

KEYWORDS

Etomidate;
Induction of
anesthesia;
Ventricular
fibrillation

Abstract

Background and objectives: Ventricular fibrillation occurring in a patient can result in unexpected complications. Here, our aim is to present a case of ventricular fibrillation occurring immediately after anesthesia induction with etomidate administration.

Case report: A fifty-six-year-old female patient with a pre-diagnosis of gallstones was admitted to the operating room for laparoscopic cholecystectomy. The induction was performed by etomidate with a bolus dose of 0.3 mg/kg. Severe and fast adduction appeared in the patient's arms immediately after induction. A tachycardia with wide QRS and ventricular rate 188 beat/min was detected on the monitor. The rhythm turned to VF during the preparation of cardioversion. Immediately we performed defibrillation to the patient. Sinus rhythm was obtained. It was decided to postpone the operation due to the patient's unstable condition.

Conclusion: In addition to other known side effects of etomidate, very rarely, ventricular tachycardia and fibrillation can be also seen. To the best of our knowledge, this is the first case regarding etomidate causing VF in the literature.

© 2013 Sociedade Brasileira de Anestesiologia. Published by Elsevier Editora Ltda. All rights reserved.

PALAVRAS-CHAVE

Etomidato;
Indução da anestesia;
Fibrilação ventricular

Desenvolvimento de fibrilação ventricular por causa de etomidato para indução anestésica: um efeito colateral muito raro, relato de caso

Resumo

Justificativa e objetivos: A ocorrência de fibrilação ventricular em um paciente pode resultar em complicações inesperadas. Nosso objetivo é apresentar um caso de fibrilação ventricular que ocorreu após a indução anestésica com administração de etomidato.

* Corresponding author.

E-mail: muratkarcioğlu@hotmail.com (M. Karcioğlu).

Relato de caso: Paciente do sexo feminino, 56 anos, com pré-diagnóstico de cálculos biliares, foi admitida na sala de cirurgia para colecistectomia laparoscópica. A anestesia foi induzida com a administração de etomidato com uma dose em bolus de 0,3 mg/kg. A paciente apresentou uma grave e rápida adução dos braços logo após a indução. Taquicardia com QRS largo e frequência ventricular de 188 bpm foram detectadas no monitor. O ritmo converteu-se em fibrilação ventricular (FV) durante a preparação para a cardioversão. A paciente foi imediatamente submetida a desfibrilação. O ritmo sinusal foi obtido. Decidimos adiar a cirurgia por causa da condição de instabilidade da paciente.

Conclusão: Além dos efeitos secundários conhecidos de etomidato, taquicardia ventricular e fibrilação, embora muito raramente, também podem ser observadas. Até onde sabemos, esse é o primeiro caso na literatura de FV causado por etomidato.

© 2013 Sociedade Brasileira de Anestesiologia. Publicado por Elsevier Editora Ltda. Todos os direitos reservados.

Introduction

Ventricular fibrillation (VF) is a cardiac pathology in which the ventricle is completely chaotic and does not contract effectively. VF can cause very serious endpoints. Etomidate is a hypnotic agent that has a stable cardiovascular profile and results in minimal respiratory side effects. For this reason, it is commonly preferred for the induction of anesthesia in hemodynamically unstable patients.¹

The reported side effects related to etomidate are myoclonus, vomiting, pain on injection site, and adrenocortical suppression.²

In rare cases, other adverse effects regarding etomidate have been mentioned. In the current report, we aimed to present a case in which VF developed during induction with etomidate in a patient underwent laparoscopic cholecystectomy due to gallstones. In the literature, this is the first report investigating this association.

Case report

A fifty-six-year-old female patient with a pre-diagnosis of gallstones was admitted to the operating room for laparoscopic cholecystectomy. The patient's history of hypertension with the irregular use of an antihypertensive drug was known during the pre-anesthesia evaluation. Routine biochemical and hematological tests were normal. ECG was in normal sinus rhythm (Fig. 1), heart rate was 74 beats/min, PA chest X-ray was normal, and considered ASA II. The patient was monitored, and the initial arterial blood pressure (BP): 140/110 mmHg, heart rate: 118 beats/min, presence of sinus tachycardia rhythm, and peripheral oxygen saturation (SpO₂): 98% were detected.

The induction was performed by etomidate (ETOMIDATE Lipuro® B. Braun Melsungen AG, Berlin-GERMANY) with a bolus dose of 0.3 mg/kg. Severe and fast adduction appeared in the patient's arms immediately after induction. Myoclonic

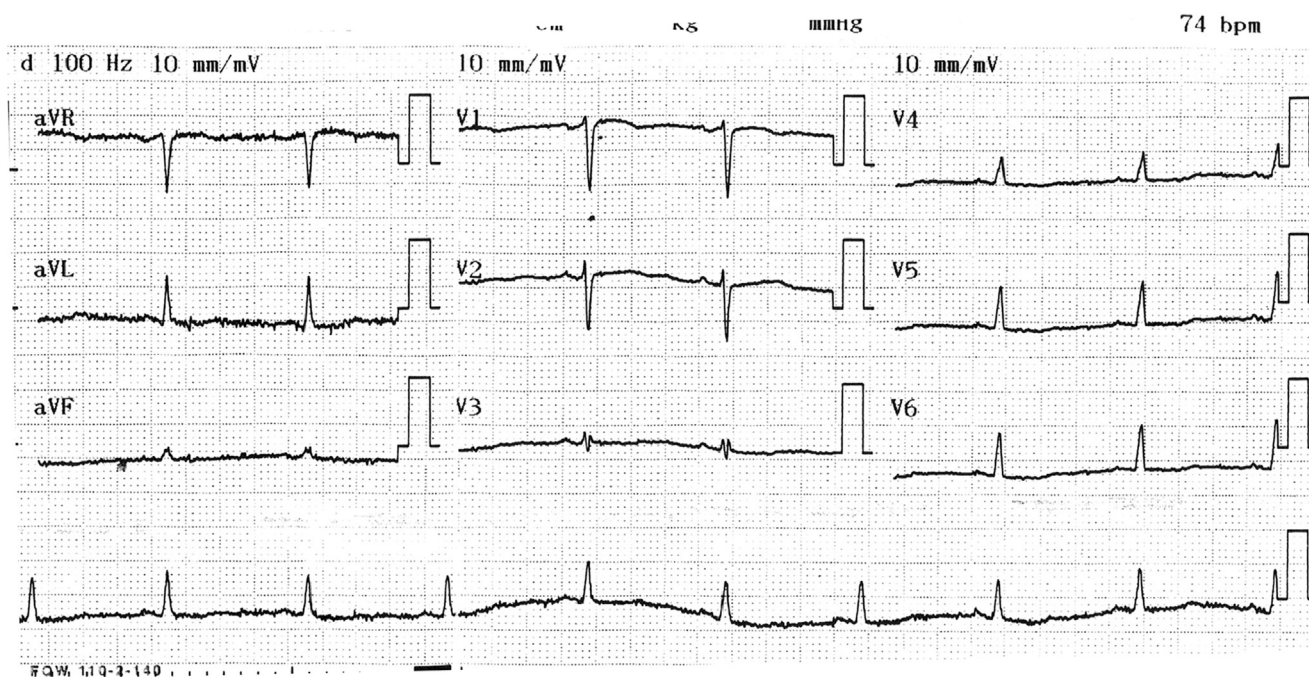


Figure 1 Preanesthetic ECG Image.

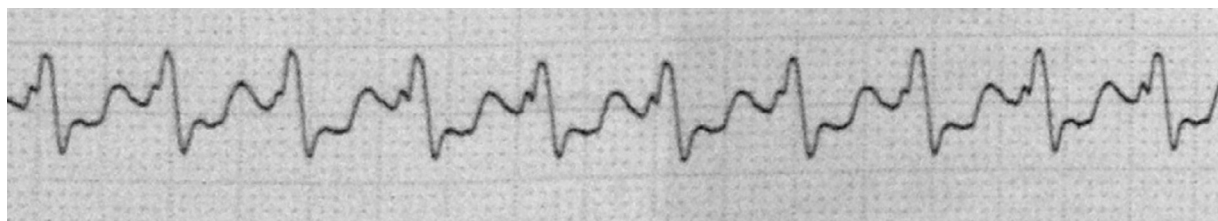


Figure 2 VT Image.

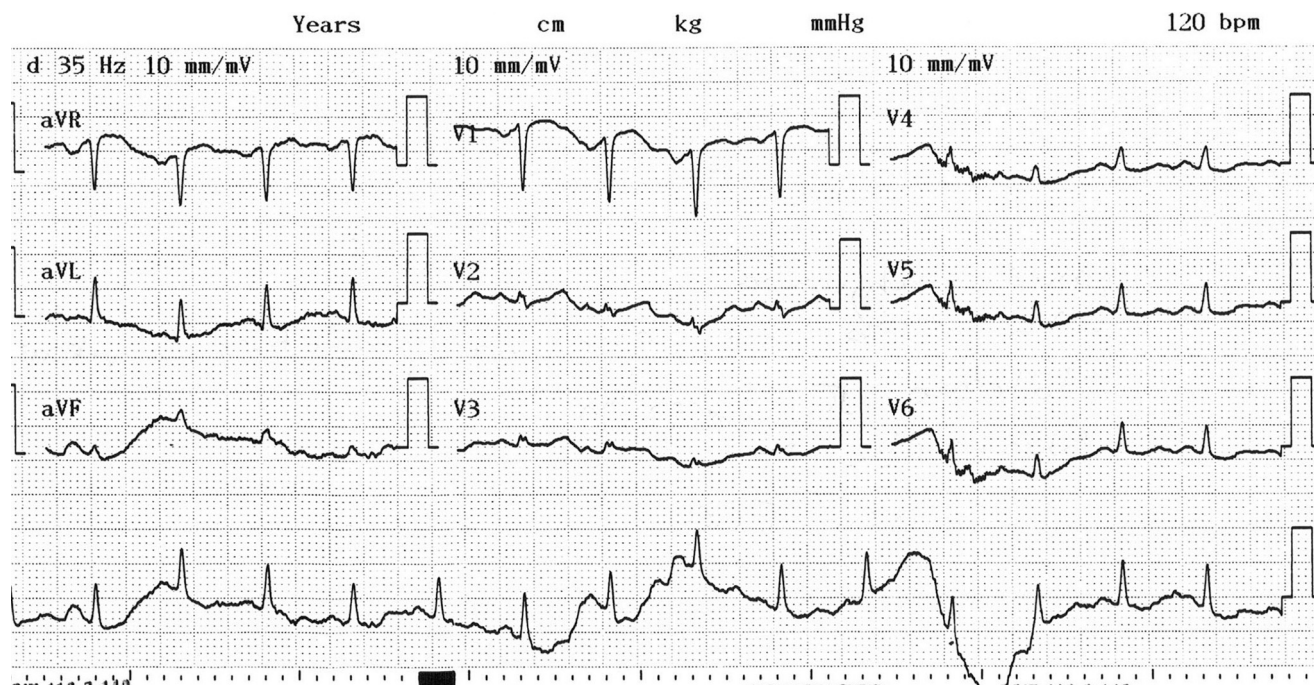


Figure 3 Postextubation ECG image.

movements were considered to be due to etomidate and a dose of 0.6 mg/kg rocuronium (Esmeron® N.V. Organon Oss, Netherlands) was given. At this time, BP was 150/110 mmHg, SpO₂ was 98%, heart rate was 110–130 beats/min, and the heart rate increased gradually. A tachycardia with wide QRS and ventricular rate 188 beat/min was detected on the monitor (Fig. 2). Blood pressure was seen as decreased to 90/60 mmHg. The rhythm turned to VF during the preparation of cardioversion. Immediately we performed defibrillation to the patient (biphasic shock with 200 J). Sinus rhythm was obtained. We decided to give amiodarone to the patient to avoid recurrent VT.

A 150 mg of IV amiodarone (Cordarone® Mefar Istanbul, Turkey) loading dose was applied within 15 min and was followed by maintenance therapy. It was decided to postpone the operation due to the patient's unstable condition.

Anesthesia was maintained with oxygen, air, sevoflurane (Sevorane® Abbott Laboratories Ltd., UK) and fentanyl (Fentanyl® Janssen N.V., Belgium). Thirty-seven minutes after the induction of anesthesia, the patient started to breathe spontaneously and extubation was proposed. The patient was extubated and admitted to the intensive care unit (ICU). A cardiology consultation was made in ICU. On patient echocardiography, Left ventricle (LV)

diameters were normal, systolic function was adequate, Left atrium (LA) dilatation was (4.1 cm), 1+ mitral regurgitation and 2–3+ tricuspid regurgitation were noted, pulmonary hypertension was present (35–40 mmHg), and ejection fraction (EF) was evaluated as 63%. Sinus tachycardia (120 beats/min) and nonspecific ST changes in the patient's ECG (Fig. 3) were found by the cardiologists. Hematological, biochemical, thyroid function tests were within normal limits.

The patient was discharged after three days following up in the ICU. Two weeks later, the patient was admitted for the laparoscopic cholecystectomy. The patient was operated without any complication, with the induction by thiopental, fentanyl and rocuronium, and sent home.

Discussion

During VF, the ventricle contractions are completely unsynchronized and ineffective. The heart cannot provide an effective cardiac output (CO). The rhythm is irregular, QRS complex is invisible, and circulation cannot be achieved because of the lack of Effective CO. Cardiopulmonary resuscitation should be initiated immediately.

Encountering unpredicted disorders are common during anesthesia induction, the maintenance of anesthesia, and awakening from anesthesia. In this case, we reported a process of ventricular tachycardia and fibrillation occurring immediately after the induction of anesthesia with etomidate. The well-known side effects of etomidate are myoclonus, pain on injection site, and adrenal suppression. The mechanism of myoclonus is not clear, though it is a form of seizure activity. High doses of etomidate depress cortical activity before than subcortical activity, and researchers have proposed that this is a disinhibition phenomenon.^{3,4} Subcortical neuronal activity inhibitor drugs such as benzodiazepines and opioids prevent the development of myoclonus.⁵

Etomidate injection has side effects in terms of pain and myoclonus because it is formulated with propylene glycol.^{6,7} However, an alternate pharmaceutical formulation exists to reduce the pain of injection. In this new formulation, etomidate is dissolved in a fat emulsion composed of medium and long chain triglycerides.⁸ In a study, using only a single bolus dose of etomidate cause adrenal dysfunction in aspect of hypocortisolemia.⁹ This impaired function results in a transient and clinically insignificant effect on adrenal gland.^{7,9} In some cases, adrenal dysfunction can be very important. Therefore practitioners must be aware of this information regarding the drug.

Case reports related to adrenal adverse effects with etomidate are common. However, the cardiovascular side effects are found in only one report associated with the drug. Etomidate typically does not alter myocardial contractility and cardiac output.¹⁰ Fideler et al. reported a case of thyrotoxicosis occurring after applying amiodarone treatment to a patient with heart failure and suffering from atrial fibrillation for the first time. Thyroidectomy was planned when hyperthyroidism was unresponsive to medical treatment. The staff noted decreased blood pressure after induction with etomidate, sufentanil and rocuronium, and norepinephrine infusion was started before the patient had VF followed by cardiac arrest.¹¹ In our case, the patient's thyroid function tests were normal and no significant cardiac pathology was detected except for the development of sinus tachycardia and a slight rise in blood pressure prior to induction in the operating room. The injection of etomidate was considered to be the only probable etiology for the development of VT and VF.

When etomidate and VF were investigated using the FDA Adverse Event Reporting System (FAERS), a total of 4 VF events had been reported for etomidate.¹²

According to another source, 1023 cases of etomidate-related adverse effects have been found. Among them, VF was reported in 23 patients (2.25%). Of these cases, 72.7% were females, 27.3% were males, 22.7% were in the range of 0–1 years old, 13.6% in the range of 20–29 years old,

4.5% in the range of 30–39 years old, 27.3% in the range of 50–59 years old, 31.8% percent over the age of 60 years. The drugs used in these patients with VF were Sufentanil citrate, Propofol, Fentanyl, Rocuronium bromide, and Amiodarone HCL.¹³

As a result, it is suggested that the development of VF in this case, after the exclusion of the probable etiologies may be due to the induction with etomidate. To the best of our knowledge, this is the first case regarding etomidate causing VF in the literature. We aimed to report that following induction with etomidate VF can occur in rare cases, and early diagnosis and immediate intervention with close follow-up are required to achieve positive outcomes in these patients.

Conflicts of interest

The author declares no conflicts of interest.

References

- Gultop F, Akkaya T, Bedirli N, et al. Lidocaine pretreatment reduces the frequency and severity of myoclonus induced by etomidate. *J Anesth.* 2010;24:300–2.
- Ruth WJ, Burton JH, Bock AJ. Intravenous etomidate for procedural sedation in emergency department patients. *Acad Emerg Med.* 2001;8:13–8.
- Doenicke AW, Roizen MF, Kugler J, et al. Reducing myoclonus after etomidate. *Anesthesiology.* 1999;90:113–9.
- Reddy RV, Moorthy SS, Dierdorf SF, et al. Excitatory effects and electroencephalographic correlation of etomidate, thiopental, methohexital, and propofol. *Anesth Analg.* 1993;77:1008–11.
- Modica PA, Tempelhoff R, White PF. Pro- and anticonvulsant effects of anesthetics (Part II). *Anesth Analg.* 1990;70:433–44.
- Doenicke AW, Roizen MF, Hoernecke R, et al. Solvent for etomidate may cause pain and adverse effects. *Br J Anaesth.* 1999;83:464–6.
- Nyman Y, Von Hofsten K, Palm C, et al. Etomidate-Lipuro is associated with considerably less injection pain in children compared with propofol with added lidocaine. *Br J Anaesth.* 2006;97:536–9.
- Cameron E, Johnston G, Crofts S, et al. The minimum effective dose of lignocaine to prevent injection pain due to propofol in children. *Anaesthesia.* 1992;47:604–6.
- Kulstad EB, Kalimullah EA, Tekwani KL, et al. Etomidate as an induction agent in septic patients: red flags or false alarms? *West J Emerg Med.* 2010;11:161–72.
- Morgan GE, Michael SM, Murray JM, et al. *Clinical anesthesiology.* 3rd ed. New York: Mc Graw Hill; 2002.
- Fideler FJ, Dieterich HJ, Schroeder TH. Fatal outcome during anaesthesia induction in a patient with amiodarone-induced thyrotoxicosis. *Eur J Anaesthesiol.* 2008;25:337–9.
- Drugcite. See drug side effects reported to the FDA by people like you.
- Real world drug outcomes A cloud computing service for drugs.