



# REVISTA BRASILEIRA DE ANESTESIOLOGIA

Official Publication of the Brazilian Society of Anesthesiology  
[www.sba.com.br](http://www.sba.com.br)



## CLINICAL INFORMATION

### Anaesthesia for infant with Jarcho Levin syndrome: case report

Sukran Geze<sup>a,\*</sup>, Ufuk Arslan<sup>a</sup>, Mustafa Tusat<sup>b</sup>

<sup>a</sup> Department of Anesthesiology and Critical Care, Faculty of Medicine, Karadeniz Technical University, Trabzon, Turkey

<sup>b</sup> Department of Pediatric Surgery, Faculty of Medicine, Karadeniz Technical University, Trabzon, Turkey

Received 24 September 2012; accepted 19 December 2012

Available online 16 October 2013

#### KEYWORDS

Anaesthesia;  
infant;  
Jarcho Levin  
syndrome

**Abstract** Jarcho Levin syndrome is a rare disorder. There are various vertebral and costal anomalies. Severe deformities and abnormal fusion of ribs and vertebrae cause respiratory insufficiency and pneumonia. We present anaesthesia in a patient with Jarcho Levin syndrome for vesicoureteral reflux.

© 2013 Sociedade Brasileira de Anestesiologia. Published by Elsevier Editora Ltda. All rights reserved.

#### PALAVRAS-CHAVE

Anestesia;  
Criança;  
Síndrome de  
Jarcho-Levin

#### Anestesia em criança com síndrome de Jarcho-Levin: relato de caso

**Resumo** A síndrome de Jarcho-Levin é um distúrbio raro que apresenta várias anomalias vertebrais e costais. Deformidades graves e fusões anormais das costelas e vértebras causam insuficiência respiratória e pneumonia. Apresentamos um caso de anestesia em paciente com síndrome de Jarcho-Levin para refluxo vesicouretral.

© 2013 Sociedade Brasileira de Anestesiologia. Publicado por Elsevier Editora Ltda. Todos os direitos reservados.

## Introduction

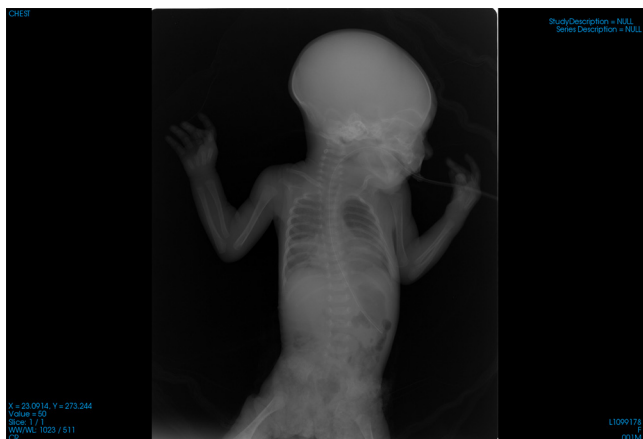Jarcho Levin syndrome is a rare disorder first described by Jarcho and Levin in 1938.<sup>1</sup> The prevalence is 0.25/10,000.<sup>2</sup> Vertebral anomalies are the forefront features of Jarcho Levin syndrome. There are various vertebral and costal anomalies. Hemivertebra, vertebral agenesis, butterfly vertebrae, hypoplastic vertebrae and costovertebral fusion defects are frequently encountered.<sup>2,3</sup> Neural tube defects,

cardiovascular, genitourinary, and parenchymal organ disorders may accompany in Jarcho Levin syndrome.

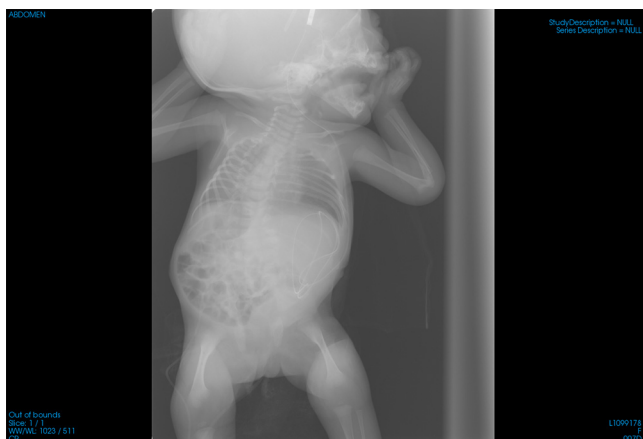
Hydrocephalus, hydronephrosis, meningomyelocele, atrial septal defect, ventricular septal defect, renal agenesis–hypoplasia, polycystic kidney, anal atresia, diaphragmatic herniation, oesophageal fistula, Meckel diverticula, biphidius uvula are among the reported anomalies.<sup>4</sup> Severe deformities and abnormal fusion of ribs and vertebrae cause respiratory insufficiency and recurrent respiratory tract infections.<sup>5</sup> There is not any literature to anaesthesia in Jarcho Levin syndrome. We present our anaesthesia method in a patient with Jarcho Levin syndrome who underwent operation for vesicoureteral reflux with accompanying vertebral anomalies, hydrocephalus, patent foramen ovale and secundum atrial septal defect.

\* Corresponding author.

E-mails: [drgez@yaho.com](mailto:drgez@yaho.com), [gez@hotmai.com](mailto:gez@hotmai.com) (S. Geze).



**Figure 1** There are costovertebral fusion defects in right 6–10 and left 7–10 ribs.



**Figure 2** Butterfly vertebrae anomaly exists in thoracic vertebrae.

## Case

The patient was two-month-old female infant of 6 kg weight. The patient was born via spontaneous vaginal delivery with 2900g birth weight from 29-year-old mother's second pregnancy. The patient had the diagnosis of Jarcho Levin syndrome. Patent foramen ovale, secundum atrial septal defect and hydrocephalus in addition to vertebral and costal anomalies had been detected in the follow up period (Figs. 1 and 2). An operation was planned for the patient with the indication of vesicoureteral reflux. Bilateral rales were auscultated in the preoperative physical examination. A systolic murmur was detected in the cardiovascular examination. The patient had grade 3 mallampati score. Sensorial and motor functions were normal in the neurological examination. Routine preoperative laboratory tests were normal. The patient was monitored by electrocardiography and peripheral oxygen saturation in the operation room. Arrangements were made for the patient with difficult airway before general anaesthesia. Because the mask ventilation was normal, mask induction with oxygen and sevoflurane was performed. Intravenous remifentanyl 0.5  $\mu\text{g}/\text{kg}$  was administered. Lidocaine 1 mg/kg was applied to inhibit airway reflex. LMA of size 1 inserted.

The anaesthesia was maintained with sevoflurane of 2.5–3% concentration, 50% oxygen, 50% nitrous oxide. Soon after the onset of operation, through closure of  $\text{NO}_2$ , additional remifentanyl of 0.5  $\mu\text{g}/\text{kg}$  was administered. Suppository paracetamol after induction of anaesthesia and intravenous tramadol of 0.5 mg/kg postoperatively were administered to maintain postoperative analgesia. After 45 min follow up at the postoperative care unit the patient was transferred to paediatric surgery clinic.

## Discussion

Jarcho Levin syndrome is a rare congenital disorder characterized by distinctive vertebral anomalies. Vertebral anomalies and defects in the costovertebral fusion result in a smaller thoracic cavity and respiratory insufficiency. Patients frequently experience serious respiratory problems due to pneumonia or restrictive type lung disease at most cases leading to early mortality.<sup>2,5</sup> Also central airway anomalies are encountered in this syndrome. Smaller thoracic cavity and inadequate lung maturation, lower respiratory tract infections and airway problems complicate anaesthesia required for any kind of operation in child patients with Jarcho Levin syndrome.<sup>6</sup> The patient had severe vertebral anomalies in our case (Figs. 1 and 2). The patient had recovered postnatal pneumonia but inspiratory rales and secretions in the respiratory tract still persisted. Induction was performed by mask inhalation and the surgical operation was performed under LMA anaesthesia without the need for intubation. Because the patient was not intubated, muscle relaxant was avoided minimizing the likely complications in the postoperative period. LMA was first discovered in 1980 and had a widespread use thereafter in anaesthesia practice. It has been used with success particularly in patients difficult to intubate.<sup>7–10</sup> In our case, LMA was used for general anaesthesia for the patient who underwent operation for vesicoureteral reflux due to hydronephrosis. Short acting anaesthetic and analgesic agents in LMA anaesthesia was advantageous for the safety of anaesthesia in our case. There was no respiratory compromise postoperatively. There are reports in the literature indicating that LMA ensures satisfactory airway for patients undergoing general anaesthesia.

In our clinic, LMA anaesthesia had previously been performed with success for a patient with Pierre-Robin syndrome undergoing tracheotomy. In literature, LMA was shown to be performed with comfort and success in patients difficult to intubate. Hara et al. reported that LMA was a promising anaesthesia method for a patient with CHARGE syndrome with airway anomalies.<sup>10</sup> We could not find data relevant to anaesthesia in Jarcho Levin syndrome in literature. We suppose that the lack of literature data is due to the poor prognosis of the disease because of respiratory insufficiency leading to early mortality in the infantile period rendering any operation under general anaesthesia impossible. Recently more developed medical care has improved the prognosis of Jarcho Levin syndrome and the patients had the chance of operation indicated for various problems. LMA was evaluated as a promising anaesthesia method for our patient with Jarcho Levin syndrome.

## Conflicts of interest

The authors declare no conflicts of interest.

## References

1. Jarcho S, Levin PM. Hereditary malformation of the vertebral bodies. *Johns Hopkins Med J.* 1938;62:216–26.
2. Teli M, Hosalkar H, Gill I, Noordeen H. Spondylocostal dysostosis. *Spine.* 2004;29:1447–51.
3. Bannykh SI, Emery SC, Gerber JK. Aberrant Pax1 and Pax9 expression in Jarcho–Levin syndrome: report of two Caucasian siblings and literature review. *Am J Med Genet.* 2003;120:241–6.
4. Kansal R, Mahore A, Kukreja S. Jarcho–Levin syndrome with diastematomyelia: a case report and review of literature. *J Pediatr Neurosci.* 2011;6:141–3.
5. Roberts AP, Conner AN, Tolmie JL, et al. Spondylothoracic and spondylocostal dysostosis. *J Bone Joint Surg Br.* 1988;70:123–6.
6. Schulman M, Gonzalez MT, Bye MR. Airway abnormalities in Jarcho–Levin syndrome: a report of two cases. *J Med Genet.* 1993;30:875–6.
7. Brain AIJ. The laryngeal mask airway: a possible new resolution to airway problems in the emergency situation. *Arch Emerg Med.* 1984;1:229–32.
8. Geze S, Cekic B, Ulusoy H, Erturk E. The use of laryngeal mask airway for surgical tracheotomy in a neonate with Pierre Robin syndrome: a case report. *Ir J Med Sci.* 2011;180:297–8.
9. Hara Y, Hirota K, Fukuda K. Successful airway management with use of a laryngeal mask airway in a patient with CHARGE syndrome. *J Anesth.* 2009;23:630–2 [Epub November 2009].
10. Kiernan F, Crowe S. Safe use of the classic laryngeal mask airway and endotracheal intubation in general anaesthesia for a patient with Mowat–Wilson syndrome. *Paediatr Anaesth.* 2009;19:174–5.