



■ Author(s)

Yavuz O^I
Özdemir Ö^{II}
Ortatatlı M^{III}
Atalay B^{III}
Hatipoglu F^{III}
Terzi F^{III}

^I Aksaray University, Faculty of Veterinary Medicine, Department of Pathology, Aksaray/TURKEY

^{II} Selçuk University, Faculty of Veterinary Medicine, Department of Pathology, Konya/TURKEY

^{III} Batman University, Vocational High School of Health Services, Batman/TURKEY

■ Mail Address

Corresponding author e-mail address
Yavuz Orhan
Aksaray University, Faculty of Veterinary Medicine, Department of Pathology, 68100 PBX /Aksaray/TURKEY.
Tel: +903822882940
Email: vetorhanyavuz@gmail.com

■ Keywords

Aflatoxin, glucomannan, histopathology, quail.

The Preventive Effects of Different Doses of Glucomannan on Experimental Aflatoxicosis in Japanese Quails

ABSTRACT

This experimental study was performed to investigate whether there is a protective effect of different doses of Glucomannan using against aflatoxicosis in Japanese quail, and pathological changes and relative organ weights were compared.

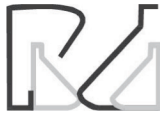In the experiment, 60 one-day old male Japanese quails were used as divided into six different groups. Experimental groups were designated as Control(C), aflatoxin(A), glucomannan(GM), 2-fold dose of glucomannan(2GM), aflatoxin+glucomannan(A+GM) and aflatoxin+2-fold dose of glucomannan(A+2GM). While control group quails fed the standard ration as ad libitum, other groups were fed with the administrations additionally to standard diet respectively; 2mg/kg of aflatoxin to group A, 1g/kg of glucomannan to group GM, 2g/kg of glucomannan to group 2GM, 2mg/kg of aflatoxin and 1g/kg glucomannan to group A+GM, 2mg/kg of aflatoxin and 2g/kg glucomannan to group A+2GM. All quails were euthanized at day 21 of the study and organs, (liver, spleen, kidney, thymus and bursa of Fabricius) were removed, weighed and subjected to routine histopathological procedures.

Although any important macroscopic changes were not observed in the C, GM and 2GM groups, significant pathological changes were found in the groups of A, A+GM and A+2GM. In the A+GM group, the partial reduction in the severity of microscopic lesions were seen in liver, bursa of Fabricius, thymus and spleen, however a significant reduction in severity of lesions was noticed in A+2GM group.

As a result of the study, 2g/kg of glucomannan has been found pathologically to be more effective than 1g/kg glucomannan in terms of the protection against aflatoxicosis by giving orally.

INTRODUCTION

Aflatoxins (AF) are toxic metabolites produced by fungi, such as *Aspergillus flavus* and *Aspergillus parasiticus*, and are considered to be the most harmful mycotoxins as they are highly toxic to animals and humans (Kaya, 1989; Hoerr, 2003). There are six different kinds of aflatoxins: B1, B2, G1, G2, M1, M2. Aflatoxin B1 (AFB1) is accepted as the most harmful, as well as most common metabolite in feeds and foods (Hatch, 1988). Aflatoxicosis in quails has been thoroughly investigated by many scientists, and was shown to be as economically important for quail production as for that of other poultry (Parlat *et al.*, 2001; Oliveira *et al.*, 2002; Oguz & Parlat, 2004; Sehu *et al.*, 2005; Cengiz *et al.*, 2008). Aflatoxins impair performance parameters, such as feed conversion ratio, body weight gain, egg production, and growth rate in all poultry species (Erdeger, 2002). Similarly, it has been reported that AF have adverse effects on the growth performance and health



of quails, and as well as carcinogenic and mutagenic effects (Parlat *et al.*, 2001).

When orally ingested with water and feed, AF are absorbed in the digestive tract and are bound to serum albumin. Circulating AF are largely metabolized in the liver. Part of the AF bind to macromolecules, such as endoplasmic steroids and enzymes in the hepatocytes, whereas the remaining part is converted into fat – and water – soluble metabolites. AF itself is actually harmless, but its metabolization in the liver through cytochrome P-450, produces epoxide derivatives. After this stage, AF acquires toxic properties and plays a role in the inhibition of DNA, RNA, and protein synthesis in liver. In addition, its binding to several macromolecules causes cytotoxic, carcinogenic and teratogenic effects (Abdel-Wahhab & Aly, 2005). In addition, acute and chronic poisoning, as well as mutagenic and immunosuppressive effects have been reported (Kiran *et al.*, 1998; Sur & Celik, 2003).

Duck and turkeys are the most sensitive poultry species to aflatoxicosis, quails are moderately susceptible, whereas chickens are considered the most resistant. It has been reported that pheasants, geese, and chickens are more resistant than ducks and turkeys. Bobwhite quails are more susceptible than Japanese quails (Ruff *et al.*, 1992). The most obvious macroscopic findings related to acute and chronic aflatoxicosis are observed in the liver. Lesions can also be observed in other organs, such as the kidneys, spleen and bursa of Fabricius (Diaz *et al.*, 2008).

As in other poultry, AF can cause depression, anorexia, icterus, hemorrhages, and death in quails (Oliveira *et al.*, 2002). The most obvious macroscopic findings are observed in the liver in acute and chronic aflatoxicosis. In addition, lesions are found in other organs such as the kidney, spleen, and bursa of Fabricius (Sawhney *et al.*, 1973; Ortatlatli *et al.*, 2005). At gross examination, the liver is pale and enlarged. The main histopathological findings are oil vacuoles in the hepatocytes, hydropic degeneration, necrosis, and bile duct proliferation (Ortatlatli & Oguz, 2001). The kidney and spleen may be enlarged, and their surfaces may present petechial hemorrhages (Bilgic & Yesildere, 1992). Tubular degeneration and capillary hyperemia are commonly observed in the kidneys, and lymphoid-cell depletion and necrosis in the spleen. The bursa of Fabricius may present lymphoid-cell depletion and intrafollicular cysts (Ortatlatli *et al.*, 2002).

Glucomannans (GM) are extracted from the cell wall of the live yeast *Saccharomyces cerevisiae*, and were used to prevent the absorption of mycotoxins in the

early 1990s (Stanley *et al.*, 1993). It was demonstrated that GM present a strong capacity to bind AF in vivo and in vitro when added to poultry diets (Bintvihok *et al.*, 2002; Karaman *et al.*, 2005; Oguz, 2011; Azizpour & Moghadam, 2015). The positive effect of GM on oxidative stress parameters was also shown in quails (Atalay, 2010).

The present study investigated if the dietary addition of different doses of GM were effective for the protection of Japanese quails against aflatoxicosis. For this purpose, relative organ weights (liver, kidney, spleen, bursa of Fabricius and thymus) were calculated, and pathological changes in the organs were compared.

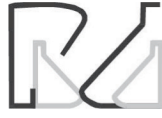MATERIALS AND METHODS

Birds and treatments

Sixty one-day old male Japanese quails (*Coturnix coturnix japonica*) were evaluated. The quails were obtained from Selçuk University, Faculty of Agriculture, Poultry Unit. The quails were housed in electrically-heated cages, at a density of 30 birds per cage, and provided with continuous lighting. A commercial basal diet (65% corn, 32% soybean meal, 3% vitamin-mineral premix), supplemented with amino acids, minerals, and vitamins at the levels recommended by the National Research Council (NRC, 1994), was fed. Before being supplied, the basal diet was proven to be clear from any detectable levels of residual AF (Howell & Taylor, 1981) at a detection limit of 1 µg/kg feed, using thin-layer chromatography (TLC) at 95% recovery rate. This basal diet was contaminated or not with aflatoxin and supplemented with a glucomannan at 1 or 2 g/kg of diet, according to the treatments: control (C), basal diet; aflatoxin (A), 2mg aflatoxin/kg basal diet; glucomannan (GM), 1g glucomannan/kg basal diet; two-fold dose of glucomannan (2GM), 2g glucomannan/kg basal diet; aflatoxin + glucomannan (A+GM), basal diet containing 2mg aflatoxin/kg plus 1g glucomannan/kg; and aflatoxin + two-fold dose of glucomannan (A+2GM), basal diet containing 2mg aflatoxin/kg plus 2g glucomannan/kg. The Japanese quails were equally divided into the six treatments with 10 birds each, and were fed the experimental diets from one to 21 days of age.

Aflatoxin and glucomannan analyses

The AF content in rice powder was analyzed and measured on thin layer chromatography-fluorometric densitometer (TLC) (Camag II, Basel, Switzerland). The AF was produced from a culture of *Aspergillus parasiticus* NRRL 2999 (USDA, Agricultural Research



Service, Peoria, IL) via rice fermentation by the method of Shotwell *et al.* (1966), with minor modifications by Demet *et al.* (1995) and Oguz (1997). Briefly, 100 g of sterile polished rice were inoculated with 1 mL of resuspended spores (1.5×10^6 spores/mL) of *Aspergillus parasiticus* NRRL 2999, placed an incubator at 28°C, and fermented for five days. AF was extracted as follows. Briefly, 10 g of fermented rice powder were accurately weighed and dispersed in 100 mL of distilled water and fixed for five minutes. Then, 100 mL of chloroform were added to the solution and blended for 15 minutes at 3000 rpm in a centrifuge. The chloroform phase was taken into a separating funnel already containing 15 g of anhydrous sodium sulfate. The collected chloroform evaporated to dryness in a rotary evaporator. Dried sample extracts were individually (2, 5, 10 µL) applied on the TLC plates, which were developed in an unlined tank containing 20 mL of chloroform:xylene:acetone (7:2:1; v/v) and observed under UV light (365 nm wavelengths and 425 emission). The AF in the rice powder consisted of 82.3% AFB1, 2.06% AFB2, 7.68% AFG1, and 7.96% AFG2 based on total AF in the ground rice powder (detection limit of aflatoxin: 1µg aflatoxin/kg rice powder. Recovery of the extraction method: 92%). The rice powder was incorporated into the basal diet in order to provide the desired amount of 2 mg AF/kg feed.

Esterified glucomannan (Mycosorb®, Alltech Inc. KY., USA) was used as binding agent of AF.

Pathological Examination

All quails in each group on day 21 of the study were weighed, euthanized by decapitation, and necropsied. The liver, kidneys, spleen, thymus and bursa of Fabricius

were collected and weighed on a precision scale to calculate relative organ weight as a percentage of live weight.

The collected organs were fixed in 10% formalin solution, dehydrated in graded alcohol series, cleared in xylene, and embedded in paraffin blocks. Tissues were cut in 5-µm thick sections using a microtome, mounted on slides, stained with hematoxylin and eosin (Luna, 1968), and examined under a light microscope.

In histopathological examination, liver degenerative changes were scored according to the method described by Ortatlatli *et al.* (2005). Mild hepatocellular swellings due to hydropic and fatty degeneration only in centrilobular areas were scored as 1 (Mild); evident hepatocellular swelling in the centrilobular and the intermediate areas of lobules, were scored as 2 (Intermediate); and severe hepatocellular swellings extending to the whole lobules were scored as 3 (Severe). Lymphoid depletion in the bursa of Fabricius and spleen, cortical atrophy in the thymus, and tubular degeneration in the kidney were evaluated by histopathology.

Statistical Analysis

The Kruskal-Wallis test was applied to compare the gross and histopathological findings among treatments. Relative organ weight differences were compared by Duncan's multiple range test (IBM® SPSS® Statistics Version 22). Statements of statistical significance are based on a *p* value of <0.05.

RESULTS

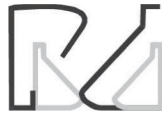Pathological findings of liver, spleen, kidney, thymus and bursa of Fabricius are summarized in Table 1.

Table 1 – Distribution of the lesions in the organs from day 1 to 21 trial period.

Lesions/Changes	Control Normal Diet	A 2mg/kg of AF	GM 1g/kg of GM	A+GM 2mg/kg of AF + 1g/kg of GM	2GM 2g/kg of GM	A+2GM 2mg/kg of AF + 2g/kg of GM
Gross findings on liver (Enlargement and paleness)	0/10 ^b	6/10 ^a	1/10 ^{ab}	4/10 ^{ab}	1/10 ^{ab}	1/10 ^{ab}
Hydropic and/or fatty changes in hepatocytes	1/10 ^b	9/10 ^a	4/10 ^b	5/10 ^{ab}	3/10 ^b	5/10 ^{ab}
Mild	1	1	3	1	3	3
Moderate	0	2	1	0	0	2
Severe	0	6	0	4	0	0
Bile duct proliferation	0/10 ^b	6/10 ^a	2/10 ^{ab}	6/10 ^a	2/10 ^{ab}	2/10 ^{ab}
Lymphoid depletion (Spleen)	1/10 ^{ab}	5/10 ^a	2/10 ^{ab}	4/10 ^{ab}	0/10 ^b	0/10 ^b
Lymphoid depletion (Bursa of Fabricius)	4/10 ^{ab}	9/10 ^a	5/10 ^{ab}	7/10 ^{ab}	2/10 ^b	2/10 ^b
Cortical atrophy (Thymus)	1/10 ^b	8/10 ^a	3/10 ^{ab}	6/10 ^{ab}	1/10 ^b	1/10 ^b
Tubular degeneration (Kidney)	1/10 ^b	9/10 ^a	1/10 ^b	9/10 ^a	0/10 ^b	1/10 ^b

^{a-b} Values within rows with no common superscripts are significantly different, according to Kruskal Wallis test.

Control: Normal diet; A: Aflatoxin Group, 2mg/kg aflatoxin; GM: Glucomannan Group, 1g/kg glucomannan; A+GM: Aflatoxin + Glucomannan Group, 2 mg/kg aflatoxin + 1g/kg glucomannan; 2GM: 2-fold dose of Glucomannan Group, 2g/kg glucomannan; A+2GM: Aflatoxin + 2-fold dose of Glucomannan Group, 2 mg/kg aflatoxin + 2g/kg glucomannan.



Liver gross lesions were observed in the livers of six quails of group A, in four of the group A+GM and only one bird of the group A+2GM (Figure 1). The highest frequency of fatty and hydropic liver degeneration (9/10 birds) was determined in group A, and the lowest in the GM and 2GM groups (3 and 4/10 birds, respectively), while groups A+GM and A+2GM presented intermediate frequencies (5/10 birds). Relative to severity, only groups A and A+GM presented severe lesions (6 and 4 birds, respectively). Moderate lesions were observed in 3 A+2GM birds, 2 A birds, and one GM bird, but not in the other groups. Mild lesions were detected in 1/10 bird of the Control, A, and A+GM groups, and 3/10 birds of the GM, 2GM, and A+GM groups.




Figure 1 – Gross findings on the livers. A. Control group. The normal view of the liver. B. Aflatoxin Group (2mg/kg of AF). The liver is quite enlarged and faded. C. A+GM Group (2mg/kg of AF + 1g/kg of GM). The enlargement and paleness of the liver are milder than B when compared to Aflatoxin Group. D. A+2GM Group (2mg/kg of AF + 2g/kg of GM). Liver with the normal and healthy appearance.

A higher frequency of bile duct proliferation and periportal fibrosis was detected in Groups A and A+GM (6 birds) compared with the groups fed GM (2 birds) (Figure 2).

In the spleen, lymphoid cell depletion was observed in 5/10 birds of group A, 4/10birds of group A+GM, and 1/10 bird of group GM. No lymphoid cell depletion was detected in groups 2GM and A+2GM.

In the bursa, 9/10 birds of group A presented the highest central lymphoid cell depletion, as well as intrafollicular cysts. Groups A+GM and GM presented intermediate frequencies (7/10 and 5/10 birds, respectively), whereas no depletion was detected in birds of groups 2GM and A+2GM.

Group A presented the highest number of birds (8/10) with thymus cortical atrophy, followed by groups A+GM and GM with intermediate frequencies (6/10

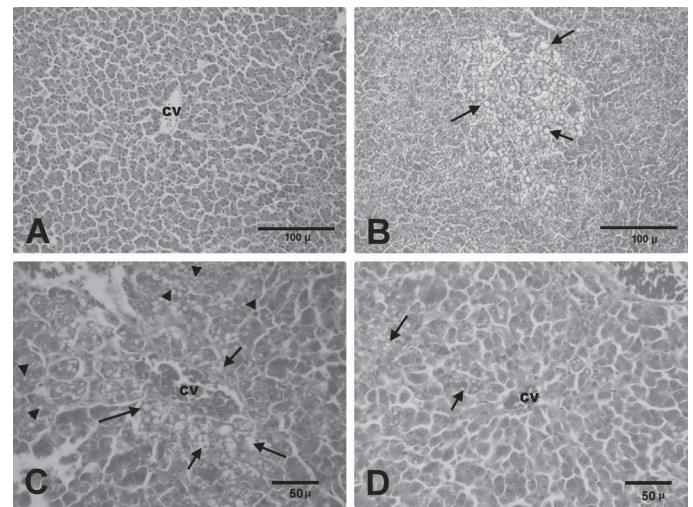


Figure 2 – Histopathological findings on the liver. A. Control group. Central vein (CV) and normal hepatocytes. B. Aflatoxin Group (2mg/kg of AF). Severe fatty changes and hydropic degenerations on the hepatocytes (arrows). C. A+GM Group (2mg/kg of AF + 1g/kg of GM). Centro-lobular (arrows) and intermedial (arrow heads) fatty changes on the hepatocytes around of the central vein (CV). D. A+2GM Group (2mg/kg of AF + 2g/kg of GM). A small number of hydropic degenerations (arrows) around of the central vein (CV).

and 3/10, respectively), and groups 2GM and A+2GM, the lowest, with only 1/10 birds each.

No kidney necrosis and hemorrhages were found. Degenerative changes in renal tubular epithelia were observed in a higher number of birds of groups A and A+GM (9/10 each) compared with the other groups (1/10 in GM and A+2GM and none in the 2GM group), as shown in Table 1.

The relative organ weights of liver, kidney, spleen, bursa of Fabricius, and thymus are presented in Table 2. There were no differences in the relative weights of the kidneys and spleen among treatments. Birds of group A presented the heaviest livers and the A+GM and 2GM birds, the lightest, whereas the relative liver weights of the GM and the A+GM birds had intermediate values. The bursa of A+GM birds was lighter than those of the 2GM birds, whereas the other groups presented intermediate values. The highest and the lowest relative thymus weight were observed in group A+2GM and A+GM, respectively, whereas the remaining groups weren't statistically different from each other.

DISCUSSION

Macroscopic and microscopic examinations are very effective methods to demonstrate the pathological findings of aflatoxicosis (Bintvihok *et al.*, 2002). In particular, it was reported that the liver, kidney, spleen, thymus, and bursa of Fabricius are the target organs of aflatoxicosis (Ortatlatli *et al.*, 2005). As mentioned



Table 2 – Effects of glucomannan on relative organ weights for quails fed on diet containing total aflatoxin between 1 – 21 days age.

Groups	Relative Organ Weights (organ weight / 100 gr live body weight)				
	Liver	Kidney	Spleen	B.Fabircius	Thymus
Control	3.660 ^a ± 0.151	0.586 ^a ± 0.029	0.079 ^a ± 0.007	0.157 ^c ± 0.017	0.357 ^c ± 0.041
A	4.552 ^b ± 0.195	0.635 ^a ± 0.041	0.093 ^a ± 0.013	0.108 ^{ab} ± 0.010	0.233 ^{ab} ± 0.020
GM	3.292 ^a ± 0.111	0.528 ^a ± 0.033	0.067 ^a ± 0.006	0.132 ^{abc} ± 0.018	0.313 ^{bc} ± 0.025
A+GM	3.929 ^{ab} ± 0.286	0.544 ^a ± 0.046	0.072 ^a ± 0.011	0.089 ^a ± 0.015	0.182 ^a ± 0.014
2GM	4.041 ^{ab} ± 0.273	0.601 ^a ± 0.039	0.066 ^a ± 0.006	0.144 ^{bc} ± 0.010	0.250 ^{ab} ± 0.022
A+2GM	3.716 ^a ± 0.330	0.573 ^a ± 0.022	0.084 ^a ± 0.008	0.132 ^{abc} ± 0.013	0.371 ^c ± 0.035

Values represent the mean ± SEM of six groups of 10 quails each per treatment.

^{a-c}Values within column with no common superscripts are significantly different (p value<0.05), according to Duncan's Multiple Range Test

Control: Normal diet; A: Aflatoxin Group, 2mg/kg aflatoxin; GM: Glucomannan Group, 1g/kg glucomannan; A+GM: Aflatoxin + Glucomannan Group, 2 mg/kg aflatoxin + 1g/kg glucomannan; 2GM: 2-fold dose of Glucomannan Group, 2g/kg glucomannan; A+2GM: Aflatoxin + 2-fold dose of Glucomannan Group, 2 mg/kg aflatoxin + 2g/kg glucomannan.

in previous studies, aflatoxicosis histopathological findings are directly proportional to the exposure time and intensity of the toxin (Magnoli *et al.*, 2012). In 21-day trial period of the present study, the toxic effects of AF and the protective effects of GM were histologically demonstrated.

Liver paleness and hepatomegaly are important indicators of aflatoxicosis (Hoerr, 2003;Ortatatli *et al.*, 2005). While no gross changes were observed in the Control, GM and 2GM groups, the livers of the birds of the A and A+GM groups were very swollen and pale. In contrast, the severity of liver lesions was mild in the A+2GM group, whereas 6/10 and 4/10 birds of the A and A+GM groups presented severe lesions. The difference between these groups (A and A+2GM) was statistically significant. The macroscopic liver changes observed in the present study are consistent with previously reported studies (Sawhney *et al.*, 1973; Ortatatli & Oguz, 2001; Oliveira *et al.*, 2002;Ortatatli *et al.*, 2005; Citil *et al.*, 2007; Magnoli *et al.*, 2012; Ibrahim, 2013).

The most common finding in aflatoxicosis fatty and hydropic degeneration of the liver, as observed by microscopic examination (Sawhney *et al.*, 1973; Bryden & Cumming, 1980; Ortatatli & Oguz, 2001; Oliveira *et al.*, 2002; Karaman *et al.*, 2005; Ortatatli *et al.*, 2005; Attia *et al.*, 2016). No severe lesions were observed in the Control, GM, 2GM, and A+2GM birds. Severe hydropic and fatty degeneration were present in the livers of group A. In addition, marked diffuse fatty changes, bile duct proliferation, and periportal fibrosis were detected in the portal areas of those birds. In a similar study in broiler chickens, broilers were fed 2 mg aflatoxins/kg diet+0.5g or 1 g glucomannan / kg diet and reported very mild liver lesions with the addition of glucomannan (Karaman *et al.*, 2005). In

the present study, the severity of the hydropic and fatty degeneration was reduced when broilers fed the AF-contaminated diet received 2g of GM compared with 1g.

Lymphoid organs, such as the spleen, bursa of Fabricius, and thymus are primarily affected by aflatoxicosis (Ortatatli *et al.*, 2005). Pathological changes in the lymphoid organs caused by aflatoxicosis were microscopically shown in the present study. Lymphoid cell depletion in bursa of Fabricius, thymus and spleen were more frequently observed in groups A and A+GM. Necrosis of the germinal centers of the lymphoid follicles and rarely intrafollicular cysts were found in these groups. Cortical atrophy of thymus and necrosis and spleen lymphoid tissue depletion were evident. The highest frequency of birds with lymphoid tissue depletion both in the spleen and the bursa were determined in group A, whereas the lowest in groups 2GM and A+2GM. The lesions of group A+2GM were mild and found in a limited number of birds. The number of birds with lymphoid lesions in the control, GM and 2GM groups was not statistically different from the A and the A+2GM groups.

Due to the short duration of this study, only degenerative changes were observed in the kidneys, and not necrosis and intertubular hemorrhages commonly observed with the chronic intoxication with aflatoxin (Bilgic & Yesildere, 1992; Valchev *et al.*, 2014).

Kubena *et al.* (1990) observed that changes in liver weight are a more sensitive indicator of aflatoxicosis compared with the weight of other organs, such as kidneys, spleen, and pancreas. In our study, relative liver weight was higher in group A compared with the Control, GM and A+2GM groups, whereas the groups 2GM and A+GM presented intermediate values. The heavier livers of the birds fed only aflatoxin may be due to the histopathological fatty changes in the



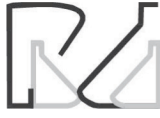hepatocytes, as previously reported in other studies (Ortatlati & Oguz, 2001; Ortatlati *et al.*, 2005). Raju & Devegowda (2000) reported that an esterified glucosamin reduced liver weight, but did not affect kidney weight, as also observed in the present study in the birds fed aflatoxin and 2 g GM/kg of diet (A+2GM).

The relative weights of the bursa of Fabricius and thymus were affected by the dietary treatments. In particular, the birds fed only AF presented significant atrophy of these organs compared with the controls, probably due to lymphoid tissue depletion and necrosis of the parenchyma of these organs (Ortatlati & Oguz, 2001; Girish & Devegowda, 2006). However, the addition of 2 g glucosamin/kg to the AF-containing diet (A+2GM group) statistically increased the relative weights of the bursa and thymus in comparison with the supplementation of 1 g glucosamin/kg of the AF-containing diet.

Therefore, the addition of 2 g of glucosamin per kg of an aflatoxin-contaminated diet may protect Japanese quails from aflatoxicosis, as demonstrated by the alleviation of gross and pathological changes in the liver and lymphoid organs.

REFERENCES

- Azizpour A, Moghadam N. Effects of yeast glucosamin and sodium bentonite on the toxicity of aflatoxin in broilers. *Brazilian Journal of Poultry Science* 2015;17:7-13.
- Atalay B. The effects of dietary esterified glucosamin on lipid peroxidation and some antioxidant system parameters during experimental aflatoxicosis in japanese quails. *Dicle Üniversitesi Veteriner Fakültesi Dergisi* 2010;2:29-33.
- Attia YA, Abd Al-Hamid AE, Allakany HF, Al-Harhi MA, Mohamed NA. Necessity of continuing of supplementation of non-nutritive feed additive during days 21–42 of age following 3 weeks of feeding aflatoxin to broiler chickens, *Jornal of Applied Animal Research* 2016;44:87-98.
- Abdel-Wahhab MA, Aly SE. Antioxidant property of nigella sativa (black cumin) and syzygium aromaticum (clove) in rats during aflatoxicosis, *Journal of Applied Toxicology* 2005;25:218-223.
- Bilgic HN, Yesildere T. Renal lesions on experimental aflatoxicosis in chickens. *Istanbul Üniversitesi Veteriner Fakültesi Dergisi* 1992;18:102-108.
- Bintvihok A, Banlunara W, Kaewamatawong T. Aflatoxin detoxification by esterified glucosamin in ducklings. *Journal of Health Research* 2002;16:135-148.
- Bryden WL, Cumming RB. Observations on the liver of the chicken following aflatoxin B1 ingestion. *Avian Pathology* 1980;9:551-556.
- Cengiz Ö, Cakir S, Sehu A, Essiz D, Ergün E, Ergün L, *et al.* Effects of Moldstop® on aflatoxicosis in quails. *Journal of Veterinary Research* 2008;52:561 – 564.
- Citil M, Karapehlivan M, Tuzcu M, Dogan A, Uzlu E, Atakisi E, *et al.* Effect of L-carnitine supplementation on biochemical, haematological and pathological parameters of quails (*Coturnix coturnix japonica*) during chronic aflatoxicosis. *Kafkas Üniversitesi Veteriner Fakültesi Dergisi* 2007;13:75-85.
- Demet O, Oguz H, Celik I, Nizamlioglu F. Pirinçte aflatoksin üretimi. *Eurasian Journal of Veterinary Science* 1995;11:19-23.
- Diaz GJ, Calabrese E, Blain R. Aflatoxicosis in chickens (*Gallus gallus*). an example of hormesis. *Poultry Science* 2008;87(4):727-732.
- Eraslan G, Liman BC, Guclu BK, Atasever A, Koc AN, Beyaz L. Evaluation of aflatoxin toxicity in japanese quails given various doses of hydrated sodium calcium aluminosilicate. *Bulletin of the Veterinary Institute in Pulawy* 2004;48:511-517.
- Erdeger J. Aflatoxikozis. *Kanatlı hayvan hastalıkları*. Ankara: Medisan Press; 2002.
- Girish CK, Devegowda G. Efficacy of glucosamin-containing yeast product (mycosorb) and hydrated sodium calcium aluminosilicate in preventing the individual and combined toxicity of aflatoxin and t-2 toxin in commercial broilers. *Asian-Australasian Journal of Animal Sciences* 2006;19:877 – 883.
- Hatch RC. *Veterinary pharmacology and therapeutics*. 6th ed. Ames: Iowa State University Press; 1988.
- Hoerr JF. *Mycotoxicoses*. In: Calnek BW, *et al.* Diseases of poultry. 11th ed. Ames: Iowa State University Press; 2003.
- Howell MV, Taylor PW. Determination of aflatoxins, ochratoxin a, and zearalenone in mixed feeds, with detection by thin layer chromatography or high performance liquid chromatography. *Journal - Association of Official Analytical Chemists* 1981;64:1356-1363.
- Ibrahim QQ. Histopathological study of quails liver experimentally induced by aflatoxin. *Basrah Journal of Veterinary Research* 2013;12:116-127.
- Karaman M, Basmacioglu H, Ortatlati M, Oguz H. Evaluation of the detoxifying effect of yeast glucosamin on aflatoxicosis in broilers as assessed by gross examination and histopathology. *British Poultry Science* 2005;46:394-400.
- Kaya S. Yem ve besinlerdeki mikotoksinler: insan hayvan sağlığı için önemleri. *Ankara Üniversitesi Veteriner Fakültesi Dergisi* 1989;36:226-253.
- Kiran MM, Demet O, Ortatlati M, Oguz H. The preventive effect of polyvinyl-polypyrrolidone on aflatoxicosis in broilers. *Avian Pathology* 1998;27:250–255.
- Kubena LF, Harvey RB, Huff WE, Corrier DE, Phillips TD, Rottinghaus GE. Efficacy of hydrated sodium calcium aluminosilicate to reduce the toxicity of aflatoxin and t-2 toxin. *Poultry Science* 1990;69:1078-1086.
- Luna LG. Processing of tissue. In: Luna LG. *Manual of histology staining methods of the armed forces institute of pathology*. 3rd ed. New York; 1968.
- Magnoli AP, Monge MP, Nazar FN, Magnoli CE, Cavaglieri LR, Bagnis G, *et al.* Combined effects of aflatoxin B1 and corticosterone treatment on selected performance indices and liver histopathology in Japanese quail. *Poultry Science* 2012;91:354–361.
- NRC - National Research Council. *Nutrient requirements of poultry*. 9th ed. Washington; 1994.
- Oguz H. The preventive efficacy of polyvinylpolypyrrolidone (PVPP) alone and its combination with the other adsorbents into broiler feeds against aflatoxicosis [dissertation]. Konya (TR): University of Selçuk; 1997.
- Oguz H, Parlak SS. Effects of dietary mannanoligosaccharide on performance of japanese quail affected by aflatoxicosis. *South African Journal of Animal Science* 2004;34:144–148.



- Oguz H. A review from experimental trials on detoxification of aflatoxin in poultry feed. *Eurasian Journal of Veterinary Science* 2011;27:1-12.
- Oliveira CAF, Rosmaninho JF, Butkeraitis P, Correa B, Reis A, Guerra JL, et al. Effect of low levels of dietary aflatoxin b1 on laying japanese quail. *Poultry Science* 2002;81:976-980.
- Ortatlatli M, Oguz H. Ameliorative effects of dietary clinoptilolite on pathological changes in broiler chickens during aflatoxicosis. *Research in Veterinary Science* 2001;71:59-66.
- Ortatlatli M, Ciftci MK, Tuzcu M, Kaya A. The effects of aflatoxin on the reproductive system of roosters. *Research in Veterinary Science* 2002;72:29-36.
- Ortatlatli M, Oguz H, Hatipoglu F, Karaman M. Evaluation of pathological changes in broilers during chronic aflatoxin (50 and 100 ppb) and clinoptilolite exposure. *Research in Veterinary Science* 2005;78:61-68.
- Parlat SS, Ozcan M, Oguz H. Biological suppression of aflatoxicosis in japanese quail (*coturnix coturnix japonica*) by dietary addition of yeast (*saccharomyces cerevisiae*). *Research in Veterinary Science* 2001;71:207 - 211.
- Raju MVLN, Devegowda G. Influence of esterified-glucomannan on performance and organ morphology, serum biochemistry and haematology in broilers exposed to individual and combined mycotoxicosis (aflatoxin, ochratoxin and T-2 toxin). *British Poultry Science* 2000;41:640-650.
- Ruff MD, Huff WE, Wilkins GC. Characterization of the toxicity of the mycotoxins aflatoxin, ochratoxin, and t-2 toxin in game birds. III. bobwhite and japanese quail. *Avian Diseases* 1992;36:34-39.
- Sawhney DS, Vadehra DV, Baker RC. Aflatoxicosis in the laying japanese quail (*coturnix coturnix japonica*). *Poultry Science* 1973;52:465-473.
- Sehu A, Cakir S, Cengiz Ö, Essiz D. Mycotox® and aflatoxicosis in quails. *British Poultry Science* 2005;46:520-524.
- Shotwell OL, Hesseltine CV, Stubblefield RD, Sorenson WG. Production of aflatoxin on rice. *Journal of Applied Microbiology* 1966;14:425-429.
- Stanley VG, Ojo R, Woldensenbet S, Hutchinson DH. The use of *Saccharomyces cerevisiae*, to suppress the effect of aflatoxicosis in broiler chicks. *Poultry Science* 1993;72:1867-1872.
- Sur E, Celik I. Effects of aflatoxin b1 on the development of bursa of fabricius and blood lymphocyte acid phosphatase of the chicken. *British Poultry Science* 2003;44:558-566.
- Valchev I, Kanakov D, Hristov TS, Lazarov L, Binev R, Grozeva N, et al. Effects of experimental aflatoxicosis on renal function in broiler chickens. *Bulgarian Journal of Veterinay Medicine* 2014;17:302-313.

