

# Totally endoscopic mitral valve repair: a case report

## *Reoperação de valva mitral totalmente endoscópica: relato de caso*

Jeronimo Antonio FORTUNATO JÚNIOR<sup>1</sup>, Alcides D. BRANCO FILHO<sup>2</sup>, Anibal BRANCO<sup>3</sup>, André Luiz M. MARTINS<sup>4</sup>, Marcelo PEREIRA<sup>5</sup>

RBCCV 44205-1008

### *Abstract*

Minimum incision techniques in cardiac surgery have been on the rise after their inclusion in videothoracoscopy. Video-assisted minimally invasive cardiac surgery is considered by many centers in the world to be the approach of choice for treatment of mitral and aortic valve diseases. The aim of this study is to report a case of valve repair in a patient with mitral stenosis after surgical repair 12 years before. Through a minimally invasive and totally endoscopic procedure, it was possible to successfully perform a mitral commissurotomy with only videoscopic support, and without any incisions larger than those needed to introduce the trocars for instrumentation.

**Descriptors:** Video-assist surgery. Cardiac surgical procedures/methods. Thoracic surgery, video-assisted/methods. Mitral valve/surgery. Reoperation.

### INTRODUCTION

Mitral stenosis is still the most common valve disease in our country, mainly due to its association with rheumatic disease. Surgical procedures for opening valves may be recommended at some point in the disease's evolution due to a progressive degeneration. Percutaneous mitral valvuloplasty performed by hemodynamicists presents excellent results when used appropriately. In surgical cases, valve correction preservation is more effective when

### *Resumo*

As mínimas incisões na cirurgia cardíaca receberam um grande impulso após a inclusão da videotoracosopia. Cirurgia cardíaca minimamente invasiva videoassistida é considerada hoje, por muitos centros no mundo, abordagem de escolha para tratamento das doenças na valva mitral e aórtica. Nosso objetivo é relatar um caso de reoperação, em uma paciente com reestenose mitral pós-plastia 12 anos antes. Através de um procedimento minimamente invasivo e totalmente endoscópico foi possível realizar com sucesso uma comissurotomia mitral, somente com apoio da videoscopia, sem incisões maiores do que as necessárias para introdução dos trocateres para instrumentação.

**Descritores:** Cirurgia vídeo-assistida. Procedimentos cirúrgicos cardíacos/métodos. Cirurgia torácica vídeo-assistida/métodos. Valva mitral/cirurgia. Reoperação.

compared to valve replacement. Median sternotomy is the conventional and compatible approach, and produces good results in terms of valve preservation. Minimally invasive techniques using minithoracotomy for aortic and mitral valve surgery have progressed slowly in recent years [1]. New equipment for video-assisted surgeries and cardiopulmonary bypasses (CPB) using peripheral approaches (port access technology) assumes that surgeons can perform less invasive surgeries with the promising results presented in the literature [2].

1. Cardiac surgeon and Master's Degree in Clinical Surgery; Head of the Cardiac Surgery Department of the HCV-PR
2. General Surgeon; Member of the General Surgery Department of the HCV-PR
3. Urologist; Member of the Urology Service of the HCV-PR
4. Cardiac Surgeon; Member of the Cardiac Surgery Department of the HCV-PR

This study was carried out at the Red Cross Hospital - Paraná - Rua Vicente Machado 1310, Bairro Batel, Curitiba, PR, Brazil.

Address for correspondence:

Jerônimo A. Fortunato Júnior. Rua Amauri Gabriel Grassi Matei 50, Santo Inácio, Curitiba, PR, Brasil, CEP 82.010.620.

E-mail address: jfjunior@uol.com.br

Article received on March 5<sup>th</sup>, 2008

Article accepted on July 16<sup>th</sup>, 2008

## OBJECTIVE

The aim of this report is to demonstrate the technical approach for the mitral valve with a totally endoscopic procedure through a case of reoperation for mitral valve restenosis, with peripheral CPB and without the assistance of a minithoracotomy.

## CASE REPORT

This is a report about a 24-year-old female patient with rheumatic mitral stenosis and a previous heart surgery at 12 years of age. Mitral valvuloplasty with Carpentier ring was performed at that time. The patient was referred to our service for reoperation for mitral valve restenosis. Symptomatic patient in functional class III (NYHA), several episodes of lung congestion. Electrocardiogram revealed sinus rhythm and the chest radiography showed left atrial enlargement; echocardiogram showed normal function of the left ventricle; significant mitral valve stenosis with a maximum gradient of 18 mmHg and 1.2cm<sup>2</sup> valve area, but with preserved subvalvar apparatus; pulmonary artery pressure of 55 mmHg.

The balloon percutaneous valvuloplasty was discarded since it was a case of reoperation, and a plasty ring was already present. After a consultation for a minimally invasive procedure, the patient signed the formal document to authorize the surgery. She was referred to surgery and underwent general anesthesia with selective intubation. Inguinal vessel dissection for cannulation of femoral artery and vein was performed. CPB was peripherally conducted with femoral cannulation kit without a need for negative venous pressure.

Cardiac arrest was performed by ventricular fibrillation (VF) with moderate hypothermia, and the VF temperature level was maintained until the end of cardiotomy with the mean temperature of 25 degrees. Surgical instruments, such as clamps, scalpels and optical, were introduced through the 3 10-mm trocars, which penetrated the thorax through the intercostal spaces in 2-cm incisions in the skin. After individually separating the pericardium, a left atriotomy was performed below the phrenic and transpericardium nerve and without dissections (Figure 1). With the use of a cushioning retractor, the interior of the left atrium was exposed, allowing us to see the mitral valve (Figure 2). The valve aspect showed pure commissural fusion with preserved subvalvar apparatus (Figure 3). Next anterior and posterior commissurotomy and separation of fused bundles were performed with n° 11 scalpel blade (Figure 4).

The valve test showed an excellent opening and slight insufficiency, confirming the good surgical result. During left atrial suture, a catheter was introduced to remove air from the left ventricle. It was passed through the mitral

valve and used until the effective return of the patient's heartbeat. CPB was concluded without complications, and its total time was 140 minutes. The patient was extubated in the operating room. She remained in the ICU over 30 hours with good evolution, and was then discharged from the unit. On the fourth postoperative day, the patient presented sudden hemoptysis and returned to the ICU and was diagnosed with pulmonary hemorrhage in the right inferior lobe without detectable surgical cause. The possibility of induced pulmonary re-expansion in the right lung (after selective intubation during surgery), although late, may have been a possible cause. Swan Ganz catheter was not used, which is sometimes another cause of pulmonary hemorrhage. The patient stayed in the ICU for another 7 days, and was discharged from the hospital after 15 days of postoperative evolution.

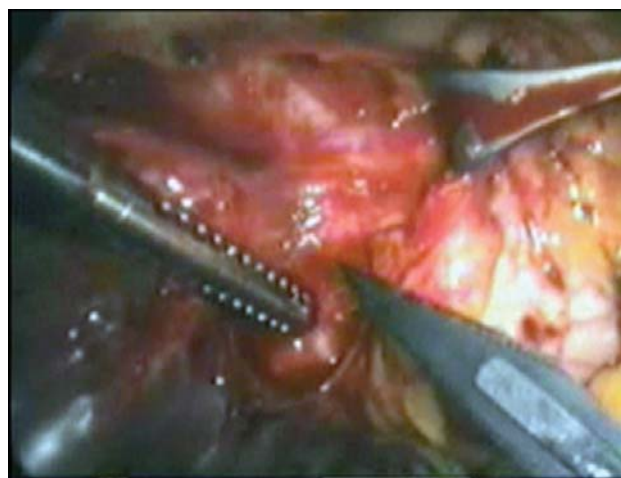

Fig. 1 – Location of atriotomy exposing the left superior pulmonary vein, below the phrenic nerve

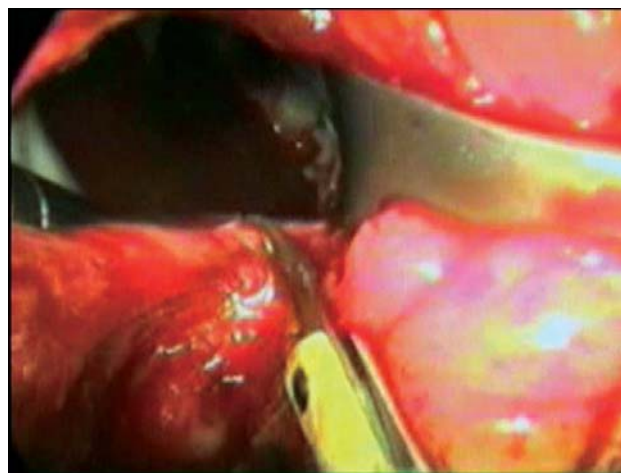


Fig. 2 – Left atriotomy with the atrial cavity pulled away by Cushioning retractor

The echocardiography control showed correction of mitral stenosis, with an area estimated at 2.2 cm<sup>2</sup> without transvalvar gradient and slight insufficiency, decrease of the SPAP to normal values (55 to 20 mmHg). The patient was asymptomatic during the 24 months of follow-up, and was pregnant during this period.

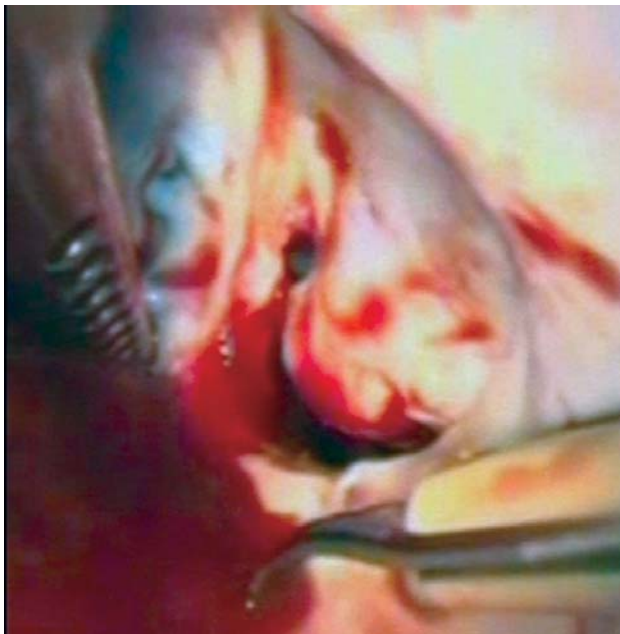

Fig. 3 – Preoperative view of the mitral valve, showing critical stenosis

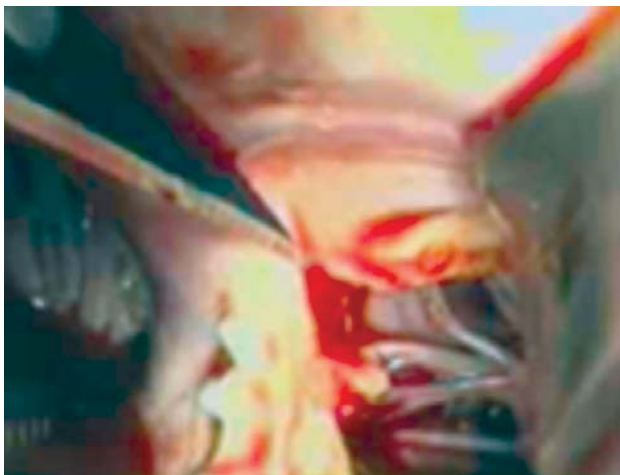


Fig. 4 – Anterior commissurotomy of the mitral valve. Detail of the n° 11 scalpel blade and the subvalvar apparatus

## DISCUSSION

Despite the promise of great results in terms of postoperative pain, aesthetic effects of small incisions, and a reduction in surgical bleeding, many reports questioned the complications and survival rates of minimally invasive procedures, particularly when compared to conventional procedures. Several studies indicated a higher rate of complications in minimally invasive procedures.

However, favorable results were reported in other studies, such as Machler et al. [1], who compared the conventional technique to the minimal incision approach for aortic valves. They reported similar survival rates in 120 patients, but reported a significant differences regarding the postoperative pain, needs for hemotransfusion, minimal analgesia and low incidence of arrhythmias in the minimally invasive cases.

With the advent of videosurgery, the implementation of percutaneous and low profile cannulas for peripheral CPB and aortic endoclamping (port-access technology), the video-assisted minimally invasive cardiac surgery (MICS), as it is known, has taken the procedure in a new direction, with increasingly promising results and more frequent reports [2].

Brazil is included in this transition with the experiences of Jatene et al. [3], who, in 1997, reported the use of videothoracoscopy for dissection of the left internal thoracic artery and its coronary implantation through minithoracotomy. Seventy-three patients underwent surgery with a low rate of complications and with early hospital discharge. In 2000, Souto et al. [4] showed the technique of closing of the arterial channel through videothoracoscopy in 40 patients, emphasizing the simplicity and singularity of the new method of approach. There are few Brazilian studies that report the use of CCMI, but several centers have shown interest in this new area of heart surgery.

This study reports a case of mitral commissurotomy performed with CCMI using a totally endoscopic procedure (using only thoracoscopy), without any possibility of a direct view or even incisions larger than those required to introduce trocars for instrumentation. A similar procedure in the literature was reported by Gersak et al. [5] in 2003 with the title “Endoscopic Aortic Valve Replacement.” It reported on a minimally invasive aortic valve surgery. In this study, surgeons used the totally endoscopic procedure following the 4<sup>th</sup> right intercostal space approach for minithoracotomy, which is aesthetically superior, but which did not allow for a direct view of the aortic valve, and the replacement was performed only using videoscscopy. This approach was considered to be the first report of its kind in the world literature.

In our case, the thoracoscopy, in addition to eliminating the need to dissect pericardial adhesions, allowed for excellent visibility of the operative field, even in a case of

reoperation. With a small Cushing retractor, it was possible to expose, view, and treat the mitral valve. Cardiac arrest, which was performed without aortic clamping and using hypothermic ventricular fibrillation, was not a complicating factor, with no need for dissection of the aortic root or insertion of endoclamp. Casselman et al. [6], in a 2007 publication, reported the same hypothermic ventricular fibrillation technique in cases of mitral and tricuspid reoperation, and with excellent results. Despite a pulmonary complication, the initial postoperative result was obtained, with extubation in the operating room, minimal postoperative pain, slight chest drainage. Time spent in the ICU (before hemoptysis) was 30 hours.

Reoperations in the tricuspid and mitral valves have been increasingly recommended to be performed through minimally invasive video-assisted procedures. Such procedures are associated with better postoperative results, since there is no longer a need for larger dissections. Morbidity and mortality rates have been lower when compared to conventional reoperations. Many centers consider the minimal incisions as the primary approach for valve reoperations [6].

Reports of video-guided cardiac surgeries are frequently found in the literature. The use of such a procedure today is much more limited by the ability of surgical teams and the familiarity with the technical approach than by evidence of its effectiveness.

Multicenter studies have shown the real benefits of minimally invasive surgeries, confirming low morbidity and mortality, excellent aesthetic benefits and rapid postoperative recovery. These studies show that such a technique is recommended as the first option for valve procedures [2-6]. The robot improves this new technique by providing dexterous instruments that answer to voice commands or can be controlled by a joystick.

## CONCLUSION

We conclude that the minimally invasive and video-guided approach performed without minithoracotomy was

feasible and effective in performing mitral commissurotomy in a case of reoperation for restenosis. The procedure, which is performed endoscopically, is not reported in the literature and was used because it did not require any kind of prostheses or major intervention. It is possible that, with more experience and better training for surgeons, and with the addition of robotics, major interventions will be performed in the future without a need for minithoracotomies.

## REFERENCES

1. Mächler HE, Bergmann P, Anelli-Monti M, Dacar D, Rehak P, Knez I, et al. Minimally invasive versus conventional aortic valve operations: a prospective study in 120 patients. *Ann Thorac Surg.* 1999;67(4):1001-5.
2. Mishra YK, Khanna SN, Wasir H, Sharma KK, Mehta Y, Trehan N. Port-access approach for cardiac surgical procedures: our experience in 776 patients. *Indian Heart J.* 2005;57(6):688-93.
3. Jatene FB, Pêgo-Fernandes PM, Assad RS, Dallan LA, Hueb W, Arbulu HEVD, et al. Cirurgia de revascularização do miocárdio minimamente invasiva: resultados com o uso da videotoracoscopia e do estabilizador de sutura. *Rev Bras Cir Cardiovasc.* 1997;12(3):233-8.
4. Souto GLL, Tinoco RC, Tinoco ACA, Caetano CS, Souza JB, Paula AG, et al. Ligadura videotoracoscópica da persistência do canal arterial. *Rev Bras Cir Cardiovasc.* 2000;15(2):154-9.
5. Gersak B, Sostaric M, Kalisnik J. Endoscopic aortic valve replacement. *Heart Surg Forum.* 2003;6(6):E197-9.
6. Casselman FP, La Meir M, Jeanmart H, Mazzarro E, Coddens J, Van Praet F, et al. Endoscopic mitral and tricuspid valve surgery after previous cardiac surgery