

Mitral insufficiency surgery to treat advanced heart failure

Cirurgia da insuficiência mitral no tratamento da insuficiência cardíaca avançada

João Victor Caprini OLIVEIRA¹, Walter Vilella de Andrade VICENTE², Alfredo José RODRIGUES³, Cesar Augusto FERREIRA⁴, Lafaiete ALVES JUNIOR⁵, Solange BASSETTO⁵, Andrea Carla CELOTTO⁶, Paulo Roberto Barbosa EVORA⁷

RBCCV 44205-1129

Abstract

Dilated cardiomyopathy is characterized by severe, progressive myocardial dysfunction, that is almost always irreversible. That syndrome leads to cardiac remodeling with augmentation of left ventricle volume and sphericity, dilation of the mitral annulus and dislocation of papillary muscles that pulls up the mitral cords thereby restraining mitral leaflet excursion. These biomechanical modifications generate functional mitral valve insufficiency, a dismal prognostic sign. Mitral valve repair or replacement was introduced as surgical coadjuvants to conventional medical treatment, with good symptomatic improvement. The long-term survival benefit is yet to be demonstrated.

Descriptors: Heart failure. Mitral valve/surgery. Mitral valve insufficiency.

Resumo

A cardiomiopatia dilatada caracteriza-se por disfunção

miocárdica grave, progressiva e, quase sempre, irreversível. Essa síndrome cursa com remodelamento cardíaco e, em especial, por aumento do volume e da esfericidade do ventrículo esquerdo com dilatação do anel mitral. Como consequência ocorre deslocamento lateral dos músculos papilares, estiramento das cordas tendíneas e consequente restrição da excursão sistólica dos folhetos mitrais. Esse conjunto de alterações biomecânicas causa insuficiência mitral funcional, um indicador de mau prognóstico. A plastia ou a troca da valva mitral foram introduzidas como alternativas cirúrgicas coadjuvantes ao tratamento clínico convencional e têm se mostrado eficazes em combater os sintomas de insuficiência cardíaca. Resta, todavia, demonstrar, seu benefício sobre o aumento da sobrevida em longo prazo.

Descritores: Insuficiência cardíaca. Valva mitral/cirurgia. Insuficiência da valva mitral.

1. Student; Student at Ribeirão Preto Medical School – USP.
2. Full Professor; Head of the Thoracic and Cardiovascular Surgery Department at Ribeirão Preto Medical School – USP.
3. Full Professor; Head of the Thoracic and Cardiovascular Surgery Department at Ribeirão Preto Medical School – USP.
4. Full Professor; Assistant of the Thoracic and Cardiovascular Surgery Department at Ribeirão Preto Medical School – USP.
5. Master's Degree; Assistant of the Thoracic and Cardiovascular Surgery Department at Ribeirão Preto Medical School – USP.
6. Master's Degree; Postgraduate Student of the Surgery and Anatomy Department at Ribeirão Preto Medical School – USP.
7. Titular Professor; Head of the Surgery and Anatomy Department at Ribeirão Preto Medical School – USP.

This study was carried out at Ribeirão Preto Medical School at University of São Paulo. Ribeirão Preto, SP, Brazil.

Correspondence address:

Paulo Roberto B. Évora.
Rua Rui Barbosa, 367, Apto. 150. Ribeirão Preto, SP, Brazil.
Brasil. CEP: 14015-120.
E-mail: prbevora@netsite.com.br

Support: FAPESP, FAEPA e CNPq

Article received on June 1st, 2009
Article accepted on October 28th, 2009

INTRODUCTION

Dilated cardiomyopathy (DC) is one of the more serious diseases, of higher morbidity and worst prognosis in public health, becoming the leading cause of death in the adult population, both in first world countries as well as Brazil [1]. Although this is a syndrome with many etiologies recognized, among which the predominant is the ischemic disease, there is also DC by tachyarrhythmias, storage and/or metabolic disorders, viral and postpartum, including many idiopathic cases. Under evolution, the left ventricular volume, the parietal tension and energy expenditure of this chamber increases. It is unleashed a positive feedback mechanism that determines the progressive cardiac remodeling, with marked cardiomegaly, spherical deformation of the left ventricle (LV) and stretch of the cords of the mitral valve (MV), whose annulus, almost always, is also dilated. The progression of these mechanisms generates a frequent late complication of DC, the functional mitral insufficiency (FMI) or secondary, as defined due to lack of intrinsic degeneration of the leaflets or the subvalvular structure [2,3].

The volume overload of the LV determined by the FMI is considered critical in the pathogenesis of subsequent ventricular dysfunction. It worsens, dramatically, the functional level and has a great negative impact on survival of patients with DC, leading to raise of mortality rate to about 70% in the first 12 months consecutive to detection of FMI, regardless of its seriousness at the moment of clinical detection [4,5].

Although heart transplantation is the gold standard of treatment, most patients are excluded from such treatment, the older ones, with comorbidities or socioeconomic limitations unavoidable. The controversies that accompany the currently available surgical alternative to correct the FMI and attempt to reconstruct the ovoid shape of the LV in the same surgery, led to the study presented herein. The anatomy of the MV and pathophysiology of FMI, as well as surgical options introduced over the years to repair the FMI, in DC, will be reviewed, focusing on the contribution of national authors.

ANATOMY AND PHYSIOLOGY OF THE MITRAL VALVE

The mitral valve apparatus consists of six elements, i. e., the valve leaflets, its implantation annulus, the chordae tendinae, the papillary muscles and surrounding LV wall. The wall of the left atrium (LA) is now also included in the mitral apparatus, because its rapid relaxation increases the ventricular atrial pressure gradient, before the initiation of ventricular systole, contributing in this manner for the immediate closure of the MV. Furthermore, the dilation of

the LA may cause FMI when deforming the base of the posterior leaflet of the MV that is in continuity with the endocardium, without any anatomic support [4,6-9].

The total area of the anterior and posterior leaflet of the MV is 2.5 times higher than the level of left atrioventricular junction, so as to provide a safety margin in the formation of a zone of coaptation to ensure perfect systolic pressure [10]. Interestingly, the area of the two leaflets is similar, so that, having much smaller base, the anterior leaflet is much wider than the posterior one, and its free edge tours much more during the cardiac cycle [11].

It is also important to note that, besides the two commissures that separate the leaflets, there are generally two well-marked fissures that divide the posterior leaflet into three parts (P1, P2 and P3), numbered from the superior left commissure, each one, roughly, with area similar to 1/3 of the area of the anterior leaflet. In the latter, portions corresponding to them, designated A1, A2 and A3 can be imagined by the virtual extension of the fissures, as this leaflet does not have such fissures [12].

The anterior mitral leaflet, whose length is about 1/3 of the annular perimeter, it is implanted in the anterior portion of the annulus, composed of the fibrous skeleton of heart, little extendable and in anatomical continuity with the aortic root. During ventricular filling, the mitral annulus increases in size and becomes more circular, with cross-sectional area in adults of approximately five to 11 cm² and, midway through the ventricular systole, it becomes more elliptical and reaches its minimum area, about 25% lower. When the MV in a closed position is observed over nearly edge-on, most of the top of the zone of apposition of the leaflets is located below the plane of the atrioventricular junction, but it rises near the commissures, so as to provide conformation of the saddle to the atrial surface of the leaflets [6,13-16].

Viewed from the LA, two conical muscle projections, the papillary muscles, are aligned with the mitral commissures. Just as the commissures, papillary muscles began to be called "lower right" and "upper left" based on a recent study by computed tomography, which describes the cardiac structures in accordance with the classical anatomical projections. The papillary muscles arise from the apical end and the middle third from the ventricular wall and, although they are described over the years as two individual endoluminal protrusions, they correspond, more commonly, to two neighboring muscle groups, whose base is sometimes merged or interconnected by muscle or fibrous bridges. The extreme merger of them is the anatomical substrate of the parachute MV, a congenital malformation susceptible to mitral stenosis [9].

The systolic contraction of the papillary muscles precedes the rest of the LV wall and tightens the tendinae chordae before occurrence of a great increase in

intraventricular pressure. With this increase, the surfaces of the leaflets overlap slightly below or at the level of the atrioventricular junction, sealing it, while the more central portions of the leaflets are rounded, slightly to the interior of the LA.

The worsening of the DC is accompanied by spherical deformation of the left ventricle with consequent deleterious effect, represented by the withdrawal of the papillary muscles to each other and in relation to the long axis of the pre-existing ellipsoid ventricular, so that its base of implantation approaches the level of the MV. In an analogy, one should remember how the walls of the balloon, when filled, they approach the mouth that breathes it. This biomechanical deformation makes the force resultant of papillary traction may be applied to MV more tangentially, widening the stretch of cords, especially the most central ones. Consequently, the closure of the MV, the excursion of the leaflets and, in particular, the medial portion of them, is constrained in its insertion impaired, with reduced coaptation surface and facilitating the emergence of FMI [17,18].

For these reasons, the greater the papillary displacement, the greater the closure plan of the MV sinks in relation to the annular plan. The average distance between these two plans, described as the coaptation depth of MV is usually 4.1 ± 1.6 mm in normal individuals, and as we will see in this study, its very sharp increase represents a marker for poor outcome in mitral valve [19,20].

The LV dilation almost always stretches the mitral annulus, but contrary to expectations, the degree of dilation of the LV and annulus may worsen somewhat independently from one another [13]. In dilated annulus, the physiological systolic annular contraction is compromised and added to the restriction on systolic excursion of the leaflets, culminates in FMI. Faced with the interaction of the pathophysiological mechanisms described, it is understandable why the FMI, in general, is expressed by a single jet, central, in echocardiography, particularly in idiopathic DC [19].

SURGICAL TREATMENT OF DILATED CARDIOMYOPATHY

In 1984, the group of Harvard University was the precursor of mitral valve surgery as an adjunct to clinical therapy of FMI, in DC, based on the assumption that the correction of the FMI would determine mandatory increase in systolic volume, because it would be returning only anterograde, regardless of left ventricular ejection fraction. As a result, the heart minute volume would increase and LV volume overload would be reduced, with consequent decrease in end-diastolic pressure of this chamber [21].

However, Bolling et al. [22], from the University of

Michigan, had the merit of proposing the undersizing of the mitral annulus in plastic repair of FMI, because they believed that with the implantation of a prosthetic mitral ring smaller than usual, the authors would obtain, in addition to the correction of FMI, the additive effect, very desirable, of reshaping negatively the portion of the LV adjacent to the mitral annulus in order to optimize the reduction of end diastolic volume and facilitate the return of ventricular ellipsoid conformation. The absence of mortality in the first series of 16 consecutive patients, together with the improved postoperative clinical attracted the interest of the medical community for the procedure. Average follow-up of 40 months found a reduction in the functional class by the New York Heart Association (NYHA) of 2.8 to 1.3, in 44 patients. In addition, the absence rate of hospital admission for treatment of DC stood at 88%, 82% and 72% at 1, 2 and 5 years postoperatively.

Even if other researchers, as Bishay et al. [23] and De Bonis et al. [24] also have subsequently obtained similar results, it is important to remember that this surgical approach was at first considered a very daring, because at the time, mitral valve replacement in patients with primary severe MI, with 30% or less of LV ejection fraction, was considered high risk, since they feared the poor tolerance of the left ventricle to adapt to the sudden increase in afterload resulting from the elimination of the regurgitation fraction into the chamber of low impedance, i.e., the LA. This concept began to be debunked in 1987 by Corin et al. [25] and, currently, is completely redesigned. It is known that in the decompensated chronic MI, the afterload of the LV actually increases when the reduction of the impedance determined by the regurgitation fraction is supplanted by increase of the ventricular parietal tension, as teaches the Laplace'law ($\sigma = p \times r/2h$, where σ is the parietal tension and, p, r and h, represent respectively, the pressure, the radius of curvature and thickness of the LV). Indeed, when analyzing the morphofunctional repercussion of severe FMI it seems that LV dilation is capable of generating the highest ratio between the radius of curvature and thickness of the LV, as well as the lower mass-volume of the ventricular chamber, among all other possible injuries of the four heart valves [26].

Although the emergence of FMI in the advanced stages of dilated cardiomyopathy of either ischemic or idiopathic origin worses the prognosis, it remains controversial the interpretation of this fact. It is logical to conceive that the additional LV overload aggravates a condition by itself that is already quite adverse. With this reasoning, the FMI can be considered a therapeutic target, even if its resolution determines only a symptomatic improvement, time-limited and not associated with major impact on survival [27]. The perception that in patients undergoing partial ventriculectomy (Batista operation), the functional

improvement seemed more evident in patients in which the mitral regurgitation was corrected simultaneously reinforces this concept [26].

However, there is a chance that the MI can only represent a mere indicator of worsening of ventricular myocardial function, but this a major determinant of clinical worsening. In this dilemma is the crux of the decision to recommend surgical treatment of the FMI, as if it represents nothing but the final denouement of the dysfunction and progressive ventricular dilation, the correction of functional MI may have little impact on the natural evolution of the DC and submit the patient to an unnecessary additional risk [26].

Moreover, thanks to new knowledge about the mechanics of mitral regurgitation, evolution in the design and manufacture of valve prostheses, improvement of surgical techniques and innovations in the postoperative treatment, the mortality rate in surgical mitral valve repair or replacement in FMI declined, sharply, to less than two digits [20,28]. However, if the right ventricular function is also severely lowered, the average pressure of the pulmonary artery is greater than 40 mmHg and there is concomitant renal and hepatic insufficiency, it is prudent to contraindicate the procedure, since in these patients the results have been poor [19].

Respecting the selection of cases in a less critical situation than those admitted at the ICU in critical condition, several series have shown, in addition to low postoperative mortality, improvement of symptoms, accompanied by reduced volume and increased left ventricular ejection fraction. Unfortunately, although the mid-term results also seem favorable in terms of survival, the same group that reported the operation in 1998, reported in 2005, a retrospective analysis of all 126 patients who underwent mitral annuloplasty between 1995 and 2002, and found no increase in survival when compared to a similar group who refused the operation and continued under clinical treatment [29].

However, the clear clinical benefit due to the elimination of mitral regurgitation and the low mortality rate reported by the best centers continue providing strong enthusiasm to groups involved in the surgical treatment of the FMI in the DC. Coating devices and ventricular support [28] seem to optimize the surgical procedure, but still require long-term studies and are not available for use in larger scale yet.

Furthermore, industry interest in the field of FMI has led to the development and clinical testing of some percutaneous procedures in order to duplicate the results of surgery, a priori, in a less invasive manner [30]. Based on the favorable evidences with respect to symptomatic palliative care, but considering the lack of long-term prospective, multicenter, randomized studies, McCarthy

[31] introduced the topic in a pre-meeting of the AATS in April 2009. The author concluded that, at the time, surgical correction of the FMI can be indicated, but still can not be recommended for inclusion in the compulsory treatment of DC associated to FMI.

One should consider that this field should still present a significant evolution, to the extent that promising technical innovations in the surgical treatment of the FMI continue to be introduced [32,33]. If mortality remains significant in the waiting lines for heart transplantation, it may be that the surgical treatment of the FMI will constitute a bridge to transplantation in refractory DC. One should also remember that in some cases, more rarely, the DC may be reversed and in such cases the correction of FMI may be used as a bridge to healing [32]. In addition, there are surgical alternatives such as cardiomyoplasty [34], myocardial revascularization in ischemic DC [19], partial left ventriculectomy (Batista operation) [35], Cox procedure [36], ventricular resynchronization [37], implantation of a cardioverter-defibrillator [38], and even artificial ventricles [39], whose aggregation concomitant or a posteriori of surgical correction of the FMI can improve the long-term survival.

THE IMPORTANCE OF PRESERVATION OF THE SUBVALVULAR APPARATUS IN CORRECTION OF FUNCTIONAL MITRAL INSUFFICIENCY

In 1956, Rushmer et al. [40,41] found that at the beginning of ventricular systole, the contraction of the papillary muscles promotes both the shortening of the long axis as increasing the diameter of the basal portion of the LV, and found that this pre-ejective deformation increases parietal tension in order to increase contractile efficiency and promote the subsequent systolic ejection. The next decade, Lillehei et al. [42,43] has shown very significant reduction in operative mortality from 37% to 14% when the authors started to preserve the leaflets and/or subvalvular apparatus, fully or partially.

However, the fear that the maintenance of the subvalvular apparatus might interfere with the function of synthetic valve prostheses available at the time, or that the technique might involve the implantation of prosthesis with size less than the ideal, the change proposed by Lillehei won little acceptance.

It was up to Miller et al. [44], in 1979, to renew the interest in the preservation of the subvalvular apparatus in valve replacement of MI, when they emphasized the great benefit of removing the risk of ventricular rupture. This surgical procedure was also embraced and emphasized by David et al. [45-49], in Canada, and Hetzer et al. [50], in Germany, in successive publications that showed improvement in both survival and postoperative function of the LV. However,

even subsequent demonstrations of favorable effect on long-term survival [51,52] made this technical resource have been systematically adopted as the standard of surgical practice [53].

In a recent meta-analysis, Athanasiou et al. [53] reviewed the experience of 17 groups, with the preservation of the subvalvular apparatus in mitral valve replacement in different clinical conditions, both from a functional or etiological standpoint. They suggested that the concept is important and should be considered because the evidence that both early and long-term results may improve when the ventricular-mitral continuity is preserved. The authors emphasized, however, that the operative decision should be individualized, based on the valve anatomy, etiopathogeny and left ventricular function, and they recommended that the surgeon is acquainted with more than one surgical technique to preserve the subvalvular apparatus. This observation is important for the surgeon to choose the technique that best fits the anatomical and functional conditions found. Intraoperative echocardiography support is important for monitoring the postoperative course, and to promptly detect any complications relevant to the technique used.

A closer analysis at the results contained in this review also shows that as much as the early mortality and that found at five years of evolution, the comparison between the preservation of the subvalvular apparatus versus its resection was not statistically significant in most studies, raising, in our opinion, that maintenance of the controversy, although with a tendency to favor the preservation of the subvalvular apparatus.

It is also important to notice that despite the positive evidence, many groups remain reluctant to employ the techniques of preservation due to fear of possible complications even fatal. Among these are included the possibility of obstruction of LV outflow tract, prosthetic dysfunction imposed by the permanence of the subvalvular apparatus, undesirable deformations of ventricular geometry, papillary muscle rupture and postoperative embolism. In addition, there is dehiscence in the attachment of preserved leaflets, sutured to the fixing ring and/or the valve annulus, and poor coaptation of the prosthesis in the anatomic ring, resulting in paravalvular leak and need for reoperation [54-61].

Another word of caution is implicit by the existence of many different techniques of preservation of parts or all of the valve apparatus, which means that neither is ideal, and perhaps, appropriate for all cases. Therefore, in 1982, one of the authors (PRBE) and associates, even without taking into account the possibility of valve replacement in the context of DC, tested five techniques to preserve the mitral subvalvular apparatus in 23 patients with rheumatic mitral valve disease - in some, calcified - who had undergone valve replacement: a) attachment of the top of the papillary muscles in the posterior ring in thirteen patients (Figure 1), b) attachment of the papillary muscles and tendinae chordae to the posterior annulus in four patients (Figure 2), c) partial excision of the anterior leaflet with attachment of its set of cords and preservation of the tendinae chordae of posterior leaflet in four patients (Figure 3), and 4) preservation of the entire mitral subvalvular apparatus in two patients (Figure 4).

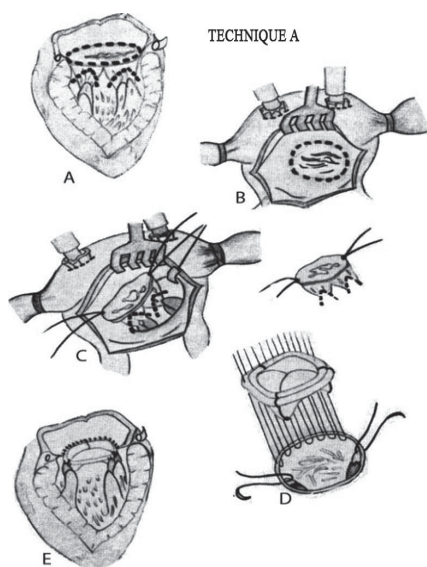


Fig. 1 - Mitral prosthesis with preservation of subvalvular system components: attachment of the top of the papillary muscles to the posterior annulus (Évora et al., Braz J Cardiovasc Surg. 1988; 3 (1):36-49)

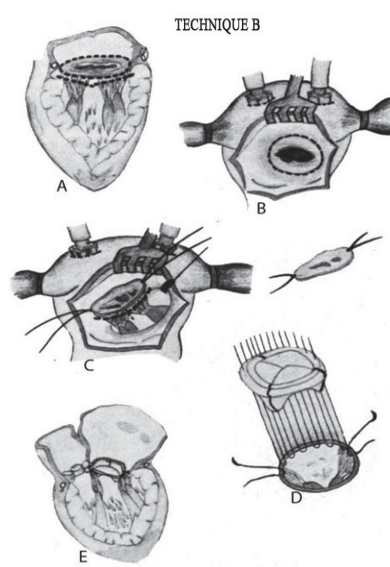


Fig. 2 - Mitral prosthesis with preservation of subvalvular system components: attachment of the papillary muscles and tendinae chordae to the posterior annulus (Évora et al., Braz J Cardiovasc Surg. 1988; 3 (1):36-49)

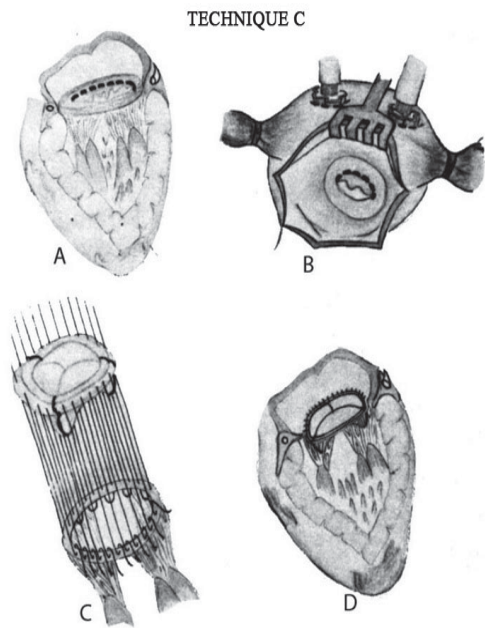


Fig. 3 - Mitral prosthesis with preservation of subvalvular system elements: partial excision only of the anterior leaflet with attachment of their papillary muscles of tendinae chordae (Évora et al. *Braz J Cardiovasc Surg.* 1988; 3 (1):36-49)

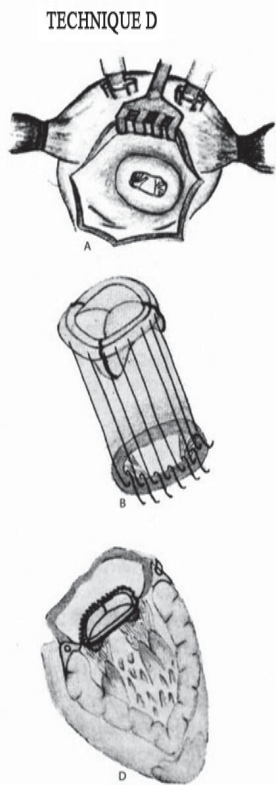


Fig. 4 - Mitral prosthesis with preservation of subvalvular system components: preservation of the entire valve apparatus (Évora et al., *Braz J Cardiovasc Surg.* 1988; 3 (1):36-49)

One should add to these four variants that from David et al. of partial excision of the anterior leaflet and plication of the posterior one (Figure 5) [62].

In Brazil, it is important to emphasize the studies by Gomes et al. [63] and Benfatti et al. [64] about the benefits of MV replacement using the technique of cross papiloplexia in patients with heart failure and moderate/severe MI (Figure 6). In these studies, the group found that this technique was able to promote a significant left ventricular functional improvement as well as favorable ventricular and atrial remodeling.

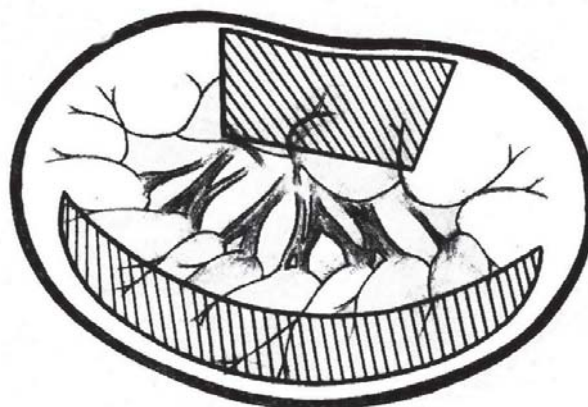


Fig. 5 - Mitral prosthesis with preservation of subvalvular system components: partial excision of the anterior leaflet and reduction of the posterior leaflet by keeping their borders as copied from David TE (*Ann Thorac Surg.* 1986; 41 (6) :680-2), (Évora et al., *Braz J Cardiovasc Surg* 1988; 3 (1):36-49)

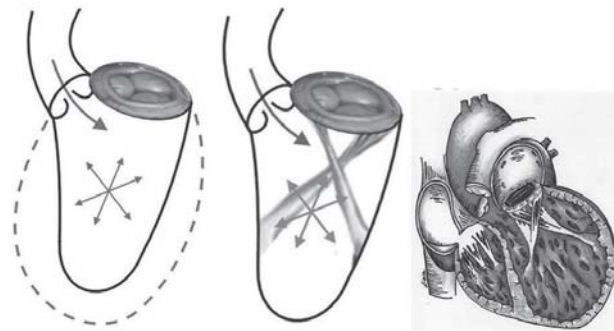


Fig. 6 - Mitral prosthesis with preservation of subvalvular system components: crossed papiloplexy. (Gomes et al., *Braz J Cardiovasc Surg.* 2005; 20 (3):340-5)

Some surgeons use to preserve the continuity of the valve annulus to the LV wall, according to the valve deformity, or calcification, the subvalvular apparatus of only one of the leaflets. This approach is a matter of caution. The function of the papillary muscles and the cords, was eloquently compared to a pair of gymnasts on parallel bars (Figure 7). When the gymnasts (cords) moving toward the parallel bars (mitral annulus), bring the soil (LV wall) with them and thereby avoid excessive hiperdistention of the LV cavity. When one of the cords is cut, only one gymnast works, and the unsupported LV portion thins and dilates. When both the anterior and posterior cords are sectioned, the gymnasts do not have the arm to rise and, in this situation the heart loses its spherical shape, the walls are thinning and dilation throughout the heart cavity occurs [65,66].

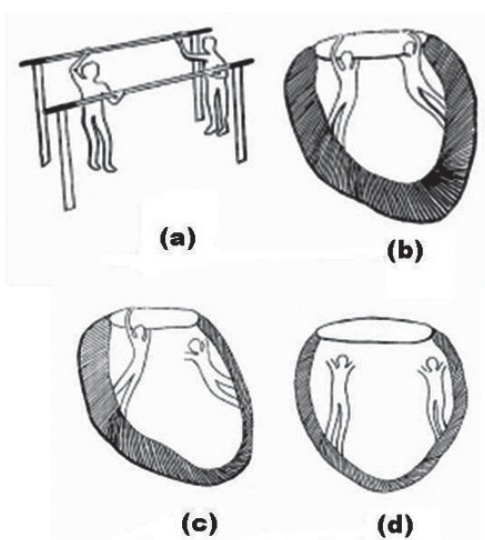


Fig. 7 - (a) The parallel bars correspond to the mitral annulus, (b) The arms of the gymnasts are the tendinae chordae and the papillary muscles are the bodies. The soil is the left ventricular wall; (c) Partial resection of the chordae, (d) Complete resection of chordae. Effect of resection of the chordae - Note the dilation and thinning in places where the chordae were removed partially or completely. (Reproduced from: Kumar AS. *Ind J Thorac Cardiovasc Surg* 2004;20:115-16.)

One should add that, even among the major supporters of complete or partial preservation of the mitral apparatus, some authors do not recommend, in unfavorable cases, characterized by intense scar fibrotic subvalvular process, accompanied or not by gross calcification of the valve annulus, as often occurs in rheumatic mitral stenosis [53]. In spite of these observations and, particularly in the DC, it is important to use the techniques of preservation of valve apparatus, because in addition to conformational and hemodynamic advantages, the risk of rupture of the postero-basal LV wall, one of the most catastrophic

complications of mitral valve replacement is almost eliminated by this tactic [65]. One should be noted, even the attractive option to preserve the MV completely, thanks to the endovascular implant of the prosthesis. [67,68].

Although in the mitral valve replacement in primary MI is recommended not to impose excessive tension to the subvalvular apparatus, in order to avoid the complications mentioned above, more recently, contrary recommendations have been raised. An example is pulling the cords or the top of the papillary muscles in order to anchor them in the anatomical ring, along the ipsilateral commissures, in order to get the mechanical benefit of internal reconfiguration, immediate, of ventricular ovoid. Although this conceptual change is attractive, we can criticize the possible adverse effect, hypothetical, to determine the undesirable restriction to ventricular diastolic filling. The technique has increased the life expectancy of the DC with FMI at the end of five years to about 60%, which superimposes the results of heart transplantation, although survival have been hampered by mortality hospital of 16.1%, due to the research have included cases in very poor clinical condition. Further, related techniques will be highlighted, also introduced in the country [32].

VALVE REPLACEMENT OR PLASTY IN DILATED CARDIOMYOPATHY?

First we must consider that, as patients with DC remain so after the surgery, the purpose of surgical correction of the FMI is to reduce symptoms and prolong life expectancy [19]. Another important aspect is the assessment of the need to associate the tricuspid valve surgery to the surgical procedure, as there are groups [69] preconizing double annuloplasty, mitral and tricuspid, in the first decompensation of DC, but the vast majority of surgeons still believes that the surgical repair of FMI should be reserved for patients with severe FMI, in the final stages of DC [70].

Despite the results of valve repair and replacement can be superimposed [71], for most, mitral annuloplasty is a surgical procedure of choice [26,72-77], while others, like Calafiore et al. [19], are eclectic as the surgical option, arguing, however, that the valve replacement is necessary when the distance between the left atrioventricular junction and the top of the valve coaptation zone, measured by echocardiography and called coaptation depth of mitral valve, is greater than 11 mm, because as a rule, there was recurrence of the FMI in this subgroup of patients who underwent surgery by their team. De Bonis et al. [78], suggest that when it is added the statement by Alfieri in respect to annuloplasty, one should obtain favorable results even in these cases.

One should also consider that in the DC with FMI, the

tolerance for failure in the valve repair is very small, because of clinical comorbidities that usually accompany the severe depletion of cardiovascular function and age, the latter often more advanced [22, 26]. For this reason, many surgeons fear the implementation of plasties of time-consuming type, involving greater technical complexity, as well as others fear the potential interference with the movements of occlusion and opening of synthetic prostheses, while preserving the subvalvular structure. Another aspect worthy of criticism is about the proposal of undersizing the diameter of the prosthesis, and the possibility of creating obstruction in the LV inlet, when prostheses with effective useful orifice smaller than synthetic prostheses of the same diameter. Dancini et al. [79], at Inco-HCFMUSP developed a prospective study of 28 patients divided into three groups, as the surgical technique in the correction of chronic MI. Although the sample was small, the authors could show that valvuloplasty offers greater benefit than valve replacement, whether it preserves both leaflets or only the posterior leaflet.

On the other hand, if the echocardiographic and intraoperative analyses show that the FMI can be resolved with a plasty of relatively simple fulfillment, fast and reliable, this option should be valued, but if the surgeon anticipates that the repair will be difficult, with greater chance of poor outcome, which is more common in cases where the annular dilatation is not significant, the decision of valve replacement is certainly the best. In the initial experience of the Cleveland Clinic, with 44 patients, the preferential option for the repair had to be reversed for valve replacement, due to technical reasons in 20% of them [80].

Other important information comes from the multicenter prospective randomized ACORN study, which included patients with DC and FMI in functional classes III and IV according NYHA, with an ejection fraction less than 35%. Most (84.2%, n=155) of patients underwent annuloplasty and 25.8% of them (n=29) the valve replacement, with preservation of subvalvular apparatus in most of them. There was improvement in functional class of 3.9 ± 0.3 to 2.0 ± 0.6 and quality of life at 3, 6, 12 and 18 months of postoperative, assessed by specific questionnaires or stress test. The option for valve replacement was up to the surgeon and has been applied most often when it was found that the repair could result unsatisfactorily [28].

In turn, it is appropriate in many situations, the argument from Buffolo et al. [81], that the drawback of the implantation of a valvular bioprosthesis in DC is irrelevant, since the life expectancy of patients should be lower than that of valve replacement, which decay, almost always, could only express themselves clinically after 7-8 years of implantation. One should add that the implantation is safe, fast and reliable for those patients, because in addition to potentially eliminate the risk of recurrence of the FMI, it may also

promote reverse remodeling of the heart base when it is chosen valve replacements one or two numbers less than the anatomical ring [81,82].

As noted above, at the same time one can reshape the ventricular ellipsoid through the application of traction and/or reconfiguration of the papillary muscles. However, recalling the saying of Voltaire that sometimes the great is enemy of the good, the surgeon should always take precedence, first, for the safety of valve replacement in order to not incur complications such as leak, demanding reoperation. This recommendation is relevant in clinical cases of highest risk and facing surgical conditions and/or adverse valvular disease, most often characterized by gross annular calcification.

EFFECTS OF PRESERVATION OF THE MITRAL SUBVALVULAR APPARATUS IN RIGHT VENTRICULAR (RV) FUNCTION

It is expected that the improvement of left ventricular function should automatically lead to improvement in RV function. Facing this expectation, a Swedish study showed statistically significant improvement in right ventricular function after preservation of the LV chords. This improvement in RV function has been clearly documented by studies with radioisotopes and is an important area of future investigation in patients with severe pulmonary arterial hypertension, who can be carriers of RV dysfunction prior to surgery and who can benefit from the preservation of LV chords [83].

BRAZILIAN CONTRIBUTION IN THE CORRECTION OF THE FUNCTIONAL MITRAL INSUFFICIENCY IN DILATED CARDIOMYOPATHY

The group at the Federal University of São Paulo, headed by Prof. Enio, Buffolo, was pioneer in the country when introduced, promoted and encouraged the correction of the FMI due to DC.

The experience of the group began in 1995, reached until 2005, 116 patients undergone valve replacement, almost all by bioprosthesis. After a mean time of follow-up of 38 ± 16 months, the mortality hospital rate was 16.3% (19/116), followed by the actuarial survival curve with a slight decrement, reaching satisfactory late mortality rate, comparable to that of heart transplants. Furthermore, there was significant improvement both clinical and echocardiographic, particularly in terms of reduction of LV sphericity. They concluded that, despite the high mortality rate, the technique is a feasible alternative in the treatment of terminal DC associated with FMI. In 2006, the experience was reported abroad, by Buffolo et al. [32], and in Brazil by Breda et al. [84]. It is worth adding that, especially at the

beginning of the experiment severe cases were included, some of them, admitted to ICU and under use of endovenous inotropic agents, which contributed to the overall mortality rate, higher than that resulting from more selective studies on the selection criteria. Furthermore, the authors had the merit of associating the mitral valve to an innovative idea, represented, as already described, by the search for LV ellipsoid reformation.

At InCor-HCFMUSP, also in order to obtain the immediate reversal of ventricular remodeling, Puig et al. [85] proposed in 2002, the replacement of MV with the traction of the tendinae cordae, fixed on the upper surface of the prosthetic ring. In mid- to long-term follow-up [86], the results were favorable in terms of symptoms. There was also a reduction of left ventricular systolic and diastolic end volumes until the 3rd month of postoperative, with stabilization of the process of cardiac remodeling so on.

It is also important to highlight the original idea of Gomes et al. [63], in Belo Horizonte, of association of crossed papilopexy to valve replacement in patients with DC and FMI, and have been useful in reversing at least partially, the dilation of the left atrium and ventricle, with significant functional recovery of the latter [64].

Besides the aforementioned, it is worth noting the morphological study of Hueb et al. [13] in 2001, which changed the paradigm that the mitral annular dilatation spared the implantation of the anterior leaflet. The authors demonstrated that this portion of the mitral annulus is also dilated, although to a lesser degree. This information has direct effect on the selection of surgical approach in mitral annuloplasty in MI [87].

CONCLUSION

The DC is a chronic, progressive disease, focused on cardiac remodeling, with LV and mitral annulus dilation, which may trigger a vicious cycle of extreme gravity when it generates FMI. Many authors have shown that the current mortality rate in the correction of the FMI in the DC is low and that the surgical procedure can improve symptoms and reduce the number of readmissions due to decompensation of the DC, thereby improving the quality of life. However, the benefit in the long-term survival still needs to be demonstrated, apparently, because the correction of the FMI does not alter the progression of underlying myocardial dysfunction.

REFERENCES

1. Barreto ACP, Ramires JAF. Insuficiência cardíaca: um problema de saúde pública. *Rev Bras Cardiol.* 2000;2:142-7.
2. Kono T, Sabbah HN, Rosman H, Alam M, Jafri S, Goldstein S. Left ventricular shape is the primary determinant of functional mitral regurgitation in heart failure. *J Am Coll Cardiol.* 1992;20(7):1594-8.
3. Perloff JK, Roberts WC. The mitral apparatus. Functional anatomy of mitral regurgitation. *Circulation.* 1972;46(2):227-39.
4. Blondheim DS, Jacobs LE, Kotler MN, Costacurta GA, Parry WR. Dilated cardiomyopathy with mitral regurgitation: decreased survival despite a low frequency of left ventricular thrombus. *Am Heart J.* 1991;122(3 Pt 1):763-71.
5. McCarthy PM. Valve surgery for patients with left ventricular dysfunction. In: *Heart failure: a combined medical and surgical approach*, 2007. 10:154.
6. Ho SY. Anatomy of the mitral valve. *Heart.* 2002;88(Suppl 4):iv5-10.
7. Fortuna ABP. Anatomia cirúrgica da válvula mitral. Aspecto valvar [Tese de Livre Docência]. Campinas: Faculdade de Ciências Médicas, UNICAMP;1983.
8. Levy MJ, Edwards JE. Anatomy of mitral insufficiency. *Prog Cardiovasc Dis.* 1962;5:119-44.
9. Frater RW. Attitudinally correct designation of papillary muscles. *J Heart Valve Dis.* 2003;12(5):548-50.
10. Boltwood CM, Tei C, Wong M, Shah PM. Quantitative echocardiography of the mitral complex in dilated cardiomyopathy: the mechanism of functional mitral regurgitation. *Circulation.* 1983;68(3):498-508.
11. May-Newman K, Yin FC. Biaxial mechanical behavior of excised porcine mitral valve leaflets. *Am J Physiol.* 1995;269(4 Pt 2):H1319-27.
12. Carpentier A. Cardiac valve surgery-the "French correction". *J Thorac Cardiovasc Surg.* 1983;86(3):323-37.
13. Hueb AC, Jatene FB, Moreira LFP, Pomerantzeff PMA, Mioto BM, Chabelmann RC, et al. Estudo comparativo do anel valvar mitral e do ventrículo esquerdo na cardiomiopatia dilatada. *Rev Bras Cir Cardiovasc.* 2001;16(4):354-63.
14. Bolling SF. Mitral valve reconstruction in the patient with heart failure. *Heart Fail Rev.* 2001;6(3):177-85.
15. Ormiston JA, Shah PM, Tei C, Wong M. Size and motion of the mitral valve annulus in man. I. A two-dimensional echocardiographic method and findings in normal subjects. *Circulation.* 1981;64(1):113-20.
16. Komoda T, Hetzer R, Uyama C, Siniawski H, Maeta H, Rosendahl UP, et al. Mitral annular function assessed by 3D imaging for mitral valve surgery. *J Heart Valve Dis.* 1994;3(5):483-90.

17. He S, Fontaine AA, Schwammenthal E, Yoganathan AP, Levine RA. Integrated mechanism for functional mitral regurgitation: leaflet restriction versus coapting force: in vitro studies. *Circulation*. 1997;96(6):1826-34.
18. Cuenca JJC. Tratamiento quirúrgico de la insuficiencia cardíaca. Restauración ventricular y cirugía de la válvula mitral. *Rev Esp Cardiol Supl*. 2006;6(supl F):71-81.
19. Calafiore AM, Gallina S, Di Mauro M, Gaeta F, Iaco AL, D'Alessandro S, et al. Mitral valve procedure in dilated cardiomyopathy: repair or replacement? *Ann Thorac Surg*. 2001;71(4):1146-52.
20. Ngaage DL, Schaff HV. Mitral valve surgery in non-ischemic cardiomyopathy. *J Cardiovasc Surg (Torino)*. 2004;45(5):477-86.
21. Chen FY, Adams DH, Aranki SF, Collins JJ Jr, Couper GS, Rizzo RJ, et al. Mitral valve repair in cardiomyopathy. *Circulation*. 1998;98(19 Suppl):II124-7.
22. Bolling SF, Deeb GM, Brunsting LA, Bach DS. Early outcome of mitral valve reconstruction in patients with end-stage cardiomyopathy. *J Thorac Cardiovasc Surg*. 1995;109(4):676-82.
23. Bishay ES, McCarthy PM, Cosgrove DM, Hoercher KJ, Smedira NG, Mukherjee D, et al. Mitral valve surgery in patients with severe left ventricular dysfunction. *Eur J Cardiothorac Surg*. 2000;17(3):213-21.
24. De Bonis M, Lapenna E, La Canna G, Ficarra E, Pagliaro M, Torracca L, et al. Mitral valve repair for functional mitral regurgitation in end-stage dilated cardiomyopathy: role of the "edge-to-edge" technique. *Circulation*. 2005;112(9 Suppl):I402-8.
25. Corin WJ, Monrad ES, Murakami T, Nonogi H, Hess OM, Kraysenbuehl HP. The relationship of afterload to ejection performance in chronic mitral regurgitation. *Circulation*. 1987;76(1):59-67.
26. Carabello BA. The current therapy for mitral regurgitation. *J Am Coll Cardiol*. 2008;52(5):319-26.
27. Buffolo E, Paula IAM, Palma H, Branco JNR. Nova abordagem cirúrgica para o tratamento de pacientes em insuficiência cardíaca refratária com miocardiopatia dilatada e insuficiência mitral secundária. *Arq Bras Cardiol*. 2000;74(2):129-34.
28. Acker MA, Bolling S, Shemin R, Kirklin J, Oh JK, Mann DL, et al; Acorn Trial Principal Investigators and Study Coordinators. Mitral valve surgery in heart failure: insights from the Acorn Clinical Trial. *J Thorac Cardiovasc Surg*. 2006;132(3):568-77.
29. Wu AH, Aaronson KD, Bolling SF, Pagani FD, Welch K, Koelling TM. Impact of mitral valve annuloplasty on mortality risk in patients with mitral regurgitation and left ventricular systolic dysfunction. *J Am Coll Cardiol*. 2005;45(3):381-7.
30. Merino SFG, Ebner A, Alvarez E, Silva E. Sistema Mitralign de anuloplastia mitral percutânea para pacientes com regurgitação mitral e insuficiência cardíaca congestiva: Experiência First-In-Man. *Rev Bras Cardiol Invas*. 2009;17(2):183-9.
31. McCarthy PM. Curso pré-Congresso AATS, CTSnet;2009.
32. Buffolo E, Branco JN, Catani R; RESTORE Group. End-stage cardiomyopathy and secondary mitral insufficiency surgical alternative with prosthesis implant and left ventricular restoration. *Eur J Cardiothorac Surg*. 2006;29(Supl 1):S266-71.
33. Buckberg G, Menicanti L, De Oliveira S, Isomura T; RESTORE team. Restoring papillary muscle dimensions during restoration in dilated hearts. *Interact Cardiovasc Thorac Surg*. 2005;4(5):475-7.
34. Carpentier A, Chachques JC, Acar C, Relland J, Mihaileanu S, Bensasson D, et al. Dynamic cardiomyoplasty at seven years. *J Thorac Cardiovasc Surg*. 1993;106(1):42-52.
35. Batista RJ, Santos JL, Takeshita N, Bocchino L, Lima PN, Cunha MA, et al. Partial left ventriculectomy to improve left ventricular function in end-stage heart disease. *J Card Surg*. 1996;11(2):96-7.
36. Lee AM, Melby SJ, Damiano RJ Jr. The surgical treatment of atrial fibrillation. *Surg Clin North Am*. 2009;89(4):1001-20.
37. Jeevanantham V, Daubert JP, Zareba W. Cardiac resynchronization therapy in heart failure patients: an update. *Cardiol J*. 2009;16(3):197-209.
38. Haqqani HM, Mond HG. The implantable cardioverter-defibrillator lead: principles, progress, and promises. *Pacing Clin Electrophysiol*. 2009;32(10):1336-53.
39. Holman WL, Pae WE, Teutenberg JJ, Acker MA, Naftel DC, Sun BC, et al. INTERMACS: interval analysis of registry data. *J Am Coll Surg*. 2009;208(5):755-61.
40. Rushmer RF, Finlayson BL, Nash AA. Movements of the mitral valve. *Circ Res*. 1956;4(3):337-42.
41. Rushmer RF. Initial phase of ventricular systole: asynchronous contraction. *Am J Physiol*. 1956;184(1):188-94.
42. Lillehei CW. Value of preserving chordal integrity. Both experimental and clinical data. *J Thorac Cardiovasc Surg*. 1963;46:494-5.
43. Lillehei CW, Levy MJ, Bonnabeau RC Jr. Mitral valve replacement with preservation of papillary muscles and chordae tendineae. *J Thorac Cardiovasc Surg*. 1964;47:532-43.

44. Miller DW Jr, Johnson DD, Ivey TD. Does preservation of the posterior chordae tendineae enhance survival during mitral valve replacement? *Ann Thorac Surg.* 1979;28(1):22-7.
45. David TE, Strauss HD, Mesher E, Anderson MJ, Macdonald IL, Buda AJ. Is it important to preserve the chordae tendineae and papillary muscles during mitral valve replacement? *Can J Surg.* 1983;24(3):236-9.
46. David TE, Uden DE, Strauss HD. The importance of the mitral apparatus in left ventricular function after correction of mitral regurgitation. *Circulation.* 1983;68(3 Pt 2):II76-82.
47. David TE, Burns RJ, Bacchus CM, Druck MN. Mitral valve replacement for mitral regurgitation with and without preservation of chordae tendineae. *J Thorac Cardiovasc Surg.* 1984;88(5 Pt 1):718-25.
48. David TE, Ho WC. The effect of preservation of chordae tendineae on mitral valve replacement for postinfarction mitral regurgitation. *Circulation.* 1986;74(3 Pt 2):II16-20.
49. Hetzer R, Bougioukas G, Franz M, Borst HG. Mitral valve replacement with preservation of the papillary muscles and chordae tendineae-revival of a seemingly forgotten concept. I. Preliminary clinical report. *Thorac Cardiovasc Surg.* 1983;31(5):291-6.
50. Hetzer R, Drews T, Siniawski H, Komoda T, Hofmeister J, Weng Y. Preservation of papillary muscles and chordae during mitral valve replacement: possibilities and limitations. *J Heart Valve Dis.* 1995;4(Suppl 2):S115-23.
51. Dottori V, Barberis L, Lijoi A, Giambuzzi M, Maccario M, Faveto C. Initial experience of mitral valve replacement with total preservation of both valve leaflets. *Tex Heart Inst J.* 1994;21(3):215-9.
52. Dubiel TW, Borowiec JW, Mannting F, Landelius J, Hansson HE, Nyström SO, et al. Mitral valve prosthetic implantation with preservation of native mitral valve apparatus. *Scand J Thorac Cardiovasc Surg.* 1994;28(3-4):115-21.
53. Athanasiou T, Chow A, Rao C, Aziz O, Siannis F, Ali A, et al. Preservation of the mitral valve apparatus: evidence synthesis and critical reappraisal of surgical techniques. *Eur J Cardiothorac Surg.* 2008;33(3):391-401.
54. Gallet B, Berrebi A, Grinda JM, Adams C, Deloche A, Hiltgen M. Severe intermittent intraprosthetic regurgitation after mitral valve replacement with subvalvular preservation. *J Am Soc Echocardiogr.* 2001;14(4):314-6.
55. Prabhakar G, Kumar N, Hatle L, al-Halees Z, Duran CM. Accelerated failure of bioprosthesis by entrapment in chordal-sparing mitral valve replacement. *J Thorac Cardiovasc Surg.* 1994;108(1):185-7.
56. Thomson LE, Chen X, Greaves SC. Entrapment of mitral chordal apparatus causing early postoperative dysfunction of a St. Jude mitral prosthesis. *J Am Soc Echocardiogr.* 2002;15(8):843-4.
57. Mok CK, Cheung DL, Chiu CS, Aung-Khin M. An unusual lethal complication of preservation of chordae tendineae in mitral valve replacement. *J Thorac Cardiovasc Surg.* 1988;95(3):534-6.
58. Come PC, Riley MF, Weintraub RM, Wei JY, Markis JE, Lorell BH, et al. Dynamic left ventricular outflow tract obstruction when the anterior leaflet is retained at prosthetic mitral valve replacement. *Ann Thorac Surg.* 1987;43(5):561-3.
59. Esper E, Ferdinand FD, Aronson S, Karp RB. Prosthetic mitral valve replacement late complications after native valve preservation. *Ann Thorac Surg.* 1997;63(2):541-3.
60. Rietman GW, van der Maaten JM, Douglas YL, Boonstra PW. Echocardiographic diagnosis of left ventricular outflow tract obstruction after mitral valve replacement with subvalvular preservation. *Eur J Cardiothorac Surg.* 2002;22(5):825-7.
61. Waggoner AD, Pérez JE, Barzilai B, Rosenbloom M, Eaton MH, Cox JL. Left ventricular outflow obstruction resulting from insertion of mitral prostheses leaving the native leaflets intact adverse clinical outcome in seven patients. *Am Heart J.* 1991;122(2):483-8.
62. Évora PRB, Ribeiro PJF, Brasil JCF, Otaviano AG, Reis CL, Bongiovani HL, et al. Experiência com dois tipos de técnicas para o tratamento cirúrgico da insuficiência mitral: I. Prótese com preservação de elementos do sistema valvar. II. Plastia valvar com reconstrução e avanço da cúspide posterior. *Rev Bras Cir Cardiovasc.* 1988;3(1):36-49.
63. Gomes OM, Gomes ES, Santana Filho GP, Pontes JCDV, Benfatti RA. Nova abordagem técnica para papilopexia cruzada em operação de substituição valvar mitral: resultados imediatos. *Rev Bras Cir Cardiovasc.* 2005;20(3):340-5.
64. Benfatti RA, Pontes JCDV, Gomes OM, Dias AEMAS, Gomes Júnior JF, Gardenal N, et al. Substituição valvar mitral com papilopexia cruzada e constrição anular em pacientes com insuficiência cardíaca. *Rev Bras Cir Cardiovasc.* 2008;23(3):372-7.
65. Kumar AS. Heart strings. *Ind J Thorac Cardiovasc Surg.* 2004;20(3):1156.
66. Talwar S, Jayanthkumar HV, Kumar AS. Chordal preservation during mitral valve replacement: basis, techniques and results. *Ind J Thorac Cardiovasc Surg.* 2005;21(1):45-52.
67. Vander Salm TJ, Pape LA, Mauser JF. Mitral valve replacement with complete retention of native leaflets. *Ann Thorac Surg.* 1995;59(1):52-5.
68. Alsaddique AA. Mitral valve replacement with the preservation of the entire valve apparatus. *Rev Bras Cir Cardiovasc.* 2007;22(2):218-23.

-
69. Radovanovic N, Mihajlovic B, Selestiansky J, Torbica V, Mijatov M, Popov M, et al. Reductive annuloplasty of double orifices in patients with primary dilated cardiomyopathy. *Ann Thorac Surg.* 2002;73(3):751-5.
 70. Kapoor JR. Role of mitral valve surgery for secondary mitral regurgitation in heart failure. *J Am Coll Cardiol.* 2009;53(1):74.
 71. Rothenburger M, Rukosujew A, Hammel D, Dorenkamp A, Schmidt C, Schmid C, et al. Mitral valve surgery in patients with poor left ventricular function. *Thorac Cardiovasc Surg.* 2002;50(6):351-4.
 72. Carpentier A, Chauvaud S, Fabiani JN, Deloche A, Relland J, Lessana A, et al. Reconstructive surgery of mitral valve incompetence: ten-year appraisal. *J Thorac Cardiovasc Surg.* 1980;79(3):338-48.
 73. Enriquez-Sarano M, Schaff HV, Orszulak TA, Tajik AJ, Bailey KR, Frye RL. Valve repair improves the outcome of surgery for mitral regurgitation. A multivariate analysis. *Circulation.* 1995;91(4):1022-8.
 74. Bonow RO, Carabello BA, Chatterjee K, de Leon AC Jr, Faxon DP, Freed MD, et al. ACC/AHA 2006 guidelines for the management of patients with valvular heart disease: a report of the American College of Cardiology/American Heart Association Task Force on Practice Guidelines (writing Committee to Revise the 1998 guidelines for the management of patients with valvular heart disease) developed in collaboration with the Society of Cardiovascular Anesthesiologists endorsed by the Society for Cardiovascular Angiography and Interventions and the Society of Thoracic Surgeons. *J Am Coll Cardiol.* 2006;48(3):e1-148.
 75. Horskotte D, Schulte HD, Bircks W, Strauer BE. The effect of chordal preservation on late outcome after mitral valve replacement a randomized study. *J Heart Valve Dis.* 1993;2(2):150-8.
 76. Jokinen JJ, Hippeläinen MJ, Pitkänen OA, Hartikainen JE. Mitral valve replacement versus repair: propensity-adjusted survival and quality-of-life analysis. *Ann Thorac Surg.* 2007;84(2):451-8.
 77. David TE. Outcomes of mitral valve repair for mitral regurgitation due to degenerative disease. *Semin Thorac Cardiovasc Surg.* 2007;19(2):116-20.
 78. De Bonis M, Lapenna E, La Canna G, Ficarra E, Pagliaro M, Torracca L, et al. Mitral valve repair for functional mitral regurgitation in end-stage dilated cardiomyopathy: role of the "edge-to-edge" technique. *Circulation.* 2005; 112(9 Suppl):I402-8.
 79. Dancini JL, Pomerantzeff PMA, Spina GS, Pardi MM, Giorgi MCP, Sampaio RO, et al. Troca valvar com preservação de cordas e plástica na cirurgia da insuficiência mitral crônica. *Arq Bras Cardiol.* 2004;82(3):235-42.
 80. Bishay ES, McCarthy PM, Cosgrove DM, Hoercher KJ, Smedira NG, Mukherjee D, et al. Mitral valve surgery in patients with severe left ventricular dysfunction. *Eur J Cardiothorac Surg.* 2000;17(3):213-21.
 81. Buffolo E, Paula IAM, Palma H, Branco JNR. Nova abordagem cirúrgica para o tratamento de pacientes em insuficiência cardíaca refratária com miocardiopatia dilatada e insuficiência mitral secundária. *Arq Bras Cardiol.* 2000;74(2):129-34.
 82. Buffolo E, Paula IM, Branco JNR, Carvalho ACC, Mantovani C, Caputi G, et al. Tratamento da insuficiência cardíaca terminal através da correção da insuficiência mitral secundária e remodelação ventricular. *Rev Bras Cir Cardiovasc.* 2001;16(3):203-11.
 83. Dubiel TW, Borowiec JW, Mannting F, Landelius J, Hansson HE, Nyström SO, et al. Mitral valve prosthetic implantation with preservation of native mitral valve apparatus. *Scand J Thorac Cardiovasc Surg.* 1994;28(3-4):115-21.
 84. Breda JR, Palma JHA, Teles CA, Branco JNR, Catalani R, Buffolo E. Miocardiopatia terminal com insuficiência mitral secundária: tratamento com implante de prótese e remodelamento interno do ventrículo esquerdo. *Rev Bras Cir Cardiovasc.* 2006;21(3):283-8.
 85. Puig LB, Gaiotto FA, Oliveira Jr JL, Pardi M, Bacal F, Mady C, et al. Mitral valve replacement and remodeling of the left ventricle in dilated cardiomyopathy with mitral regurgitation: initial results. *Arq Bras Cardiol.* 2002;78(2):224-9.
 86. Gaiotto FA, Puig LB, Mady C, Fernandes F, Tossuniam CE, Pardi MM, et al. Substituição da valva mitral com tração dos músculos papilares em pacientes com miocardiopatia dilatada. *Rev Bras Cir Cardiovasc.* 2007;22(1):68-74.
 87. McCarthy PM. Does the intertrigonal distance dilate? Never say never. *J Thorac Cardiovasc Surg.* 2002;124(6):1078-9.