

# Stents in triple layer in endovascular treatment of expanding abdominal aortic aneurysm

*Stents em tripla camada no tratamento endovascular do aneurisma de aorta abdominal em expansão*

Guilherme B. B. Pitta<sup>1</sup>, Cezar Ronaldo Alves da Silva<sup>2</sup>, Josué Dantas de Medeiros<sup>3</sup>, Adriano Dionisio Santos<sup>4</sup>

DOI: 10.5935/1678-9741.20120018

RBCCV 44205-1357

**Descriptors:** Stents. Aneurysm. Endovascular Procedures.

**Descritores:** Stents. Aneurisma. Procedimentos Endovasculares.

Endovascular treatment of abdominal aortic aneurysm expansion with a transverse diameter of 6.5 cm with triple-layer stents in 88-year-old patient with a history of hypertension, increased cholesterol and smoking evolving with abdominal pain, vomiting and malaise (Fig. 1). The surgical technique used was the placement of stents in triple layer of nitinol manufactured at Braile Biomedica (São José do Rio Preto, Brazil) in right aortic moniliacal position for treatment of abdominal aortic aneurysm and right common iliac artery [1].

Right brachial catheterization was performed with the placement of 5F introducer and 5F pig catheter just to the level of the superior mesenteric artery for contrast injection and for light diagnostic and visceral branches. Through

right inguinitomy, the right common femoral artery was dissected with the passage of 6F introducer with cauterization of common and right external iliac arteries that were tortuous.

Puncture of the left common femoral artery and placement of 5F introducer.

An injection of contrast near the renal arteries was performed with visualization of the superior mesenteric artery, renal, abdominal aortic aneurysm and iliac arteries with visualization of flow with turbulence within the aortic aneurysm sac.

Through the right external iliac artery with 5F Cobra catheter introduced with a hydrophilic wire of 0.035 mm above the renal arteries and exchanged for a super stiff

1. Director of BMA (Brazilian Medical Association). Adjunct Professor of Surgery at UNCISAL; Renorbio Doctoral Advisor, Master Surgery Advisor at UFRGS
2. Vascular Surgeon at Arthur Ramos Memorial Hospital and Specialist in Vascular Surgery by SBACV
3. Vascular Surgeon at Arthur Ramos Memorial Hospital
4. Doctor at Arthur Ramos Memorial Hospital

Correspondence address

Guilherme B. B. Pitta

Rua Hugo Correia da Paz 253 - Farol - Maceió, AL, Brazil.

Zip Code: 57050-730.

E-mail: guilherme@guilhermepitta.com

Work performed at Hospital Memorial Arthur Ramos - Maceió, AL, Brazil.

Article received on February 18<sup>th</sup>, 2012

Article accepted on March 28<sup>th</sup>, 2012

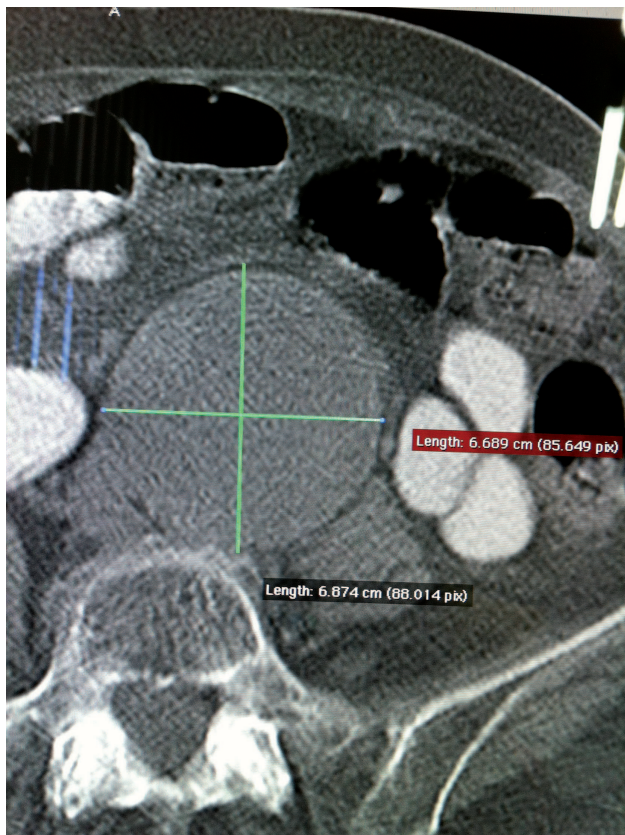


Fig. 1 - AngioCT pre-endovascular treatment of abdominal aortic aneurysm and right common iliac expanding > 6.5 cm in transverse diameter

0.035, with the Cobra catheter and the right femoral introducer being withdrawn, with the passage of the first stent 28 mm in diameter and 13 cm length when fully open.

This first stent had its extremity at the level of the superior mesenteric artery, and on the renal ending at the middle portion of the right common iliac artery.

The second stent of 30 mm in diameter and 11 cm long was with its proximal end just below the renal arteries and its distal end at the level of the right distal common iliac artery.

The third stent of 32 mm in diameter and 11 cm in length was immediately below the renal arteries and above the iliac bifurcation sealing the first two stents, performing the ballooning of the stents in triple layers in the proximal, medial and distal portions.

During angiographic control, predominately central laminar flow was observed with filling predominantly of right iliac arteries and the presence of peri-stent flow with

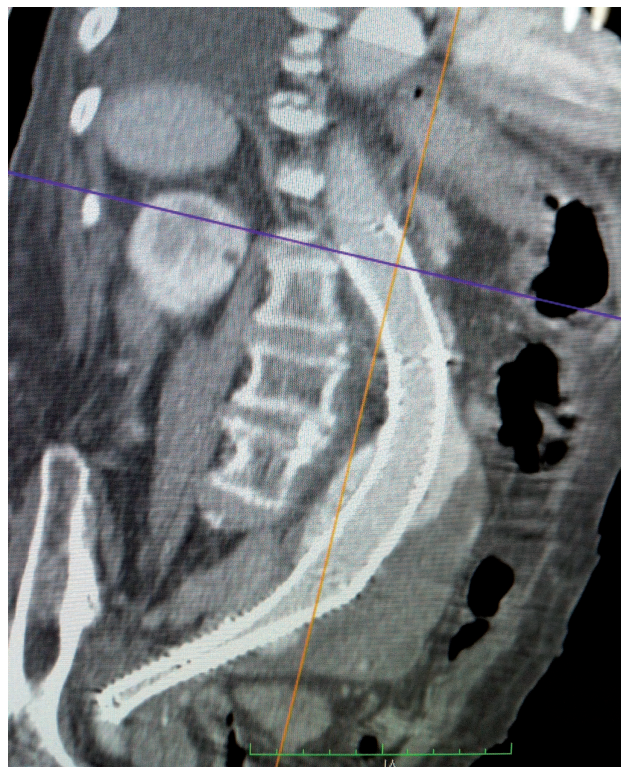

Fig. 2 - Post-stent implantation in triple layer except for abdominal aortic aneurysm and right common iliac

filling of left iliac arteries. The visceral and renal arteries were patent (Fig. 2).

On the fifth postoperative period, angiography was performed in the thoracic aorta, abdominal and iliac arteries with the presence of laminar flow in the interior of stents, partial thrombosis of the aortic aneurysm sac and right iliac arteries, reducing the diameter of the aortic aneurysm to 5.0 cm and peri-stent flow, keeping the left iliac arteries patent. Clinically, the patient was stable conditions, no drugs, maintaining blood pressure, without abdominal pain, good diuresis, without fever, however, with behavior disorders. The patient was discharged after 7 days.

#### REFERENCE

1. Aquino M. Gradiente de pressão na correção endovascular do aneurisma de aorta em porcos com stents tripla camada. [Tese de mestrado]. Porto Alegre: UFRGS, 2012.