



Surgical and non-surgical procedures for eyebrow lift: systematic review and decision flowchart

Procedimentos cirúrgicos e não cirúrgicos para elevação das sobrancelhas: revisão sistemática e fluxograma de abordagem

RICARDO EUSTACHIO DE MIRANDA ^{1*}
SUZANA MATAYOSHI ¹

Institution: Hospital das Clínicas,
Universidade de São Paulo, São Paulo,
SP, Brazil.

Article received: June 2, 2019.
Article accepted: July 8, 2019.

Conflicts of interest: none.

DOI: 10.5935/2177-1235.2019RBCP0235

■ ABSTRACT

Introduction: To review the medical literature regarding the surgical and non-surgical treatments of eyebrow ptosis and to present a decision flowchart for eyebrow lift. **Methods:** A systematic review of the literature available was held in PUBMED following inclusion and exclusion criteria. A flowchart was elaborated to systematize the approach to eyebrow ptosis based on the experience of the authors. **Results:** Several articles were included describing a variety of surgical and non-surgical correction techniques for eyebrow ptosis. The most common surgical approaches were internal eyebrow elevation, direct elevation, temporal elevation, and coronal/pretrichial/endoscopic rhytidoplasty. The non-surgical approaches found were botulinum toxin injections, fillers, and fixation threads. **Conclusion:** There are several surgical and non-surgical procedures described in the literature for lifting of the eyebrow, demonstrating that there is no ideal method for all patients. The use of a flowchart can help carry out a systematic and personalized approach according to the characteristics of each patient. **Keywords:** Eyebrows; Removal; Flowchart; Literature Review as Topic; Blepharoplasty.

¹Universidade de São Paulo, São Paulo, SP, Brazil.

■ RESUMO

Introdução: Realizar levantamento na literatura médica sobre os tratamentos cirúrgicos e não cirúrgicos da ptose de sobrancelha e apresentar um fluxograma de decisão para elevação da sobrancelha. **Métodos:** Revisão sistemática da literatura disponível no banco de dados da PUBMED seguindo critérios de inclusão e exclusão. Elaboração de um fluxograma para abordagem da queda de sobrancelha baseado na experiência dos autores. **Resultados:** Foi encontrada uma abundância de artigos descrevendo diversas táticas cirúrgicas e não cirúrgicas para correção da ptose de supercílio. As táticas cirúrgicas mais comuns foram a elevação interna do supercílio, elevação direta, elevação via temporal e ritidoplastia coronal / pré-triquial / endoscópica. Para a abordagem não cirúrgica foram encontradas o uso de toxina botulínica, preenchimento e fios de sustentação. **Conclusão:** Há diversas táticas cirúrgicas e não cirúrgicas descritas na literatura para elevação da sobrancelha, demonstrando que não há uma tática ideal para todos os pacientes. O uso de fluxograma pode ajudar a realizar uma abordagem sistemática e personalizada e considerando característica de cada paciente.

Descritores: Sobrancelhas; Remoção; Fluxo de trabalho; Literatura de revisão como assunto; Blefaroplastia.

INTRODUCTION

The position of the eyebrow is important both from an esthetic and functional point of view, varying in shape according to race, age and gender. A well-positioned eyebrow is a sign of youth and beauty, with its position being classified in the literature¹.

Besides an esthetic aspect, eyebrow ptosis contributes to excess skin on the eyelid which in extreme cases can impair the visual field².

The execution of blepharoplasty alone without a diagnosis of eyebrow ptosis can lead to its deterioration³.

There are cultural and temporal influences in the perception of what is considered an esthetically desirable eyebrow. Currently, the concept of the ideal eyebrow is that the medial portion begins in the same vertical plane of a line passing through the nasal wing and medial canthus and ending laterally in an oblique line drawn between the most lateral part of the nasal wing passing by the lateral canthus. The medial and lateral part of the eyebrow should be at the same height as in a horizontal line. The highest part of the eyebrow is in a vertical line passing through the corneal limbus and should be 2.5 cm from the pupillary midpoint^{4,5}.

In men, the eyebrow should be at the height of the orbital edge, being thicker and presenting a slight arc. In women, it should be a few millimeters above the orbit and present a more pronounced arc. Some deviations from this standard may cause unnatural results. An exaggerated lift of the entire eyebrow or medial part can cause a surprised look. A marked lift

of the side with the lower medial portion might result in a look of annoyance⁶.

When performing the repositioning of the eyebrow, the particularities of the face of each patient must be taken into account and not only established standards⁷.

An accentuated drop of the lateral part of the eyebrow occurs over time. This is due to less frontal muscle support, decreasing tone in the lateral part of the temporal fusion line, and the depressing action of the orbicularis muscles. To compensate this decline, a contraction of the frontalis muscle occurs creating wrinkles in the area^{5,8}.

Due to the importance of the eyebrow, several surgical and non-surgical procedures have been developed aiming at their lift. The non-surgical procedures include the use of botulinum toxin injections, fillers, lasers and peelings. Some of the most common surgical procedures are a direct lift of the eyebrow, open rhytidoplasty and laparoscopic surgery, and the elevations via temporalis^{9,10}.

The aim of this report was to describe the surgical and non-surgical procedures for eyebrow lift obtained through a review of the medical literature, and to present a decision flowchart for the approach of eyebrow ptosis, taking into account the specific characteristics of each patient.

METHODS

A search was performed within Medline and Lilacs databases, up to 31 May 2019, using the MeSH

descriptor [eyebrows (MeSH term)] and the DeCS descriptor “eyebrow,” without language restrictions.

Inclusion and exclusion criteria

Two authors independently assessed titles and abstracts according to the eligibility criteria. Disagreements between authors were resolved by consensus between both.

Articles that contained surgical and non-surgical procedures for eyebrow lift were included in the study.

Articles involving experiments on animals, eyebrow lift in reconstructive surgeries, reviews, letters and responses to articles were excluded.

The flowchart of surgical decision was drawn based on the literature and on the experience of the authors.

Consents were obtained and stored for publication of patient photographs in this study, which adhered to the ethical principles of the Declaration of Helsinki.

RESULTS

A total of 1,695 studies were identified following the search strategy. After assessing the titles and/or abstracts, 1,491 articles were excluded following the eligibility criteria. After assessment of the full-texts of 204 articles, 67 articles were included in the study (Figure 1).

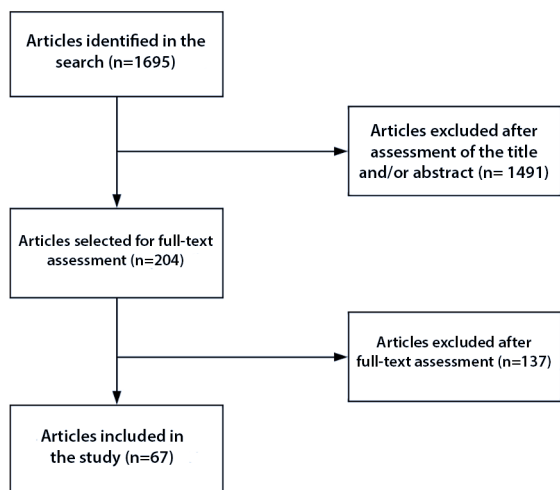


Figure 1. Inclusion and exclusion process of studies for the systematic review.

The bibliographic survey resulted in the description of several surgical and non-surgical approaches of eyebrow lift. The most commonly used procedures are described below.

Surgical procedures:

Open Rhytidoplasty: This technique uses a pretrichial incision for people with a long forehead, medium-trichial for men with pronounced frontal

wrinkles, or coronal for people with a short forehead (Figure 2). Regardless of the incision, all techniques have the advantage of elevating the entire eyebrow, treating the frontals and glabellar wrinkles. Open rhytidoplasties are not appropriate for people with baldness. The complications include loss of motor function and sensitivity, skin necrosis, alopecia, and asymmetry or overcorrection of the eyebrows. There is no evidence in the literature that favors one surgical approach at the expense of another¹¹⁻¹⁷.

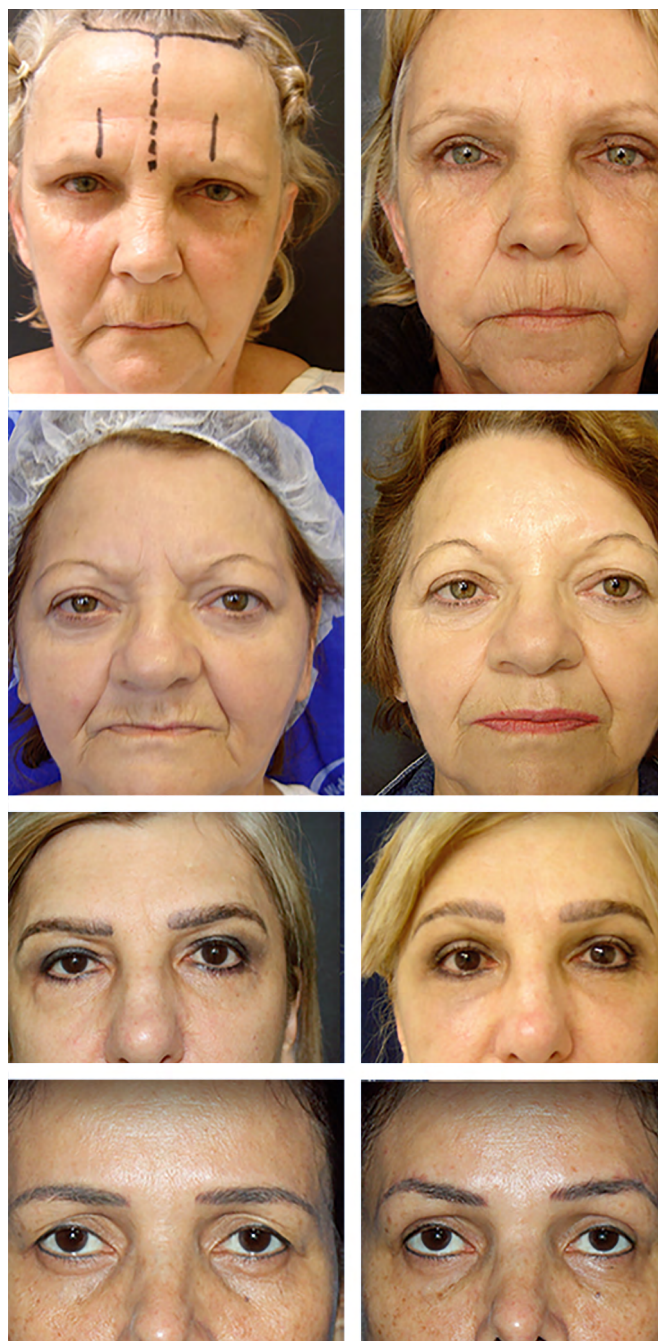

Figure 2. Pre- and 1 year postoperative aspect of open rhytidoplasty with pretrichial incision (upper left), coronal incision (upper right), endoscopic (lower left) and direct elevation of the eyebrow (bottom right).

Dissection approaches may be subcutaneous, subgaleal, or subperiosteal. The subcutaneous plane can be used in patients with very pronounced frontal wrinkles with lateral eyebrow drop, and in reoperation cases. Although there is a higher accuracy of eyebrow positioning, there is also a higher risk of flap necrosis, alopecia, and dehiscence. The subgaleal plane is an avascular plane that also raises the eyebrow without tension and with a lower risk of flap necrosis. The subperiosteal plane has the advantage of preserving the irrigation of the galea, leaving the flap more robust and with a lower chance of necrosis, besides preserving the frontoparietal innervation, but with more tension for elevation^{5,18-20}. The flap can be fixed through resection of the skin and suture or by fixing the flap in the periosteum using mesh or screws. The relationship between skin excision and eyebrow lift may range from 2:1 to 5:1^{5,21}.

Endoscopic Rhytidoplasty: This was introduced by Vasconez and Isse, 1992, and since then, it has been an alternative to open rhytidoplasty in select cases. The best patients for this technique are those with normal or low brow, since this surgery can increase the size of the forehead (Figure 2). The repositioning of the forehead is achieved through a repositioning and fixation of the scalp, unlike the open method that depends on its resection and suture^{22,23}.

This procedure has the same success rates as open rhytidoplasties, but with the advantages of smaller scars, faster recovery, lower incidence of necrosis, and paresthesia of the scalp. In this process, both the corrugator and the procerus can be weakened through a partial resection. The shortcoming includes a lower exposure of the anatomy, expensive specific equipment and higher learning curve²⁴⁻²⁷.

Fixation by endoscopy can be achieved through sutures in the cortical tunnels, Kirschner wires, fixation with plate and internal screw, and through Endotine (polylactic acid). The plates and screws can be made of absorbable or non-absorbable material. Regardless of the method, the fixation must remain in place for 40 to 60 days until the healing secures the flap in position^{5,22,28-32}.

The ideal patient for this surgery includes those with thin skin, moderate ptosis and slight skin flaccidity. Relative contraindications include bald people or with high hairline and those with thick skin³³.

Elevation of the eyebrows via temporal fascia: This technique uses an incision in the temporal region that can be pretrichial or in the scalp. It resects a portion of skin to raise the lateral part of the eyebrow, and it can be combined with other surgical procedures such as blepharoplasty. The lift is obtained through the resection of the skin in the temporal region and suture^{29,34}.

Direct eyebrow lift (Castanãres surgery): This consists of a skin incision above the eyebrow allowing

for a greater control and predictability in its lift and contour (Figure 2). It is indicated for the correction of unilateral ptosis of the eyebrows due to nerve lesions. The disadvantage includes an apparent scar and supraorbital nerve injury with paresthesia³⁵.

Elevation of the eyebrow via the transpalpebral approach: Described by Paul and Ramirez, in 1996^{36,37}, it entails the subperiosteal lift of the eyebrow via the blepharoplasty incision. An incision is performed in the periosteum through this access, just above the edge of the orbit, myomectomy or myotomy of the corrugator and procerus. The advantage of this technique is in correcting dermatochalasis as it yields results similar to endoscopic rhytidoplasty without the need for specific equipment^{22,36}.

Internal fixation of the eyebrows: Entails the internal lift of the lateral eyebrow through a blepharoplasty incision (Figure 3). The dermis and fat on the side of the eyebrow are fixed in the periosteum of the frontal bone through a suture. The disadvantage includes limited lifting of the eyebrow^{6,36,37}.

Fixation Threads: This technique uses polylactic acid, nylon or polydioxanone (PDS) thread to raise the eyebrows. Through a subcutaneous or subgaleal tunnel, the thread is fixed to the dermis of the eyebrow, and the dermis of the scalp at the hairline in the temporal region. After traction, the eyebrow is raised. The durability of the result is lower when compared to other surgical procedures (Figure 3)^{29,38}.

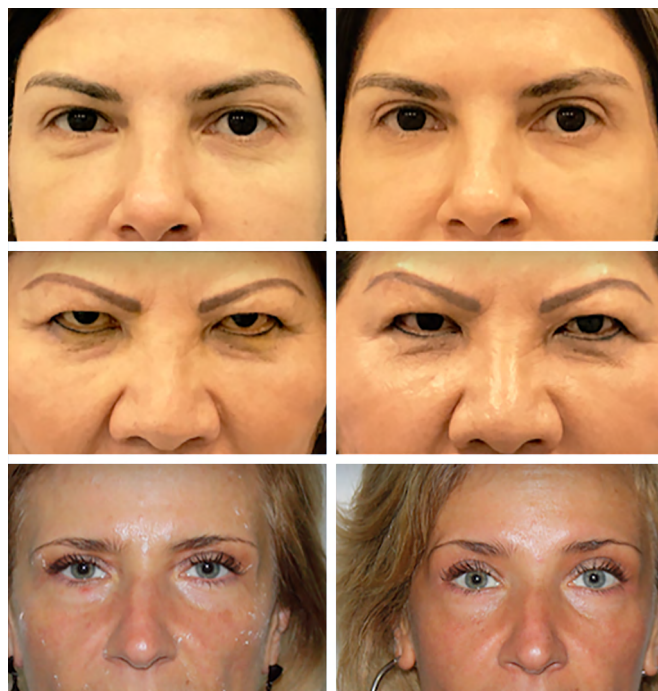

Figure 3. Pre- and 3 months postoperative aspect of upper blepharoplasty with internal fixation of the eyebrow (top photo), elevation of the eyebrows with sustentation threads (middle photo) and elevation of eyebrow with botulinum toxin (bottom photo).

Non-surgical procedures

Botulinum toxin: The application of botulinum toxin in the depressor muscles (procerus, orbicularis oculi, and corrugator supercilli muscles) produces a temporary paralysis of these muscles, enabling a lift without opposition from the frontalis muscle, and raising of the eyebrow (Figure 3). There is a possible complication of eyelid ptosis^{5,39}.

Fillers: Filling in the upper region of the orbits results in mild lift of the tail of the eyebrow, without repercussion in the medial and central region. It can be accomplished with hyaluronic acid or fat graft, always in depth, above the periosteum⁴⁰.

Given all these techniques and the experience of the authors, a decision flowchart was elaborated to approach eyebrow ptosis (Figure 4).

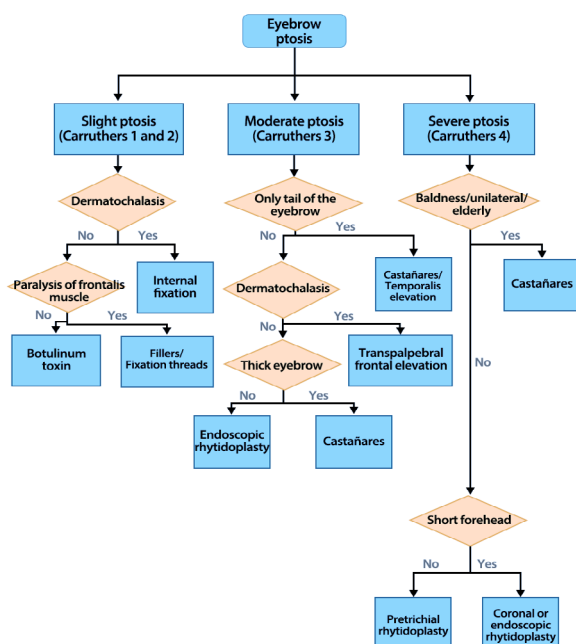


Figure 4. Decision flowchart to approach eyebrow ptosis.

Table 1. Advantages of eyebrow lift techniques.

	Degree of lift	Extension of lift	Correction of dermatochalasis	Treatment of wrinkles	Duration of results
Botulinum Toxin	+	+	+	+++	+
Fillers	+	+	+	+	+
Fixation threads	++	+	++	+	++
Fixation threads	+	+	+++	+	+
Castañares	++	+++	++	+	+++
Temporal Lift	++	+	++	+	+++
Transpalpebral Elevation	++	+++	+++	++	+++
Endoscopic Rhytidoplasty	+++	+++	++	+++	+++
Pretrichial Rhytidoplasty	+++	+++	++	+++	+++
Coronal Rhytidoplasty	+++	+++	++	+++	+++

+ Slight; ++ Average; +++ Large; *Raises the whole eyebrow or part.

DISCUSSION

Several surgical and non-surgical approaches for eyebrow lift were found in this literature review, highlighting the evolution and incorporation of technology over the years.

Several articles presented slight variations of the same surgical approach, making it difficult to describe each one in this study. It is to be assumed that there is no gold standard approach to eyebrow lift that suits all patients, with each approach presenting advantages and disadvantages (Tables 1 and 2).

To choose the best approach for the correction of eyebrow ptosis, it is important to evaluate some of their characteristics, such as the degree and extent of ptosis, the thickness of the eyebrow, presence of dermatochalasis, presence of glabellar and frontal wrinkles and the height of the hairline (Figure 4).

The only classification of eyebrow positioning validated in the literature was used in the elaboration of the flowchart¹. Mild eyebrow ptosis was classified as 1 and 2, moderate ptosis as 3 and severe as 4.

Classification of eyebrow positioning (Carruthers et al., 2008¹):

- Youthful, refreshed look and high-arch eyebrow;
- Medium-arch eyebrow;
- Slight arch of the eyebrow;
- Flat arch of the eyebrow, visibility of folds, and tired appearance;
- Flat eyebrow with barely any arch, marked visibility of folds, and very tired appearance.

In general terms, the non-surgical procedures correct the mild forms of eyebrow ptosis, while the surgical procedures correct the moderate and severe forms.

Although there are reports in the literature related to the choice of the best approach of eyebrow ptosis, none included non-esthetic procedures that take into account other factors than the severity of the ptosis.

Table 2. Disadvantages of eyebrow lift techniques.

	Visible Scar	Loss Of Sensitivity	Change in hairline	Risk of alopecia	Learning Curve
Botulinum Toxin	+	+	+	+	+
Fillers	+	+	+	+	+
Support thread	+	+	+	+	++
Internal fixation	++	+	+	+	++
Castañares	+++	++	+	+	++
Temporal Lift	++	++	+	+	++
Transpalpebral Elevation	++	++	+	+	+++
Endoscopic Rhytidoplasty	+	++	+	+	+++
Pretrichial Rhytidoplasty	+++	+++	+++	+	+++
Coronal Rhytidoplasty	+	+++	+++	+++	+++

+ Slight; ++ Average; +++ Large;

The success of the surgical procedure to correct eyebrow ptosis depends greatly on the surgeon's familiarity with the procedure. The decision of the best approach should also take into account the surgeon's experience. Surgical approaches reserved for severe ptosis of the eyebrow can be used in moderate ptosis, if the surgeon has no experience with other options.

On the other hand, more complex surgical approaches can be left aside in the face of simpler treatments. For example, to privilege direct lift of the eyebrows for moderate ptosis and use botulinum toxin to treat frontal wrinkles, instead of, performing an endoscopic rhytidoplasty. In summary, the best surgical approach is the one that provides the surgeon with better results.

The drafting of the flowchart for the choice of the best approach for each eyebrow and patient considered the experience of the authors and the services for which they work. More than a rigid guideline, the objective of the flowchart is to demonstrate that treatments must be customized and that there is a reason for the choice of any procedure.

CONCLUSIONS

There is an abundance of articles describing various surgical and non-surgical approaches for eyebrow lift, showing that there is no gold standard treatment, and that new technologies have been incorporated throughout the years.

The decision flowchart for the best approach for eyebrow lift intends to show the surgeon the need to customize the treatment and to highlight the reasoning behind each approach.

COLLABORATIONS

REM

Analysis and/or data interpretation, Conception and design study, Data Curation, Final manuscript approval, Formal Analysis, Investigation, Methodology, Project Administration, Validation, Visualization, Writing - Original Draft Preparation, Writing - Review & Editing

SM

Final manuscript approval, Supervision, Writing - Original Draft Preparation, Writing - Review & Editing

REFERENCES

- Carruthers A, Carruthers J, Hardas B, Kaur M, Goertelmeyer R, Jones D, et al. A validated brow positioning grading scale. *Dermatol Surg.* 2008 Nov;34(Suppl 2):S150-4.
- Har-Shai Y, Gil T, Metanes I, Schefflan M. Brow lift for the correction of visual field impairment. *Aesthet Surg J.* 2008 Sep/Oct;28(5):512-7.
- Prado RB, Silva-Junior DE, Padovani CR, Schellini SA. Assessment of eyebrow position before and after upper eyelid blepharoplasty. *Orbit.* 2012 Aug;31(4):222-6.
- Griffin GR, Kim JC. Ideal female brow aesthetics. *Clin Plast Surg.* 2013 Jan;40(1):147-55.
- Arneja JS, Larson DL, Gosain AK. Aesthetic and reconstructive brow lift: current techniques, indications, and applications. *Ophthalmic Plast Reconstr Surg.* 2005 Nov;21(6):405-11.
- Yalcinkaya E, Cingi C, Soken H, Ulusoy S, Muluk NB. Aesthetic analysis of the ideal eyebrow shape and position. *Eur Arch Otorhinolaryngol.* 2016 Feb;273(2):305-10.
- Alex JC. Aesthetic considerations in the elevation of the eyebrow. *Facial Plast Surg.* 2004 Aug;20(3):193-8.
- Fitzgerald R. Contemporary concepts in brow and eyelid aging. *Clin Plast Surg.* 2013 Jan;40(1):21-42.
- Nahai FR. The varied options in brow lifting. *Clin Plast Surg.* 2013 Jan;40(1):101-4.
- Pedroza F, Anjos GC, Bedoya M, Rivera M. Update on brow and forehead lifting. *Curr Opin Otolaryngol Head Neck Surg.* 2006 Aug;14(4):283-8.

11. Warren RJ. The modified lateral brow lift. *Aesthet Surg J*. 2009 Mar/Apr;29(2):158-66.
12. Walrath JD, McCord CD. The open brow lift. *Clin Plast Surg*. 2013 Jan;40(1):117-24.
13. Graham DW, Heller J, Kurkjian TJ, Schaub TS, Rohrich RJ. Brow lift in facial rejuvenation: a systematic literature review of open versus endoscopic techniques. *Plast Reconstr Surg*. 2011 Nov;128(4):335e-41e.
14. Guillot JM, Rousso DE, Replogle W. Forehead and scalp sensation after brow-lift: a comparison between open and endoscopic techniques. *Arch Facial Plast Surg*. 2011 Mar/Apr;13(2):109-16.
15. Fattahi T. Open brow lift surgery for facial rejuvenation. *Atlas Oral Maxillofac Surg Clin North Am*. 2016 Sep;24(2):161-4.
16. Romo T 3rd, Zoumalan RA, Rafii BY. Current concepts in the management of the aging forehead in facial plastic surgery. *Curr Opin Otolaryngol Head Neck Surg*. 2010 Aug;18(4):272-7.
17. Bosch G, Jacobo O, Seoane J, Martirena A, Ríos G. The extended brow lift: the toucan technique. *Aesthetic Plast Surg*. 2002 Jul/Aug;26(4):255-62.
18. Codner MA, Kikkawa DO, Korn BS, Pacella SJ. Blepharoplasty and brow lift. *Plast Reconstr Surg*. 2010 Jul;126(1):1e-17e.
19. Lee YJ, Cho YJ, Lee SY, Yoon JS. Comparison of satisfaction after direct browplasty in Asian patients with and without brow tattoo. *Can J Ophthalmol*. 2014 Apr;49(2):174-9.
20. Nassif PS, Kokoska MS, Homan S, Cooper MH, Thomas JR. Comparison of subperiosteal vs subgaleal elevation techniques used in forehead lifts. *Arch Otolaryngol Head Neck Surg*. 1998 Nov;124(11):1209-15.
21. Mutaf M. Mesh lift: a new procedure for long-lasting results in brow lift surgery. *Plast Reconstr Surg*. 2005 Oct;116(5):1490-9;discussion:1500-1.
22. Dailey RA, Saulny SM. Current treatments for brow ptosis. *Curr Opin Ophthalmol*. 2003 Oct;14(5):260-6.
23. Hidalgo DA. Discussion: Finesse in forehead and brow rejuvenation: modern concepts, including endoscopic methods. *Plast Reconstr Surg*. 2014 Dec;134(6):1151-3.
24. Patrocínio LG, Patrocínio JA. Forehead-lift: a 10-year review. *Arch Facial Plast Surg*. 2008 Nov/Dec;10(6):391-4.
25. Lee NG, Callahan AB, Migliori ME, Freitag SK. Minimally invasive approaches to eyebrow lifting. *Int Ophthalmol Clin*. 2013;53(3):47-57.
26. Rowe DJ, Guyuron B. Optimizing results in endoscopic forehead rejuvenation. *Clin Plast Surg*. 2008 Jul;35(3):355-60;discussion:3.
27. Holck DE, Ng JD, Wiseman JB, Foster JA. The endoscopic browlift for forehead rejuvenation. *Semin Ophthalmol*. 1998 Sep;13(3):149-57.
28. Berkowitz RL, Jacobs DI, Gorman PJ. Brow fixation with the Endotine Forehead device in endoscopic brow lift. *Plast Reconstr Surg*. 2005 Nov;116(6):1761-7;discussion:8-70.
29. Almousa R, Amrith S, Sundar G. Browlift--a South East Asian experience. *Orbit*. 2009;28(6):347-53.
30. Naif-de-Andrade NT, Hochman B, Abila LEF, Ferreira LM. Elevação dos supercílios na ritidoplastia frontal videoassistida. *Rev Bras Cir Plást*. 2013;28(Supl 3):18.
31. Guyuron B, Kopal C, Michelow BJ. Stability after endoscopic forehead surgery using single-point fascia fixation. *Plast Reconstr Surg*. 2005 Dec;116(7):1988-94.
32. Chowdhury S, Malhotra R, Smith R, Arnstein P. Patient and surgeon experience with the endotine forehead device for brow and forehead lift. *Ophthalmic Plast Reconstr Surg*. 2007 Sep/Oct;23(5):358-62.
33. Angelos PC, Stallworth CL, Wang TD. Forehead lifting: state of the art. *Facial Plast Surg*. 2011 Feb;27(1):50-7.
34. Tayani R, Rubin PA. Aesthetic periocular surgery including brow, midface, and upper face. *Curr Opin Ophthalmol*. 1999 Oct;10(5):362-7.
35. Voth H, Grunewald S, Miller B, Simon JC, Kendler M. Direct brow lift for the correction of unilateral brow ptosis due to frontal branch injury following cutaneous surgery in the frontotemporal region. *J Dtsch Dermatol Ges*. 2015 Dec;13(12):1298-301.
36. Burroughs JR, Bearden WH, Anderson RL, McCann JD. Internal brow elevation at blepharoplasty. *Arch Facial Plast Surg*. 2006 Jan/Feb;8(1):36-41.
37. Chiari Júnior A, Alves TA, Laia PHS, Casali TG, Fleury DPC. Blefaroplastia: elevação transpalpebral das sobrancelhas. *Rev Bras Cir Plást*. 2014;29(1):44-9.
38. Gruber RP, Nahai F. Brow or forehead fixation with sutures only: a preliminary communication. *Aesthetic Plast Surg*. 2003 Sep/Oct;27(5):403-5.
39. Chen AH, Frankel AS. Altering brow contour with botulinum toxin. *Facial Plast Surg Clin North Am*. 2003 Nov;11(4):457-64.
40. Chiu CH. Objective evaluation of eyebrow position after autologous fat grafting to the temple and forehead. *Aesthetic Plast Surg*. 2017 Dec;41(6):1342-50.

***Corresponding author:**

Ricardo Eustachio de Miranda

Rua Bandeira Paulista, 530, Sala 43, Itaim Bibi, São Paulo, SP, Brazil.

Zip code: 04532-001

E-mail: ricardomiranda@hotmail.com