

Article

Received 11 Jul 2010
Accepted 30 Nov 2010
Available online 8 Jul 2011

Keywords:

Abarema cochliacarpus
chronic colitis
inhibitor protein kappa B
JNK
p-38
trinitrobenzensulfonic acid

ISSN 0102-695X
doi: 10.1590/S0102-695X2011005000122

Chronic administration of *Abarema cochliacarpus* attenuates colonic inflammation in rats

Maria Silene da Silva,^{*§,1} Susana Sánchez-Fidalgo,^{§,2} Ana Cárdeno,² Elena Talero,² Marcelo Aparecido da Silva,³ Wagner Vilegas,³ Alba R. M. Souza Brito,¹ Catalina A. de la Lastra²

¹Departamento de Anatomia, Biologia Celular e Fisiologia e Biofísica, Universidade Estadual de Campinas, Brazil,

²University of Seville, Departamento de Farmacología, Facultad de Farmacia, Spain,

³Departamento de Química Orgânica, Instituto de Química, Universidade Estadual de São Paulo, Brazil.

Abstract: Inflammatory bowel diseases are characterized by a chronic clinical course of relapse and remission associated with self-destructive inflammation of the gastrointestinal tract. Active extracts from plants have emerged as natural potential candidates for its treatment. *Abarema cochliacarpus* (Gomes) Barneby & Grimes, Fabaceae (Barbatimão), is a native medicinal plant in to Brazil. Previously we have demonstrated in an acute colitis model a marked protective effect of a butanolic extract, so we decided to assess its anti-inflammatory effect in a chronic ulcerative colitis model induced by trinitrobenzensulfonic acid (TNBS). *Abarema cochliacarpus* (150 mg/day, v.o.) was administered for fourteen consecutive days. This treatment decreased significantly macroscopic damage as compared with TNBS. Histological analysis showed that the extract improved the microscopic structure. Myeloperoxidase activity (MPO) was significantly decreased. Study of cytokines showed that TNF- α was diminished and IL-10 level was increased after *Abarema cochliacarpus* treatment. In order to elucidate inflammatory mechanisms, expression of cyclooxygenase (COX)-2 and nitric oxide synthase (iNOS) were studied showing a significant downregulation. In addition, there was reduction in the JNK and p-38 activation. Finally, I κ B degradation was blocked by *Abarema cochliacarpus* treatment being consistent with an up-regulation of the NF-kappaB-binding activity. These results reinforce the anti-inflammatory effects described previously suggesting that *Abarema cochliacarpus* could provide a source for the search for new anti-inflammatory compounds useful in ulcerative colitis treatment.

Introduction

Inflammatory bowel diseases (IBD) such as Crohn's disease (CD) and ulcerative colitis (UC) are illness characterized by a chronic clinical course of relapse and remission associated with self-destructive inflammation of the gastrointestinal tract. IBD has long been appreciated to have a genetic basis and likely involves a response of the immune system to some environmental agent(s). What differentiates the inflammatory responses observed in IBD from normal gut is an inability to downregulate these responses (Gambero et al., 2007; Kaser et al., 2010). One of the earliest factors involved is the breach of the intestinal epithelial barrier and the development of abnormal immune and inflammatory responses that are mediated predominantly by activated neutrophils, monocytes,

lymphocytes, and macrophages (Schmidt & Stallmach, 2005; Thompson-Chagoyan et al., 2005). Infiltrated granulocytes and macrophages produce high levels of pro-inflammatory cytokines, such as tumour necrosis factor- α (TNF- α), that plays a central role in mucosal inflammation and is likely to be at the apex of the inflammatory cascade in IBD (Waetzig et al., 2002; Talero et al., 2008). Another mediators that have been closely associated with the initiation and maintenance of intestinal inflammation are COX-2 and iNOS, which play a pivotal role in mediating inflammation; both produce important inflammatory mediators that contribute to loss the integrity of the colonic mucosal (Sánchez-Calvo et al., 2009; Sánchez-Fidalgo et al., 2010).

Among the signaling pathways which are involved in the development or propagation of IBD,

the mitogen-activated protein kinases (MAPK) and/or the nuclear factor κ B (NF- κ B) are of particular interest (Atreya et al., 2008), by modulating a number of different steps in the inflammatory cascade. Recent studies have highlighted the importance of the MAPK pathway, moreover it has been shown that specific inhibitors against p38 and JNK attenuate the disease (Kwon et al., 2007; Di Mari et al., 2007; Hollenbach et al., 2005; Assi et al., 2006; Broom et al., 2009). On the other hand, NF- κ B dimers are kept in an inactive cytoplasmic complex by inhibitory proteins, the inhibitor protein kappa B (I κ B) family, in resting cells. Phosphorylation of I κ B generally leads to the rapid dissociation of the complex accompanied by proteolytic degradation of I κ B and release of NF- κ B that subsequently translocate from cytoplasm into the nucleus. NF- κ B can induce gene transcription by binding to specific promoter elements (Atreya et al., 2008; Glasgow et al., 2000; Tak & Firestein, 2001).

Abarema cochliacarpus (Gomes) Barneby & Grimes, Fabaceae, is an ornamental tree and native medicinal species in Brazil. It is popularly known as "barbatimão" or "babatenã". It appears mainly in the Atlantic Forest and in the Caatinga (dryland) region of Northeastern Brazil, which hosts many different ethnic communities (Albuquerque et al., 2007; World Conservation Center, 1998). In this same region, on the traditional medicine of Colônia Treze village (Lagarto/Sergipe) the decoction of stem bark of *Abarema cochliacarpus* is frequently used for wound-healing, as an analgesic and anti-inflammatory (Silva et al., 2006; Silva et al., 2009).

Previous studies performed by our group have shown the antiulcer effect of the aqueous extract of the bark in experimental alcohol gastric ulcer demonstrating for the first time a reduction of the lesions (Silva et al., 2006). Recently, the butanolic fraction of the methanolic extract was tested on acute experimental colitis model induced by trinitrobenzene sulfonic acid (TNBS) and showed anti-inflammatory effects. Moreover, phytochemical screening of this fraction by electrospray ionization (ESI)/MS was also performed showing a high content of polyphenols. Its major constituents were catechins, flavonoid-type compounds and the minor were its dimers and trimers. The tannins belong to the proanthocyanidin subgroup. The NMR characterization shown the major constituent was (+)-catechins (da Silva et al., 2010).

Ethnopharmacological studies demonstrated that *Abarema cochliacarpus* is used in traditional medicine for many diseases, including gastrointestinal diseases, through the daily ingestion of this decoction or the tincture, which is made by placing the bark in white wine or "cachaça" (Silva et al., 2006; Santos, 2008). Thus, considering this fact, and the promising

results that have been showed by acute administration of butanolic fraction of *Abarema cochliacarpus*, we decided to assess the response and mechanisms involved after its chronic administration in experimental colitis induced by TNBS.

We evaluated the inflammatory response by histological analysis and by the determination of inflammation markers such as MPO activity and cytokines profile. In order to gain a better insight into the action mechanism(s) the expression of inducible enzymes COX-2 and iNOS, the expression and activation of MAPKs and I κ B degradations were also analyzed by Western blotting.

Materials and Methods

Plant material

The bark of *Abarema cochliacarpus* (Gomes) Barneby & Grimes, Fabaceae, was obtained from collection by Maria Silene da Silva and the folk medicine practitioner, in Colônia Treze village, Lagarto city, Sergipe state, Brazil, in July 2006. Voucher specimens of this species were identified by Prof. Dra. Christine Niezgodá from Field Museum of Natural History and was deposited under number 007628 at the Federal University of Sergipe.

Preparation of the extract

Fresh bark of *Abarema cochliacarpus* was dried at room temperature for 10-14 days. Then it was powdered (1200 g) and exhaustively extracted with methanol (5 L) at room temperature during fifteen days at room temperature by maceration. The suspension was concentrated at 40 °C under reduced pressure to provide a crude methanolic extract with 34.61% yield (415.4 g).

The methanolic extract (200 g) was partitioned three times with a mixture of ethyl acetate: water (1:1, v/v). The ethyl acetate fraction was evaporated at 35 °C under reduced pressure to obtain an ethyl acetate fraction (AF) of 46.12 g (23.06% yield). The aqueous phase was partitioned with a mixture of *n*-butanol/water (1:1 v/v, three times), producing 92.62 g of butanolic fraction (AC) with 46.31% yield and 45.19 g of aqueous fraction (AQF) with 22.59% yield.

Animals

Male and female Wistar rats supplied by Animal Services of the University of Seville, Spain, weighing 180-200 g, were placed in single in cages with wire-net floors in a controlled room (temperature 24-25 °C, humidity 70-75%, lighting regimen of 12L/12D) and were fed a normal

laboratory diet (Panlab, Barcelona, Spain). Rats were deprived of food for 12 h prior to the induction of colitis, but were allowed free access to tap water throughout. They were randomly assigned to groups of 8-13 animals. Experiments followed a protocol observed by the Animal Ethics Committee of the University of Seville and all experiments were in accordance with the recommendations of the European Union regarding animal experimentation (Directive of the European Council 86/609/EC).

Induction of colitis

Colitis was induced according to the procedure described by Morris et al. (1989). Briefly, rats were slightly anesthetized with 12% chloral hydrate by intraperitoneal route (*i.p.*) following a 12 h fast, and then a medical-grade polyurethane cannula for enteral feeding (external diameter 2 mm) was inserted into the anus and the tip was advanced to 8 cm proximal to the anus verge. TNBS (Sigma-Chemical Co., St. Louis, MO, USA) dissolved in ethanol (50%, v/v) was instilled into the colon through the cannula (TNBS-30 mg in a volume of 0.25 mL to induce a long-chronic colitis) and the animals were maintained in a head-down position for a few minutes (2-3 min) to prevent leakage of the intracolonic instillate.

Butanolic fraction of *Abarema cochliacarpus* (150 mg/kg) was suspended in 2% Tween 80 (Sigma-Chemical Co., St. Louis, MO, USA) (Santos et al, 2004) and was administered in a volume of 10 mL/kg body weight by oral route 24 h after TNBS instillation and, daily during the two weeks before the sacrifice. We selected this dose of the extract since this was the most active in acute study (da Silva et al, 2010). A reference control group was applied for comparison with the TNBS colon instillation group: the sham group that received physiological saline instead of the TNBS solution in a comparable volume. Sham and TNBS groups also received the vehicle by oral route. The rats were checked daily for behavior, body weight, and stool consistency.

Assessment of colitis

An independent observer who was blinded to the treatment evaluated the severity of colitis. For each animal, the distal 10 cm portion of the colon was removed and cut longitudinally, slightly cleaned in physiological saline to remove fecal residues and weighed. Macroscopic damage was quantified measuring the extent of the lesions in the distal colon (mm²) using Bioview 4 (AvSoft, Brazil) an image analysis software (Khan, 2004). The presences of adhesions (score 0-2), and/or stool consistency (score

0-1) were evaluated according to the criteria of Bobin-Dubigeon et al. (2001) with slight modifications. Photographs taken from colon samples were digitized using Kodak D290 Zoom camera (Eastman Kodak Co., Rochester, NY, USA). Pieces of colon were collected and frozen in liquid nitrogen for measurement of biochemical parameters.

Histological studies

For examination with the light microscope we used tissue samples from the distal inflamed colon of each animal and fixed in 4% buffered formaldehyde, then submerged into 20-30% sucrose and after embeded in tissue freezing medium (Tissue-Tek Sakura, Netherlands), and finally were frozen in liquid nitrogen. 7 µm thick slices were obtained by utilizing a cryostat (HM 525, Microm, Walldorf, Germany) and stored at -80 °C until use. The samples were stained with hematoxylin-eosin in accordance with the standard procedures for histological evaluation of colonic damage. All tissue sections were examined in an Olympus BH-2 microscope (GMI, MN, USA). Motic Images 2000 software was used for characterization of histopathological changes.

Assessment of leukocyte involvement

Myeloperoxidase (MPO) activity, an indicator of polymorphonuclear leukocyte accumulation, was assessed de according to the method of Bradley et al. (1982) with slight modifications. Samples were obtained from all animals were weighed and homogenized in 10 volumes of 50 mM potassium phosphate buffer (PBS), pH 7.4. The homogenates were centrifuged at 20,000g, 20 min, 4 °C. The pellets were again homogenized in 10 volumes PBS, pH 6.0, containing 0.5% hexadecyltrimethylammonium bromide (HETAB) and 10 mM ethylenediaminetetraacetic acid (EDTA). These homogenates were subjected to one cycle of freezing/thawing and a brief period of sonication.

The supernatants (50 µL) were diluted in 10 volumes of 50 mM PBS, pH 6. Then it was added consecutively 50 µL of O-dianisidine dihydrochloride (0.067%), of HETAB (0.5%) and of hydrogen peroxide (0.003%). Each well containing the complete reaction mixture was incubated for 5 min. The changes in absorbance at 450 nm were measured with a microplate reader (Labsystem Multiskan EX, Helsinki, Finland). One unit MPO activity was defined as the amount of enzyme present that produced a change in absorbance of 1.0 U/min in the final reaction volume.

Assessment of TNF-α and IL-10

Distal colon samples were weighed and homogenized, after thawing, in ten volumes PBS, pH 7.2, 1% bovine serum albumin (BSA) at 4 °C. They were centrifuged at 12,00 x g for 10 min and the supernatants were collected and stored at -80 °C. Mucosal cytokines levels were assayed with quantitative TNF- α (eBioscience, San Diego, CA) and IL-10 (Diacclone, Besançon, France) enzyme immunoassay kits. TNF- α and IL-10 values were expressed as pg/mg tissue.

Western blotting assay

Frozen colonic tissues were weighed and homogenized in ice cold buffer (50 mM Tris-HCl, pH 7.5, 8mM MgCl₂, 5mM ethylene glycol bis (2-aminoethyl ether)-N,N,N',N'-tetraacetic acid (EGTA), 0.5 mM EDTA, 0.01 mg/mL leupeptin, 0.01 mg/mL pepstatin, 0.01 mg/mL aprotinin, 1 mM phenylmethylsulfonyl fluoride (PMSF) and 250 mM NaCl. Homogenates were centrifuged (12000 x g, 15min, 4 °C) and the supernatants were collected and stored at -80 °C. Protein concentration of the homogenate was determined following Bradford's colorimetric method. Aliquots of supernatants containing equal amounts of protein (50 μ g) were separated on 10% acrylamide gel by sodium dodecyl sulfate polyacrylamide gel electrophoresis. In the next step, the proteins were electrophoretically transferred onto a nitrocellulose membrane and incubated with specific primary antibodies: rabbit polyclonal anti-COX-2 and anti-iNOS (Cayman Chemical, USA) at dilution of 1:3000, mouse polyclonal anti- JNK and anti-pJNK (Cell Signalling Technology, USA) at dilution of 1:2000 and 1:500 respectively, and mouse polyclonal anti-p38 and anti-p-p38 (Santa Cruz Biotechnology, Inc) at dilution of 1:1000 overnight at 4 °C. After, each filter was washed three times for 15 min and incubated with the anti-rabbit (Pierce Biotechnology, IL, U.S.A) and anti-mouse (Sigma-Aldrich, MO, USA) immunoglobulin G antibodies respectively. To prove equal loading, the blots were analyzed for β -actin expression using an anti- β -actin antibody (Sigma-Aldrich, MO, USA). Immunodetection was performed using enhanced chemiluminescence light-detecting kit (SuperSignal®

West Femto Chemiluminescent Substrate, Pierce, IL, USA). Densitometric data were studied following normalization to the control (housekeeping gene). The signals were analyzed and quantified by a Scientific Imaging Systems (KODAK 1D, Image Analysis Software).

I κ B α degradations analysis

Using the western blot technique as herein before narrated for cytoplasmic protein extracts, it was evaluated degradations of cytoplasmic I κ B protein of intestinal mucosa. The specific primary antibody used was rabbit polyclonal anti-I κ B α (Cell Signalling Technology, USA) at dilution of 1:1000 and the next day with the anti-rabbit immunoglobulin G antibodies (Pierce Biotechnology, IL, USA).

Statistic analysis

All values in the figures and text are expressed as arithmetic means \pm standard error of the mean (SEM). Data were evaluated with Graph Pad Prism1 Version 5 software. The statistical significance of any difference in each parameter among the groups was evaluated by one-way analysis of variance (ANOVA) followed by Tukey test. *p* values of <0.05 were considered statistically significant. In the experiment involving histology, the figures shown are representative of at least three experiments performed on different days.

Results

At fourteen days after intracolonic administration of TNBS, control animals underwent severe anorexia with a marked body weight loss and intense diarrhea in the majority of animals in comparison with sham group (*p*<0.001). Presence of adhesions to adjacent organs and a marked increase in the weight/length of the colon were also observed in TNBS treated rats (*p*<0.001) (Table 1). Macroscopic inspection of the colon after two weeks of colitis induction showed a flaccid appearance, bowel wall thickening, inflammation and ulcers. The damage was

Table 1. Quantified parameters after administration of butanolic fraction of bark of *Abarema cochliacarpus* (AC, 150 mg/kg) in rats with chronic colitis induced by trinitrobenzene sulfonic acid (TNBS) intracolonic instillation (30 mg/animal).

Group	n	Body weight	Adhesions (score 0-2)	Diarrhea (score 0-1)	Colon weight/length (g/cm)	Mortality (%)
Sham	8	180.25 \pm 3.14	0	0	0.09 \pm 0.004	0
TNBS-30	8	163.40 \pm 3.19	1.80 \pm 0.20	0.83 \pm 0.16	0.56 \pm 0.09	40
AC 150	8	172.23 \pm 2.93	1.20 \pm 0.20	0.25 \pm 0.25	0.29 \pm 0.03	20

Colonic parameters were quantified in the sham group, which received saline instillation. TNBS group received the hapten intracolonic in a vehicle of 50% (v/v) ethanol. Data are expressed as mean \pm SEM. (***) *p*<0.001 vs. sham group; (+) *p*<0.05 and (++) *p*<0.01 vs. TNBS control group

quantified and the affected area was $1169 \pm 116.30 \text{ mm}^2$ ($p < 0.001$) (Figure 1A and Figure 2B).

After *Abarema cochliacarpus* treatment in TNBS-rats during 14 days, significant changes were observed respect to the presence of diarrhea ($p < 0.05$), adhesions to adjacent organs ($p < 0.05$) and colon weight/length ($p < 0.01$) vs. TNBS control group; although no significant reduction in the body weight loss was observed. Treatment with *Abarema cochliacarpus* also significantly ameliorated the extent and severity of the colonic inflammation, reflecting signs of greater recovery as evidenced by the quantification of macroscopic damage ($291.8 \pm 10.82 \text{ mm}^2$; $p < 0.001$ vs. TNBS group) as is reflect in Figure 1A and Figure 2C.

The histological analysis of the colon of sham-treated rats showed typical features of normal structure (Figure 2D). In TNBS-treated rats, the inflammation extended through the mucosa and submucosa. Extensive granulation tissue with presence of fibroblasts and lymphocytes, leukocytes, and diffuse inflammatory infiltrates was apparent (Figure 2E). The mucosa adjacent to lesions showed extensive crypt distortion and goblet cells were totally absent at the surface epithelium. After chronic administration of *Abarema cochliacarpus*, the colonic histopathology was dramatically reduced: there was an attenuation of morphological signs of cell damage; the colonic mucosa showed ulcers in the process of healing, goblet cells were most visible and a repair process was observed in some areas. The mucosa showed a healing course with signs of mucosal reepithelization (Figure 2F, 2G).

As shown in Figure 1B, the colitis caused by

TNBS was also characterized by a marked increase in MPO activity ($2.43 \pm 0.80 \text{ U/mg tissue}$, $p < 0.01$ vs sham group), an indicator of the infiltration of the colon with polymorphonuclear leukocytes. This result was consistent with the histological findings. This assay of MPO activity showed that *Abarema cochliacarpus* significantly reduced the degree of polymorphonuclear neutrophil infiltration as compared to TNBS group ($0.54 \pm 0.16 \text{ U/mg tissue}$, $p < 0.05$ vs. TNBS group).

Regarding the pro-inflammatory cytokines production, the colonic injury provoked by 30 mg of TNBS administration by animal was characterized by a significant increase in TNF- α levels ($40.95 \pm 5.45 \text{ pg/mg tissue}$, $p < 0.01$ vs. sham group). After treatment with *Abarema cochliacarpus*, data clearly indicated a significant reduction in this cytokine ($18.94 \pm 0.44 \text{ pg/mg tissue}$, $p < 0.01$, vs. TNBS group) (Figure 1C).

In contrast, IL-10 levels were diminished in TNBS control group ($2.05 \pm 0.71 \text{ pg/mg tissue}$, $p < 0.05$ vs. sham group) and *Abarema cochliacarpus* administration increased IL-10 levels, reaching values similar to sham group ($6.63 \pm 0.70 \text{ pg/mg tissue}$, $p < 0.01$ vs. TNBS group) (Figure 1D).

The levels of expression of COX-2 and iNOS were measured by western blotting of cytosolic extracts from colonic mucosa. Exposure of colon to TNBS caused strong expression of COX-2 and iNOS ($p < 0.001$ and $p < 0.01$ respectively), indicating that these proteins expression could be induced at the chronic stage of colonic lesion caused by TNBS. Nevertheless, oral administration of *Abarema cochliacarpus* was able to diminish significantly the up-regulation of both COX-2

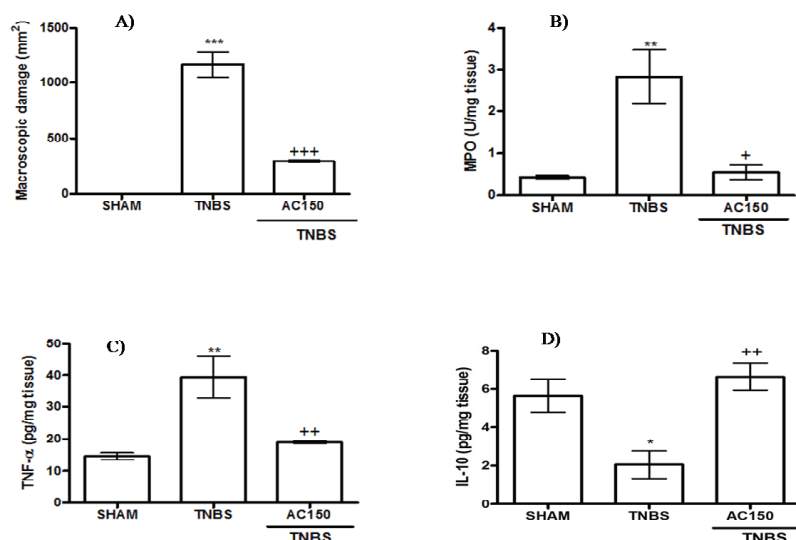


Figure 1. Effect of chronic administration of butanolic fraction of *Abarema cochliacarpus* (AC) on colonic macroscopic damage (A), myeloperoxidase activity (MPO, U/mg tissue) (B), tumor necrosis factor- α (TNF- α , pg/mg tissue) (C), and interleukin-10 (IL-10, pg/mg tissue) (D), in trinitrobenzene sulfonic acid-induced colitis model in rats (TNBS, 30 mg/animal). The control-sham group received physiological saline instead of the TNBS solution in an equal volume. Data are expressed as the means \pm S.E.M. One way ANOVA followed by Tukey's test. * $p < 0.05$; ** $p < 0.01$; *** $p < 0.001$ vs sham; + $p < 0.05$; ++ $p < 0.01$ and +++ $p < 0.001$ vs TNBS group.

and iNOS proteins ($p < 0.05$, vs TNBS) (Figure 3A, 3B).

JNK and p38 MAPK protein activation was also detected in cytosolic extracts of normal colon mucosa by western blot using phosphospecific MAPK antibodies (Figure 4). To standardize protein loading in each line, blots were stripped and re-probed with the corresponding antibodies against both proteins. Phosphorylation of JNK protein was not detected in cytosolic extracts of normal colon mucosa, whereas a high expression appeared in colon mucosa from control TNBS-treated rats ($p < 0.01$ vs. sham group), indicating that JNK protein activation could be induced at the chronic stage of colonic lesion caused by TNBS. Nonetheless, upon treatment with *Abarema cochliacarpus* the protein expression of p-JNK was significantly decreased ($p < 0.05$ vs TNBS group) (Figure 4A). Study from p38 protein showed that it remained unchanged in all groups, indicating that this protein was constitutively expressed in the colonic tissue and, its activation was significantly changed after TNBS-enema ($p < 0.001$ vs. sham group). Chronic *Abarema cochliacarpus*

administration demonstrated a significantly reduction of phosphorylation of this protein ($p < 0.05$ vs TNBS group) (Figure 4B).

Since NF- κ B activity is controlled by the steady state level of I κ B α we further investigated the effect of *Abarema cochliacarpus* on I κ B degradation in rat's colonic mucosa. As shown in Figure 5, protein extracts of colon tissues showed that intestinal inflammation of TNBS group induced a significant I κ B degradation which is consistent with an up-regulation of the NF- κ B-binding activity. However, this was blocked by *Abarema cochliacarpus* treatment.

Discussion

In particular we have demonstrated that fourteen days of *Abarema cochliacarpus* treatment decreased the degree of adhesions, diarrhea and colon weight/length, as well as colonic macroscopic damage. There was an attenuation of morphological signs of cell damage, the colonic mucosa showed ulcers at the beginning of

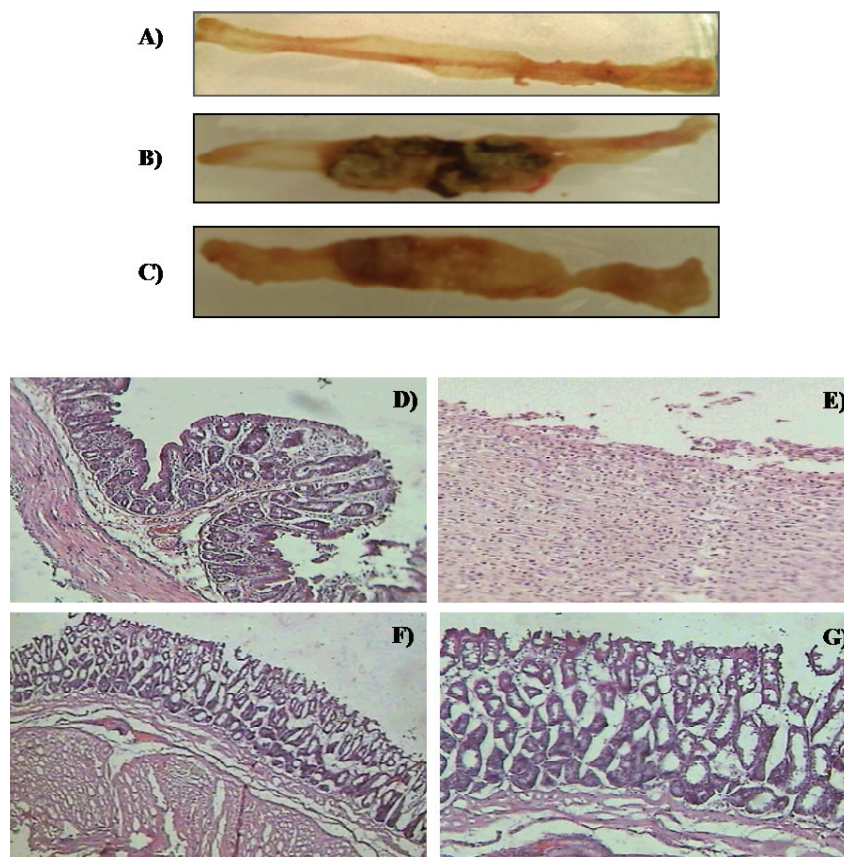


Figure 2. Effect of butanolic fraction of *Abarema cochliacarpus* on colon injury in chronic colitis model induced by trinitrobenzene sulfonic acid (TNBS, 30 mg/animal). Representative macroscopic and histological appearance of rat colonic mucosa in control animals (A and D respectively), TNBS treatment (B and E respectively) and butanolic fraction of *Abarema cochliacarpus*-treated animals (150 mg kg⁻¹ v.o.) (C, F and G respectively). TNBS lesions were characterized by necrosis of epithelium, focal ulceration and diffuse infiltration of inflammatory cells in the mucosa and submucosa. Hematoxylin and eosin. Original magnification: D, E and F 100X; G, 200X.

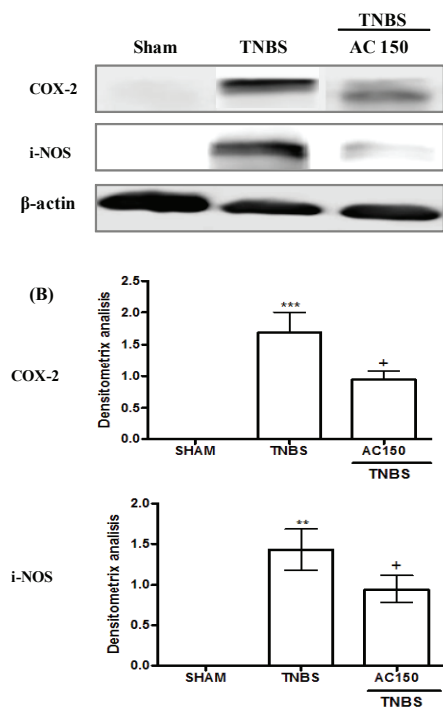


Figure 3. Effects of chronic administration of butanolic fraction of *Abarema cochliacarpus* (AC150 mg/kg) on cyclooxygenase-2 (COX-2) and inducible nitric oxide synthase (iNOS) (A and B) in trinitrobenzene sulfonic acid (TNBS, 30 mg/animal). The results are representative of three experiments performed on different samples. Data are expressed as the means±SEM. One way ANOVA followed by Tukey's test. ** $p < 0.01$ and *** $p < 0.001$ vs sham; + $p < 0.05$ vs TNBS.

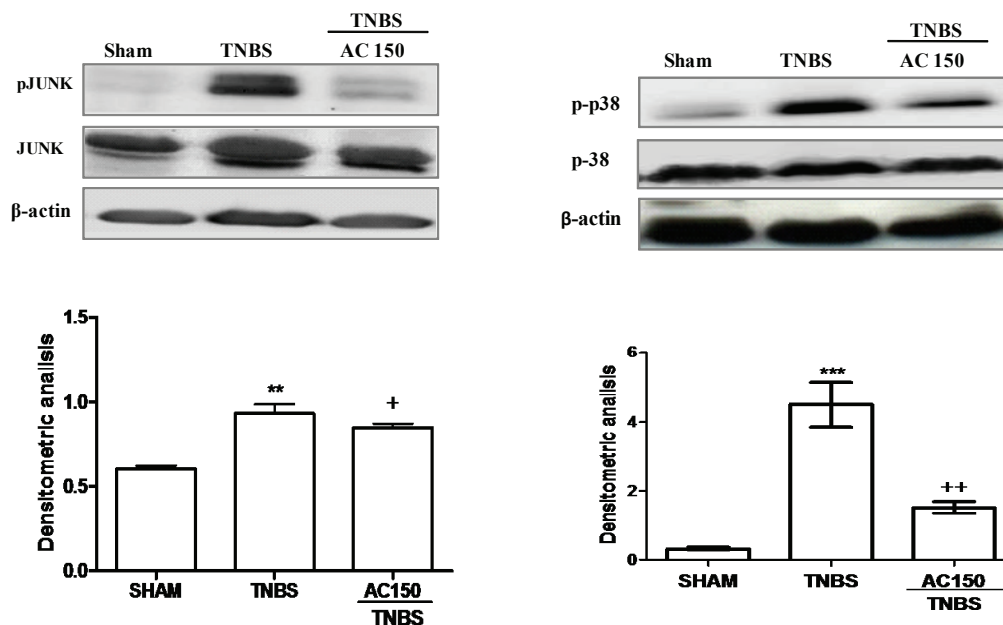


Figure 4. Effects of chronic administration of butanolic fraction of *Abarema cochliacarpus* (AC150 mg/kg) on activation of the JUNK and p38 MAPKs proteins in trinitrobenzene sulfonic acid (TNBS, 30 mg/animal). The results are representative of three experiments performed on different samples. Data are expressed as the means±S.E.M. One way ANOVA followed by Tukey's test. ** $p < 0.01$ and *** $p < 0.001$ vs sham, + $p < 0.05$ and ++ $p < 0.01$ vs TNBS.

reepithelization and healing process. The infiltration of polymorphonuclears and the increase on TNF- α production caused by TNBS in the colon were also diminished after *Abarema cochliacarpus* treatment. Moreover, administration of the extract was able to increase the levels of the anti-inflammatory cytokine IL-10, which were diminished after TNBS administration. COX-2 and iNOS proteins were downregulated after administration of *Abarema cochliacarpus* as well as the intestinal phosphorylation of JNK and p38. Moreover, this extract blocked I κ B degradation.

As we have mentioned above phytochemical screening results from butanolic fraction of *Abarema cochliacarpus* demonstrated that its main bioactive constituents is (+)-catechin (da Silva et al, 2010). Several studies have demonstrated that catechins intake has been associated with a wide whose variety of beneficial health effects *in vitro*, *in vivo* and clinically, including experimental model of ulcerative colitis (Sato et al, 1998; Mazzon et al, 2005), although its mechanism of action is unknown yet.

Studies of bioavailability of catechins show that although most of an oral dose of catechins remains in the gut and becomes available for metabolism by the colonic microflora, some certainly are absorbed and appear in the plasma (Gee & Johnson, 2001; Nakagawa & Miyazawa, 1997). Conversely, Okushio et al. (1996) confirmed that the principal catechins of green tea are absorbed in the rat small intestine by measuring their appearance in the

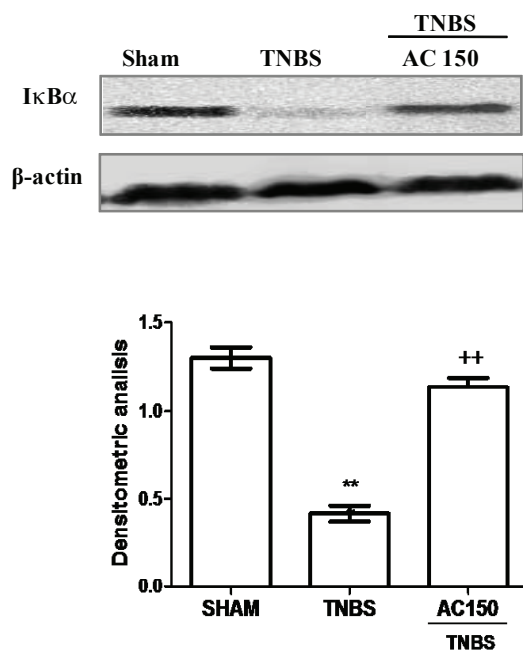


Figure 5. Effects of chronic administration of butanolic fraction of *Abarema cochliacarpus* (AC150 mg/kg) on degradation of the IκBα protein in trinitrobenzene sulfonic acid (TNBS, 30 mg/animal). The results are representative of three experiments performed on different samples. Data are expressed as the means±S.E.M. One way ANOVA followed by Tukey's test. *** $p < 0.001$ vs sham and ++ $p < 0.01$ vs TNBS.

portal circulation after an oral dose. All these observations may have significance on the beneficial effect of *Abarema cochliacarpus* in our ulcerative chronic colitis model.

Whatever the trigger of IBD, neutrophils are early responders and play a central role in the inflammatory process. During the initial innate immune response, they are seen passing from the circulation through gaps in the vascular endothelium to infiltrate the tissues (Villegas et al., 2003). Once there, neutrophils release antimicrobial peptides, as enzyme MPO, which catalyses the formation of such potent cytotoxic oxidants as hypochlorous acid from hydrogen peroxide and chloride ions and N-chloramines (Martin et al., 2006) and reactive oxygen intermediates that may in themselves cause further tissue damage (Hanauer, 2006). The increase in MPO activity in TNBS-treated animals was reduced after chronic administration of *Abarema cochliacarpus*. Microscopic evaluation also revealed an increased number of neutrophil leukocytes that possibly contributed to the elevated MPO activity observed in TNBS group. This anti-inflammatory effect has already been demonstrated after acute treatment (da Silva et al., 2010), but we confirm these previous results and demonstrate that this effect has been higher after chronic treatment. The antioxidant activity of phenol compounds, as well as catechins, has been shown by many studies. In

this way, the reduction in colonic MPO activity as well as the reduction of cellular infiltration after treatment with *Abarema cochliacarpus* may be reflective of its antioxidant and anti-inflammatory effects.

Some works by our group have shown that in this well-characterized TNBS-induced colitis model mucosal pro-inflammatory cytokines increase, such as IL-1β, IL-6 and TNF-α, induces the production of chemoattractants for neutrophils, which regulate endothelial adhesion molecules expression on vascular endothelial cells and promote neutrophil adherence to these cells (Sánchez-Fidalgo et al., 2007; Camacho-Barquero et al., 2007; Talero et al., 2008; Sánchez-Calvo et al., 2009). On the other hand, the cytokine IL-10 inhibits both antigen presentation and subsequent release of pro-inflammatory cytokines, thereby attenuating mucosal inflammation in IBD (Sanchez-Muñoz et al., 2008). This anti-inflammatory cytokine possesses important immune-modulatory properties and its deficiency allows for the development of unrestrained activation of a Th-1-mediated immune response (Wirtz & Neurath, 2007), as it occurs in the spontaneous colitis induced in IL-10-knockout mice (Strober et al., 2002). Therefore, it has been suggested that using different strategies that increase IL-10 may be useful in IBD therapy.

The present results show that chronic administration of *Abarema cochliacarpus* was able to diminish TNF-α levels and significantly to increase IL-10 levels. These results are of interest since although the diminution of TNF-α levels after *Abarema cochliacarpus* administration has been observed in the acute colitis model (da Silva et al., 2010), the increase of the anti-inflammatory IL-10 cytokine after chronic treatment has not been demonstrated yet. Thus, chronic administration of (+) catechins from *Abarema cochliacarpus* seems capable to modulate the Th1/Th2 response, which may be other of the mechanisms of action responsible to the improvement of the colitis. Previous studies have shown as epicatechins from green tea extracts exhibit similar effects, they decreased TNF-α in others IBD models (Mazzon et al., 2005; Ran et al., 2008; Varilek et al., 2001) and stimulated IL-10 production in human leukocytes (Crouvesier et al., 2001).

Macroscopic damage in this chronic colitis model was associated with both COX-2 and iNOS overexpression and, (+)-catechins from *Abarema cochliacarpus* fraction significantly down regulated both proteins. Many researchers show the effects of catechins on COX-2 and iNOS activities in different in vivo and in vitro studies (Seeram et al., 2003; Peng et al., 2006; Chan et al., 1997; Shirakami, et al., 2008; Ran et al., 2008), demonstrating its involvement on COX-2 and iNOS expression. Therefore, these findings are significant since it has been shown as inhibition of both proteins by *Abarema cochliacarpus* administration improves chronic inflammation in this disease.

In order to deep in the mechanism of action, MAPKs and NF κ B activation were studied. MAPKs have been implicated in many physiologic processes, including cell proliferation, differentiation, and death. The three major types of MAPKs in mammalian cells are ERK, the p38 MAPKs, and JNK, which support a role in mediating IBD (Broom et al., 2009). In this study, we showed that activation of JNK and p38 by TNBS was downregulated by (+)-catechins from *Abarema cochliacarpus*, which is of interesting because inflammatory responses - mainly cytokine production, inflammatory cell infiltration and COX-2 and iNOS upregulation- have been shown to be attenuated by usage of specific inhibitors against JNK and p38 MAPKs (Kwon et al., 2007; Hayashi, 2000; Di Mari et al., 2007; Hollenbach et al., 2005; Assi et al., 2006; Broom et al., 2009). On the other hand, NF κ B could be an important molecular target and its activation has been linked to inflammation. Phosphorylation of I κ B generally leads to the degradation of I κ B α , with the concomitant release of NF κ B and nuclear translocation of NF κ B, which binds to the promoter of many pro-inflammatory genes, most notably iNOS, COX-2, and TNF among others (Cheung & Kong 2010). We have demonstrated that the extract of *Abarema cochliacarpus* was able to block the degradation of I κ B α .

Recently, catechins have been shown to inhibit the MAPK pathway and NF- κ B activity (Kim et al., 2009; Guiterrez-Orozco et al., 2010). Consistent with these reports, our findings suggest that the inhibition of MAPK activation and NF- κ B activity might be a good therapeutic strategy for TNBS-induced ulcerative colitis and propose that the inhibitory effect of catechins from *Abarema cochliacarpus* on inflammatory mediator expression could be mediated, at least in part, by blocking the MAPK pathway with subsequent inhibition of NF- κ B activity.

In conclusion, this study demonstrates that the degree of colitis caused by administration of TNBS is significantly attenuated by (+) catechin, the major constituent of *Abarema cochliacarpus*. The anti-inflammatory effects are associated with (i) a reduction in pro-inflammatory T-helper 1 cytokine response, (ii) an increase in anti-inflammatory T-helper 2 cytokine response leading to the attenuation of the recruitment of neutrophils, (iii) attenuation of COX-2 and iNOS proteins expression potentially by modulation of MAPK pathway and inhibition of NF- κ B activity. In conclusion, these results reinforce the anti-inflammatory effects described previously, suggesting that *Abarema cochliacarpus* could provide a source for the search for new anti-inflammatory compounds useful in ulcerative colitis treatment

Acknowledgements

This study was supported by funds from Coordenação de Aperfeiçoamento de Pessoal de Nível

Superior-PDEE, Brazil, Universidade Estadual de Alagoas, Brazil, and Instituto Federal de Educação Ciência e Tecnologia-Sergipe, Brazil.

References

- Albuquerque UP, Medeiros PM, Almeida ALS, Monteiro JM, Neto EMFL, Melo JG, Santos J P 2007. Medicinal plants of the caatinga (semi-arid) vegetation of NE Brazil: a quantitative approach. *J Ethnopharmacol* 114: 325-354.
- Assi K, Pillai R, Gomez-Munoz A, Owen D, Salh B 2006. The specific JNK inhibitor SP600125 targets tumour necrosis factor-alpha production and epithelial cell apoptosis in acute murine colitis. *Immunology* 118: 112-121.
- Atreya I, Atreya R, Neurath MFJ 2008. NF-kappaB in inflammatory bowel disease. *Intern Med* 263: 591-596.
- Bobin-Dubigeon C, Collin X, Grimaud N, Robert JM, Le Baut G, Petit JY 2001. Effects of tumor necrosis factor- α synthesis inhibitors on rat trinitrobenzene sulphonic acid-induced chronic colitis. *Eur J Pharmacol* 421: 103-110.
- Bradley PP, Priebe DA, Christensen RD, Rothstein G 1982. Measurement of cutaneous inflammation: estimation of neutrophil content with an enzyme marker. *J Invest Dermatol* 78: 206-209.
- Broom OJ, Widjaya B, Troelsen J, Olsen J, Nielsen OH 2009. Mitogen activated protein kinases: a role in inflammatory bowel disease? *Clin and Exper Immunol* 158: 272-280.
- Camacho-Barquero L, Villegas I, Sánchez-Calvo JM, Talero E, Sánchez-Fidalgo S, Motilva V, Alarcón de la Lastra C 2007. Curcumin, a Curcuma longa constituent, acts on MAPK p38 pathway modulating COX-2 and iNOS expression in chronic experimental colitis. *Immunopharmacol Int* 7: 333-342.
- Chan MM, Fong D, Ho CT, Huang HI 1997. Inhibition of inducible nitric oxide synthase gene expression and enzyme activity by epigallocatechin gallate, a natural product from green tea. *Biochem Pharmacol* 54: 1281-1286.
- Cheung KL, Kong AN 2010. Molecular targets of dietary phenethyl isothiocyanate and sulforaphane for cancer chemoprevention. *AAPS J* 12: 87-97.
- Crouvezier S, Powell B, Keir D, Yaqoob P 2001. The effects of phenolic components of tea on the production of pro- and anti-inflammatory cytokines by human leukocytes *in vitro*. *Cytokine* 713: 280-286.
- da Silva MS, Sánchez-Fidalgo S, Talero E, Cárdeno A, Silva MA, Villegas W, Souza Brito A RM., de La Lastra CA 2010. Anti-inflammatory intestinal activity of *Abarema cochliacarpus* (Gomes) Barneby & Grimes in TNBS colitis model. *J Ethnopharmacol* 128: 467-475.
- Di Mari, JF, Saada, JI, Mifflin, RC, Valentich, JD, Powell, DW 2007. HETEs enhance IL-1-mediated COX-2 expression via augmentation of message stability in human colonic myofibroblasts. *Am J Physiol Gastroint Liver Physiol* 293: G719-G728.
- Gambero, A, Maróstica, M, Saad, MJA, Pedrazzoli Jr J 2007. Mesenteric adipose tissue alterations resulting from experimental reactivated colitis. *Inflammatory Bowel Disease* 13: 1357-1364.

- Gee JM, Johnson JT 2001. Polyphenolic compounds: interactions with the gut and implications for human health. *Curr Med Chem* 8: 1245-1255.
- Glasgow JN, Wood T, Perez-Polo JR 2000. Identification and characterization of nuclear factor kappaB binding sites in the murine bcl-x promoter. *J Neurochem* 75: 1377-1389.
- Gutierrez-Orozco F, Stephens BR, Neilson AP, Green R, Ferruzzi MG, Bomser JA 2010. Green and black tea inhibit cytokine-induced IL-8 production and secretion in AGS gastric cancer cells via inhibition of NF- κ B activity. *Planta Med* 76: 1659-1665.
- Hayashi R, Yamashita N, Matsui S, Fujita T, Araya J, Sassa K, Arai N, Yoshida Y, Kashii T, Maruyama M, Sugiyama E, Kobayashi M 2000. Bradykinin stimulates IL-6 and IL-8 production by human lung fibroblasts through ERK- and p38 MAPK-dependent mechanisms. *Eur Respiratory J* 16: 452-458.
- Hanauer SB 2006. Inflammatory bowel disease: epidemiology, pathogenesis, and therapeutic opportunities. *Falk Symp* 12: S3-9.
- Hollenbach E, Vieth M, Roessner A, Neumann M, Malfertheiner P, Naumann M 2005. Inhibition of RICK/nuclear factor-kappaB and p38 signaling attenuates the inflammatory response in a murine model of Crohn's disease. *J Biol Chem* 280: 14981-14988.
- Kaser A, Zeissig S, Blumberg RS 2010. Inflammatory bowel disease. *Ann Rev Immunol* 28: 573-621.
- Khan HA 2004. Computer-assisted visualization and quantitation of experimental gastric lesions in rats. *J Pharmacol Toxicol Methods* 49: 89-95.
- Kim EH, Shim B, Kang S, Jeong G, Lee JS, Yu YB, Chun M 2009. Anti-inflammatory effects of *Scutellaria baicalensis* extract via suppression of immunomodulators and MAP kinase signaling molecules. *J Ethnopharmacol* 126: 320-331.
- Kwon KH, Ohigashi H, Murakami A 2007. Dextran sulfate sodium enhances interleukin-1 beta release via activation of p38 MAPK and ERK1/2 pathways in murine peritoneal macrophages. *Life Sci* 81: 362-371.
- Martin AR, Villegas I, Sanchez-Hidalgo M, de la Lastra CA 2006. The effects of resveratrol, a phytoalexin derived from red wines, on chronic inflammation induced in an experimentally induced colitis model. *Br J Pharmacol* 147: 873-885.
- Mazzon E, Muià C, Di Paola R, Genovese T, Menegazzi M, De Sarro A, Suzuki H, Cuzzocrea S 2005. Green tea polyphenol extract attenuates colon injury induced by experimental colitis. *Free Radical Res* 39:1017-1025.
- Morris GP, Beck PL, Herridge MS, Depew WT, Szewczuk MR, Wallace JL 1989. Hapten-induced model of chronic inflammation and ulceration in the rat colon. *Gastroenterology* 96: 795-803.
- Nakagawa K, Miyazawa T J 1997. Absorption and distribution of tea catechin, (-)-epigallocatechin-3-gallate, in the rat. *J Nutr Sci Vitaminol* 43: 679-684.
- Okushio K, Matsumoto N, Kohri T, Suzuki M, Nanjo F, Hara Y 1996. Absorption of tea catechins into rat portal vein. *Biol Pharm Bull* 19: 326-329.
- Peng G, Dixon DA, Muga SJ, Wargovich MJ 2006. Green tea polyphenol (-)-epigallocatechin-3-gallate inhibits cyclooxygenase-2 expression in colon carcinogenesis. *Mol Carcinog* 45: 309-319.
- Ran ZH, Chen C, Xiao SD 2008. Epigallocatechin-3-gallate ameliorates rats colitis induced by acetic acid. *Biomed Pharmacotherapy* 62: 189-196.
- Sánchez-Calvo, JM, Villegas, I, Sánchez-Fidalgo, S, Camacho-Barquero, L, Talero, E, Motilva, V, Alarcón de la Lastra, C 2009. Protective effect of curcumin, a *Curcuma longa* constituent, in early colonic inflammation in rats. *Drug Dev Res* 70: 425-437.
- Sánchez-Fidalgo S, Villegas I, Martín A, Sánchez-Hidalgo M, de la Lastra CA 2007. PARP inhibition reduces acute colonic inflammation in rats. *Eur J Pharmacol* 563: 216-223.
- Sánchez-Fidalgo S, Cárdeno A, Villegas I, Talero E 2010. Alarcón de la Lastra, C. Dietary supplementation of resveratrol attenuates chronic colonic inflammation in mice. *Eur J Pharmacol* 633: 78-84.
- Sanchez-Muñoz F, Dominguez-Lopez A, Yamamoto-Furouranlsho J K 2008. Role of cytokines in inflammatory bowel disease. *World J Gastroenterol* 14: 4280-4288.
- Santos FA, Silva RM, Campos AR, de Araújo RP, Lima Júnior RCP, Rao VSN 2004. 1,8-cineole (eucalyptol), a monoterpene oxide attenuates the colonic damage in rats on acute TNBS-colitis. *Food Chem Toxicol* 42: 579-584.
- Santos, ALS 2008. Interação de comunidades rurais com recursos vegetais: o caso dos remanescentes de floresta estacional do município de Junqueiro (AL-Brasil). 133 f. Tese de doutorado, Universidade Federal de Pernambuco.
- Sato K, Kanazawa A, Ota N, Nakamura T, Fujimura K 1998. Dietary supplementation of catechins and α -tocopherol accelerates the healing of trinitrobenzene sulfonic acid-induced ulcerative colitis in rats. *J Nutr Sci Vitaminol* 44: 769-778.
- Schmidt C, Stallmach A 2005. Etiology and pathogenesis of inflammatory bowel disease. *Minerva Gastroenterol Dietol* 51: 127-145.
- Seeram NP, Cichewicz RH, Chandra A, Nair MG 2003. Cyclooxygenase inhibitory and antioxidant compounds from crabapple fruits. *J Agric Food Chem* 51: 1948-1951.
- Shirakami Y, Shimizu M, Tsurumi H, Hara Y, Tanaka T, Moriwaki H 2008. EGCG and polyphenon E attenuate inflammation-related mouse colon carcinogenesis induced by AOM and DSS. *Mol Med Rep* 1: 355-361.
- Silva MS, Antonioli AR, Batista, JS, Mota, CN 2006. Plantas medicinais usadas nos distúrbios do trato gastrointestinal no povoado Colônia Treze, Lagarto, SE, Brasil. *Acta Bot Bras* 20: 815-829.
- Silva NCB, Esquibel MA, Alves IM, Velozo ES, Almeida MZ, Santos JES, Campos-Buzzi F, Meira AV, Cechinel-Filho V 2009. Antinociceptive effects of *Abarema cochliacarpus* (B.A. Gomes) Barneby & J.W.Grimes (Mimosaceae). *Rev Bras Farmacogn* 19: 46-50.
- Strober W, Fuss IJ, Blumberg RS 2002. The immunology of mucosal models of inflammation. *Ann Rev Immunol* 20: 495-549.
- Tak PP, Firestein GS 2001. NF- κ B: a key role in inflammatory diseases. *J Clin Invest* 107: 7-11.
- Talero E, Sanchez-Fidalgo S, Alarcón de la Lastra C, Ilanes M, Calvo JR, Motilva V 2008. Acute and chronic responses

- associated with adrenomedullin administration in experimental colitis. *Peptides* 29: 2001-2012.
- Thompson-Chagoyan OC, Maldonado J, Gil A 2005. Aetiology of inflammatory bowel disease (IBD): role of intestinal microbiota and gut-associated lymphoid tissue immune response. *Clin Nutr* 24: 339-352.
- Varilek GW, Yang F, Lee FY, de Villiers WJS, Zhong Y, Helieh SOZ, Kenloch F, Westberry JM, Craig JM 2001. Green tea polyphenol extract attenuates inflammation in interleukin-2-deficient mice, a model of autoimmunity. *J Nutr* 131: 2034-2039.
- Villegas I, Alarcon de la Lastra C, Orjales A, La Casa C 2003. A new flavonoid derivative, dosmalfate, attenuates the development of dextran sulphate sodium-induced colitis in mice. *Internat Immunopharmacol* 3: 1731-1741.
- Waetzig GH, Seegert D, Rosenstiel P, Nikolaus S, Schreiber S 2002. p38 mitogen-activated protein kinase is activated and linked to TNF-alpha signaling in inflammatory bowel disease. *J Immunol* 168: 5342-5351.
- Wirtz S, Neurath MF 2007. Mouse models of inflammatory bowel disease. *Adv Drug Delivery Rev* 59: 1073-1083.
- World Conservation Monitoring Centre 1998. *Abarema cochliacarpus*. *Red list of threatened species*. <http://www.iucnredlist.org>, accessed in November 2009.

***Correspondence**

Maria Silene da Silva
Universidade Estadual de Campinas, Laboratório de Produtos Naturais, Departamento de Anatomia e Biologia Celular e Fisiologia e Biofísica
Rua Monteiro Lobato s/n, Caixa Postal 6109, 13083-86 Campinas-SP, Brazil
mariasilene.silva@uneal.edu.br
Tel.: +55 19 3521 6192 and 3521 6131
Fax: +55 19 3521 6185