

# Acute effects of mechanical ventilation with hyperoxia on the morphometry of the rat diaphragm

Efeitos agudos da ventilação mecânica com hiperoxia na morfometria do diafragma de ratos

Célia R. Lopes<sup>1</sup>, André L. M. Sales<sup>2</sup>, Manuel De J. Simões<sup>3</sup>, Marco A. Angelis<sup>4</sup>, Nuno M. L. Oliveira<sup>5</sup>

## Abstract

**Background:** Prolonged mechanical ventilatory support (MVS) combined with high oxygen concentrations has a negative impact on diaphragm function. However, the acute effects of MVS with hyperoxia have not been elucidated. **Objective:** To analyze the acute effects of mechanical ventilation with hyperoxia on the morphometry of the rat diaphragm. **Methods:** An experimental, prospective study was conducted with Wistar rats (weight: 400±20 g), which were randomly allocated to two groups. The control group (n=4) was anesthetized, tracheostomized and kept spontaneously breathing room air for 90 minutes. The experimental group (n=5) was also anesthetized, curarized, tracheostomized and kept in controlled mechanical ventilation for the same amount of time. Both groups were submitted to median thoracotomy for sample collection of costal fibers from the diaphragm muscle, which were sectioned every 5 µm and stained with hematoxylin and eosin for the morphometric study. Independent Student's t tests were employed to investigate differences between groups, with a significance level of p<0.05. **Results:** There were no signs of acute muscle lesions, however the blood capillaries became dilated in the experimental group. The mean morphometric data related to the maximum cross-sectional diameter of the diaphragm costal fibers were 61.78 ±17.79 µm and 70.75±9.93 µm (p=0.045) for the control and experimental groups, respectively. **Conclusions:** Short-term mechanical ventilation with hyperoxia led to significant microvascular and muscle changes, which may reflect the onset of an inflammatory process.

**Key words:** mechanical ventilation; hyperoxia; morphometric analysis; diaphragm; rats.

## Resumo

**Contextualização:** A assistência ventilatória mecânica (AVM) prolongada associada a altas frações de oxigênio produz impacto negativo na função diafragmática. No entanto, não são claros os efeitos agudos da AVM associada a altas frações de oxigênio em pulmões aparentemente saudáveis. **Objetivo:** Analisar os efeitos agudos da ventilação mecânica com hiperóxia na morfometria do diafragma de ratos. **Métodos:** Estudo experimental prospectivo, com nove ratos Wistar, com peso de 400±20 g, randomizados em dois grupos: controle (n=4), anestesiados, traqueostomizados e mantidos em respiração espontânea em ar ambiente por 90 minutos e experimental (n=5), também anestesiados, curarizados, traqueostomizados e mantidos em ventilação mecânica controlada pelo mesmo tempo. Foram submetidos à toracotomia mediana para coleta da amostra das fibras costais do diafragma que foram seccionadas a cada 5 µm e coradas pela hematoxilina e eosina para o estudo morfométrico. Para a análise estatística, foi utilizado o teste *t* de Student não pareado, com nível de significância de p<0,05. **Resultados:** Não foram encontrados sinais indicativos de lesão muscular aguda, porém observou-se dilatação dos capilares sanguíneos no grupo experimental. Os dados morfométricos do diâmetro transversal máximo da fibra muscular costal foram em média de 61,78±17,79 µm e de 70,75±9,93 µm (p=0,045) nos grupos controle e experimental respectivamente. **Conclusão:** A ventilação mecânica de curta duração com elevada concentração de O<sub>2</sub> produziu marcantes alterações microvasculares e musculares, podendo refletir o início do processo inflamatório.

**Palavras-chave:** ventilação mecânica; hiperóxia; análise morfométrica; diafragma; ratos.

Received: 17/06/2008 – Revised: 10/12/2008 – Accepted: 19/05/2009

<sup>1</sup> Physical Therapy Course, Universidade Federal de Uberlândia (UFU), Uberlândia (MG), Brazil

<sup>2</sup> Physical therapist

<sup>3</sup> Department of Histology, Universidade Federal de São Paulo (UNIFESP), São Paulo (SP), Brazil

<sup>4</sup> Department of Anatomy, UNIFESP

<sup>5</sup> Physical Therapy Course, Universidade Federal do Triângulo Mineiro (UFTM), Uberaba (MG), Brazil

Correspondence to: Célia Regina Lopes, Rua Xavantes, 1.056, Apto:1.503, Bairro Lídice, CEP 38400-082, Uberlândia (MG), Brazil, e-mail: tsila@uol.com.br

## Introduction

Mechanical ventilation (MV) is clinically used to treat patients who are unable to maintain appropriate alveolar ventilation, to optimize gas exchange and to prevent respiratory muscle fatigue<sup>1</sup>. However, invasive MV combined with high oxygen concentrations can lead to many complications, including: infection, barotrauma, cardiovascular injury, tracheal injury, oxygen toxicity and lung injury induced by the ventilator<sup>2</sup>. It is also associated with diaphragmatic atrophy and a decrease in maximal specific force production<sup>3,4</sup>. Higher oxygen concentration also implies more oxidative substrate available for this type of reaction, and with more oxygen-activated free radicals, generalized vasoconstriction occurs, with lung circulation being an exception<sup>1</sup>.

Yang et al.<sup>5</sup> and Shanely et al.<sup>6</sup> analyzed the effects of controlled mechanical ventilation (CMV) on diaphragm muscle mass and contractile function in rats ventilated for four days, and they concluded that MV produces remodeling and functional changes in the diaphragm that can hinder the discontinuation of ventilatory support. Another study carried out with anesthetized rats under CMV for two days demonstrated a 42% reduction in diaphragm contraction force when compared to animals breathing spontaneously<sup>7</sup>. Zergeroglu et al.<sup>8</sup>, in an experimental study through biochemical analysis, observed that intubated rats undergoing MV for 6 and 18 hours showed diaphragmatic oxidative stress. In contrast, no changes were observed in the diaphragm of rats ventilated for three hours. According to Van Gammeren et al.<sup>3</sup>, it has been reported that only 12 hours of MV reduce diaphragmatic contraction force by approximately 18%, and 48 hours of MV reduce force by 60%. Periods of approximately 18 hours of MV have been shown to promote proteolysis, atrophy and oxidative injury in the diaphragm muscle fiber, similar to what occurs in the locomotive system when it remains immobilized for a long period of time<sup>9</sup>.

Some experimental studies have used morphometric analysis to evaluate the biological tissues quantitatively after medical and/or physical therapy intervention<sup>10,11</sup>, e.g. short-duration procedures such as hyperventilation and hyperbaric oxygen therapy carried out by physical therapists during tracheal aspiration of patients under MV.

Based on the findings described above, it is feasible to study the effects of short-term MV on the diaphragmatic morphology of rats as a method of evaluating a type of intervention frequently used in critical patients<sup>12</sup>. The effects of MV on the muscle function of animal models have been described in the literature, however studies on short-term MV and its influence on morphology and microvascular changes in the diaphragm muscle are less known. Therefore, this experimental study

aims to examine the acute effects of MV with hyperoxia on the morphometry of the rat diaphragm with the intention of providing a better understanding of the different conditions seen in Intensive Care Unit patients and, thus, promote the study of preventive and/or therapeutic strategies in physical therapy, applied to critically ill individuals.

## Methods

### Experimental animals

Nine Wistar rats (400±20 g) were divided into two plastic cages. All animals had free access to water and standard food pellets and were submitted to environmental conditions of controlled lighting (alternating light and dark cycle of 12 hours) and temperature. The study was carried out in agreement with the International Guide for the Care and Use of Laboratory Animals (National Research Council)<sup>13</sup> and approved by the Animal Research Ethics Committee of Faculdades Metropolitanas Unidas (UniFMU) under protocol number 002/2000.

The animals were randomly divided into two groups: control group (n=4), in which the rats were anesthetized, tracheostomized and kept spontaneously breathing room air for 90 minutes, and experimental group (n=5), in which the rats were also anesthetized, curarized, tracheostomized and kept in controlled MV in a pediatric ventilator (Atlanta<sup>®</sup> model, K. Takakoka<sup>®</sup>) for 90 minutes. The following parameters were set: peak inspiratory pressure of 15 cmH<sub>2</sub>O, positive end-expiratory pressure of 1 cmH<sub>2</sub>O, respiratory frequency of 60 rpm, inspiratory flow of 1 L/min, tidal volume of 1mL/100g and with fraction of inspired oxygen equal to 1.0, for an hour and a half. In order to prevent hypothermia, all animals in the study were covered and kept close to the heater during the entire protocol. There were no sample losses.

### Surgical and experimental procedure

The animals were weighed to calculate the appropriate dosage of anesthetic. Each animal was positioned on a 90 cm<sup>2</sup> wooden board and kept immobilized, fixed by the paws and teeth and anesthetized with intraperitoneal application of 60 mg/kg of sodium thiopental. A surgical scalpel with a no. 23 blade was used to make the 3-cm incision starting from the manubrium of the sternum. The skin was sectioned, the sternohyoid muscle was opened and the trachea was subsequently dissected. The device used as tracheotomy was fixed with suture to the underside of trachea. A partial incision was made in the trachea, allowing the insertion of a 4-cm intravenous access device (the BD Asepto<sup>®</sup> no. 27 G) through tracheotomy until

the level of the carina, and the access was held by the above-mentioned suture. The control group remained in spontaneous ventilation for 90 minutes, while the experimental group was connected to the mechanical ventilator in the previously mentioned parameters. An injection of 0.4 mg/kg of pancuronium bromide was applied intraperitoneally for neuromuscular block.

After the prescribed period, both groups underwent thoracotomy, with an incision between the manubrium and the xiphoid process. The chest skin flaps were raised and an incision was made on the penultimate right intercostal space to remove a diaphragmatic fragment of right costal area. This fragment was then placed on a cork plate and immersed in 10% formaldehyde, thus preventing proteolysis of the diaphragm. The euthanasia was carried out with a lethal dose of sodium pentobarbital (65 mg/Kg) via intraperitoneal injection (Cristália Produtos Químicos e Farmacêuticos Ltda, Campinas, SP).

## Histological preparation

The histological processing and morphometric analysis of the diaphragm were performed at the Histology and Morphology Laboratory of Universidade Federal São Paulo (UNIFESP). The fragments were dehydrated in increasing concentrations of ethyl alcohol, cleared in xylol and embedded in paraffin. The inclusion was done in a way that the cross-sections of the muscle fibers of the costal diaphragm could be observed in the histological slides. Next, the blocks were sliced in a Minot microtome, adjusted for 5  $\mu$ m, and the slices were placed on albumin-coated slides and incubated for 24 hours at 37° C. A slide from each animal was then submitted to hematoxylin and eosin (H&E) staining for subsequent morphometric analysis.

The H&E-stained slides were used to quantify the maximum cross-sectional diameter of the muscle cell of the costal diaphragm. In each slide, ten images were obtained for each slice under 40x magnification. The images were captured on a computerized system consisting of a light microscope (Axioskop, Carl Zeiss) with a 100X objective lens adapted to a high-resolution camera (AxioCam MRC, Carl Zeiss) and a Pentium® 4 PC, with Axion Vision Rel 4.2 software (Carl Zeiss) and a color monitor (Samsung). The software IMAGELAB® (SOFTIUM Informatics Ltda.) was used for image processing.

## Statistical analyses

Statistical analyses were performed using the Prism® software (GraphPad, California, USA), and unpaired Student's *t* test was applied. The  $\alpha$  level was set at 0.05 to reject the null hypothesis.

## Results

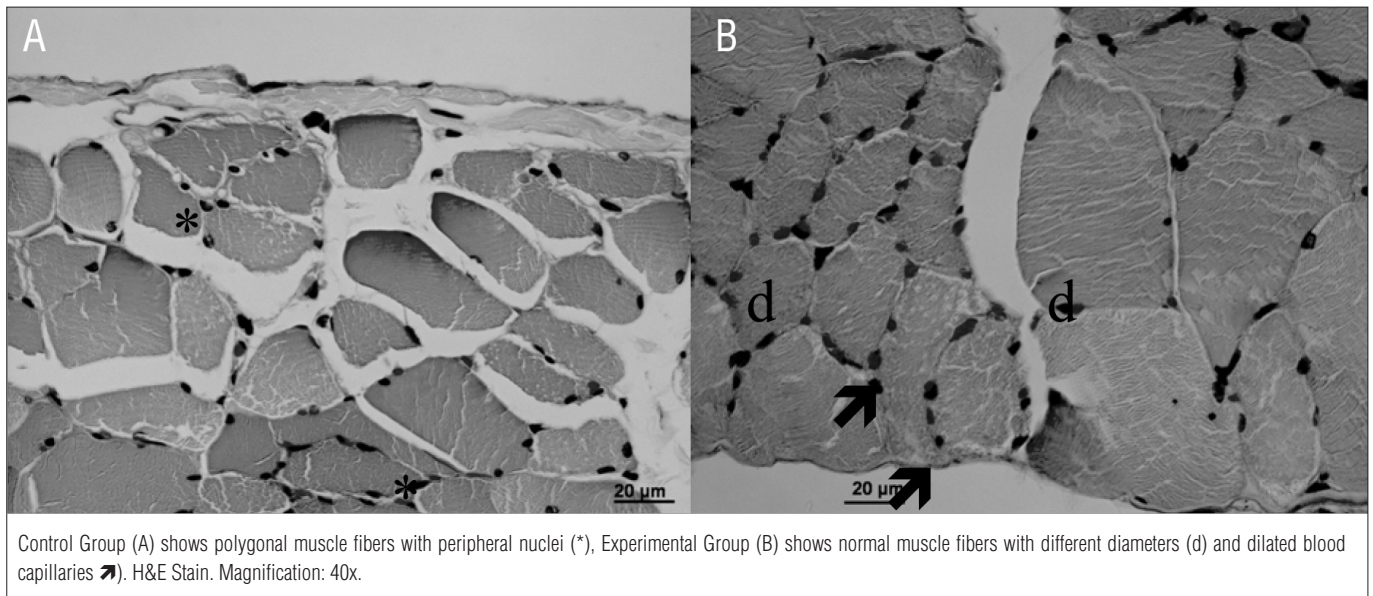
Through the morphometric procedure, it was possible to analyze qualitatively the vascular changes and the cross-sectional diameter of the fibers of the diaphragm muscle under normal conditions and under the influence of MV. The analyses demonstrated that, during 90 minutes of MV, there were no signs indicating the presence of acute muscle injury. In the control group, the diaphragm muscle had the characteristics of a healthy skeletal muscle tissue, showing muscle fibers with polygonal shape, heterogeneous cytoplasm, peripheral nuclei and fascicular organization (Figure 1A).

In the experimental group, the diaphragm muscle demonstrated similar characteristics to the control group, but with muscle fibers of various diameters and shapes and the presence of dilated blood capillaries (Figure 1B). In the control group, the maximum cross-sectional diameter of the diaphragm muscle fibers was  $61.78 \pm 17.79 \mu\text{m}$  while, in the experimental group, it was  $70.75 \pm 9.93 \mu\text{m}$ . There was a statistically significant difference ( $p=0.045$ ) in the cross-sectional diameter of muscle fibers in the experimental group compared to the control group (Figure 2).

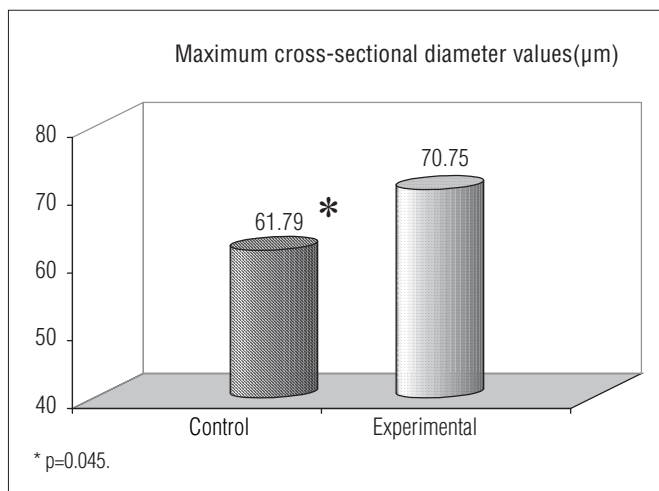
## Discussion

The main morphological change observed when comparing the control and experimental groups was the presence of dilated blood capillaries which perfuse the muscle cells of the costal diaphragm in the group undergoing short-term MV combined with hyperoxia. The vasodilation observed in the present study may be due to the increase in the production of free radicals produced during the invasive MV and during hyperoxia. The study by Brancatisano et al.<sup>14</sup> on anesthetized dogs demonstrated that blood flow to the diaphragm during MV in the CMV modality was significantly reduced when compared with spontaneous ventilation and that, in the costal region of muscle, the topography of the flow was independent of gravity, and these areas are well-perfused regardless of the position adopted. To Gayan-Ramirez and Decramer<sup>15</sup>, two hours of MV is not sufficient to initiate a diaphragm contractile dysfunction or cause damage to the muscle fiber, but only to increase the infiltration of neutrophils and macrophages, with myeloperoxidase activity and muscle edema.

In the morphometry carried out in this study, it was possible to observe a significant increase in the cross-sectional diameter of the diaphragmatic muscle cells in the experimental group compared with the group control. In a study with rats that underwent CMV for four days, Yang et al.<sup>5</sup> observed a decrease in the relative mass of the diaphragm compared to the



**Figure 1.** Cross-section of the diaphragm muscle of rats.



**Figure 2.** Mean values of the maximum cross-sectional diameter (µm) of the diaphragm muscle fibers in the control and experimental groups.

total mass, with a non-selective reduction in cross-sectional area of muscle fiber for all types of muscle fibers.

Prolonged MV can cause muscle atrophy and a decrease in diaphragm peak force with a reduction in myofibrillar protein and in the cross-section of all the types of muscle fibers. The presence of protein oxidation and lipid peroxidation increases the activity of proteases and the oxidative stress of the diaphragm. Thus, the reduction in diaphragmatic function is time-dependent on the use of controlled ventilation<sup>6</sup>. Sassoon et al.<sup>7</sup> also carried out an *in vivo* and *in vitro* study in which they have analyzed the morphological and contractile characteristics of the diaphragm of rabbits ventilated on CMV for one to three days. The authors observed that diaphragm inactivity with CMV compromises diaphragm force and causes myofibril damage.

In the present study, there was no evidence of injury to the diaphragm muscle, although other studies using short-term MV (up to 18 hours) have demonstrated the occurrence of proteolysis<sup>15</sup>, atrophy<sup>16</sup> and oxidative damage to the diaphragm muscle fibers<sup>8</sup>. These studies indicate that controlled MV results in rapid diaphragmatic atrophy and contractile dysfunction in test animals<sup>17</sup>. However, Decramer and Gayans-Ramirez<sup>12</sup> demonstrated that 24 hours of mechanical ventilation is insufficient to produce damage to the membrane of the muscle fiber and induce an inflammatory response. Powers et al.<sup>1</sup> reported changes in diaphragmatic contractile function after short-term ventilation, and these changes are directly proportional to the time spent in ventilation. MV induces diaphragmatic contractile dysfunction with no membrane damage or inflammation, but with significant neutrophil infiltration and edema<sup>3</sup>.

The increase in cross-sectional diameter observed in this study does not represent hypertrophy of the diaphragm cell. It may represent a delay in the return of the membrane potential to baseline because the muscle was inactive and without acetylcholine action from the use of the neuromuscular blocker, as seen in Lawler, Hu and Barnes<sup>18</sup> who reported a change in the relaxation phase of potassium (K<sup>+</sup>) contractures in diaphragm fiber bundles exposed to concentrations of reactive oxygen species.

It was possible to observe in the studied group that, during invasive short-duration MV with high inspired oxygen fraction, morphological and structural changes occur in the diaphragm muscle cells, and these changes may contribute to diaphragmatic dysfunction induced by the ventilator<sup>19</sup> and to the difficulty weaning patients after CMV and higher inspired oxygen fraction. Gayans-Ramirez and Decramer<sup>15</sup> demonstrated

intrinsic changes in diaphragm myofibrils related to the modifications in muscle fiber size, sarcomere length, mass and muscle metabolism resulting from MV. These effects are multifactorial firstly because there is no electrical activity in the diaphragm during CMV. Secondly, the passive pace of shortening may have a negative effect on the muscle and can be the cause of fiber injury or of adaptation of the muscle phenotype. Thirdly, as the MV is used to reduce the work of the diaphragm, it becomes a cause of muscle deconditioning.

According to Oliveira et al.<sup>20</sup>, there was an increase in inflammatory mediators analyzed after 60, 120 and 180 minutes from the time of lung injury produced with hydrochloric acid in rats undergoing MV, which shows an early pro-inflammatory response that has been demonstrated in the pathogenesis of several models which are neutrophils mediated. In the experimental evaluation of the acute effects of MV with hyperoxia in the rat diaphragm, there was an increase in tissue vascularization and in the variation of the cross-sectional muscle diameter. However, in this study, the duration of the MV may not have been sufficient to induce an inflammatory response; longer periods of ventilation could demonstrate a greater extent of

diaphragmatic atrophy and increase the risk of diaphragmatic injury induced by the ventilator or the high concentration of oxygen.

## Conclusions

Short-term MV with high oxygen concentrations led to significant microvascular and muscular changes and may reflect the onset of an inflammatory process. These changes may have clinical relevance in addressing critical patients.

## Acknowledgments

We thank the technical staff of the Experimental Laboratory and the Physical Therapy course coordinator at UniFMU; the technical staff of the Laboratory of Histology and Morphology at UNIFESP; Marcelo Costa, representative of K. Takakoka®, for the ventilatory support equipment for the research; to all who supported this study.

## References

1. Powers SK, Shanely RA, Coombes JS, Koesterer TJ, Mackenzie M, Gammeren D, et al. Mechanical ventilation results in progressive contractile dysfunction in the diaphragm. *J Appl Physiol.* 2002;92(5):1851-8.
2. Vassilakopoulos T, Petrof JB. Ventilator-induced diaphragmatic dysfunction. *Am J Respir Crit Care Med.* 2004;169(3):336-41.
3. Van Gammeren D, Falk DJ, DeRuisseau KC, Sellman JE, Decramer M, Powers SK. Reloading the diaphragm following mechanical ventilation does not promote injury. *Chest.* 2005;127(6):2204-10.
4. RácZ GZ, Gayan-Ramirez G, Testelmans D, Cadot P, DePaepe K, Zador E, et al. Early changes in rat diaphragm biology with mechanical ventilation. *Am J Respir Crit Care Med.* 2003;168(3):297-304.
5. Yang L, Luo J, Bourdon J, Lin MC, Gottfried SB, Petrof BJ. Controlled mechanical ventilation leads to remodeling of the rat diaphragm. *Am J Respir Crit Care Med.* 2002;166(8):1135-40.
6. Shanely RA, Van Gammeren D, Deruisseau KC, Zergeroglu AM, McKenzie ML, Yarasheski KF, et al. Mechanical ventilation depresses protein synthesis in the rat diaphragm. *Am J Respir Crit Care Med.* 2004;170(9):994-9.
7. Sassoon CS, Caiozzo VJ, Manka A, Sieck GC. Altered diaphragm contractile properties with controlled mechanical ventilation. *J Appl Physiol.* 2002;92(6):2585-95.
8. Zergeroglu M, McKenzie MJ, Shanely RA, Gammeren D, DeRuisseau KC, Powers S. Mechanical ventilation-induced oxidative stress in the diaphragm. *J Appl Physiol.* 2003;95(3):1116-24.
9. Supinski G. Free radical induced respiratory muscle dysfunction. *Mol Cell Biochem.* 1998;179(1-2):99-110.
10. Fernandes KCBG, Polacow MLO, Guirro RRR, Campos GER, Somazz MC, Pinto VF, et al. Análise morfológica dos tecidos musculares e conjuntivo após desnervação e estimulação elétrica de baixa frequência. *Rev Bras Fisioter.* 2005;9(2):235-41.
11. Oliveira NML, Rainero EP, Salvini TF. Three intermittent sessions of cryotherapy reduce the secondary muscle injury in skeletal muscle of rat. *J Sports Sci Med.* 2006;5:228-34.
12. Decramer M, Gayan-Ramirez G. Ventilator-induced diaphragmatic dysfunction: toward a better treatment? *Am J Respir Crit Care Med.* 2004;170(11):1141-2.
13. Institute of Laboratory Animal Research, Commission on Life Sciences, National Research Council. Guide for the care and use of laboratory animals. Washington: National Academy Press; 1996.
14. Brancatisano A, Amis TC, Tully A, Kelly WT, Engel LA. Regional distribution of blood flow within the diaphragm. *J Appl Physiol.* 1991;71(2):583-9.

15. Gayan-Ramirez G, Decramer M. Effects of mechanical ventilation on diaphragm function and biology. *Eur Respir J*. 2002;20(6):1579-86.
16. Shanely RA, Coombes JS, Zergeroglu AM, Webb AI, Powers SK. Short-duration mechanical ventilation enhances diaphragmatic fatigue resistance but impairs force production. *Chest*. 2003;123(1):195-201.
17. Bernard N, Matecki S, Py G, Lopez S, Mercier J, Capdevila X. Effects of prolonged mechanical ventilation on respiratory muscle ultrastructure and mitochondrial respiration in rabbits. *Intensive Care Med*. 2003;29(1):111-8.
18. Lawler JM, Hu Z, Barnes WS. Effect of reactive oxygen species on K<sup>+</sup> contractures in the rat diaphragm. *J Appl Physiol*. 1998;84(3):948-53.
19. Jubran A. Critical illness and mechanical ventilation: effects on the diaphragm. *Respir Care*. 2006;51(9):1054-64.
20. Oliveira WR, Silva I, Simões RS, Fuchs LF, Oliveira-Filho RM, Oliveira-Junior IS. Effects of prone and supine position on oxygenation and inflammatory mediator in a hydrochloric acid-induced lung dysfunction in rats. *Acta Cir Bras*. 2008;23(5):451-5.