

Branch retinal artery occlusion in Susac's syndrome

Oclusão de ramo arterial da retina na Síndrome de Susac

Ricardo Evangelista Marrocos de Aragão¹, Lorena Maria Araújo Gomes², Ieda Maria Alexandre Barreira³, Francisco Holanda Oliveira Neto⁴, Ariane Sá Vieira Bastos⁵

ABSTRACT

Susac's syndrome is a rare disease attributed to a microangiopathy involving the arterioles of the cochlea, retina and brain. Encephalopathy, hearing loss, and visual deficits are the hallmarks of the disease. Visual loss is due to multiple, recurrent branch arterial retinal occlusions. We report a case of a 20-year-old woman with Susac syndrome presented with peripheral vestibular syndrome, hearing loss, ataxia, vertigo, and vision loss due occlusion of the retinal branch artery.

Keywords: Vasculitis; Cerebrovascular disorders; Retinal artery occlusion; Hearing loss; Susac's Syndrome

RESUMO

Síndrome de Susac é uma microangiopatia rara que afeta as arteríolas da cóclea, retina e encéfalo. Encefalopatia, perda auditiva e baixa da acuidade visual formam a tríade clássica da doença. A baixa de acuidade visual ocorre devido a múltiplas e recorrentes oclusões de ramo arterial da retina. Relatamos o caso de uma paciente de 20 anos com síndrome de Susac apresentando síndrome vestibular periférica, perda auditiva, vertigem, ataxia e baixa da acuidade visual por oclusão de ramo arterial de retina.

Descritores: Vasculite; Transtornos cerebrovasculares; Oclusão da artéria retiniana; Perda auditiva; Síndrome de Susac

¹Doutor em Medicina pela Universidade de Regensburg – Alemanha; preceptor de Retina do Hospital Universitário Walter Cantídio da Universidade Federal do Ceará (UFC) – Fortaleza (CE), Brazil;

^{2,4,5}Hospital Universitário Walter Cantídio da Universidade Federal do Ceará (UFC) – Fortaleza (CE), Brazil;

³CIDH - Centro Integrado de Diabetes e Hipertensão do Estado do Ceará – Fortaleza (CE), Brazil.

Study carried out at Universidade Federal do Ceará (UFC) – Fortaleza (CE), Brazil

The authors declare no conflicts of interest

Received for publication: 31/3/2013 - Accepted for publication: 14/6/2013

INTRODUCTION

Susac's syndrome (SS) is a rare disease characterised by the clinical triad of vision disturbances, encephalopathy, and sensorineural hearing loss. The exact prevalence of SS is unknown, and its pathogenesis is still unclear autoimmune vasculitis process that leads to an occlusion of small vessels in the brain, retina and inner ear are believed to play an important role⁽¹⁾. Typically, the SS affects young women between 20 and 40⁽²⁾. The prognosis mainly depends on the severity, the often self-limited and monophasic, sometimes fluctuating and rarely relapsing clinical course, and the appropriate treatment. Retinal infarction, due recurrents brach retinal artery occlusions (BRAO), presenting with scotoma is one of the clinical hallmarks although often not predominant. Patients can present with episodic or permanent vision loss⁽¹⁾. This syndrome was first described by John O. Susac in 1979 in two young women presenting with the classic clinical triad. Since then, more than 60 cases have been reported⁽³⁾. This condition is often under diagnosed or misdiagnosed as multiple sclerosis or systemic lupus erythematosos⁽⁴⁻⁶⁾.

Case report

A 20-year-old caucasian woman was referred to our service to confirm the presence of a Susac's Syndrome due to visual loss in the right eye. She started 2 months before with headache, vertigo, hearing loss, ataxia, vomiting, and weakness in the left side of the body. Laboratory studies, including lupus anticoagulant, cerebrospinal fluid analysis, and sorologies were normal. Chest X-ray, and electrocardiogram did not reveal alterations.

Cerebral MRI (magnetic resonance imaging) showed multiple small foci of high signal intensity in the periventricular white matter, corpus callosum and left centrum semiovale. The aspect and distribution of these lesions favored the diagnosis of multiple sclerosis. The standard audiometric tests showed an asymmetric neurosensory hearing loss with right side predominance. The visual acuity was 20/100 OD, 20/20 OS. Campimetry disclosed visual field deficits on the right eye, and on the left was normal. The anterior segment biomicroscopy did not show note-

worthy findings. The fundoscopy revealed extensive ischemic retinal edema of the superior part of macular area of the OD (figure 1). Fluorescein angiography (FA) showed lack of perfusion in the involved artery of the superior part of the macular area and artery wall hyperfluorescence, obstruction in the peripheral retina of the OD, and hyperfluorescence in retinal artery with a "boxcar" segmentation of the blood column (figure 2). The patient has been treated with pulse corticosteroid therapy with 1g of methylprednisolone IV once a day for five days followed by 80mg once a day. Immunoglobulin was decided to be started. The patient showed no improvement of the visual, auditory and neurological complains. She was maintained on treatment in the hospital.

DISCUSSION

Susac's Syndrome consists of the clinical triad of encephalopathy, branch retinal artery occlusions, and hearing loss due to a microangiopathy involved the vessel of the brain, cochlea and retina. The syndrome was first described in 1975 by John O. Susac, when he saw two young women with the classical triad. Acronyms have been suggested; RED-M: retinopathy, encephalopathy, hearing loss associated microangiopathy and SICRET: small infarcts of cochlear, retinal, and encephalic tissues. There is a female predominance of 3 to 1, and the age extending from 16 years to 58 years⁽⁷⁾. Headache is often the initial symptom followed by cognitive changes, ataxia, confusion, and memory and psychiatric disturbance due to involvement of the brain⁽⁸⁾. Following by hearing loss and visual impairment due to cochlea and retinal arterial branch involvement respectively. Our patient presented with vertigo, ataxia, and hearing loss 6 months before ocular complaint.

Sometimes the triad may become complete only after a delay of weeks or even years⁽⁶⁾. The clinical course of the SS is usually self-limited, fluctuating, and monophasic. It can last from 2-4 years or can also be as short as 6 months or as long as 5 years. Partial forms of the triad have been reported, making the diagnosis more challenging. Encephalopathic symptoms may also obscure initial visual or auditory complaints. Neuropsychiatric disturbance may be seen in 75% of cases; in only 10% of

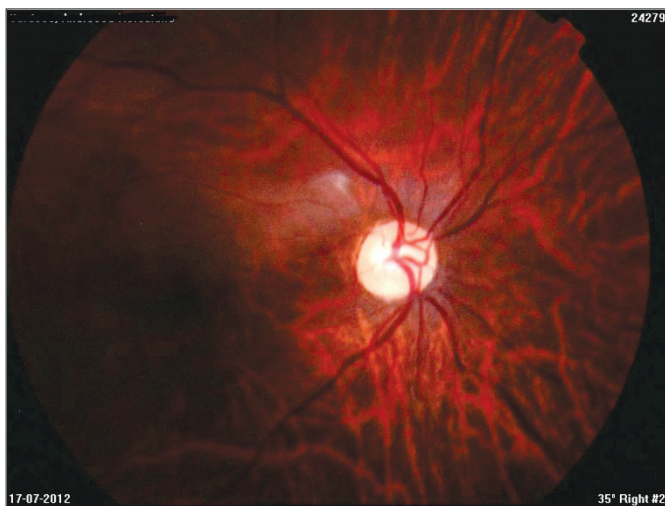


Figure 1: Extensive ischemic retinal edema of the superior part of macula partially involving fovea, and palor of the optic disc on the right eye

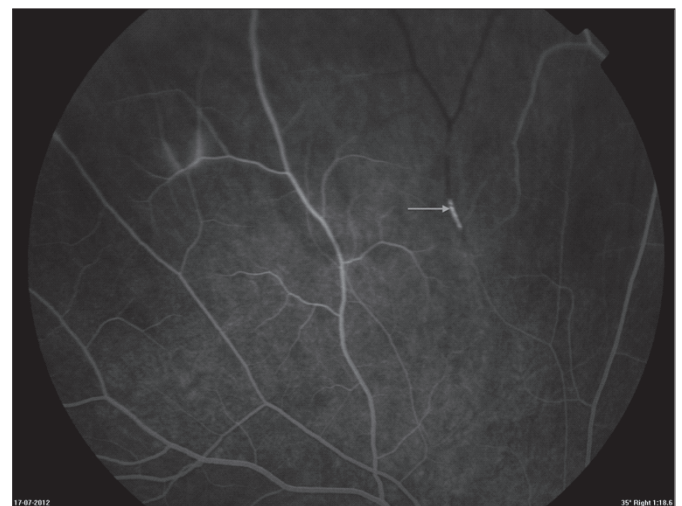

Figure 2: Fluorescein angiogram on the right eye shows obstruction of perfusion caused by serous deposit along the vessel wall known as Gass plaques (arrow); revealed also leaking in arterioles characterizing vasculitis

cases the disease is revealed by ophthalmologic or cochlear symptoms^(3,7). Some patients recover with little or no residual disease, albeit some are profoundly impaired with deafness, gait disturbance and cognitive deficits.

The pathogenesis is still unknown, response to immunosuppressive therapy suggests an autoimmune basis, leading to small vessels vasculitis causing infarction in the related tissues.

MRI findings in SS always show corpus callosum involvement. The lesions are typically small, multifocal, and frequently enhance during the acute stage. Involve typically the central fibers and spare the periphery. The white matter is also involved. Our case reported typical brain lesions of the corpus callosum and white matter. The cranial nerves are not involved in SS. Characteristic audiological findings included low-frequency hearing loss, vertigo, and tinnitus due to microangiopathic lesions of the apical cochlea end arterioles, as presented in our case. Branch retinal arterial occlusions in patient with SS are due to vasculitis. They tend to be bilateral, and to be multiple, widely disseminated in the retina, and temporally separated by as long as several months. They are not seen in the very onset. The white material in the arterial lumen may represent aggregations of immune complexes or debris from damaged endothelium.

Multiple peripheral retinal arteriolar branch occlusions can be seen on ophthalmoscopic examination or on retinal fluorescein angiography. The occlusions may be quite extensive or may be very subtle. Segmental loss of vision in one or both eyes and scintillating scotomas are a typical visual complaint. Retinal fluorescein angiography is the best method for detecting the retinal arteriolar occlusions⁽³⁾.

A characteristic feature on FA is arterial wall hyperfluorescence, often proximal to sites of occlusion, as shown in our patient. Histopathological descriptions of a SS in the retina and optic nerve head confirm the clinical observations of vascular occlusions and subsequent ghost vessels. Serous deposits with compression of retinal vessel lumens observed histologically probably represent the “string of pearls” described clinically in SS. Chronic extension of these serous deposits along the vessel wall are possibly the cause of retinal arterial wall plaques as described as Gass plaques (figure 2), typically seen in SS⁽⁹⁾.

The diagnosis of SS is not easy because its characteristic signs often do not occur simultaneously or may be too subtle⁽⁵⁾. In one case report presented with encephalopathy 10 years before hearing loss, with recurrence of encephalopathy 18 years later, another patient experienced multiple BRAO episodes over 30 years, followed with lesions on corpus callosum on MR without signs of encephalopathy^(10,11). It can mimic several others diseases and is frequently misdiagnosed⁽⁶⁾. Multiple sclerosis, migraine, Behcet’s disease, systemic lupus erythematosus, acute and

chronic encephalitis, thromboembolic stroke must be rule out to confirm the diagnosis.

Treatment remains controversial and includes high-dose intravenous corticosteroids, anticoagulants, and immunomodulatory medications⁽¹²⁾.

Although this rare a syndrome, it is probably more common than thought⁽⁶⁾. The early recognition of this syndrome is a very important factor, because the triad has a good prognosis when treated promptly, and therefore permanent cognitive, audiological and visual sequelae may be avoided.

REFERENCES

1. Brandt AU, Zimmermann H, Kaufhold F, Promesberger J, Schipling S, Finis D et al. Patterns of retinal damage facilitate differential diagnosis between Susac’s syndrome and MS. *Plos One*. 2012;7(6):e38741.
2. Aviño JA, España E, Peris-Martínez C, Menezo JL. (Atypical ophthalmic findings in Susac’s syndrome) *Arch Soc Esp Oftalmol*. 2007;82(3):179-81.
3. Do Th, Fisch C, Evoy F. Susac’s syndrome: report of four cases and review of the literature. *AJNR Am J Neuroradiol*. 2004;25 (3):382-8.
4. Sandhya V, Anand N. Susac’s syndrome. *Eye (Lond)*. 2002;16 (6):788-90.
5. Joe SG, Kim JG, Kwon SU, Lee CW, Lim HW, Yoon YH. Recurrent bilateral branch retinal artery occlusion with hearing loss and encephalopathy: the first case report of Susac’s syndrome in Korea. *J Korean Med Sci*. 2011;26(11):1518-21.
6. Milbratz GH, Marquardt FA, Guimarães Neto HP, Marquardt DA, Souza ES. Retinal vasculitis in Susac’s syndrome: case report. *Arq Bras Oftalmol*. 2009;72(3):397-9.
7. Susac JO. Susac’s syndrome. *AJNR Am J Neuroradiol*. 2004;25(3):351-2.
8. Szilasióvá J, Klímová E. Susac’s syndrome: retinocochleocerebral vasculopathy. *Croat Med J*. 2004;45(3):338-43.
9. McLeod DS, Ying HS, McLeod CA, Grebe R, Lubow M, Susac JO et al. Retinal and optic nerve head pathology in Susac’s syndrome. *Ophthalmology*. 2011;118(3):548-52.
10. Rennebohm RM, Egan RA, Susac JO. Treatment of Susac’s syndrome. *Curr Treat Options Neurol*. 2008;10(1):67-74.
11. Murata Y, Inada K, Negi A. Susac’s syndrome. *Am J Ophthalmol*. 2000;129(5):682-4.
12. Aubart-Cohen F, Klein I, Alexandra JF, Bodaghi B, Doan S, Fardeau C, et al. Long-term outcome in Susac’s syndrome. *Medicine (Baltimore)*. 2007;86(2):93-102.

Corresponding author

Ricardo Evangelista Marrocos de Aragão
Rua Osvaldo Cruz, nº 2335 – Bairro Dionísio Torres
Zip Code: 60125-151 – Fortaleza (CE), Brazil
E-mail: ricardomarrocos@yahoo.com