



ELSEVIER



## Original Article

# Reverse arthroplasty of the shoulder for treating rotator cuff arthropathy<sup>☆,☆☆</sup>

Marcus Vinicius Galvão Amaral, José Leonardo Rocha de Faria\*, Gláucio Siqueira, Marcio Cohen, Bruno Brandão, Rickson Moraes, Martim Monteiro, Geraldo Motta

Instituto Nacional de Traumatologia e Ortopedia, Rio de Janeiro, RJ, Brazil

## ARTICLE INFO

## Article history:

Received 17 June 2013

Accepted 21 June 2013

Available online 25 April 2014

## Keywords:

Arthroplasty

Shoulder

Joint diseases

Rotator cuff

Prostheses and implants

## ABSTRACT

**Objective:** to present a retrospective analysis on the clinical-functional results and complications among patients with rotator cuff arthropathy (RCA) who underwent reverse arthroplasty of the shoulder.

**Methods:** patients with a diagnosis of RCA associated with pseudoparalysis of anterior elevation who underwent reverse arthroplasty of the shoulder with a minimum follow-up of one year were selected.

**Results:** preoperative information was gathered from our shoulder and elbow arthroplasty register, comprising age, sex, laterality, history of previous procedures, Constant's functional scores and the preoperative range of motion as described in the protocol of the American Academy of Shoulder and Elbow Surgery (ASES). After a mean follow-up of 44 months, 17 patients (94%) were satisfied with the result from the procedure.

**Conclusion:** reverse arthroplasty for treating RCA in patients with pseudoparalysis of the shoulder was shown to be effective in achieving a statistically significant improvement in range of motion regarding anterior flexion and abduction. However, in this series, there was no improvement in range of motion regarding external and internal rotation. Reverse arthroplasty is a procedure that reestablishes shoulder joint function in patients who previously did not present any therapeutic possibilities.

© 2014 Sociedade Brasileira de Ortopedia e Traumatologia. Published by Elsevier Editora Ltda. All rights reserved.

## Artroplastia reversa do ombro no tratamento da artropatia do manguito rotador

## RESUMO

**Objetivo:** apresentar uma análise retrospectiva dos resultados clínico-funcionais e das complicações dos pacientes com artropatia do manguito rotador (AMR) submetidos à artroplastia reversa do ombro.

## Palavras-chave:

Artroplastia

Ombro

<sup>☆</sup> Please cite this article as: Amaral MVG, de Faria JLR, Siqueira G, Cohen M, Brandao B, Moraes R, et al. Artroplastia reversa do ombro no tratamento da artropatia do manguito rotador. Rev Bras Ortop. 2014;49:279-285.

<sup>☆☆</sup> Work performed at the Shoulder and Elbow Surgery Center, Instituto Nacional de Traumatologia e Ortopedia.

\* Corresponding author.

E-mail: leorochajf@hotmail.com (J.L.R. de Faria).

Artropatias  
Bainha rotadora  
Próteses e implantes

**Métodos:** foram selecionados pacientes com diagnóstico de AMR associada à pseudoparalisia da elevação anterior submetidos à artroplastia reversa do ombro com seguimento mínimo de um ano.

**Resultados:** foram coletadas informações pré-operatórias, por meio do nosso Registro de Artroplastias do Ombro e Cotovelo, que consistiam em idade, sexo, lateralidade, história de procedimentos prévios, escores funcionais de Constant, além da amplitude de movimentos pré-operatórios, conforme protocolo da American Academy of Shoulder and Elbow Surgery (Ases). Com seguimento médio de 44 meses, 17 pacientes (94%) estavam satisfeitos com o resultado do procedimento.

**Conclusão:** a artroplastia reversa no tratamento da AMR em pacientes com pseudoparalisia do ombro demonstrou-se efetiva na melhoria, com significância estatística, da amplitude de movimentos de flexão anterior e abdução. Porém, nesta série não houve melhoria da amplitude dos movimentos de rotação externa e interna. A artroplastia reversa é um procedimento que restabelece a função da articulação do ombro em pacientes que previamente não apresentavam possibilidades terapêuticas.

© 2014 Sociedade Brasileira de Ortopedia e Traumatologia. Publicado por Elsevier Editora Ltda. Todos os direitos reservados.

## Introduction

In 1985, Paul Grammont developed a semiconstricted prosthesis for treating shoulder arthrosis associated with massive injuries to the rotator cuff for which anatomical prostheses were unable to restore the stability and mobility of the joint.<sup>1,2</sup>

The advantage of the design of this reverse prosthesis was based on two biomechanical principles: inferiorization and medialization of the center of rotation of the shoulder joint. These principles favor stretching of the humerus and re-tensioning of the deltoid muscle, which increases its strength and function and also diminishes the mechanical torque at the interface between the glenoid component, the metaglene and the bone surface, which reduces the risk of loosening.<sup>3</sup>

The results from using this type of implant that have been published in the orthopedic literature have concentrated on their use in patients with rotator cuff arthropathy (RCA). Good functional results and pain relief have been presented among patients with short and medium-term follow-up.<sup>3-7</sup> In Brazil, use of reverse prostheses of the shoulder started in 2007 and there are no published papers relating to their clinical results in this country.

The objective of this study was to present a retrospective analysis on the clinical-functional results and complications among patients with RCA who underwent reverse arthroplasty of the shoulder at the Shoulder and Elbow Surgery Center (CCOC), National Institute of Traumatology and Orthopedics (INTO), and presented a minimum follow-up of one year.

## Materials and methods

CCOC-INTO has a register of arthroplasty procedures in which epidemiological and clinical data and information relating to the surgical procedure and implants used are gathered through specific protocols and stored in a database.

After gaining approval from the institution's Research Ethics Committee, we conducted a retrospective analysis in which, from the register, we identified all the patients with a diagnosis of RCA in association with pseudoparalysis of

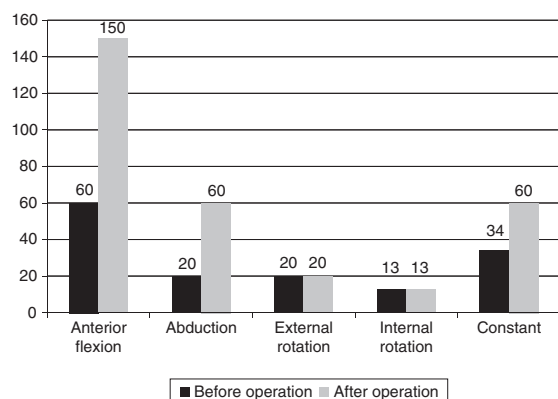
anterior flexion of the shoulder, with a minimum follow-up of one year. Patients who underwent reverse arthroplasty of the shoulder due to other diagnoses, those who did not present the minimum postoperative follow-up, those with arthropathy who did not present pseudoparalysis and those who underwent other types of shoulder arthroplasty were excluded.

The arthroplasty register provided demographic information, data on previous surgical procedures, the preoperative range of motion according to the protocol of the American Shoulder and Elbow Surgeons (ASES), the Constant functional score and information on the surgical procedure performed, the implants used and the immediate complications.

Following this, the patients were recalled for clinical and functional evaluations, in which the Constant scores, shoulder range of motion (ROM) measurements and subjective satisfaction were used. In this clinical evaluation, the incidence of the following complications was also determined: peripheral nerve injuries, periprosthetic fractures, infection and instability.

Next, radiographic images produced in the immediate postoperative period in true anteroposterior view of the shoulder, lateral view of the scapula and axillary view were evaluated. It was sought to determine the positioning of the implant, the fixation of the components and the degree of stretching of the humerus, in comparison with the contralateral side.<sup>8</sup> Recent images were compared in order to verify occurrences of alterations.<sup>9</sup>

From the Shoulder Arthroplasty Register of CCOC-INTO, 43 patients who underwent reverse arthroplasty of the shoulder between September 2007 and January 2011 were identified. Of these, 21 underwent reverse arthroplasty to treat RCA in association with pseudoparalysis. All of them underwent the standardized surgical technique, with deltopectoral surgical access, adequate exposure of the glenoid, preparation of the joint surface with preservation of the subchondral bone, fixation of the metaglene with screws by means of a mixed stabilization system with bone-implant compression and locking of the screws to the implant. On the humeral side, all the implants were positioned neutrally versed, and orthopedic



**Fig. 1 – Mean range of motion and constant functional score before and after the operation.**

cement was used for fixation. In no case was it necessary to use any extensor device for the humeral component.

Among the 21 patients, 18 were evaluated with a mean follow-up of 44 months (range: 12–51). The mean age was 72 years (62–82); 13 patients were female (61%); and injury on the right side predominated (57%). The patients had presented symptoms for a mean of five years, and two had already undergone surgical procedures by means of an arthroscopic technique.

The mean preoperative range of motion was 60° for anterior flexion (20° to 80°), 20° for abduction (10° to 40°), 20° for external rotation (–10° to 60°) and L1 for internal rotation (T8 to S1). The mean preoperative Constant score was 34 points (22 to 50).

#### Analysis on results

The comparative analysis on the range of motion and Constant functional score, from before to after the operation, was done using the Wilcoxon nonparametric test. Satisfaction and the incidence of complications were compared using the chi-square test.

Spearman's rank correlation coefficient was used to define the correlation between the degree of lengthening of the humerus and the range of motion and Constant functional score. The significance level was  $p \leq 0.05$ .

#### Results

With a mean follow-up of 44 months (range: 12–53), 17 patients (94%) were satisfied with the results from the procedure.

In the clinical-functional evaluation, the mean postoperative range of motion was 150° for anterior flexion, 60° for abduction, 20° for external rotation and L3 for internal rotation. There were significant improvements in the anterior flexion and abduction movements ( $p < 0.05$ ), which did not occur with external and internal rotation ( $p > 0.05$ ).

The mean Constant functional score after the operation was 60 points, which represented a statistically significant improvement in shoulder joint function ( $p < 0.050$ ) (Fig. 1).

In the radiographic evaluation, the mean stretching of the humerus was measured as 2.4 cm. There was a positive correlation between the stretching and the improvements in anterior flexion and Constant score, but without statistical significance ( $p > 0.05$ ).

The incidence of a lower notch in the glenoid was 60%, but without any correlation with the functional results.

In our series, the incidence of complications was 22%. There was one case of perioperative fracturing of the anterior border of the glenoid which occurred while the joint surface was being milled; one case of neuropraxia of the radial nerve, with spontaneous recovery after a period of approximately six weeks, after the operation; one case of complex regional syndrome, with slow but complete recovery from the pain symptoms and restoration of joint mobility; and one case of fracturing due to stress on the acromion, 36 months after the operation, which evolved with anterior instability of the prosthesis (Fig. 2A and B).

Below, two clinical cases showing the postoperative clinical-radiographic results from two patients evaluated in this study are illustrated (Figs. 3–6).

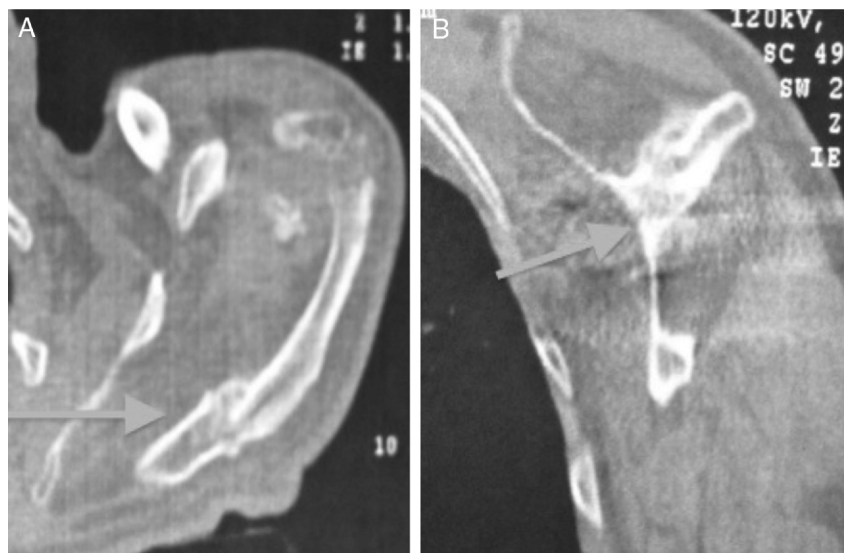
#### Discussion

Reverse arthroplasty of the shoulder has already been shown to be an excellent therapeutic option for patients who present RCA. In our case series, the mean age of the patients who underwent reverse arthroplasty of the shoulder was 72 years. This information is concordant with what was suggested by Mole and Favard,<sup>10</sup> who documented the deterioration of the radiographic results from the reverse prosthesis, eight years after its implantation, and suggested that this procedure should be reserved for patients over the age of 70 years.

The success of reverse arthroplasty of the shoulder reported in published scientific papers has correlated with the type of indication.<sup>5,7,11,12</sup> Greater success rates and lower complication rates have occurred among patients with RCA in association with pseudoparalysis.<sup>5,7</sup> On the other hand, patients with RCA without pseudoparalysis have not presented such encouraging results, possibly because the functional improvement in these patients is not significant, in comparison with the preoperative mobility.<sup>13</sup>

The previous history of procedures performed on the joint with RCA is another variable that may influence the results from reverse arthroplasty, but our sample did not allow this evaluation, since only two of the patients presented this characteristic. Sirveaux et al.<sup>12</sup> suggested that patients with histories of previous surgical procedures in their shoulders did not present any functional differences or differences regarding the risk of complications, but Harreld et al.<sup>13</sup> suggested the opposite.

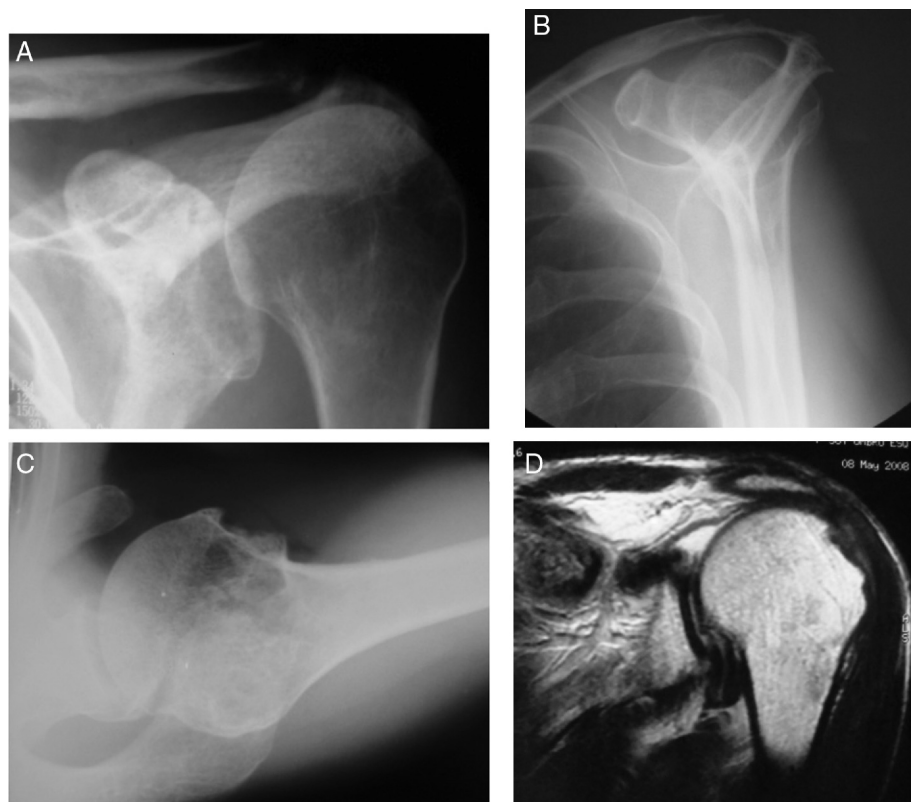
In our series, reverse arthroplasty for treating RCA in patients with pseudoparalysis of the shoulder provided statistically significant increases in range of motion for anterior flexion and abduction. The mean improvement in anterior flexion was 90° ( $p < 0.05$ ) and in abduction, 40° ( $p < 0.05$ ). However, in our series, there was no improvement in the range of motion relating to external and internal rotation movements. The mean external rotation did not present any changes from



**Fig. 2 - (A and B) Stress fracture of the acromion.**

before to after the operation and remained at 20°, while the mean internal rotation worsened from L1 to L3, without statistical significance ( $p > 0.05$ ). These results are concordant with those published in the specialized literature,<sup>11,12,14-16</sup> in which the improvements in anterior flexion and abduction occurred as a consequence of the implant design, which medialized and inferiorized the center of joint rotation, increased the moment of deltoid force and transformed the shearing forces that

existed in the glenoid, into compression forces.<sup>17</sup> Otherwise, reestablishment of active external rotation is biomechanically impossible in reverse arthroplasty through isolated action by the deltoid. Since external rotation is fundamental for activities of daily living, because it enables positioning of the hand in space and gives individuals the capacity to eat and get dressed, it is therefore important that future studies should determine criteria for combining tendon transfer with reverse arthro-



**Fig. 3 - (A-D) Preoperative imaging examinations. Clinical case 1: 72-year-old male patient with RCA reconstruction 36 months earlier.**

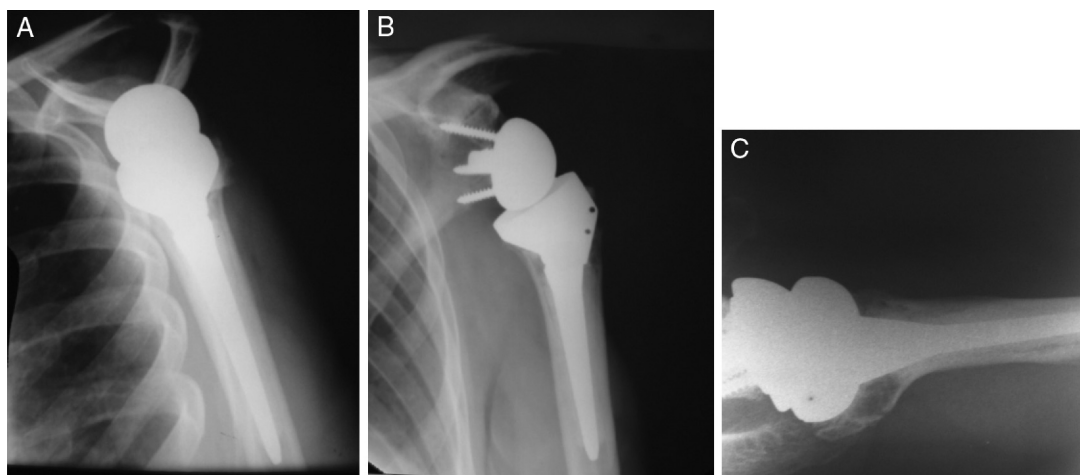


Fig. 4 – (A–C) Postoperative imaging examinations.

plasty, as described by Boileau et al.,<sup>18</sup> which allows recovery of active external rotation.

In this group, there was a notable improvement in the Constant functional score in all the assessment parameters, which was in agreement with the results already published in the specialized literature.<sup>10,11,14,19</sup> The mean Constant score went from 34 points before the operation to 60 after the operation ( $p < 0.005$ ).

This evaluation did not make it possible to measure variables relating to the functional results or to the complications. The following variables have been correlated with better clinical results: use of prosthetic components of greater diameter; absence of retroversion in the humeral component; and absence of fatty infiltration from the teres minor muscle before the operation.<sup>14</sup> In this series, neutral version was always used in the humeral component; although it was not always possible to use large-diameter prosthetic components because of the small height of our patients, particularly the women. No assessments of the status of the teres minor muscle by means of imaging examinations were made on any of the patients of this series; instead, this was done by means of clinical examination, looking for the presence of the

“bugler”.<sup>20</sup> Patients who were positive for this sign and who underwent a procedure combining reverse arthroplasty with lateral transfer of the tendons of the latissimus dorsi and teres minor and major were excluded from the present series and will be the subject of a specific future study.

The biomechanical principle of reverse arthroplasty of the shoulder is based on improving the leverage of the deltoid, through medialization and inferiorization of the center of joint rotation. Therefore, establishing the degree of stretching of the humerus is a fundamental point in prognosing the patients’ functional improvement. This measurement is an appropriate method for defining the tension in the deltoid.<sup>6,8</sup> In the present study, radiographs of the contralateral humerus were used as a comparison parameter for establishing the degree of stretching of the humerus. The mean value obtained was 2.4 cm, and this had a positive correlation with improvement of the anterior flexion and Constant functional score, but without statistical significance ( $p > 0.05$ ). Although this measurement technique has not been validated, it seems to us to be an appropriate and reproducible means of estimating the tension in the deltoid,<sup>8</sup> given that the technique suggested by Ladermann et al.<sup>8</sup> presents limitations similar to ours, i.e.

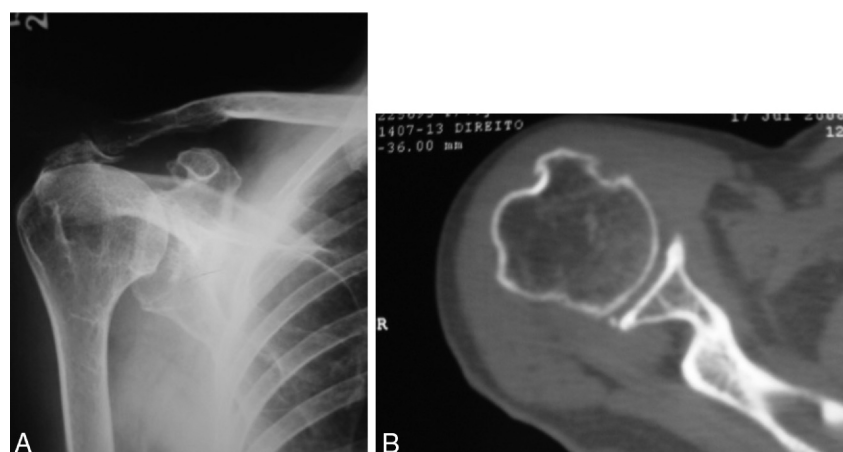
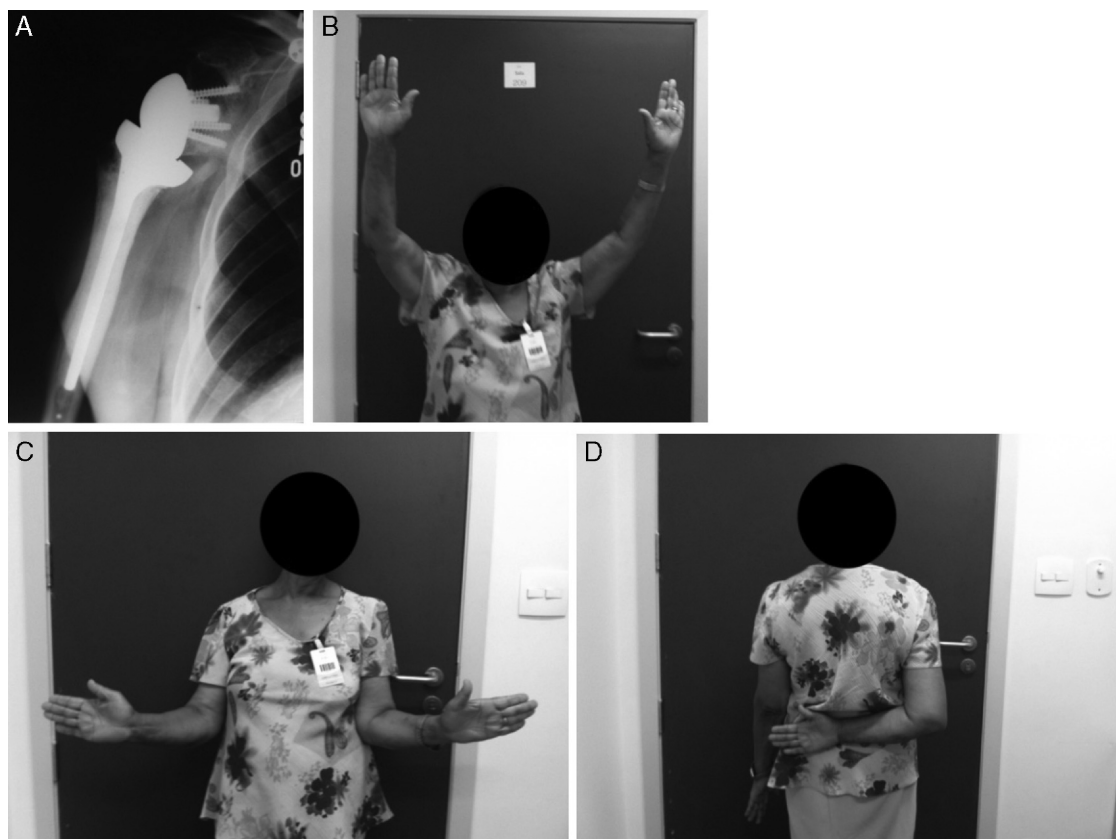

Fig. 5 – (A and B) Preoperative imaging examinations. Clinical case 2: 79-year-old female patient presenting pain and limitations for six years, with pseudoparalysis.



**Fig. 6 – (A-D) Postoperative imaging examination and clinical result.**

quality of the radiographs, projection errors, arm rotation and correct selection of the anatomical parameters.

Our mean humeral stretching was 2.4 cm, and this is in agreement with what has been published in the literature derived from another measurement method, i.e. 2.3 mm ( $\pm 7$  mm). This value represents adequate retensioning of the deltoid muscle and, although our data did not demonstrate statistical significance, there was a positive correlation with functional improvement among the patients.<sup>8</sup> Excessive humeral stretching increases the risk of stress fractures in the acromion and peripheral neurological injury; but quantifying the degree of stretching that correlated with occurrences of peripheral neurological injury is difficult because of the subjectivity of the method and because the numerical range between high and low stretching that might provide sufficient scientific evidence is only measured in millimeters.<sup>8</sup> When neurological injuries occur, they can be attributed to surgical dissection, nerve compression due to major surgical separation, mobilization of the arm or scalene block anesthesia.<sup>8</sup> When appropriate tension in the deltoid is not achieved, there is the risk of prosthetic instability, which needs to be effectively treated with revision of the humeral component.<sup>8</sup>

Despite the excellent published results relating to reverse arthroplasty, the incidences of problems and complications are 44% and 22%, respectively.<sup>3</sup> Problems of intra or postoperative events that commonly do not affect the final result from the procedure are: scapular notches, hematomas, heterotopic ossification, phlebitis and radiolucency lines.<sup>3</sup> Complications

are events that affect the final result from the procedure and they are: periprosthetic fractures, infection, instability, neurological injury, laxity and dissociation of the prosthetic components.<sup>3</sup>

The incidence of scapular notches was 60%, which was similar to what has been published in the literature. This is the most frequent complication following reverse arthroplasty of the shoulder.<sup>3,4,6,9</sup> The impact between the humeral component and the neck of the scapula during arm adduction occurs through medialization of the center of rotation of the reverse prosthesis.<sup>3,9</sup> Scapular notches appear during the first year after the operation and their progression is uncertain.<sup>9</sup> Inferior positioning of the glenoid component and the scapular angle of the prosthesis are important factors in preventing this problem.<sup>15,17,21</sup> There is controversy regarding the clinical significance of the scapular notch; although some studies have suggested that there is a correlation with laxity of the glenoid component,<sup>4,12,18</sup> the most wide-ranging published study on this topic did not present any clinical evidence for this hypothesis.<sup>9</sup> Our sample of 18 patients with a mean follow-up of 44 months did not allow us to make an adequate statistical assessment regarding the survival of the implants and factors relating to their failure.

The incidence of complications was 22%, which is compatible with the results already published.<sup>21</sup> Among the complications that did not influence the patients' functional results, there were two cases of neurological injury (one case of radial neuropraxia and one of complex regional syndrome)

that could be correlated with the degree of humeral stretching. Another complication that did not influence the final result was a case of fracturing of the anterior rim of the glenoid while it was being milled, which prevented placement of an anterior fixation screw for the metaglene. Fracturing of the glenoid rim is rare and relates to aggressive milling of the glenoid or to the patient's bone quality and it may, depending on the characteristics of the fracture, prevent secure fixation of the glenoid component.<sup>14</sup> No cases of infection were observed in this series.

Furthermore, a case of stress fracturing of the acromion was observed 36 months after the operation, in an individual who until that time had presented an excellent functional result. This patient was treated by means of resting the arm in a sling, but the displacement of the fracture gave rise to loss of tension in the deltoid and consequent joint instability. This patient was the only case in which there was dissatisfaction with the results from the procedure. Stress fracturing of the acromion is related to excessive passive tension at the insertion of the deltoid muscle.<sup>14,16</sup> Clinically, it presents with pain after heavy physical activity.<sup>19</sup> It usually occurs at the tip of the acromion, but it can also occur at the base,<sup>19</sup> as in our patient, which causes loss of tension in the deltoid and a consequent risk of instability of the prosthesis.<sup>6,19</sup> Instability is the complication after reverse arthroplasty that is most frequently described.<sup>3</sup> The following are risk factors for instability after reverse arthroplasty: deltopectoral access; alterations to the version of the components of the humerus and glenoid; tearing and fatty infiltration of the subscapularis; and loss of tension in the deltoid.<sup>3</sup> In our patient, instability secondary to fracturing of the acromion, displacement of the fragments and consequent loss of tension in the deltoid were observed.

## Conclusion

Reverse arthroplasty of the shoulder is a procedure that reestablishes shoulder joint function in patients for whom no therapeutic options were previously available. The functional results in patients with RCA in association with pseudoparalysis were excellent in 94% of our patients, which was in agreement with the data in the specialized literature, despite the 22% incidence of complications. Restoration of tension in the deltoid muscle is fundamental to the success of the procedure.

## Conflicts of interest

The authors declare no conflicts of interest.

## REFERENCES

- Grammont PM, Trouilloud P, Laffay JP, Deries X. Etude et réalisation d'une nouvelle prothese d'épaule. *Rhumatologie*. 1987;39(1):17-22.
- Grammont PM, Baulot E. Delta shoulder prosthesis for rotator cuff rupture. *Orthopedics*. 1993;16(1):65-8.
- Zumstein MA, Pinedo M, Old J, Boileau P. Problems, complications, reoperations, and revisions in reverse total shoulder arthroplasty: a systematic review. *J Shoulder Elbow Surg*. 2011;20(1):146-57.
- Bouhassira A, Edwards TB, Walch G, Baratta RV. Early results of a reverse design prosthesis in the treatment of arthritis of the shoulder in elderly patients with a large rotator cuff tear. *Orthopedics*. 2002;25(2):129-33.
- Wall B, Nové-Josserand L, O'Connor DP, Edwards TB, Walch G. Reverse total shoulder arthroplasty: a review of results according to etiology. *J Bone Joint Surg Am*. 2007;89(7):1476-85.
- Boileau P, Watkinson DJ, Hatzidakis AM, Balg F. Grammont reverse prosthesis: design, rationale, and biomechanics. *J Shoulder Elbow Surg*. 2005;14 Suppl. 1:147S-61S.
- Hatzidakis AM, Norris TR, Boileau P. Reverse shoulder arthroplasty. indications, technique, and results. *Tech Shoulder Elbow Surg*. 2005;6(3):135-49.
- Lädermann A, Williams MD, Melis B, Hoffmeyer P, Walch G. Objective evaluation of lengthening in reverse shoulder arthroplasty. *J Shoulder Elbow Surg*. 2009;18(4):588-95.
- Lévigne C, Boileau P, Favard L, Garaud P, Molé D, Sirveaux F, et al. Scapular notching in reverse shoulder arthroplasty. *J Shoulder Elbow Surg*. 2008;17(6):925-35.
- Molé D, Favard L. Excentered scapulohumeral osteoarthritis. *Rev Chir Orthop Reparatrice Appar Mot*. 2007;93 Suppl. 6:37-94.
- Guery J, Favard L, Sirveaux F, Oudet D, Mole D, Walch G. Reverse total shoulder arthroplasty. Survivorship analysis of eighty replacements followed for five to ten years. *J Bone Joint Surg Am*. 2006;88(8):1742-7.
- Sirveaux F, Favard L, Oudet D, Huquet D, Walch G, Molé D. Grammont inverted total shoulder arthroplasty in the treatment of glenohumeral osteoarthritis with massive rupture of the cuff. Results of a multicentre study of 80 shoulders. *J Bone Joint Surg Br*. 2004;86(3):388-95.
- Harrell KL, Puskas BL, Frankle M. Massive rotator cuff tears without arthropathy: when to consider reverse shoulder arthroplasty. *J Bone Joint Surg Am*. 2011;93(10):973-84.
- Gerber C, Pennington SD, Nyffeler RW. Reverse total shoulder arthroplasty. *J Am Acad Orthop Surg*. 2009;17(5):284-95.
- Werner CM, Steinmann PA, Gilbert M, Gerber C. Treatment of painful pseudoparesis due to irreparable rotator cuff dysfunction with the Delta III reverse-ball-and-socket total shoulder prosthesis. *J Bone Joint Surg Am*. 2005;87(7):1476-86.
- Matsen 3rd FA, Boileau P, Walch G, Gerber C, Bicknell RT. The reverse total shoulder arthroplasty. *J Bone Joint Surg Am*. 2007;89(3):660-7.
- Simovitch RW, Helmy N, Zumstein MA, Gerber C. Impact of fatty infiltration of the teres minor muscle on the outcome of reverse total shoulder arthroplasty. *J Bone Joint Surg Am*. 2007;89(5):934-9.
- Boileau P, Chuinard C, Roussanne Y, Bicknell RT, Rochet N, Trojani C. Reverse shoulder arthroplasty combined with a modified latissimus dorsi and teres major tendon transfer for shoulder pseudoparalysis associated with dropping arm. *Clin Orthop Relat Res*. 2008;466(3):584-93.
- Frankle M, Siegal S, Pupello D, Saleem A, Mighell M, Vasey M. The reverse shoulder prosthesis for glenohumeral arthritis associated with severe rotator cuff deficiency. A minimum two-year follow-up study of sixty patients. *J Bone Joint Surg Am*. 2005;87(8):1697-705.
- Walch G, Bouhassira A, Calderone S, Robinson AH. The "dropping" and "hornblower's" signs in evaluation of rotator-cuff tears. *J Bone Joint Surg Br*. 1998;80(4):624-8.
- Simovitch RW, Zumstein MA, Lohri E, Helmy N, Gerber C. Predictors of scapular notching in patients managed with the Delta III reverse total shoulder replacement. *J Bone Joint Surg Am*. 2007;89(3):588-600.