



Original Article

Clinical repercussions of Martin-Gruber anastomosis: anatomical study[☆]



Cristina Schmitt Cavalheiro^{a,*}, Mauro Razuk Filho^a, Gabriel Pedro^a,
Maurício Ferreira Caetano^b, Luiz Angelo Vieira^a, Edie Benedito Caetano^a

^a School of Medical and Health Sciences, Pontifícia Universidade Católica de São Paulo, Sorocaba, SP, Brazil

^b Hand Surgery Service, Conjunto Hospitalar de Sorocaba, Sorocaba, SP, Brazil

ARTICLE INFO

Article history:

Received 4 May 2015

Accepted 11 June 2015

Available online 23 February 2016

Keywords:

Arteriovenous
anastomosis/anatomy & histology
Median nerve
Ulnar nerve

ABSTRACT

Objective: The main objective of this study was to describe Martin-Gruber anastomosis anatomically and to recognize its clinical repercussions.

Method: 100 forearms of 50 adult cadavers were dissected in an anatomy laboratory. The dissection was performed by means of a midline incision along the entire forearm and the lower third of the upper arm. Two flaps including skin and subcutaneous tissue were folded back on the radial and ulnar sides, respectively.

Results: Nerve communication between the median and ulnar nerves in the forearm (Martin-Gruber anastomosis) was found in 27 forearms. The anastomosis was classified into six types: type I: anastomosis between the anterior interosseous nerve and the ulnar nerve (n=9); type II: anastomosis between the anterior interosseous nerve and the ulnar nerve at two points (double anastomosis) (n=2); type III: anastomosis between the median nerve and the ulnar nerve (n=4); type IV: anastomosis between branches of the median nerve and ulnar nerve heading toward the flexor digitorum profundus muscle of the fingers; these fascicles form a loop with distal convexity (n=5); type V: intramuscular anastomosis (n=5); and type VI: anastomosis between a branch of the median nerve to the flexor digitorum superficialis muscle and the ulnar nerve (n=2).

Conclusion: Knowledge of the anatomical variations relating to the innervation of the hand has great importance, especially with regard to physical examination, diagnosis, prognosis and surgical treatment. If these variations are not given due regard, errors and other consequences will be inevitable.

© 2016 Sociedade Brasileira de Ortopedia e Traumatologia. Published by Elsevier Editora Ltda. All rights reserved.

[☆] Work developed in the Department of Surgery, School of Medical and Health Sciences, Sorocaba Campus, Pontifícia Universidade Católica de São Paulo, Sorocaba, SP, Brazil.

* Corresponding author.

E-mail: cristina.schmitt@hotmail.com (C.S. Cavalheiro).

<http://dx.doi.org/10.1016/j.rboe.2016.02.003>

2255-4971/© 2016 Sociedade Brasileira de Ortopedia e Traumatologia. Published by Elsevier Editora Ltda. All rights reserved.

Repercussões clínicas da anastomose de Martin-Gruber: estudo anatômico

R E S U M O

Palavras-chave:

Anastomose
arteriovenosa/anatomia e
histologia
Nervo mediano
Nervo ulnar

Objetivos: Descrever anatomicamente a anastomose de Martin-Gruber e reconhecer suas repercussões clínicas.

Método: Foram dissecados 100 antebraços de 50 cadáveres adultos no laboratório de anatomia. A dissecação foi feita através uma incisão mediana em todo o antebraço e terço inferior do braço, dois retalhos incluindo a pele e subcutâneo foram rebatidos, para o lado radial e ulnar respectivamente.

Resultados: A comunicação nervosa entre os nervos medianos e ulnar no antebraço (anastomose de Martin-Gruber) foi registrada em 27 antebraços. Classificamos a anastomose em seis tipos. Tipo I: anastomose entre o nervo interósseo anterior e o nervo ulnar (nove membros); Tipo II: anastomose entre o nervo interósseo anterior e o nervo ulnar em dois pontos (dupla anastomose - dois membros); Tipo III: anastomose entre o mediano e o nervo ulnar (quatro membros); Tipo IV: anastomose entre ramos dos nervos mediano e ulnar destinada ao músculo flexor profundo os dedos, esses fascículos formam uma alça de convexidade distal (cinco membros); Tipo V: anastomose intramuscular (cinco membros); Tipo VI: anastomose entre ramo do nervo mediano para o músculo flexor superficial e nervo ulnar (dois membros).

Conclusão: O conhecimento das variações anatômicas em relação à inervação da mão tem importância relevante, principalmente quando se considera o exame físico, diagnóstico, prognóstico e tratamento cirúrgico. Se essas variações não forem valorizadas, erros e consequências serão inevitáveis.

© 2016 Sociedade Brasileira de Ortopedia e Traumatologia. Publicado por Elsevier Editora Ltda. Todos os direitos reservados.

Introduction

The anatomy of the upper limbs is extremely complex. In addition to the complexity of the format of the brachial plexus and the existence of strategic anatomical zones such as the epitrochlear-olecranon groove (ulnar canal), carpal canal and Guyon canal, anomalous nerve branches can be found. These may form anastomoses in particular sites that have clinical and functional importance.

The innervation pattern that is most accepted in relation to the intrinsic muscles that act in relation to fine movements of the hand is that the opposing short abductor muscle, the superficial portion of the short flexor muscle and the first and second lumbrical muscles receive innervation from the median nerve. The deep portion of the short flexor muscle, the adductor muscle of the thumb, the muscles of the hypothenar region, the dorsal and palmar interosseous muscles and the fourth and fifth lumbrical muscles are innervated by the ulnar nerve. The great variety of clinical conditions observed in cases of isolated lesions of the median or ulnar nerve led us to investigate this.

Clinically, variations of the innervation of these small muscles are very important, in that even if the median or ulnar nerve is completely torn, some of these muscles may not necessarily be paralyzed. This could lead to the wrong conclusion that the nerve had not become completely torn.

The studies that we consulted showed many divergences, and these became more marked when the authors

used different investigative methods. The methods used included electroneuromyography, selective anesthetic blockage of nerves and anatomical dissection. Clinical reports and electroneuromyographic studies have suggested that these muscles may receive double innervation from the median and ulnar nerves. Highet¹ analyzed 45 patients with completely torn median or ulnar nerves and found that the short flexor muscle of the thumb was totally paralyzed in only five of them. Forrest² drew attention to this and stated that communication between the median and ulnar nerves in the hand might be more frequent than is imagined and that the muscles located close to this communication (nerve anastomosis) might be receiving innervation from both nerves (double innervation).

Reports on clinical cases have often suggested that double innervation of these muscles exists. Nerve communication (anatomical variations) between the median and ulnar nerves may occur in the forearm (Martin-Gruber anastomosis), between the thenar motor branch of the median nerve and the deep motor branch of the ulnar nerve in the palm of the hand (Cannieu and Riché anastomosis) or between the sensory branches of the two nerves, also in the palm of the hand (Berretini anastomosis or superficial sensory communicating branch). Thus, the variety of clinical conditions observed in cases of isolated lesions of the median and ulnar nerves is discordant with the classical innervation pattern of these muscles that is suggested by treatises on anatomy. Better knowledge of the anatomical variations in the innervation of these muscles is important with regard to diagnosing nerve injuries.

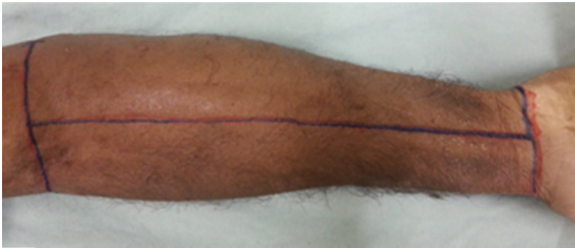


Fig. 1 – Median incision in the volar face along the entire forearm.

Nerve communication between the median and ulnar nerves in the forearm, which is known as Martin-Gruber anastomosis, causes transfer of nerve fascicles from the median nerve to the ulnar nerve. This gives rise to alteration of the normal anatomical pattern of the motor and sensory innervation of the hand. It was first described by Martin,³ who considered the possibility of communication between these nerves in the forearm. Around 100 years later, in 1870, Gruber⁴ dissected 250 forearms and found communication between these two nerves in 38 of them.

It has been demonstrated in the literature that the incidence of this nerve communication varies when different investigative methods are compared, i.e. according to whether electroneuromyography, selective anesthetic blockage of nerves or anatomical dissection is used. According to Sunderland,⁵ several factors cause difficulty in evaluating the motor function of the hand. The most important of these are anatomical variations or failure to evaluate the role of deceptive movements, given that these may imitate and cover up for loss of the original movements. If these factors are not properly valued, errors in making diagnoses and assessing the results will be inevitable.

Methods

Dissections were performed on 100 forearms of 50 adult cadavers belonging to our Anatomy Laboratory, among which 46 were male and four were female. Their ages ranged from 28 to 77 years; 27 were white and 23 were nonwhite. Forearms that had been deformed through injury, malformation or scarring were excluded.

The dissection was performed by means of a median incision along the entire forearm and the lower third of the upper arm. Two flaps that included the skin and subcutaneous tissue were pulled back toward the radial and ulnar sides, respectively. The same was done in relation to the fascia of the forearm, and thus the entire musculature was exposed (Figs. 1 and 2).

All of the muscles of the forearm were dissected. Their innervation and the presence of nerve communication between the forearm nerves were analyzed. All the anatomical variations encountered were recorded, annotated and photographed. A Keeler magnifying glass of 2.5× was used. A 1 cm segment of the anastomotic ramus was removed and taken to a surgical microscope. With the aid of microsurgical tweezers, the fascicles were separated, counted and photographed.

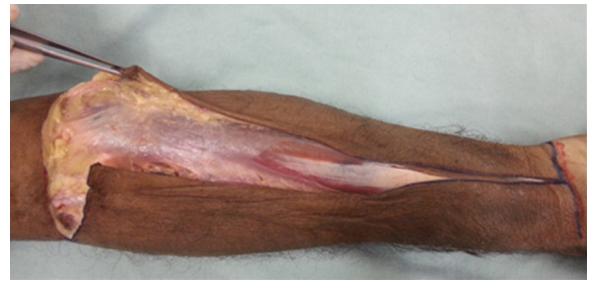


Fig. 2 – Two flaps that included the skin and subcutaneous tissue were pulled back to expose the fascia and then the musculature of the forearm.

In four limbs, we recorded only one fascicle; in eight, two; in nine, three; in four, four; in one, five; and in one, seven.

In addition to investigating Martin-Gruber nerve communication, the relationship between the Gantzer muscle and the anterior interosseous and median nerves and the anatomical variations of the forearm muscles were analyzed. This study was approved by the Research Ethics Committee.

Results

We recorded the presence of Martin-Gruber anastomosis in 27 of the 100 forearms dissected. Bilaterality was observed in three cadavers. In 13 cases, nerve communication occurred in the left forearm and in 14 cases in the right forearm. Regarding the topographic location, most of the nerve communications occurred in the proximal third of the forearm.

In the most frequently encountered form of communication, which was seen in nine forearms, the nerve fascicles originated from the anterior interosseous nerve, at a variety of sites, and headed distally at widely varying degrees of obliquity. They were located posteriorly to the ulnar artery and were supported on the deep flexors of the fingers, anteriorly to them. They headed toward the ulnar nerve and joined to it close to the junction between the proximal third and middle third of the forearm. In all of these cases, the fascicles originated distally to the elbow joint. We considered this to be type I (Fig. 3).

Type II was recorded in two limbs. The nerve fascicles originated from the anterior interosseous nerve, just like in type I, with bifurcation of the fascicles, which communicated with the ulnar nerve at two different points (Fig. 4).

Type III, which was recorded in four anatomical specimens, differed from type I only in that it originated from the median nerve, close to the emergence of the anterior interosseous nerve. It had the same path as the preceding type, with variable obliquity. In three of these four cases, the origin of the nerve communication was proximal to the elbow joint (Fig. 5).

In type IV, which was recorded in five forearms, the communication occurred between the nerve fascicles that originated from the median and ulnar nerve branches and headed toward the deep flexor muscle of the fingers. These fascicles formed a loop with distal convexity. The fascicles of this communication headed toward the muscle mass of the deep flexors of the fingers (Fig. 6).

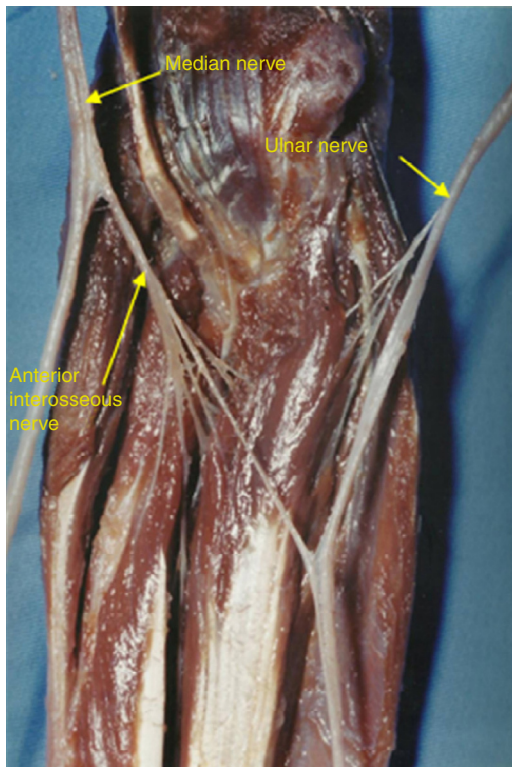


Fig. 3 – Type I. This was the most frequent form of communication (seen in nine limbs). The nerve fascicles originated from the anterior interosseous nerve and headed toward the ulnar nerve.

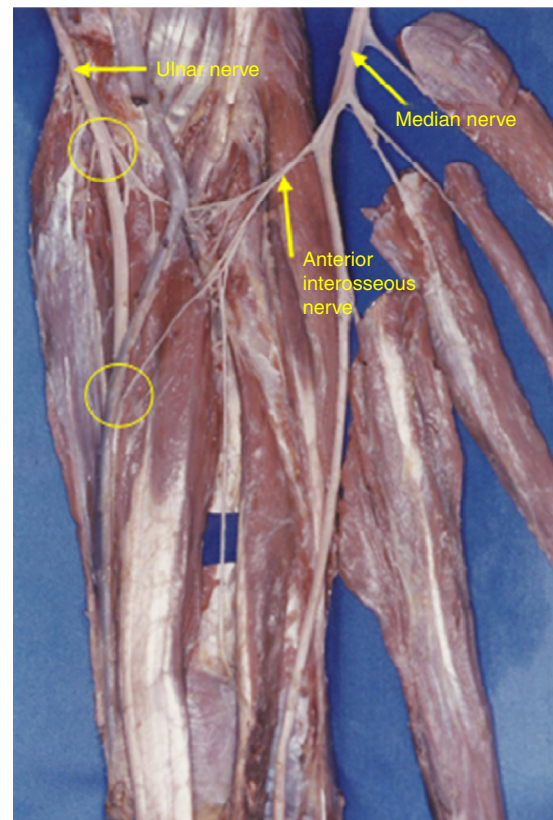


Fig. 4 – In type II, which was recorded in two limbs, the nerve fascicles originated from the anterior interosseous nerve, with bifurcation, and communicated with the ulnar limb at two different points.

Type V, which was also observed in five forearms, differed from the preceding type in that the communication between the fascicles coming from the median and ulnar nerves occurred inside the muscle mass of the deep flexors of the fingers. This was called intramuscular Martin-Gruber communication (Fig. 7).

In type VI, which was recorded in two forearms, the fascicles originated from the branch of the median nerve toward the superficial flexor muscle and headed obliquely and distally to communicate with the ulnar nerve (Fig. 8).

Segments of the anastomotic ramus of length 0.5–1.0 cm were removed. The number of fascicles was counted under a surgical microscope, at magnifications ranging from 10 to 16 \times . With the aid of microsurgical tweezers, the fascicles of the anastomotic ramus were separated. In four limbs, we recorded only one fascicle; in eight, two; in nine, three; in four, four; in one, five; and in one, seven (Fig. 9).

Discussion

The incidence of nerve communication between the median and ulnar nerves in the forearm is variable and this becomes more marked when the results obtained through electroneuromyographic studies are compared with those from anatomical dissections. Table 1 shows the authors, the nature of the study, the number of cases and the percentage of nerve communication.

To the best of our knowledge, no anatomical studies regarding the innervation of the opposing muscle of the thumb through the ulnar nerve have been conducted. However, through electromyographic studies, it was recorded by Sala⁶ in 32% of the cases, by Forrest² in 20%, by Harness and Sequeles⁷ in 77%, by Highet¹ in 20% and by Rosen⁸ in 16.7%. In comparing the studies of Sala⁶ and Forrest,² in which exactly the same technique was used yet completely different results were achieved (Sala⁶ 77% and Forrest² 20%), it can be seen that in the opinion of Forrest,² this occurred because the authors placed electrodes at different depths and because Sala⁶ placed electrodes in contact with the muscle fibers of the short flexor muscle, thereby obtaining a higher percentage. This difference demonstrates that studies conducted through electrical stimulation are not as precise as those conducted through anatomical dissection.

Thompson⁹ was the first to describe a classification for Martin-Gruber anastomosis. Hirasawa¹⁰ was the first to report intramuscular Martin-Gruber anastomosis. Kimura et al.,¹¹ Srinivasan and Rhodes,¹² Ucida and Sugioka,¹³ Nakashima,¹⁴ Oh,¹⁵ Shu et al.,¹⁶ Rodriguez-Niedenfuhr et al.¹⁷ and Lee et al.¹⁸ also described classifications for this nerve anastomosis (Table 2). These classifications show many more differences than similarities between each other, which makes comparisons difficult. Thompson⁹ reported that in two of the 406 specimens dissected, the anastomotic ramus originated from

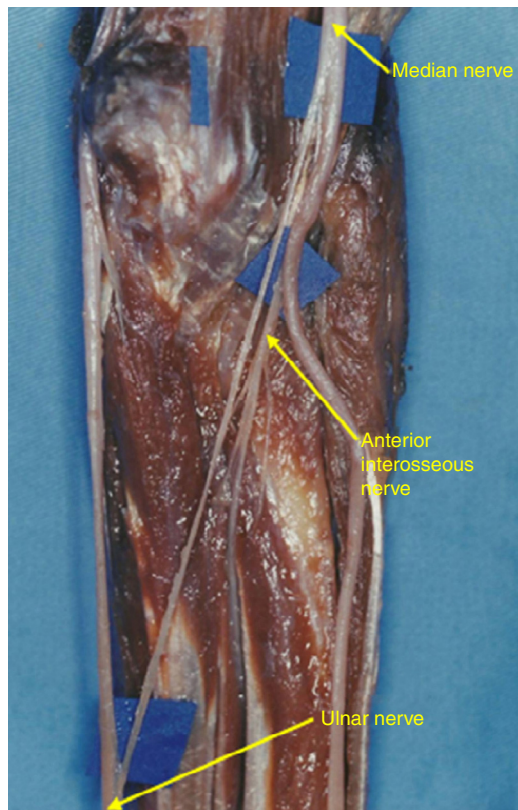


Fig. 5 – In type III, which was recorded in four limbs, the fascicles originated from the median nerve, proximal to the emergence of the anterior interosseous nerve, and headed toward the ulnar nerve.

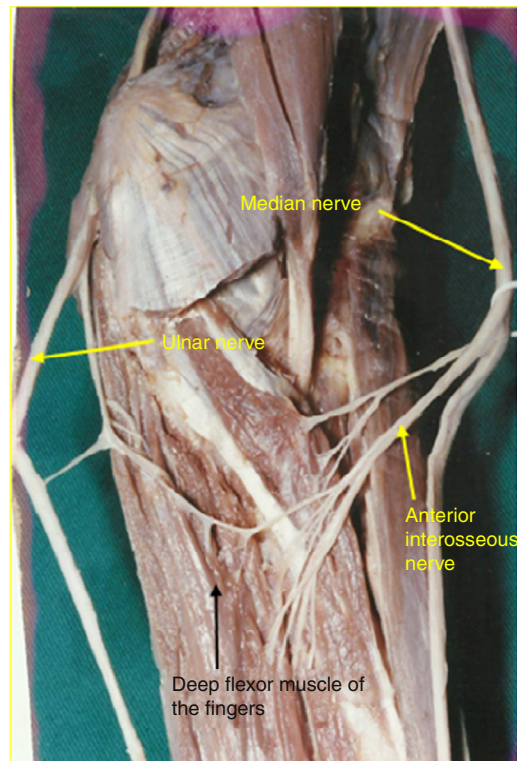


Fig. 6 – In group IV, which was recorded in five limbs, communication occurred between nerve fascicles that were heading for the deep flexor muscle of the fingers, and the fascicles formed a loop with distal convexity.

the median nerve close to the ulnar nerve, in the distal third of the forearm. This anatomical format has so far not been recorded in the literature. It is probably an extremely rare anatomical variation, or a variation of group II of our findings,

in which union with the ulnar nerve would occur in the distal third of the forearm.

The classification drawn up by Srinivasan and Rhodes¹² is the one that comes closest to our observations. We disagree with it only in relation to two points. These authors considered type I to be communications that originated in the proximal portion of the anterior interosseous nerve and group

Table 1 – Summary of the literature involving the incidence of anastomosis between the median and ulnar nerves (Martin-Gruber anastomosis), according to author.

Year	Authors	Study	Cases studied	Cases that presented Martin-Gruber anastomosis (%)
1870	Gruber ⁴	Anatomical	250	15.2
1893	Thomson ⁹	Anatomical	406	15.5
1931	Hirasawa ¹⁰	Anatomical	No data	10.5
1976	Kimura et al. ¹¹	Electrophysiological	328	17
1981	Srinivasan and Rhodes ¹²	Anatomical, genetic	200	15
1992	Uchida and Sugioka ¹³	Electrophysiological	47 (cubital syndrome) 87 (normal)	17 16
1992	Amoiridis ²⁶	Electrophysiological	100	32
1993	Nakashima ¹⁴	Anatomical	108	21.3
1999	Shu et al. ¹⁶	Anatomical, histological	72	23.6
2002	Rodriguez-Niedenfuhr et al. ¹⁷	Anatomical	140 236	13.6 13.1
2005	Lee et al. ¹⁸	Anatomical, electrophysiological	102 (anatomical) 224 (electrophysiological)	39.2 23.2
2015	Our results	Anatomical	100	27

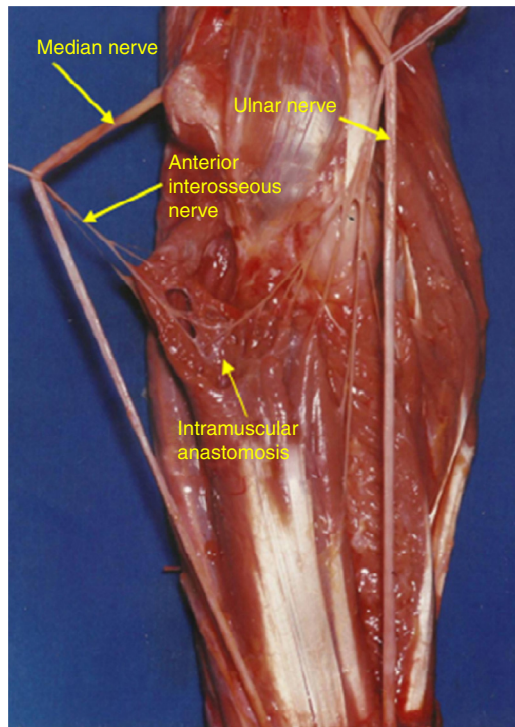


Fig. 7 – In type V, which was recorded in five limbs, nerve communication occurred inside the muscle mass of the deep flexors of the fingers (intramuscular anastomosis).

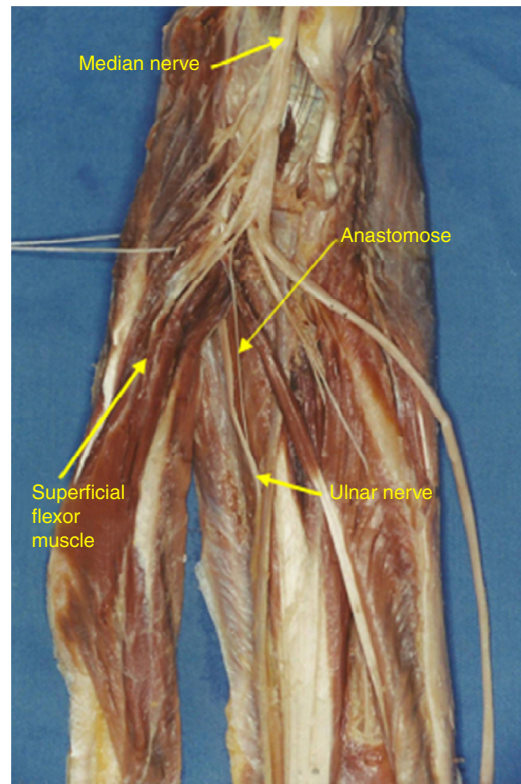


Fig. 8 – In type VI, which was recorded in two limbs, fascicles coming from the branch of the median nerve to the superficial flexor muscle headed toward communication with the ulnar nerve.

II to be those originating in the distal portion of this nerve. We observed that nerve communication could originate at different levels of the anterior interosseous nerve, but we did not see any reason to consider them to be different groups, since they originated in the same nerve and had the same format. The other point of disagreement is that these authors did not describe any occurrence of intramuscular anastomosis.

It is still not possible to identify the origin and destination of each nerve fascicle, either by electrophysiological or by anatomical means. Anatomical studies are based on the apparent path the fascicles are following, from one nerve to another. In agreement with the majority of authors,^{4,5,9,10,12,14-17} we can affirm that we did not observe any passage of motor fascicles from the ulnar nerve to the median nerve, in any of the limbs. We recorded that the communications were directed from the median nerve to the ulnar. However, nerves are composed of motor fascicles (efferent) and sensory fascicles (afferent). It is therefore possible that sensory fascicles (afferent) are directed from the ulnar to the median nerve. In group III, it is likely that in communications originating in the median nerve (which is a mixed nerve), there are both efferent (motor) and afferent (sensory) fascicles. In the other limbs, communication was by means of a motor nerve: anterior interosseous in types I, II, IV or V; or by means of a branch of the median nerve to the superficial flexor muscle in type VI. In this situation, it is unlikely that sensory fascicles will exist.

Shafic et al.¹⁹ reported the case of a patient who presented all of the symptoms of carpal tunnel syndrome, but had negative results from provocative tests such as Tinel's sign and

Phalen's test. This patient presented evident signs of ulnar nerve compression in the elbow. Nerve stimulation in the epitrochlear-olecranon groove triggered the typical symptoms of carpal tunnel syndrome, which demonstrated that transfer of sensory nerve fascicles (afferent) from the ulnar nerve to the median nerve existed.

Marinacci²⁰ described the case of a patient who suffered traumatic sectioning of the median nerve in the proximal forearm. An electromyographic evaluation showed denervation of the long flexor muscles of the thumb and the deep flexor of the index and middle fingers, which are usually innervated by the median nerve. However, the hand did not present motor alterations seen either clinically or electromyographically. From applying electromyographic stimuli and from the velocity of motor conduction of the median nerves in the wrist and elbow, it was concluded that this alteration occurred as a consequence of passage of nerve fibers from the ulnar nerve to the median nerve in the forearm, distally to the innervation of the long flexor of the thumb and the deep flexor of the index and middle fingers. The author named this type of innervation of all of the intrinsic muscles by the ulnar nerve "total ulnar hand". Among our results, we recorded one limb with five and another with seven fascicles, but we cannot affirm that these fascicles would be sufficient to innervate all of the intrinsic muscles of the hand.

Using electrophysiological methods, Clifton²¹ described a case in which all of the intrinsic muscles of the hand

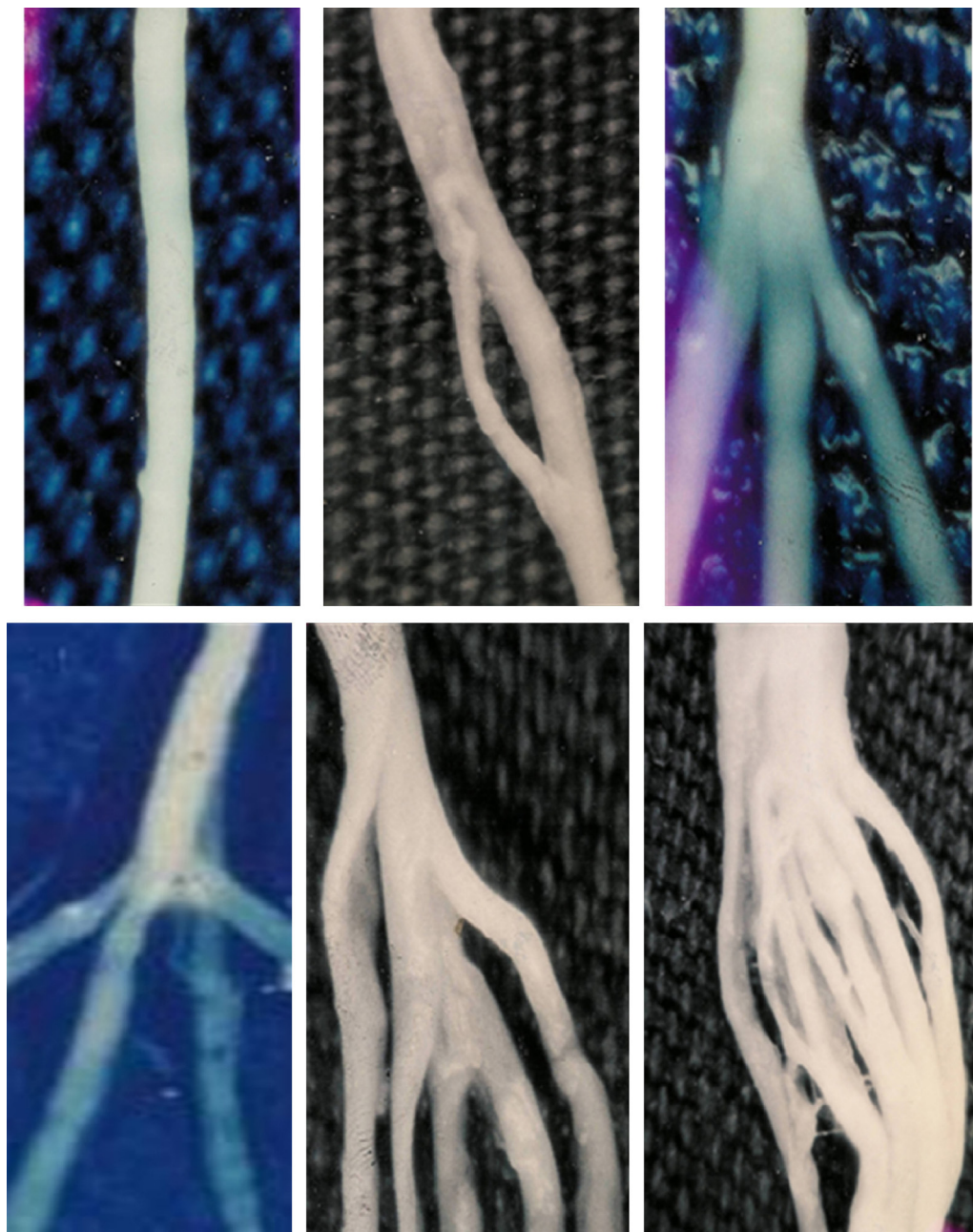


Fig. 9 – Distribution of the number of fascicles in the 27 records of Martin-Gruber anastomosis. In four limbs, we only recorded one fascicle; in eight, two; in nine, three; in four, four; in one, five; and in one, seven.

were found to be innervated and sensitivity was preserved, despite complete rupture of the ulnar nerve. This author also described another case in which there was complete rupture of the median nerve and all the intrinsic muscles were found to be functioning, despite the absence of sensitivity in the area of innervation of the median nerve. In the first situation, all the intrinsic muscles received innervation from the median nerve and in the second, from the ulnar nerve. These variations were attributed to Martin-Gruber anastomosis. Based on our studies,²² it is more likely that these variations occurred because of Cannieu-Riché anastomosis (communication from motor branches of the median nerve to the muscles of the

thenar region and the deep branch of the ulnar nerve, in the palm of the hand), because this communication is three times more frequent than Martin-Gruber anastomosis.

Some reports in the literature have differentiated three types of Martin-Gruber communication.²³ In types I and II, anomalous innervation of the abductor muscles of the little finger and the first dorsal interosseous muscle, respectively, are observed. In type III, there is anomalous innervation of the short abductor of the thumb. In types I and II, nerve fascicles head from the median to the ulnar nerve, while in type III they head from the ulnar to the median. Our view is that in these cases, the communication may have occurred either in the

Table 2 – Summary of the literature involving different classifications for anastomosis between the median and ulnar nerves.

Year	Authors	Classification proposed; anastomosis between the median and ulnar nerves
1893	Thomson ⁹	Class I: anterior interosseous nerve and ulnar nerve Class II: median nerve and ulnar nerve Class III: muscle branch to deep flexor muscle of the fingers
1931	Hirasawa ¹⁰	Oblique anastomosis: anterior interosseous nerve and ulnar nerve median nerve and ulnar nerve Loop anastomosis: muscle branch to deep flexor muscle of the fingers Combined anastomosis: combinations between others
1976	Kimura et al. ¹¹	Type I: median nerve and ulnar nerve innervating the hypothenar muscle Type II: median nerve and ulnar nerve innervating the deep flexor muscle of the fingers Type III: median nerve and ulnar nerve innervating the thenar muscle
1981	Srinivasan and Rhodes ¹²	Types I, II, VI: anterior interosseous nerve and ulnar nerve or other Type III: median nerve and ulnar nerve Types IV, V: combinations of others
1992	Uchida and Sugioka ¹³	Type I: median nerve and ulnar nerve innervating the hypothenar muscle Type II: median nerve and ulnar nerve innervating the thenar muscle Type III: median nerve and ulnar nerve innervating the deep flexor muscle of the fingers
1993	Nakashima ¹⁴	Type Ia: anterior interosseous nerve and ulnar nerve Type Ib: median nerve and ulnar nerve Type III: combination of types Ia, Ib and II
1995	Oh et al. ¹⁵	Type I: median nerve and ulnar nerve innervating the hypothenar muscle Type II: median nerve and ulnar nerve innervating the deep flexor muscle of the fingers Type III: median nerve and ulnar nerve innervating the thenar muscle
1999	Shu et al. ¹⁶	Type I: anterior interosseous nerve and ulnar nerve Type II: median nerve and ulnar nerve Type III: muscle branch to deep flexor muscle of the fingers Type IV: anterior interosseous nerve and ulnar nerve, muscle branch to deep flexor muscle of the fingers originating from the connection Type V: two anastomotic branches
2002	Rodriguez-Niedenfuhr et al. ¹⁷	Pattern I: one anastomotic ramus Pattern II: two anastomotic rami Type A: anastomotic ramus originating from a branch of the median nerve to the nerve of the superficial flexor muscle of the forearm Type B: anastomotic ramus originating from the median nerve Type C: anastomotic ramus originating from the anterior interosseous nerve
2005	Lee et al. ¹⁸	Type I: anterior interosseous nerve and ulnar nerve Type II: median nerve and ulnar nerve Type III: muscle branch to deep flexor muscle of the fingers Type IV: two anastomotic rami from the ulnar nerve or anterior interosseous nerve and ulnar nerve
2015	Our classification	Type I: anterior interosseous nerve and ulnar nerve Type II: anterior interosseous nerve and ulnar nerve (double anastomosis) Type III: median nerve and ulnar nerve Type IV: loop between anterior interosseous nerve and ulnar nerve with branches to deep flexor muscle of the fingers Type V: intramuscular anastomosis Type VI: branch from the median nerve to the superficial flexor muscle and ulnar nerve

forearm or in the palm of the hand. It is more likely that this was Cannieu-Riché anastomosis, because this is three times more frequent than Martin-Gruber anastomosis.

Brandsma et al.²⁴ described two clinical cases of patients with complete rupture of the ulnar nerve in the elbow and injury to the median nerve in the wrist, secondary to neuropathy due to leprosy, which maintained good functioning of the first dorsal interosseous muscles and the short flexor of the thumb. They attributed these findings to the presence of Martin-Gruber anastomosis. Our results contribute support to

this clinical observation that this occurrence could only have been due to Martin-Gruber anastomosis.

Rosen and Lundborg²⁵ examined 96 upper limbs of 48 patients. They found variations in the intrinsic muscles in 21% of the limbs: 75% in the hand and 25% in the forearm. They tested the electrical activity of the opposing muscles of the thumb and abductor of the little finger through stimulation of the ulnar and median nerves in the wrist and elbow. They concluded that in 11 patients there was transfer of nerve fibers from the ulnar to the median nerve. They did

not record any nerve communication from the median to the ulnar nerve. These results are surprising, because they completely disagree with those in the literature, considering that they show ulnar–median anastomosis as being more frequent than median–ulnar.

Amoiridis²⁶ reported being surprised about the results published by Golovchinsky,²⁷ who found that nerve communication from the ulnar nerve to the median nerve was present in 16.7%. This author stated that Golovchinsky²⁷ had not taken into consideration some basic principles of electrophysiological studies and that this was why the percentage of this type of nerve communication was so high. In addition, this author stated that Golovchinsky²⁷ had not taken into consideration that a response from the elbow to the wrist diminished by up to 15% could be found even in normal individuals.

Komar et al.²⁸ reported the case of a patient with complete rupture of the median nerve above the elbow, with a condition of incomplete paralysis of the median nerve in the hand and loss of sensitivity in the area of sensory innervation by the median nerve. They reported that their electromyographic evaluation suggested that nerve fiber transfer from the ulnar nerve to the median nerve in the forearm was present. Amoiridis stated that this case described by Komar was not one of nerve communication in the forearm, since stimulation in the wrist did not show a response from the muscles in the thenar region. We agree with Amoiridis, since it is likely that transfer of fascicles from the ulnar to the median nerve occurred distally to the wrist (Cannieu-Riché anastomosis).

Streib²⁹ reported the case of a 77-year-old patient with a complaint of weakness in the hands. Electrical stimulation demonstrated that the response of the musculature of the thenar region had an amplitude greater than 50% when the median nerve was stimulated in the wrist, in relation to the elbow. The opposite occurred in relation to the ulnar nerve, i.e. the amplitude was 50% greater in the elbow. There is no doubt that in this case, nerve communication occurred in the forearm (Martin-Gruber anastomosis).

Dogan et al.³⁰ described the case of a patient with a condition of compressive neuropathy of the ulnar nerve who presented altered sensitivity in the ring finger and little finger, but with atrophy of the short abductor muscle of the thumb. They attributed this finding to an anomaly of innervation of the short abductor.

The main classical treatises describe Martin-Gruber anastomosis as nerve communication in the forearm between the median and ulnar nerves, but do not mention either the origin or the destination of the nerve fibers.

Conclusion

Knowledge of the anatomical variations relating to innervation of the hand is particularly important with regard to performing physical examinations, making diagnoses, determining the prognosis and implementing surgical treatment. If these variations are not given their proper value, errors and consequences will be inevitable.

Nerve communications between the median and ulnar nerves may cause alterations to clinical symptoms, especially in patients with carpal tunnel syndrome, since these

variations may exacerbate or attenuate the symptoms and cause motor and sensory alterations that differ from the usual pattern. Clinically, variations in motor innervation are very important, in that even with complete rupture of the median or ulnar nerve, some of these muscles may not necessarily become paralyzed. Such situations could lead to the wrong conclusion that the nerve had not become completely severed. It is essential to differentiate between partial and total rupture. However, correct identification of these variables is not always easy, since rigorous clinical and electromyographic examination is needed. Alterations recorded in the electroneuromyographic examination without clinical proof are insufficient for indicating a surgical procedure. Careful dissection during the surgical procedure may prevent injury to an anastomotic ramus.

Conflicts of interest

The authors declare no conflicts of interest.

REFERENCES

1. Hight WH. Innervation an function of the thenar muscles. *Lancet*. 1943;241(6234):227–30.
2. Forrest WJ. Motor inervation of human thenar and hypothenar muscles in 25 hands: a study combining electromyography and percutaneous nerve stimulation. *Can J Surg*. 1967;10(2):196–9.
3. Martin R. *Tal om Nervers allmanna Egenskaper i Manniskans Kropp*. Stockholm: Las Salvius; 1763.
4. Gruber W. Ueber die verbindung des nervus medianus mit dem nervus ulnaris am unterame des menschen um der saugethiere. *Arch Physiol*. 1870;37(2):501–22.
5. Sunderland S. *Nervios periféricos y sus lesiones*. 2 ed. Barcelona: Salvat; 1985.
6. Sala E. Studio elletromiografico dell inervazione dei muscoli flessre breve ed opponent dl police. *Riv Pat Nerv Ment*. 1958;80:131–47.
7. Harness D, Sekeles E. The double anastomotic innervation of thenar muscles. *J Anat (London)*. 1974;117:329–31.
8. Rosen AD. Innervation of the hand: an electromyographic study. *Electromyogr Clin Neurophysiol*. 1973;13(2):175–8.
9. Thomson A. Third annual report of committee of collective investigation of anatomical society of Great Britain and Ireland for the year 1891–92. *J Anat Physiol*. 1893;27:183–94.
10. Hirasawa K. Untersuchugen uber das periphere nervensystem, plexus brachialis und dien nerven der obern extremitat. *Arb Anat Inst Kaiserlichen Univ Kyoto*. 1931;1(2):135–40.
11. Kimura J, Murphy MJ, Varada DJ. Electrophysiological study of anomalous innervation of intrinsic hand muscles. *Arch Neurol*. 1976;33(12):842–4.
12. Sirinivasan R, Rhodes J. The median ulnar anastomosis (Martin Gruber) in normal and congenitally fetuses. *Arch Neurol*. 1981;38(7):418–9.
13. Uchida Y, Sugioka Y. Electrodiagnosis of Martin Gruber connection and its clinical importance in peripheral nerve surgery. *J Hand Surg Am*. 1992;17(1):54–9.
14. Nakashima T. An study on the Martin Gruber anastomosis. *Surg Radiol Anat*. 1993;15(3):193–5.
15. Oh S. *Clinical electromyography: nerve conduction studies*. Baltimore: Williams Wilkins; 1993.

16. Shu HS, Chantelot C, Oberlin C, Alnot JY, Shao H. Martin-Gruber communicating branch: anatomical and histological study. *Surg Radiol Anat.* 1999;21(2):115-8.
17. Rodriguez-Niedenfuhr M, Vazquez T, Parkin I, Logan B, Sanudo JR. Martin-Gruber anastomosis revisited. *Clin Anat.* 2002;15(2):129-34.
18. Lee KS, Oh CS, Chung IH, Sunwoo IN. An anatomic study of the Martin-Gruber anastomosis: electrodiagnostic implications. *Muscle Nerve.* 2005;31(1):95-7.
19. Shafic A, Moussalen C, Stafford J. Cubital tunnel syndrome presenting with carpal tunnel symptoms: clinical evidence for sensory for median to ulnar nerve communication. *Am J Orthop.* 2009;38(6):104-6.
20. Marinacci A. The problem of unusual anomalous innervation of hand muscles. The value of electrodiagnosis in its evaluation. *Bull Los Angeles Neuro Soc.* 1964;29:133-42.
21. Cliffton EE. Unusual innervation of the intrinsic muscle of the hand by median and ulnar nerve. *Surgery.* 1948;23(1):12-31.
22. Caetano EB. Contribuição ao estudo da inervação dos músculos da região tenar e da anastomose de Cannieu e Riché [tese]. Sorocaba (SP): Centro de Ciências Médicas e Biológicas - PUCSP; 1982.
23. Pastor JP, Uclés AR. Estudio electrofisiológico de la inervación anómala de la mano. *Rev Neurol.* 2001;32(2):112-8.
24. Brandsma JW, Birke JA, Sims DS Jr. The Martin-Gruber innervated hand. *J Hand Surg Am.* 1986;11(4):536-9.
25. Rosén B, Lundborg G. Sensory re-education after nerve repair: aspects of timing. *Handchir Mikrochir Plast Chir.* 2004;36(1):8-12.
26. Amoiridis G. Frequency of ulnar-to-median nerve anastomosis [carta]. *Electromyogr Clin Neurophysiol.* 1992;32(4-5):255-6.
27. Golovchinsky V. Ulnar-to-median anastomosis and its role in the diagnosis of lesions of the median nerve at the elbow and the wrist. *Electromyogr Clin Neurophysiol.* 1990;30(1):31-4.
28. Kómár J, Szegvári M, Gloviczky Z, Szántó A. Traumatic section of the median nerve without complete motor paresis: the Martin-Gruber anastomosis. *Nervenarzt.* 1978;49(12):697-9.
29. Streib EW. Ulnar-to-median nerve anastomosis in the forearm: electromyographic studies. *Neurology.* 1979;29(11):1534-7.
30. Dogan N, Uysal I, Seker M. The communications between the ulnar and median nerves in upper limb. *J Neuroanat.* 2009;8(1):15-9.