



Original Article

Anatomical study on the relationship between the dorsal root ganglion and the intervertebral disc in the lumbar spine[☆]



Emiliano Vialle*, Luiz Roberto Vialle, William Contreras, Chárbel Jacob Junior

Hospital Universitário Cajuru, Pontifícia Universidade Católica do Paraná, Curitiba, PR, Brazil

ARTICLE INFO

Article history:

Received 28 May 2014

Accepted 1 August 2014

Available online 3 July 2015

Keywords:

Spine/anatomy and histology

Spinal ganglia

Minimally invasive surgical procedures

ABSTRACT

Objective: To describe the location of the dorsal root ganglion in relation to the intervertebral disc, including the “triangular” safety zone for minimally invasive surgery in the lumbar spine.

Methods: Eight adult cadavers were dissected bilaterally in the lumbar region, using a posterolateral approach, so as to expose the L3L4 and L4L5 spaces, thereby obtaining measurements relating to the space between the intervertebral disc, pedicles cranial and caudal to the disc, path of the nerve root, dorsal ganglion and safety triangle.

Results: The measurements obtained were constant, without significant differences between levels or any laterality. The dorsal ganglion occupied the lateral border of the triangular safety zone in all the specimens analyzed.

Conclusion: Precise localization of the ganglion shows that the safety margin for minimally invasive procedures is less than what is presented in studies that only involve measurements of the nerve root, thus perhaps explaining the presence of neuropathic pain after some of these procedures.

© 2014 Sociedade Brasileira de Ortopedia e Traumatologia. Published by Elsevier Editora Ltda. All rights reserved.

Estudo anatômico da relação do gânglio da raiz dorsal com o disco intervertebral na coluna lombar

RESUMO

Objetivo: Descrever a localização do gânglio da raiz dorsal em relação ao disco intervertebral, incluindo a zona “triangular” de segurança para cirurgia minimamente invasiva na coluna lombar.

Métodos: Oito cadáveres adultos foram dissecados bilateralmente, na região lombar, com a abordagem posterolateral, até exposição dos espaços L3L4 e L4L5 e se obtiveram medidas referentes ao espaço entre o disco intervertebral, os pedículos cranial e caudal ao disco, o trajeto da raiz nervosa, o gânglio dorsal e o triângulo de segurança.

Palavras-chave:

Coluna vertebral/anatomia &

histologia

Gânglios espinais

Procedimentos cirúrgicos

minimamente invasivos

[☆] Work performed in the Department of Anatomy, Medical Course, Pontifícia Universidade Católica do Paraná, Curitiba, PR, Brazil.

* Corresponding author.

E-mail: evialle@hotmail.com (E. Vialle).
<http://dx.doi.org/10.1016/j.rboe.2015.06.013>

2255-4971/© 2014 Sociedade Brasileira de Ortopedia e Traumatologia. Published by Elsevier Editora Ltda. All rights reserved.

Resultados: As medidas obtidas foram constantes, sem diferenças significativas entre níveis ou lateralidade. O gânglio dorsal ocupou a borda lateral da zona triangular de segurança em todos os espécimes analisados.

Conclusão: A localização precisa do gânglio mostra que a margem de segurança para procedimentos minimamente invasivos é menor do que a apresentada nos estudos que envolvem apenas medidas da raiz nervosa, o que explica talvez a presença de dor neuropática após alguns desses procedimentos.

© 2014 Sociedade Brasileira de Ortopedia e Traumatologia. Publicado por Elsevier Editora Ltda. Todos os direitos reservados.

Introduction

Advances in surgical treatments for degenerative pathological conditions, and specifically in relation to minimally invasive surgery for the lumbar spine, have given rise to the need to reassess previous concepts of surgical anatomy, given that new accesses that are less invasive have been developed. Minimally invasive approaches have the advantage of tissue preservation, reduction of unnecessary damage to healthy areas, acceleration of healing and reduction of the duration of treatment.¹⁻³ However, these approaches do not always enable direct viewing of the neural structures and it is at this point that reviewing anatomical knowledge becomes important.

The dorsal nerve roots are composed only of sensory fibers coming from the spinal nerves that head toward the spinal cord. The ventral nerve roots are mostly composed of motor fibers, but they may transport a small quantity of sensory fibers. Close to the junction between the dorsal and ventral roots, the dorsal root presents a dilatation known as the dorsal root ganglion (DRG),⁴ which consists of a grouping of cell bodies of sensory fibers. The DRGs are located in the intervertebral foramina, except for the sacral DRGs, which are located inside the vertebral canal, and the coccygeal DRGs, which are intradural.⁴⁻⁶

The DRG differs from the nerve roots in that it is sensitive to mechanical pressure even in the absence of chemical irritation, since it contains a large number of nociceptors that are mechanically more sensitive. Moreover, it may have greater chance of causing neuropathic pain if it is injured.^{4,5,7}

Neuropathic pain is a state of neural dysfunction provoked by functional and structural alterations to the central and peripheral sensory pathways, which produce modifications to the processing of the nociceptive information. It can be caused by injuries to the roots, DRGs, spinal cord or encephalon.^{8,9}

Transforaminal intersomatic arthrodesis or transforaminal lumbar interbody fusion (TLIF) was developed to enable access to lumbar intervertebral discs by means of a unilateral extracanal route, thereby avoiding the problems and limitations of the original technique (posterior lumbar interbody fusion, PLIF). One of the complications relating to using TLIF that has been reported in the literature is the presence of neuropathic pain subsequent to the surgery. This has been attributed to excessive manipulation of the dorsal ganglion of the emerging root.¹⁰⁻¹²

In view of the sparseness of the literature on the anatomy of the dorsal ganglion, as applied to the TLIF technique, we

conducted a study on cadavers, with the aim of determining the safest area for undertaking a transforaminal approach for treating lumbar intervertebral discs, with emphasis on their anatomical relationship with the dorsal ganglion.

The “triangular safety zone” is considered to be a safe area for accessing the intervertebral discs of the lumbar spine. This zone was first defined by Mirkovic et al.,¹³ with its lateral limit as the dura mater, its lower limit the upper vertebral plateau and its hypotenuse the lumbar root. In this zone, the intervertebral disc can be accessed without putting the surrounding neural structures at risk. The position of the DRG is not mentioned in this triangle and, because of its oval shape, it may reduce the lateral limits of the area of safety for minimally invasive approaches.^{12,13}

The present study had the aim of describing the location of the DRG in relation to the intervertebral disc, including the “triangular” safety zone for minimally invasive surgery on the lumbar spine.

Methods







This study was conducted in our institution’s Department of Human Anatomy. Eight cadavers without any previous scarring on the lumbar spine were studied. They were all male, ranging in age from 45 to 62 years (mean: 54). The number of cadavers was defined by the institution by calculating the variability of the sample.

The cadavers were positioned in ventral decubitus and a posterior access route in a single layer was constructed. Extensive laminectomy was then performed on the lumbar spine, to expose the dural sac, the lumbar roots with their respective DRGs, the pedicles and the intervertebral discs (Fig. 1). The segment L5-S1 was not studied because of the need for more extensive dissection and possible damage to the anatomical specimen. Using a straight osteotome, osteotomy was performed on the joint facets and lateral recess, and the anatomical structures of the intervertebral foramen were viewed.

Using a digital pachymeter (Mistainless®), the following measurements in millimeters were made (Table 1, Fig. 2):

- (1) Upper limit of the intervertebral disc to the axilla of the emerging root;
- (2) Axilla of the root to the start of the dorsal ganglion;
- (3) Lower portion of the pedicle to the dorsal ganglion;

Table 1 – Description of the measurements made.

Measurement	Description	Color in Fig. 2
1	Upper limit of the intervertebral disc to the axilla of the emerging root	
2	Axilla of the root to the start of the dorsal ganglion	
3	Lower portion of the pedicle to the dorsal ganglion	
4	Triangular safety zone	
5	Vertical distance between pedicles	
6	Greatest diameter of the dorsal ganglion	
7	Smallest diameter of the dorsal ganglion	
8	Axilla of the root to the lower limit of the cranial intervertebral disc	

- (4) Triangular safety zone (height, base and hypotenuse):
 Height of the triangle: lateral border of the dura mater;
 Base: upper vertebral plateau of the lower vertebra;
 Hypotenuse: spinal nerve;
- (5) Vertical distance between pedicles;
- (6) Greatest diameter of the dorsal ganglion;
- (7) Smallest diameter of the dorsal ganglion;

- (8) Axilla of the root to the lower limit of the cranial intervertebral disc.

Results

The data and the results obtained are summarized in [Tables 2 and 3](#).

In all the spines evaluated, the DRG touched or entered the limits of the triangular safety zone and thus was shown to be a risk factor for procedures that come close to this region. Another factor that emphasizes the close relationship of the DRG with the triangular safety zone is the ratio of its height (around 15 mm) to the greatest length of the DRG (7.5 mm). If the portion of the triangular zone relating to the cranial pedicle and the vertebral body (around 8 mm) is excluded, it can be seen that the remainder of the external border of the triangular zone necessarily ends up being occupied by the DRG ([Fig. 2](#)).

Discussion

One of the most unpredictable complications of minimally invasive approaches to the spine is the presence of post-surgical neuropathic pain. This is difficult to manage and its duration may range from days to years. Manipulation of the DRG and possible variations in its anatomy have been attributed as causal factors.⁸⁻¹¹

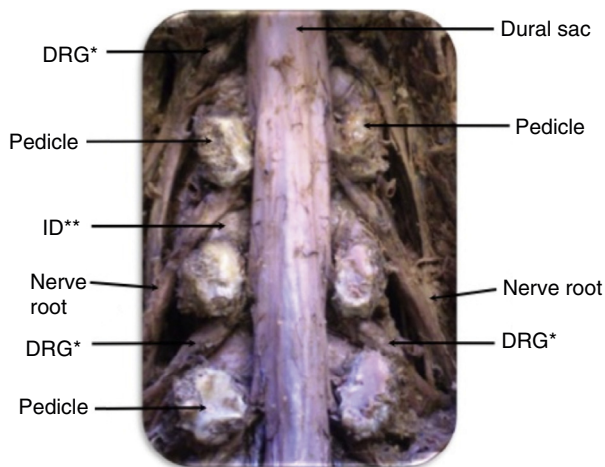


Fig. 1 – Anatomical exposure of the nerve root, intervertebral disc (ID), dorsal root ganglion (DRG), pedicle and dural sac.

Table 2 – Means of the values obtained in the study.

Measurement	Description	Mean (mm)
1	Upper limit of the intervertebral disc to the axilla of the emerging root	14.65
2	Axilla of the root to the start of the dorsal ganglion	7.95
3	Lower portion of the pedicle to the dorsal ganglion	5.45
4	Triangular safety zone	Table 3
5	Vertical distance between pedicles	15.25
6	Greatest diameter of the dorsal ganglion	13.25
7	Smallest diameter of the dorsal ganglion	7.05
8	Axilla of the root to the lower limit of the cranial intervertebral disc	8.0

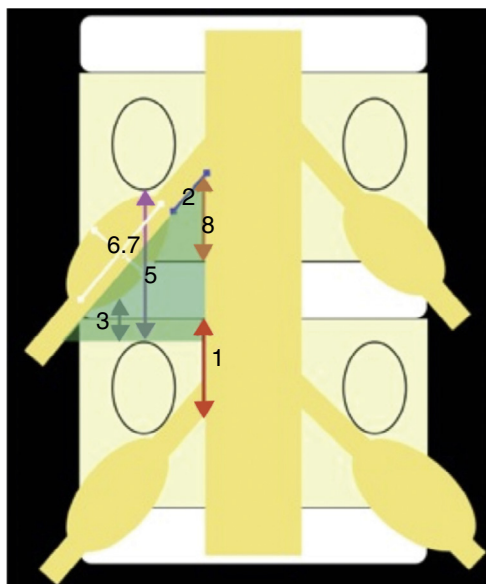


Fig. 2 – Measurements made during the study. 1, upper limit of the intervertebral disc to the axilla of the emerging root; 2, axilla of the root to the start of the dorsal ganglion; 3, lower portion of the pedicle to the dorsal ganglion; 4, green triangular area: triangular safety zone; 5, vertical distance between pedicles; 6 and 7, diameter of the DRG; 8, axilla of the root to the lower limit of the cranial intervertebral disc.

Most studies have described the DRG as an oval structure that is almost entirely located within the foramina at lumbar levels,^{10,11} but they do not describe the safety limits for it. This knowledge is of great importance for minimally invasive procedures on the spine.

The triangular safety zone was first described by Mirkovic et al.,¹³ who defined it as a space in the foraminal region that would make it possible to introduce cannulae for posterolateral percutaneous procedures in the lumbar region,

without putting the surrounding neural structures at risk. There was no mention of the position of the DRG in that initial report.¹³⁻¹⁵

The triangle constructed from the data of Choi et al.¹⁵ presented anatomical characteristics that differed from those described by Mirkovic et al.¹³ in relation to height and width. However, the general mean of the hypotenuse of the triangular safety zone was concordant. They obtained a mean of 23 mm versus 25.49 mm in the study by Mirkovic, but neither of these studies made any mention of the position of the DRG.

Kambin et al.¹⁴ described the safety limits of percutaneous procedures for accessing intervertebral discs, with introduction of instruments at a distance of 10 cm from the midline and in parallel with the vertebral plateau, with penetration of the annulus at a ten o'clock or two o'clock position. They also reported the limitations of these procedures, such as extruded and sequestered hernias.

In the present study, attention was paid to the safety limits of the DRG, which was located 7 mm from the exit point of the nerve root, usually in a location within the foramina. The distance from the intervertebral disc to the lower part of the nerve root was sufficient for a safe approach. The lower pedicle, which marks the lower limit of the safety zone, was located 5 mm from the DRG, i.e. differing from the findings of Mirkovic et al.¹³ and Choi et al.¹⁵ (Fig. 3).

The limitation of this study was the small number of specimens for analysis, which may have affected the values of the data presented. However, similar studies in the literature that presented larger numbers of levels analyzed included the

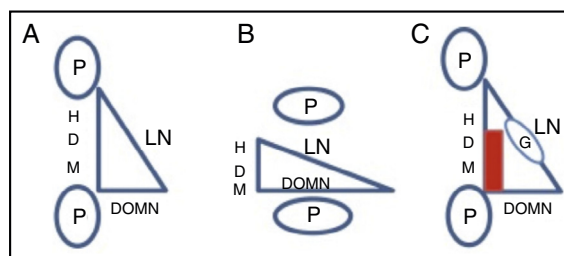


Fig. 3 – Comparative schematic appearance of the safety zones for the spinal nerve. (A) Choy et al.; (B) Mirkovic et al.; (C) Vialle et al. HDM, height of the dura mater; LN, length of the spinal nerve; DDMN, distance from the dura mater to the spinal nerve; HID, height of the intervertebral disc; P, pedicle of the vertebral arch; G, dorsal root ganglion (DRG); rectangular area in red represents the safety zone of the DRG.

Table 3 – Measurement of the triangular safety zone.

Measurement	L3 left	L3 right	L4 left	L4 right
Base (mm)	14.25	13.75	14.55	14.17
Height (mm)	14	16.55	17.52	16.4
Hypotenuse (mm)	18.98	21.53	23.03	21.72

entire lumbar spine, which generated wide variation of root angles, especially at L2-L3 and L5-S1.¹⁵ Furthermore, those studies did not place any emphasis on the dorsal ganglion and its location, perhaps for introduction points for endoscopy. In the present study, we sought to find spaces for accessing the disc in minimally invasive procedures.

Conclusion

The DRG infringes the lateral limits of the triangular safety zone, in the intervertebral foramen, and may be injured in foraminal procedures such as minimally invasive TLIF. We propose that a rectangular safety zone should be used, with the aim of reducing the nerve injury and the presence of neuro-pathic pain in percutaneous procedures.

Conflicts of interest

The authors declare no conflicts of interest.

REFERENCES

- Shen J, Wang HY, Chen JY, Liang BL. Morphologic analysis of normal human lumbar dorsal root ganglion by 3D MR imaging. *AJNR Am J Neuroradiol.* 2006;27(10):2098-103.
- Potter BK, Freedman BA, Verwiebe EG, Hall JM, Polly DW Jr, Kuklo TR. Transforaminal lumbar interbody fusion: clinical and radiographic results and complications in 100 consecutive patients. *J Spinal Disord Tech.* 2005;18(4):337-46.
- Kim KT, Lee SH, Lee YH, Bae SC, Suk KS. Clinical outcomes of 3 fusion methods through the posterior approach in the lumbar spine. *Spine (Phila PA 1976).* 2006;31(12):1351-7.
- Bougduk N, Twomey LT. *Clinical anatomy of the lumbar spine.* Edinburgh: Churchill Livingstone; 1987.
- Porterfield JA, DeRosa C. *Mechanical low back pain. Perspectives in functional anatomy.* Philadelphia: Saunders; 1998.
- Hasegawa T, Mikawa Y, Watanabe R, An HS. Morphometric analysis of the lumbosacral nerve roots and dorsal root ganglia by magnetic resonance imaging. *Spine (Phila PA 1976).* 1996;21(9):1005-9.
- Cohen MS, Wall EJ, Brown RA, Rydevik B, Garfin SR. 1990 AcroMed Award in basic science. Cauda equina anatomy. II: extrathecal nerve roots and dorsal root ganglia. *Spine (Phila PA 1976).* 1990;15(12):1248-51.
- Baron R. Neuropathic pain: the long path from mechanisms to mechanisms-based treatment. *Int J Pain Med Palliat Care.* 2001;1(1):2-14.
- Nicholson BD. Evaluation and treatment of central pain syndromes. *Neurology.* 2004;62 5 Suppl 2:S30-6.
- Rihn JA, Patel R, Makda J, Hong J, Anderson DG, Vaccaro AR, et al. Complications associated with single-level transforaminal lumbar interbody fusion. *Spine J.* 2009;9(8):623-9.
- Hee HT, Castro FP Jr, Majd ME, Holt RT, Myers L. Anterior/posterior lumbar fusion versus transforaminal lumbar interbody fusion: analysis of complications and predictive factors. *J Spinal Disord Tech.* 2001;14(6):533-40.
- Selznick LA, Shamji MF, Isaacs RE. Minimally invasive interbody fusion for revision lumbar surgery: technical feasibility and safety. *J Spinal Disord Tech.* 2009;22(3):207-13.
- Mirkovic SR, Schwartz DG, Glazier KD. Anatomic considerations in lumbar posterolateral percutaneous procedures. *Spine (Phila Pa 1976).* 1995;20(18):1965-71.
- Kambin P, Zhou L. History and current status of percutaneous arthroscopic disc surgery. *Spine (Phila Pa 1976).* 1996;21 24 Suppl:57S-61S.
- Choi PS, Basile R. Estudo anatômico da zona triangular de segurança aplicada aos procedimentos percutâneos pósterolaterais. *Coluna/Columna.* 2003;2(1):1-9.