



## Case report

# Intrathoracic fracture-dislocation of the humerus – case report and literature review<sup>☆</sup>



Wilson Carlos Sola Junior<sup>a,\*</sup>, Paulo Sérgio dos Santos<sup>b</sup>

<sup>a</sup> Hospital XV, Curitiba, PR, Brazil

<sup>b</sup> Universidade Federal do Paraná, Hospital de Clínicas, Curitiba, PR, Brazil

## ARTICLE INFO

## Article history:

Received 17 March 2016

Accepted 2 May 2016

Available online 5 February 2017

## Keywords:

Dislocations

Shoulder fractures

Shoulder joint

Humeral head

Hemiarthroplasty

## ABSTRACT

Shoulder fracture-dislocations are uncommon. Those associated with intrathoracic dislocation are very rare conditions, resulting from high-energy trauma; usually, the affected limb is in an abduction position. In Brazil, there is only one report of a teenager with displacement of the epiphysis into the chest cavity; the present is the first adult patient report of intrathoracic dislocation of the humerus. The authors present the case of a patient female, aged 56 years, who was hit by motorcycle and thrown approximately 5 meters away. She was rescued on site with thoracic, pelvic, and right upper limb trauma. Her chest was drained due to pneumothorax and multiple fractures of ribs; she was diagnosed with fracture-dislocation in four parts, with intrathoracic dislocation of the humeral head. Displaced forearm bones fracture was also diagnosed; the olecranon, scaphoid, and ischiopubic fractures were not displaced. The patient underwent a joint procedure with a cardiothoracic surgery team to remove the humeral head through thoracotomy and chest drainage; subsequently, a partial arthroplasty of the humerus was performed, with graft from the humeral head and fixation of forearm fractures. Conservative treatment was chosen for the other fractures. After three months, all fractures were healed with gradual functional improvement. The patient remained in physiotherapy and orthopedic monitoring, having been discharged from the thoracic surgery; in a severe depressive episode, the patient committed suicide after 11 months of the trauma.

© 2016 Sociedade Brasileira de Ortopedia e Traumatologia. Published by Elsevier Editora Ltda. This is an open access article under the CC BY-NC-ND license (<http://creativecommons.org/licenses/by-nc-nd/4.0/>).

<sup>☆</sup> Study conducted at Hospital XV, Curitiba, PR, Brazil.

\* Corresponding author.

E-mail: [solajr@gmail.com](mailto:solajr@gmail.com) (W.C. Sola Junior).

<http://dx.doi.org/10.1016/j.rboe.2017.01.005>

2255-4971/© 2016 Sociedade Brasileira de Ortopedia e Traumatologia. Published by Elsevier Editora Ltda. This is an open access article under the CC BY-NC-ND license (<http://creativecommons.org/licenses/by-nc-nd/4.0/>).

## Fratura luxação intratorácica do úmero – Relato de caso e revisão da literatura

### R E S U M O

#### Palavras-chave:

Luxações  
Fraturas do ombro  
Articulação do ombro  
Cabeça do úmero  
Hemiartroplastia

As fraturas luxações do ombro são incomuns; aquelas associadas com deslocamento intratorácico são condições muito raras e decorrentes de traumas de alta energia, nos quais o membro acometido geralmente está numa posição de abdução. No Brasil, existe apenas o relato de um adolescente com deslocamento da epífise para o interior da caixa torácica. Esse é o primeiro relato de paciente adulto com luxação intratorácica de úmero.

Os autores apresentam um caso de paciente feminina de 56 anos, atropelada por motocicleta e arremessada em torno de cinco metros de distância. Foi socorrida no local com trauma torácico, pélvico e do membro superior direito. Teve o tórax drenado devido a pneumotórax e múltiplas fraturas de arcos costais e recebeu o diagnóstico de fratura luxação em quatro partes com deslocamento intratorácico da cabeça umeral. Foram diagnosticadas fratura de ossos do antebraço desviada e fraturas do olécrano, do escafoide e dos ramos isquiopúbicos sem desvios. A paciente foi submetida a procedimento cirúrgico conjunto com uma equipe de cirurgia cardiotorácica para retirada da cabeça umeral por meio de toracotomia e drenagem torácica; posteriormente, uma artroplastia parcial do úmero foi feita, com enxertia proveniente da cabeça umeral, além de fixação das fraturas do antebraço. Nas demais fraturas, optou-se por tratamento conservador. Após três meses, todas as fraturas apresentavam-se consolidadas com melhora gradual das funções. A paciente permaneceu em acompanhamento fisioterápico e ortopédico e recebeu alta da cirurgia torácica. Dentro de um quadro depressivo grave, cometeu suicídio 11 meses após o trauma.

© 2016 Sociedade Brasileira de Ortopedia e Traumatologia. Publicado por Elsevier Editora Ltda. Este é um artigo Open Access sob uma licença CC BY-NC-ND (<http://creativecommons.org/licenses/by-nc-nd/4.0/>).

### Introduction

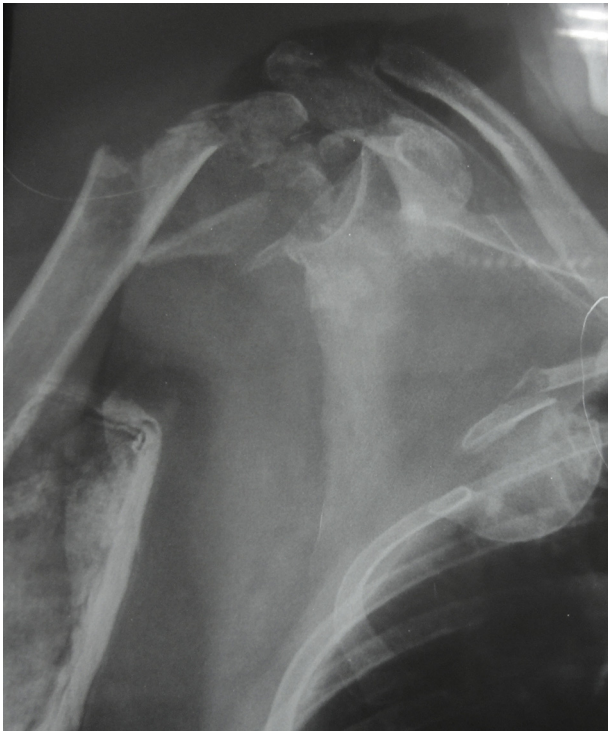Fracture-dislocations of the humerus are relatively uncommon. When associated with intrathoracic displacement, they are extremely rare and potentially fatal. The cases described in the literature have in common high-energy trauma involved, the position of the limb (predominantly in abduction), and lack of age group predilection. Penetration of the humeral head into the thoracic cavity is due to the fragility between the upper ribs, which facilitates migration. The severity of the condition stems mainly from pulmonary involvement and the numerous injuries frequently observed in this type of lesion.

The authors describe the first case in the Brazilian literature of an adult patient with an intrathoracic fracture-dislocation of the humerus, after being run over by a motorcycle.

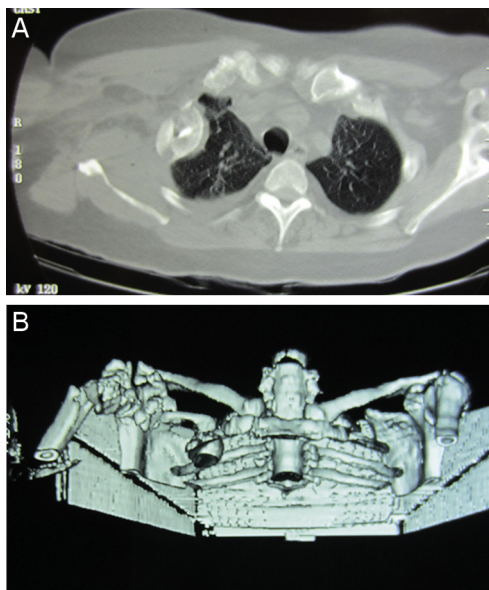
### Case report

A female patient, 56 year-old, right-handed, was struck by a motorcycle and tossed five meters away; the mobile emergency care service (Serviço de Atendimento Móvel de Urgência [SAMU]) team provided pre-hospital care and she was taken to the public hospital. Physical examination showed a severely polytraumatized, hypotensive, and tachypneic patient, with cervical and right upper limb immobilization; she presented large edema in the right shoulder, a deformity in the forearm, and ipsilateral elbow. At admission, neurological and vascular examination were normal. After

radiological evaluation, serial rib fractures, displaced forearm fracture, and undisplaced olecranon and scaphoid fractures were diagnosed, as well as fractures of the ilio- and ischiopubic branches with minimal displacement. What called the attention of the entire team was a fracture of the proximal humerus with absence of the humeral head; after imaging exams were reviewed, migration of the head to the interior of the thoracic cavity was evidenced. Patient was diagnosed with hemopneumothorax and underwent an emergency procedure for chest drainage; subsequently, she was taken to the intensive care unit. Nine days after trauma and stabilization of the hemodynamic and clinical picture, she was referred to this service for definitive fracture treatment. Initially, a radiological assessment and a computed tomography with 3-D reconstruction of the shoulder and thorax were performed, (Figs. 1 and 2A and B). The authors requested an assessment by the cardiothoracic surgery team, who agreed to do the procedure together. Patient was then submitted to a thoracotomy to remove the humeral head (Fig. 3), followed by new thoracic drainage. Subsequently, a partial arthroplasty of the humerus was performed, using the humeral head as graft (Fig. 4). The forearm fracture was fixated with conventional compression plates; other fractures were treated conservatively. Forty-eight hours after surgery, patient was discharged from the ICU and the chest drain was removed; she remained hospitalized for three days before discharge. During orthopedic follow-up, she presented fracture consolidation (and even consolidation of the tubercles next to the prosthesis [Fig. 5]), and obtained a partial gain of shoulder movement. She evolved with reflex sympathetic dystrophy of the upper limb, which was diagnosed and treated. She

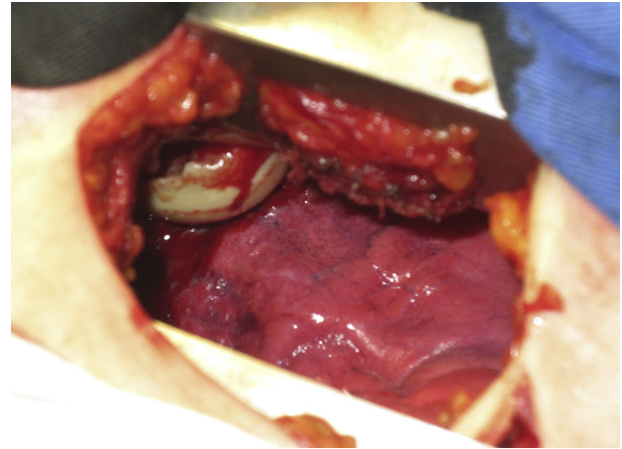


**Fig. 1 – Radiograph of the right shoulder, showing a complex fracture of the proximal humerus with intrathoracic migration of the humeral head.**



**Fig. 2 – (A) Chest computed tomography (CT): axial section showing the humeral head in direct contact with the pulmonary parenchyma; (B) chest CT: 3D reconstruction. Rib fractures and cephalic migration into the pulmonary cavity are observed.**

achieved a shoulder range of motion of 100 degrees of anterior elevation, 30 degrees of external rotation, and internal rotation at the level of L1. Eleven months after the initial trauma and in a severe depressive state, she committed suicide.



**Fig. 3 – Intraoperative image of the thoracotomy for removal of the humeral head.**

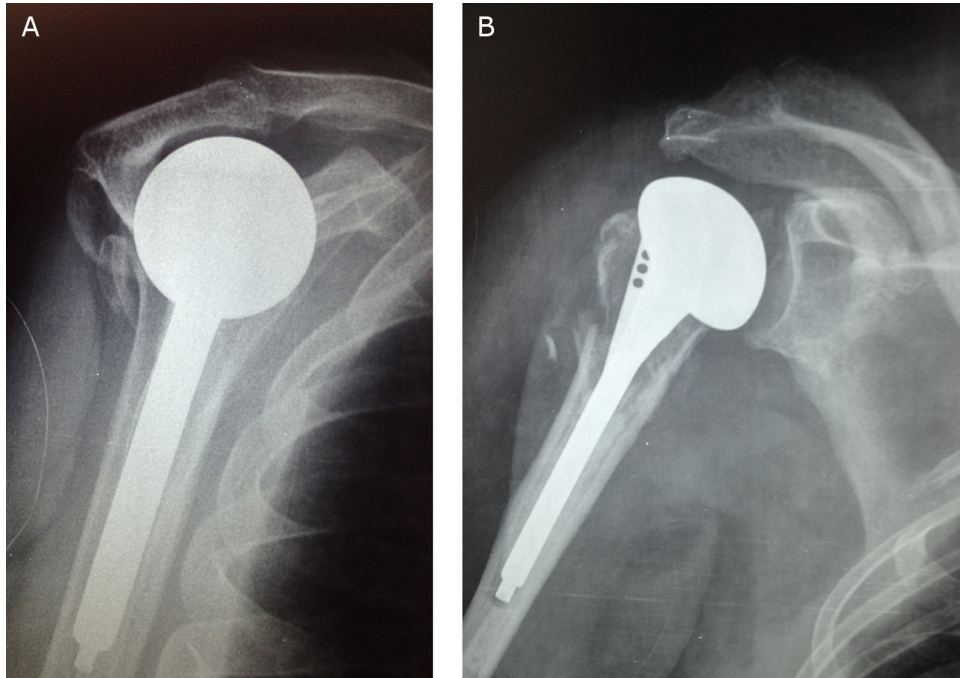
## Discussion

Reports of intrathoracic fracture-dislocation of the humerus are extremely scarce in the literature. After an extensive review in the main database, only 24 articles (20 of which in English) reporting patients with this type of lesion were retrieved. West<sup>1</sup> was one of the first authors who reported this type of atypical presentation in an adult patient, who suffered a fall from height. Other similar injury reports were described by Glessner,<sup>2</sup> in 1961, and by Patel,<sup>3</sup> in 1963, whose patients underwent fracture reduction and fixation with satisfactory results. In both cases, patients were elderly with low functional demand. Watson-Jones<sup>4</sup> also described the case of a patient with fracture-dislocation and remote migration of the head, but with no further details.

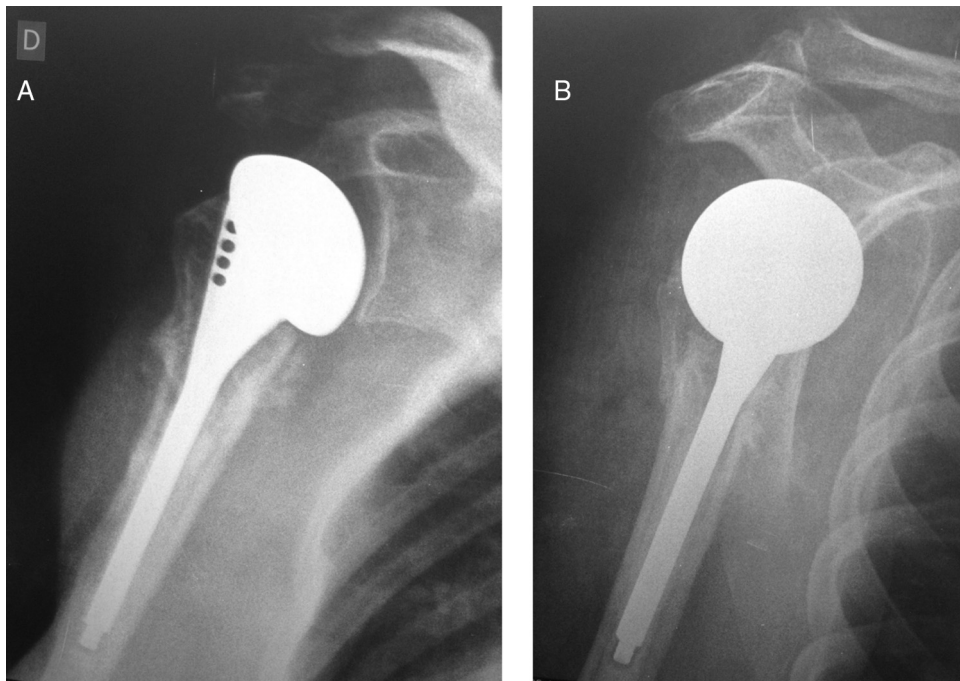
In the 1990s, Wirth et al.<sup>5</sup> and Simpson et al.<sup>6</sup> described cases of younger patients who suffered motorvehicle accident, one of whom was struck and tossed for approximately six meters, a mechanism similar to the present case. Harman et al.<sup>7</sup> reported a case of a 56-year-old patient, the victim of a rollover, with intrathoracic fracture-dislocation of the humerus with severe comminution, who underwent removal of the head from the thoracic cavity, followed by hemiarthroplasty. The only article retrieved in the Brazilian literature reported the case of a 14-year-old female patient with a fixed intrathoracic fracture-dislocation, whose six-year follow-up indicated an excellent functional outcome, despite partial avascular necrosis.<sup>8</sup>

The removal of the humeral head and fragments, followed by hemiarthroplasty at a later time, was described by Galois et al.<sup>9</sup> and recently by Fang et al.<sup>10</sup> in patients with compression of the thoracic aorta by the presence of the humeral head. This patient had to wait three weeks until clinical stabilization for arthroplastic reconstruction. A single article, by Boyer et al.,<sup>11</sup> reported a case of fracture-dislocation in four parts with intrathoracic displacement, with satisfactory results. The use of hemiarthroplasty for shoulder reconstruction has been a trend in recent reports<sup>11-13</sup>; only one article mentioned the use of reverse arthroplasty in a patient aged over 60 years.<sup>14</sup>





**Fig. 4 – Radiograph in true anteroposterior and Neer profile for postoperative control of shoulder arthroplasty with local humeral head graft.**



**Fig. 5 – Six-month postoperative radiographs showing fracture and tubercle consolidation.**

In the present case, the probable trauma energy associated with the abducted position of the arm contributed to severe comminution of the fracture and intrathoracic displacement of the humeral head. Moreover, the other fractures are evidence of the dissipation of this energy throughout the upper limb. Performing a single, combined procedure with

both teams was effective, with initial removal of the humeral head followed by shoulder hemiarthroplasty. The forearm was reduced and fixated with plates and screws immediately after the end of the prosthesis. After 11 months of follow-up, patient presented regional complex pain, which was expected due to the severity of the orthopedic condition; pain

prevented adequate rehabilitation. Unfortunately, the patient's depression worsened further and culminated in suicide one year after the accident.

The combined procedure, in which cardiothoracic and orthopedic surgery were performed for the removal of the humeral head followed by hemiarthroplasty, was effective and without complications in the short-term, which is in agreement with the scarce literature on such lesions.

---

### Conflicts of interest

The authors declare no conflicts of interest.

### REFERENCES

---

1. West EF. Intrathoracic dislocation of the humerus. *J Bone Joint Surg Br.* 1949;31(1):61.
2. Glessner JR Jr. Intrathoracic dislocation of the humeral head. *J Bone Joint Surg Am.* 1961;43:428-30.
3. Patel MR, Pardee ML, Singerman RC. Intrathoracic dislocation of the head of the humerus. *J Bone Joint Surg Am.* 1963;45:1712-4.
4. Watson-Jones R. *Fractures and joint injuries.* 4th ed. Edinburgh: Livingstone; 1956.
5. Wirth MA, Jensen KL, Agarwal A, Curtis RJ, Rockwood CA Jr. Fracture-dislocation of the proximal part of the humerus with retroperitoneal displacement of the humeral head. A case report. *J Bone Joint Surg Am.* 1997;79(5):763-6.
6. Simpson NS, Schwappach JR, Toby EB. Fracture-dislocation of the humerus with intrathoracic displacement of the humeral head. A case report. *J Bone Joint Surg Am.* 1998;80(6):889-91.
7. Harman BD, Miller NG, Probe RA. Intrathoracic humeral head fracture-dislocation. *J Orthop Trauma.* 2004;18(2):112-5.
8. Guiotti Filho J, Borges ACW, Leite MC. Fratura epifisiólise da extremidade proximal do úmero com luxação intratorácica: relato de caso. *Rev Bras Ortop.* 2008;43(1/2):48-52.
9. Jun-Song W, Jing-Yu D, Zhi-Qiang W, Fang G, Xiang-Jin L. Intrathoracic displacement of the humeral head in a trauma patient. *Indian J Orthop.* 2012;46(5):596-8.
10. Galois L, Siat J, Reibel N, Valentin S, Gasnier J, Mainard D. Intra-thoracic fracture-dislocation of the humeral head: a case report and review of the literature. *Rev Chir Orthop Reparatrice Appar Mot.* 2007;93(8):854-8.
11. Liu HH, Lee YH, Yang SW, Wong CY. Fracture of the proximal humerus with intrathoracic dislocation of the humeral head. *J Trauma.* 2007;63(2):E37-9.
12. Boyer P, Alsac JM, Etori MA, Lesèche G, Hutten D. Four-part fracture after intrathoracic displacement of the humeral head: a case report and review of the literature. *Arch Orthop Trauma Surg.* 2007;127(8):651-4.
13. Wiesler ER, Smith AM, Shilt JS. Humeral head fracture-dislocation into the thoracic outlet: case report and review of the literature. *J Shoulder Elbow Surg.* 2004;13(5):576-9.
14. Maroney SS, Devinney DS. Intrathoracic fracture-dislocation of the proximal humerus treated with reverse total shoulder arthroplasty. *Orthopedics.* 2009;32(12):924.