



Case Report

Tendon of the long head of the biceps originating from the rotator cuff – An uncommon anatomical variation: case report[☆]



Carlos Vicente Andreoli*, Leonardo Roure Esteves, Eduardo Figueiredo, Paulo Santoro Belangero, Alberto de Castro Pochini, Benno Ejnisman

Universidade Federal de São Paulo (Unifesp), São Paulo, SP, Brazil

ARTICLE INFO

Article history:

Received 31 December 2014

Accepted 14 January 2015

Available online 21 December 2015

Keywords:

Tendons
Shoulder
Rotator cuff

ABSTRACT

Anatomical variations at the origin of the biceps tendon have been described by several authors, but occurrences of an origin in the supraspinatus are rare. It is unclear whether this variation might contribute toward pathological conditions of the shoulder. Our objective here was to describe a case of an anatomical variation in the origin of the tendon of the long head of the biceps.

The clinical information, preoperative images and arthroscopic images relating to a patient with an aberrant origin of the long head of the biceps, which was observed during shoulder arthroscopy, were reviewed.

In this case study, the origin of the biceps was found in the rotator cuff, without any origin from the supraglenoid tubercle or upper labrum. This variant did not seem to contribute toward the pathological condition of the shoulder, and standard treatment for the concomitant condition was sufficient for treating it.

© 2015 Sociedade Brasileira de Ortopedia e Traumatologia. Published by Elsevier Editora Ltda. All rights reserved.

Tendão da cabeça longa do bíceps originado do manguito rotador – Uma variação anatômica incomum: relato de caso

RESUMO

As variações anatômicas na origem do tendão do bíceps foram descritas por vários autores, mas a ocorrência de sua origem no supraespinhal é rara. Não está claro se essa variação pode contribuir para condições patológicas do ombro. Nosso objetivo é descrever um caso de uma variação anatômica da origem da cabeça longa do tendão do bíceps.

Palavras-chave:

Tendões
Ombro
Bainha rotadora

[☆] Work performed in the Discipline of Sports Medicine, Department of Orthopedics and Traumatology, Escola Paulista de Medicina (EPM), Universidade Federal de São Paulo (UNIFESP), São Paulo, SP, Brazil.

* Corresponding author.

E-mail: andreolicruz@uol.com.br (C.V. Andreoli).

<http://dx.doi.org/10.1016/j.rboe.2015.12.004>

2255-4971/© 2015 Sociedade Brasileira de Ortopedia e Traumatologia. Published by Elsevier Editora Ltda. All rights reserved.

Informações clínicas, imagens pré-operatórias e imagens artroscópicas foram revisadas a partir de um paciente que teve uma origem aberrante da cabeça longa do bíceps observada durante a artroscopia do ombro.

Neste estudo de caso, a origem do bíceps foi encontrada no manguito rotador, sem origem do tubérculo supraglenoidal ou labrum superior. Essa variante não parece contribuir para a patologia ombro e o tratamento padrão de patologia concomitante foi suficiente.

© 2015 Sociedade Brasileira de Ortopedia e Traumatologia. Publicado por Elsevier Editora Ltda. Todos os direitos reservados.

Introduction

A series of descriptions of the origin of the tendon of the long head of the biceps have been made. Most of these studies have described an origin in the supraglenoid tubercle.^{1,2} Recently, many reports from anatomical dissections and findings of arthroscopy have shown that the tendon very frequently originates from the supraglenoid tubercle and the upper glenoid labrum.²

Vangsness et al.² observed that in around 50% of their patients, the tendon of the long head of the biceps originated from the upper labrum and in around 50% from the supraglenoid tubercle.

During normal embryo development, the tendon of the biceps develops from the shoulder capsule and can be found as an independent structure in fetuses aged around nine weeks. Interruptions to development or abnormalities over its course may result in variations from the normal anatomy.³

There have been several descriptions of anomalous origins of the tendon of the biceps, but their clinical implications remain mostly unknown. These reports come from incidental findings during arthroscopic surgery and include aberrant intra-articular origins, extra-articular origins and agenesis.³⁻⁶ The aim of this article was to describe a rare variation in the origin of the long head of the biceps and the associated clinical condition.

Case report

The patient was a 43-year-old male manual worker who had presented pain in his right shoulder (dominant arm) for two years, with progressive worsening while performing his work. At the time when his symptoms began, he sought medical advice and was diagnosed with shoulder impact syndrome (stage 1, according to the Neer classification), based on physical examination and ultrasonography on the shoulder. He was treated with an anti-inflammatory drug (meloxicam, 15 mg orally for 10 days) and was referred for physiotherapeutic rehabilitation. He completed 50 physiotherapy sessions, with a 50% improvement of the pain.

One year after the first treatment, magnetic resonance imaging showed a lesion that affected 40% of the supraspinatus tendon. The conservative treatment was continued, using an injectable corticosteroid (three intramuscular injections of dexamethasone, every 15 days) and physiotherapeutic rehabilitation. After two years of treatment, he still presented

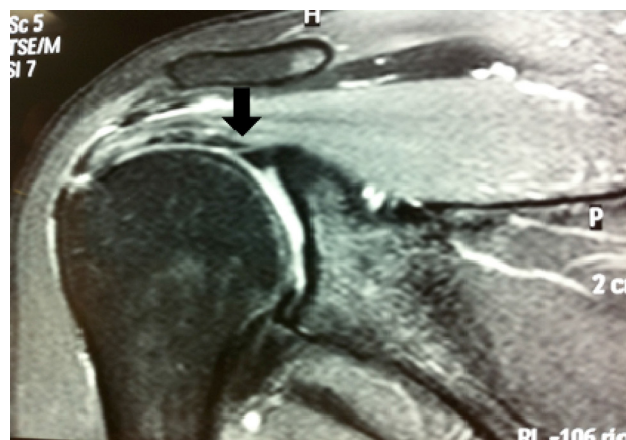

Fig. 1 – Coronal slice from magnetic resonance imaging, highlighting the anomalous origin of the long head of the biceps.

positive impact maneuvers (Neer and Hawkins), without pain on palpation of the bicipital groove, and with a negative O'Brien test. A radiographic examination showed a type II acromion (Bigliani classification).

A second magnetic resonance image revealed a bursal lesion occupying 80% of the thickness of the supraspinatus tendon (Fig. 1). Because of the persistent pain and the presence of a lesion of the supraspinatus tendon, arthroscopic repair of the rotator cuff was indicated. During the arthroscopic procedure, a variation in the anatomical origin of the tendon of the long head of the biceps was observed, such that the origin was in the lower surface of the supraspinatus tendon (Figs. 2-4). The tendon of the biceps was stable upon palpation and did not present any signs of inflammation or fibrillation along its path. Bursectomy and acromioplasty were performed and the lesion of the supraspinatus tendon was repaired using an absorbable anchor.

No procedure was performed on the tendon of the biceps. The patient returned to work five months after the operation and was seen to be asymptomatic and performing his work in a normal manner after 14 months of follow-up.

Discussion

Hyman and Warren⁷ described an extra-articular origin for the long head of the biceps in the supraspinatus. Kim et al.⁶ also described an intra-articular origin for the long head of

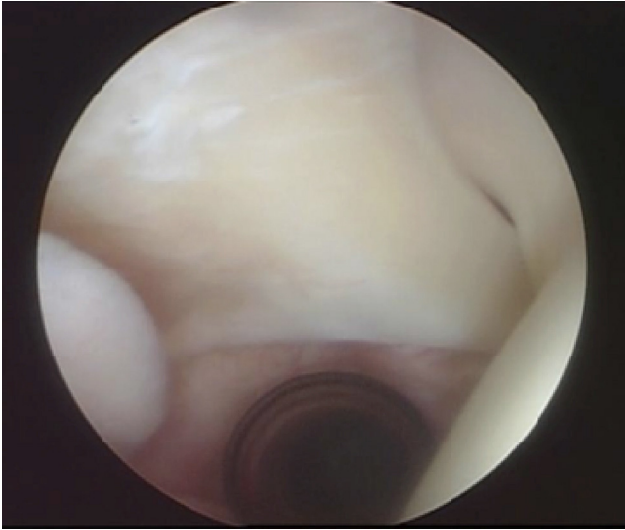

Fig. 2 – Arthroscopic image showing the origin of the long head of the biceps on the lower surface of the supraspinatus tendon.

the biceps, in the rotator cuff. In the variant described by Lang et al.,⁸ the biceps originated in the rotator head without an annex going to the upper labrum and this case presented a partial articular lesion of the rotator cuff. These authors observed that the biceps was not diseased and they therefore left it intact. They reported that complete resolution of the symptoms was achieved through arthroscopic repair of the rotator cuff.

Other intra-articular variants that have been described include a bifurcated origin of the biceps in the supraglenoid tubercle and posterosuperior labrum, a tendon of the biceps bifidus with a single origin in the supraglenoid tubercle and a tendon of the biceps that went through the supraspinatus tendon.⁹ Ogawa and Naniwa¹⁰ raised the hypothesis that if the tendon of the biceps passes through the supraspinatus tendon, this may contribute toward tearing of the rotator cuff.

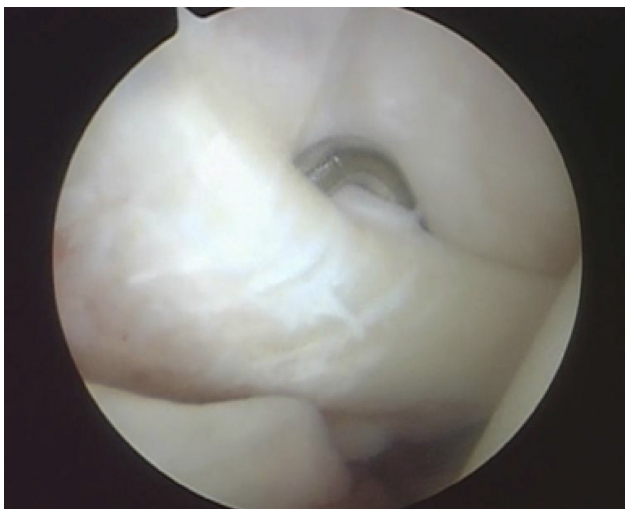

Fig. 3 – Another arthroscopic view, with the probe at the insertion of the biceps.

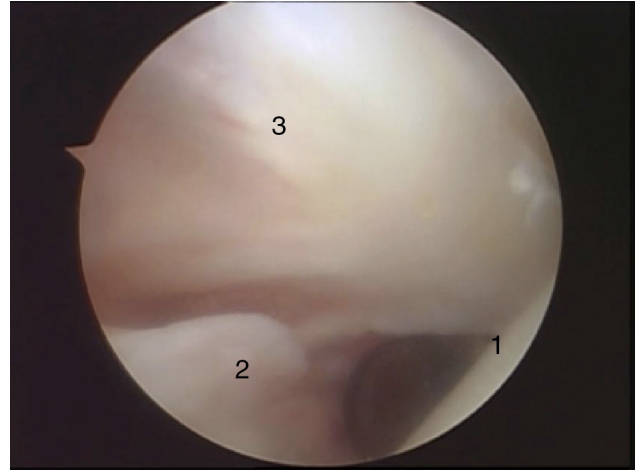


Fig. 4 – Arthroscopic views of: (1) humeral head; (2) upper labrum; (3) origin of the long head of the biceps.

Enad⁴ presented two patients with a Y-shaped bifurcated origin in the supraglenoid tubercle and posterosuperior labrum. There was no connection with the rotator cuff. Both of these patients were treated for conditions of subacromial impact and acromioclavicular arthrosis, by means of distal decompression with distal excision of the clavicle. The origin of the biceps was not inflamed and did not appear to be diseased, and it was left intact in both cases.

There is a consistent association between congenital absence of the long head of the biceps and glenohumeral instability, and studies have shown that the long head of the biceps has a stabilizing role.⁸⁻¹⁰ Specifically, the long head of the biceps acts as a depressor of the head of the humerus and a dynamic stabilizer for the glenohumeral joint.

Our case report and most other published reports on cases of abnormal intra-articular origins for the long head of the biceps suggest that these anatomical variations are benign, without any evidence that these findings are pathological.

In this report on a rare case, we found a different anatomical origin for the long head of the biceps, in which it originated from the lower surface of the supraspinatus tendon, without originating in the supraglenoid tubercle or in the upper labrum.

This variant did not appear to contribute toward the pathological condition of the shoulder and concomitant standard treatment for the condition was sufficient to achieve a clinical improvement.

Conflicts of interest

The authors declare no conflicts of interest.

REFERENCES

1. Cooper DE, Amoczky SP, O'Brien SJ, Warren RF, DiCarlo E, Allen AA. Anatomy, histology, and vascularity of the glenoid labrum – an anatomical study. *J Bone Joint Surg Am.* 1992;74(1):46-52.

2. Vangsness CT Jr, Jorgenson SS, Watson T, Johnson DL. The origin of the long head of the biceps from the scapula and glenoid labrum – an anatomical study of 100 shoulders. *J Bone Joint Surg Br.* 1994;76(6):951-4.
3. Audenaert EA, Barbaix EJ, Van Hoonacker P, Berghs BM. Extraarticular variants of the long head of the biceps brachii: a reminder of embryology. *J Shoulder Elbow Surg.* 2008;17 Suppl. 1:114S-7S.
4. Enad JG. Bifurcate origin of the long head of the biceps tendon. *Arthroscopy.* 2004;20(10):1081-3.
5. Kim KC, Rhee KJ, Shin HD. A long head of the biceps tendon confluent with the intra-articular rotator cuff: arthroscopic and MR arthrographic findings. *Arch Orthop Trauma Surg.* 2009;129(3):311-4.
6. Kim KC, Rhee KJ, Shin HD, Kim YM. Biceps long head tendon revisited: a case report of split tendon arising from single origin. *Arch Orthop Trauma Surg.* 2008;128(5):495-8.
7. Hyman JL, Warren RF. Extra-articular origin of biceps brachii. *Arthroscopy.* 2001;17(7):E29.
8. Lang JE, Vinson EN, Basamania CJ. Anomalous biceps tendon insertion into the rotator cable: a case report. *J Surg Orthop Adv.* 2008;17(2):93-5.
9. Ghalayini SR, Board TN, Srinivasan MS. Anatomic variations in the long head of biceps: contribution to shoulder dysfunction. *Arthroscopy.* 2007;23(9):1012-8.
10. Ogawa K, Naniwa T. A rare variation of the biceps: a possible cause of degeneration of the rotator cuff. *J Shoulder Elbow Surg.* 1998;7(3):295-7.