



## Case Report

# Phaeohyphomycosis infection in the knee<sup>☆</sup>



David Sadigursky\*, Luisa Nogueira e Ferreira, Liz Moreno de Oliveira Corrêa

Hospital COT, Salvador, BA, Brazil

### ARTICLE INFO

#### Article history:

Received 22 March 2015

Accepted 28 April 2015

Available online 23 February 2016

#### Keywords:

Infection

Fungi

Knee

Dermatomyces

### ABSTRACT

Phaeohyphomycosis is caused by cutaneous fungi and rarely affects large joints. This is a case report on phaeohyphomycosis in the left knee of an elderly individual without immunosuppression. It was accompanied by pain and swelling the anterior knee. The case was first suspected to be suprapatellar bursitis, and was treated with nonsteroidal anti-inflammatory drugs, without remission of symptoms. Surgical treatment was performed, with resection of the suprapatellar bursa and anterior region of the quadriceps tendon. The material was sent for anatomopathological examination and culturing. The pathological examination showed phaeohyphomycosis. The treatment instituted consisted of itraconazole, 200 mg/day for six weeks, and complete remission of symptoms was achieved. The physical examination remained normal after one year of follow-up. This is the first published case of phaeohyphomycosis infection in the suprapatellar region of the knee. Although almost all the cases reported have been associated with immunosuppressed patients, this was an exception. It is important to suspect phaeohyphomycosis in cases of knee infection, in the area of the suprapatellar bursa, when the symptoms do not resolve after clinical treatment.

© 2016 Sociedade Brasileira de Ortopedia e Traumatologia. Published by Elsevier Editora Ltda. All rights reserved.

## Infecção por feohifomicose em joelho

### RESUMO

A feohifomicose, causada por fungos demáceos, raramente acomete grandes articulações. Este é um relato de caso de feohifomicose, em joelho esquerdo de idoso não imunossuprimido, acompanhado de dor e aumento de volume em região anterior do joelho. Suspeitou-se de bursite suprapatelar, sendo medicado com anti-inflamatório não esteroide, sem apresentar remissão dos sintomas. Fez-se tratamento cirúrgico, foram ressecadas a bursa suprapatelar e a região anterior do tendão do quadríceps sendo a peça encaminhada

#### Palavras-chave:

Infecção

Fungos

Joelho

Dermatomicoses

<sup>☆</sup> Work performed in the COT Hospital, Salvador, BA, Brazil.

\* Corresponding author.

E-mail: [davidsad@gmail.com](mailto:davidsad@gmail.com) (D. Sadigursky).

<http://dx.doi.org/10.1016/j.rboe.2016.02.004>

2255-4971/© 2016 Sociedade Brasileira de Ortopedia e Traumatologia. Published by Elsevier Editora Ltda. All rights reserved.

para exame anatomopatológico e cultura. No exame anatomopatológico foi possível evidenciar o diagnóstico de feohifomicose. O tratamento instituído foi itraconazol, 200 mg/dia por seis semanas, apresentando remissão completa do quadro. O exame físico se manteve normal após um ano de seguimento. Este é o primeiro caso publicado a respeito da infecção por feohifomicose em região suprapatelar. Apesar de quase todos os casos registrados estarem associados a pacientes imunossuprimidos, este foi uma exceção. É importante que se suspeite de feohifomicose nas infecções de joelho, na área da bursa suprapatelar, quando os sintomas não resolverem após o tratamento clínico medicamentoso.

© 2016 Sociedade Brasileira de Ortopedia e Traumatologia. Publicado por Elsevier Editora Ltda. Todos os direitos reservados.

## Introduction

Phaeohyphomycosis is the term used to describe infection caused by various species of dematiaceous fungi with blackish pigment, especially of the genera *Wangiella*, *Alternaria* and *Exophiala*.<sup>1-3</sup>

It is found in widely distributed in soil around the world. It is an uncommon cause of illness among humans, but may cause infections in both immunosuppressed and immunocompetent individuals.<sup>4</sup> Almost all the cases reported have been associated with immunosuppressed patients who have undergone organ transplantation or patients treated due to malignant growths.<sup>5</sup>

Cutaneous lesions and subcutaneous nodules are the commonest forms of presentation. Most infections are superficial and are preceded by local trauma.<sup>6</sup> This disease is only very rarely associated with infection in joints: only a single case has been reported so far, which was associated with tearing of a flexor tendon.<sup>7</sup>

Here, we report a case of phaeohyphomycosis in the left knee of a previously healthy patient who was not immunosuppressed.

## Report of clinical case

The patient was a 76-year-old man with a history of pain and edema in his left knee for around two months, with increased volume in the anterior region of the patella.

When he was first seen, he presented pain and increased volume in the anterior region of the knee and suprapatellar bursitis was suspected. He was medicated with a nonsteroidal anti-inflammatory drug. He came back seven days later, with increased volume and pain. The site was punctured and a thick secretion of purulent coloration with yellowish lumps was observed. He was medicated with an oral antibiotic because of suspected superficial infection. However, he came back two days later with recurrence of the edema and an increased state of pain.

The patient was admitted to hospital for surgical treatment consisting of drainage, resection and cleaning. During the operation, thick material of whitish and yellowish coloration was observed in a large quantity of friable solid lumps. The suprapatellar bursa and all the material in the anterior region of the quadriceps tendon was resected and sent for

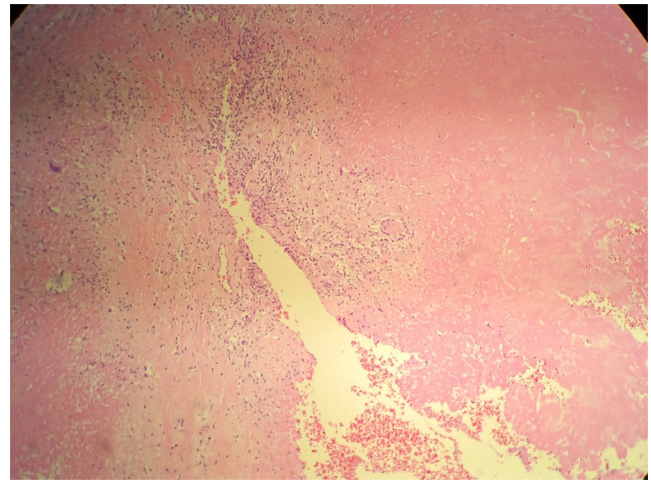


Fig. 1 – Anatomopathological examination.

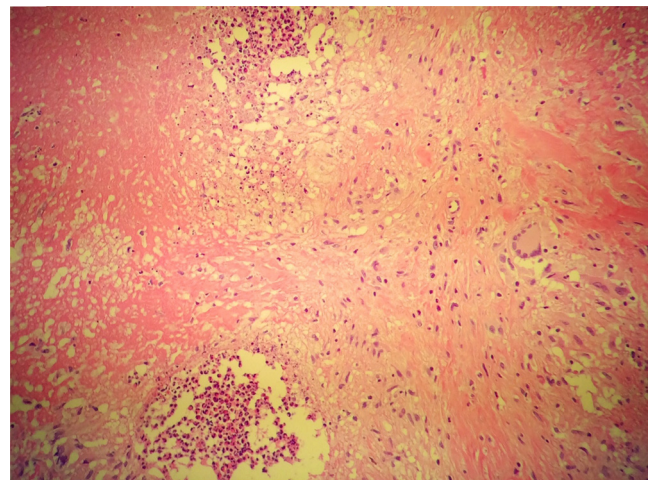
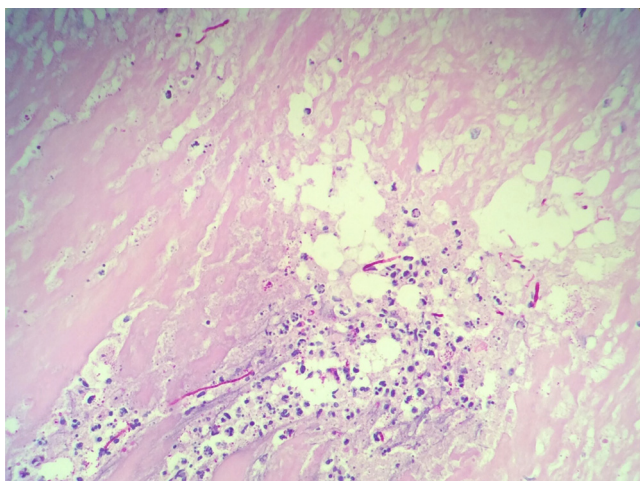


Fig. 2 – Anatomopathological examination.

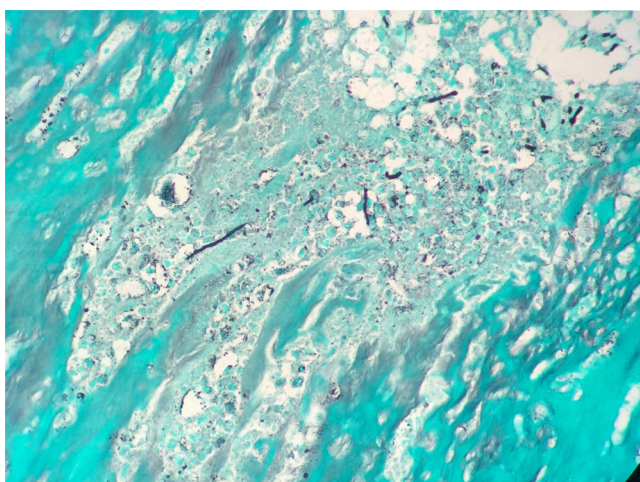
anatomopathological examination and culturing on four samples.

The result from the cultures was negative. However, the anatomopathological analysis showed phaeohyphomycosis, as demonstrated in Figs. 1-4.

The treatment instituted was itraconazole, 200 mg/day for six weeks, and complete remission from the condition was achieved by the end of this period.



**Fig. 3 – Anatomopathological examination.**



**Fig. 4 – Anatomopathological examination.**

The laboratory tests showed:

- Anti-*Histoplasma* antibodies: negative
- Hb: 14.1
- Leukocytes: 8800
- Platelets: 182,000
- VHS: 7
- Urea: 26; creatinine 0.9
- TGO: 17.3; TGP: 15.4; GGT: 14.5; FA: 139
- LDH: 281.9
- PPD: unreactive

The screening tests for inflammatory arthritis and immunosuppressive diseases were confirmed as normal. Regarding the patient's habits, he was not a smoker, alcohol abuser or drug user.

The physical examination remained normal after one year of follow-up, will full weight-bearing and complete range of motion. He was able to do routine activities without limitations.

## Discussion

The clinical case presented here is the first one published so far on infection due to phaeohyphomycosis in the knee. The infection was located in the suprapatellar region and resembled bursitis. In this case, the patient did not have any immunosuppressive diseases, unlike in the case presented by Chahal et al.,<sup>7</sup> in which the infection led to tearing of the flexor tendon. Moreover, the patient had HIV, was an alcoholic and a smoker.

Data on the incidence of phaeohyphomycosis are still scarce in the literature. In a study in San Francisco (USA), the incidence was 1:1,000,000 per year.<sup>8</sup>

The infection results from direct inoculation after trauma, cuts or wounds that are contaminated with earth, vegetation or decomposing wood.

Although almost all the cases recorded have been associated with immunosuppressed patients who had undergone organ transplantation or procedures to treat malignant growths, the presence of immunosuppression is not obligatory for the disease to appear, as was seen in our case.<sup>2,3,5,9</sup>

The location affected is preferentially the upper and lower limbs. The neck, face and buttocks are rarely affected.<sup>10</sup>

In a study on 72 patients, 76% presented fever and 33% cutaneous manifestations, including skin eruptions and ulcers. The commonest site of infection has been the lungs, which was seen in 33 (46%) of the 72 patients. This was followed by the heart, in 21 patients (29%); skin, in 19 (26%); brain, in 16 (22%); and kidneys, in 16 (22%). The liver, spleen, lymphatic ganglia, bones, joints and muscles have been less commonly reported as infection sites.<sup>5</sup>

The case of phaeohyphomycosis in the knee reported here is concordant with the literature, in that cases located in joints are rare.

To treat phaeohyphomycosis, drugs such as itraconazole, ketoconazole, fluconazole and flucytosine have frequently been used.<sup>5</sup> Itraconazole is the preferred drug.<sup>10</sup> In one study, the drug most used was amphotericin B, which was administered to 62 (97%) of the 64 patients who received antifungal therapy.<sup>5</sup>

Rare fungi of soils have pathogenic potential in chronic skin lesions and lead to formation of crusts and ulceration. In patients who have received transplants, they need to be taken into consideration in the differential diagnosis for invasive fungal infections, in immunocompromised patients.<sup>11</sup>

It is important to maintain a high degree of suspicion of phaeohyphomycosis in cases of infected tenosynovitis when the symptoms do not become resolved after irrigation, debridement and antibiotic therapy.<sup>7</sup>

Further studies on phaeohyphomycosis in joints should be conducted because of the scarcity of such information.

## Conflicts of interest

The authors declare no conflicts of interest.

## REFERENCES

1. Ferreira LM, Pereira RN, Diniz LM, Souza Filho JB. Caso para diagnóstico. *An Bras Dermatol*. 2006;81:291-3.
2. Cunha Filho RR, Schwartz J, Rehn M, Vettotato G, Resende MA. Feohifomicose causada por *Veronaea bothryosa*: relato de dois casos. *An Bras Dermatol*. 2005;80:53-6.
3. Silveira F, Nucci M. Emergence of black moulds in fungal disease: epidemiology and therapy. *Curr Opin Infect Dis*. 2001;14(6):679-84.
4. Revankar SG. Phaeohyphomycosis. *Infect Dis Clin North Am*. 2006;20(3):609-20.
5. Revankar SG, Patterson JE, Sutton DA, Pullen R, Rinaldi MG. Disseminated phaeohyphomycosis: review of an emerging mycosis. *Clin Infect Dis*. 2002;34(4):467-76.
6. Chowdhary A, Meis JF, Guarro J, de Hoog GS, Kathuria S, Arendrup MC, et al. ESCMID and ECMM joint clinical guidelines for the diagnosis and management of systemic phaeohyphomycosis: diseases caused by black fungi. *Clin Microbiol Infect*. 2014;20 Suppl 3:47-75.
7. Chahal J, Dhotar HS, Anastakis DJ. Phaeohyphomycosis infection leading to flexor tendon rupture: a case report. *Hand (N Y)*. 2009;4(3):335-8.
8. Rees JR, Pinner RW, Hajjeh RA, Brandt ME, Reingold AL. The epidemiological features of invasive mycotic infections in the San Francisco Bay area, 1992-1993: results of population-based laboratory active surveillance. *Clin Infect Dis*. 1998;27(5):1138-47.
9. Duvic M, Lowe L, Rios A, MacDonald E, Vance P. Superficial phaeohyphomycosis of the scrotum in a patient with the acquired immunodeficiency syndrome. *Arch Dermatol*. 1987;123(12):1597-9.
10. Rossetto AL, Dellatorre G, Pérsio RA, Romeiro JCM, Cruz RCB. Feohifomicose subcutânea por *Exophiala jeanselmei* localizada na bolsa escrotal - Relato de caso. *An Bras Dermatol*. 2010;85(4):517-20.
11. Gordon RA, Sutton DA, Thompson EH, Shrikanth V, Verkley GJ, Stielow JB, et al. Cutaneous phaeohyphomycosis caused by *Paraconiothyrium cyclothyrioides*. *J Clin Microbiol*. 2012;50(11):3795-8.