



## Technical Note

# Anatomical reconstruction of the anterior cruciate ligament: a logical approach



Julio Cesar Gali

Orthopedics and Traumatology Service, Faculdade de Ciências Médicas e da Saúde de Sorocaba, Pontifícia Universidade Católica de São Paulo (PUC-SP), Sorocaba, SP, Brazil

### ARTICLE INFO

#### Article history:

Received 4 July 2014

Accepted 8 July 2014

Available online 7 July 2015

#### Keywords:

Knee trauma/surgery  
Anterior cruciate ligament reconstruction  
Minimally invasive surgical procedures

#### Palavras-chave:

Traumatismos do joelho/cirurgia  
Reconstrução do ligamento cruzado anterior  
Procedimentos cirúrgicos minimamente invasivos

### ABSTRACT

We describe the surgical approach that we have used over the last years for anterior cruciate ligament (ACL) reconstruction, highlighting the importance of arthroscopic viewing through the anteromedial portal (AMP) and femoral tunnel drilling through an accessory anteromedial portal (AMP). The AMP allows direct view of the ACL femoral insertion site on the medial aspect of the lateral femoral condyle, does not require guides for anatomic femoral tunnel reaming, prevents an additional lateral incision in the distal third of the thigh (as would be unavoidable when the *outside-in* technique is used) and also can be used for double-bundle ACL reconstruction.

© 2014 Sociedade Brasileira de Ortopedia e Traumatologia. Published by Elsevier Editora Ltda. All rights reserved.

### Reconstrução anatômica do ligamento cruzado anterior: uma abordagem lógica

#### RESUMO

Descrevemos a abordagem cirúrgica que vimos usando nos últimos anos para a reconstrução do ligamento cruzado anterior (LCA) e destacamos a importância da visualização artroscópica pelo portal anteromedial e perfuração do túnel femoral por um portal anteromedial acessório, para que a reconstrução seja realmente anatômica. Essa via permite a observação direta da inserção femoral do LCA na face medial do côndilo femoral lateral, não necessita de guias para a criação do túnel femoral anatômico, dispensa a necessidade de incisão no terço distal e lateral da coxa, como é inevitável quando a perfuração do túnel femoral é feita *outside-in*, e permite, também, a reconstrução do LCA com dupla banda.

© 2014 Sociedade Brasileira de Ortopedia e Traumatologia. Publicado por Elsevier Editora Ltda. Todos os direitos reservados.

E-mails: [juliogali@globo.com](mailto:juliogali@globo.com), [juliogali@note.med.br](mailto:juliogali@note.med.br)

<http://dx.doi.org/10.1016/j.rboe.2015.06.014>

2255-4971/© 2014 Sociedade Brasileira de Ortopedia e Traumatologia. Published by Elsevier Editora Ltda. All rights reserved.

## Introduction

Some years ago, the technique most commonly used for reconstructing the anterior cruciate ligament (ACL) using a graft from the flexor tendons was via the transtibial route, with the femoral tunnel high in the intercondylar area.<sup>1</sup> However, a recent study that included 436 patients who underwent primary reconstruction of the ACL alone using an autologous graft showed that patients treated by means of the transtibial technique had a significantly higher likelihood of requiring repeated surgery in the same knee, in comparison with those treated by means of an anteromedial route.<sup>2</sup>

There is an overall tendency toward reconstructions that are anatomical in nature, since it is known that creation of non-anatomical tunnels may diminish joint mobility<sup>3</sup> and cause abnormal rotation of the knee during dynamic loading.<sup>4</sup>

Given that many authors call their reconstructions anatomical, a precise definition of what this means is needed. A reconstruction is anatomical when it seeks to functionally restore the ACL to its native dimensions, and to orientate the collagen and insertion sites, with the intention of reproducing the normal anatomy, restoring the kinematics and promoting long-term joint health.<sup>5</sup>

For greater accuracy in creating anatomical femoral tunnels, drilling them by means of an accessory anteromedial portal has been recommended.<sup>6</sup> The aim of this technical note was to describe a technique for anatomical reconstruction of the ACL, with arthroscopic viewing through the anteromedial portal and drilling of the femoral tunnel through the accessory anteromedial portal.

## Surgical technique

We made an oblique incision of around 4 cm, in the proximal and medial third of the lower leg, in order to diminish the likelihood of injury to the infrapatellar branch of the saphenous nerve.<sup>7</sup> Then, using an extractor, we removed the flexor tendons (gracilis and semitendinosus).

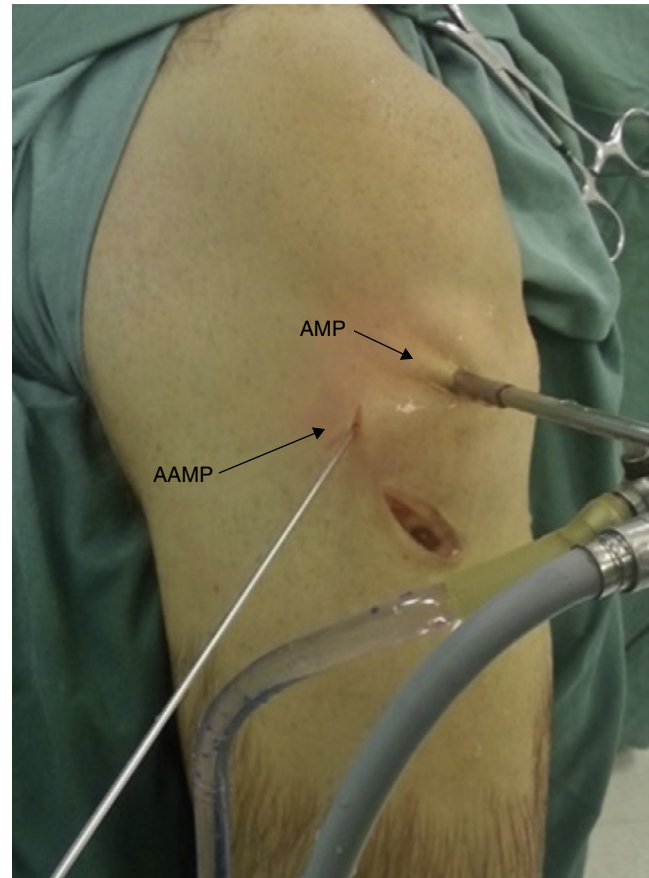
An assistant at an auxiliary table removed the remains of the muscles from the tendons and sectioned their proximal end so that they measured 18 cm. One of the ends of each of the tendons was passed into the loop of the Endobutton® and was sutured to its other end over a length of 3 cm, using com Vicryl 1. Also using Vicryl 1, we sutured the 3 cm of the graft closest to the loop of the Endobutton® to each other and, in the same way, to the other tip, so as to make a quadruple graft of 9 cm in length.

Two Ethibond 5 threads were passed through the orifices of one side of the Endobutton® and two Ethibond 2 threads through the orifices on the other side. The choice of Endobutton® loop size is determined by the length of the femoral tunnel, which is described below.

The anterolateral and anteromedial portals for arthroscopy were constructed adjacent to the lateral and medial borders of the patellar ligament, respectively. The anteromedial portal was opened at the level of the joint interline and the anterolateral portal was created slightly proximally to the joint interline.

Diagnostic arthroscopy was performed in order to treat any meniscal and/or chondral lesions, if these were present. To view the medial face of the lateral femoral condyle, we moved the optical device to the anteromedial portal.

The accessory anteromedial portal was established using a number 18 needle, under direct viewing, inferiorly and medially to the standard anteromedial portal (Fig. 1). Its positioning is critical for obtaining the correct pathway and determining the entry point for the femoral tunnel, so as to avoid injuring the surface of the medial femoral condyle and the medial meniscus, during the drilling.



**Fig. 1 – Demonstration of the anteromedial portal (AMP) (with the optical device) and accessory anteromedial portal (AAMP) (with guidewire).**

A bone pick, introduced through the accessory anteromedial portal, is used to demarcate the center of the femoral insertion of the ACL, at the junction of the insertions of its anteromedial and posterolateral bands, above the bifurcated crest.<sup>8</sup>

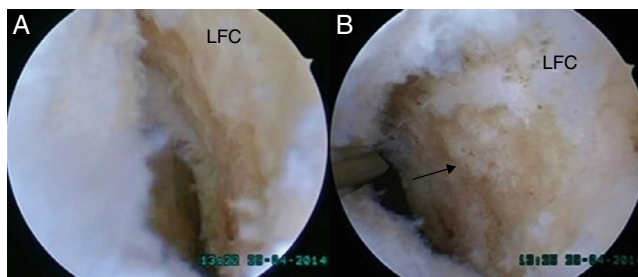
A guidewire of 2 mm in diameter was introduced through the accessory anteromedial portal and was placed at the location previously marked out by the bone pick. It was driven into the bone of the lateral femoral condyle for a few millimeters, by means of one or two hammer blows to its extra-articular end.

Following this, the guidewire was introduced by means of a drilling device, with the aim of crossing the lateral cortical bone of the lateral femoral condyle. For this drilling operation, the knee was flexed at 110°, in order to protect the common fibular nerve and so that the femoral tunnel could have greater length.<sup>9</sup>

A cannulated drill bit of 5 mm in diameter was placed around the guidewire and was used to create the femoral tunnel. The drill bit and guidewire were then removed and a measuring device was used to determine the length of the femoral tunnel. The diameter of the femoral tunnel needed to be the same as that of the graft.

The guidewire was put back into the accessory anteromedial portal and was inserted into the femoral tunnel, until it had gone beyond the cortical bone of the lateral femoral condyle. A drill bit of the same diameter as the graft should be used to increase the diameter of the preexisting tunnel, for a length that is 10 mm less than the total length of the tunnel, so that the Endobutton® could be upended.

The measurement of the Endobutton® loop should be no more than the difference between the length of the femoral tunnel and 15 mm, which is the minimum amount of soft-tissue graft inside



**Fig. 2 – (A) View through anterolateral portal; (B) view through anteromedial portal. The arrow indicates the intercondylar crest. LFC = lateral femoral condyle.**

the bone tunnels for union to occur between the bone and the graft.<sup>10</sup>

To construct the tibial tunnel, we used a drilling guide that was appropriate for the ACL, adjusted to the mark of 55°. This was introduced to the joint through the anteromedial portal, while the optical device was introduced through the anterolateral portal. The guide was placed on the tibia between the anteromedial and posterolateral bands, laterally to the medial intercondylar tubercle, in the same direction as the middle part of the anterior root of the lateral meniscus. The diameter of the drill bit for constructing the tibial tunnel was also the same as the diameter of the graft.

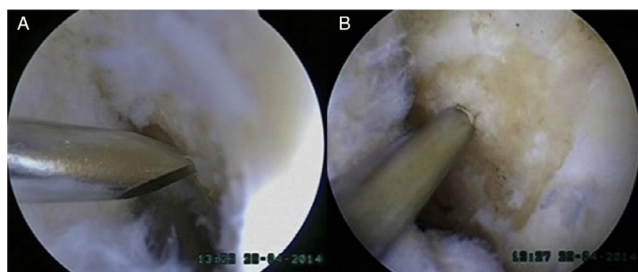
A drilling guidewire with Vicryl 1 thread placed in one of its orifices was passed through the accessory anteromedial portal, the femoral tunnel and the lateral skin of the thigh, while a double end of Vicryl 1 was kept inside the joint.

Next, this end was pulled into the tibial tunnel with the aid of a grasper or probe, and was brought to the external region of the lower leg.

The graft was lashed using Vicryl 1 and was passed through the tibial and femoral tunnels. Following this, the Endobutton was “upended”, which provided femoral fixation. We applied manual tensioning to the threads of the tibial end of the graft, with the knee flexed at 20°,<sup>11</sup> and we fixed the graft in the tibial tunnel using a metal interference screw or absorbable screw.

### Final comments

1. In our opinion, viewing through the anteromedial portal provides a clear view of the medial face of the lateral femoral condyle, with the possibility of a clearer view of the femoral



**Fig. 3 – (A) View through anterolateral portal, with guidewire placed in the anteromedial portal; (B) view through anteromedial portal, with guidewire placed in the accessory anteromedial portal.**

insertion of the ACL, in comparison with the view obtained through the anterolateral portal (Figs. 2 and 3).

2. This technique does away with the need for guides, since the insertion of the ACL is marked out by the surgeon, using a bone pick.
3. There is no need for an additional incision in the distal and lateral thigh, as would occur with the outside-in technique.
4. If the tunnels are constructed through the accessory anteromedial portal with due care, this does not cause any injury to the cartilage of the medial femoral condyle, or to the medial meniscus.
5. With this type of viewing, it is also possible to make reconstructions using other grafts, such as double-band, selective (augmentation) and those that preserve the remaining ligament.

### Conflicts of interest

The author declares no conflicts of interest.

### REFERENCES

1. Williams RJ 3rd, Hyman J, Petrigliano F, Rozental T, Wickiewicz TL. Anterior cruciate ligament reconstruction with a four-strand hamstring tendon autograft. *J Bone Joint Surg Am.* 2005;87 Suppl. 1 (Pt 1):51-66.
2. Duffee A, Magnussen RA, Pedroza AD, Flanigan DC, Kaeding CC. Transtibial ACL femoral tunnel preparation increases odds of repeat ipsilateral knee surgery. *J Bone Joint Surg Am.* 2013;95(22):2035-42.
3. Harner CD, Irrgang JJ, Paul J, Dearwater S, Fu FH. Loss of motion after anterior cruciate ligament reconstruction. *Am J Sports Med.* 1992;20(5):499-506.
4. Tashman S, Collon D, Anderson K, Kolowich P, Anderst W. Abnormal rotational knee motion during running after anterior cruciate ligament reconstruction. *Am J Sports Med.* 2004;32(4):975-83.
5. Van Eck CF, Lesniak BP, Schreiber VM, Fu FH. Anatomic single- and double-bundle anterior cruciate ligament reconstruction flowchart. *Arthroscopy.* 2010;26(2):258-68.
6. Fu FH, Shen W, Starman JS, Okeke N, Irrgang JJ. Primary anatomic double-bundle anterior cruciate ligament reconstruction: a preliminary 2-year prospective study. *Am J Sports Med.* 2008;36(7):1263-74.
7. Sabat D, Kumar V. Nerve injury during hamstring graft harvest: a prospective comparative study of three different incisions. *Knee Surg Sports Traumatol Arthrosc.* 2013;21(9):2089-95.
8. Ferretti M, Ekdahl M, Shen W, Fu FH. Osseous landmarks of the femoral attachment of the anterior cruciate ligament: an anatomic study. *Arthroscopy.* 2007;23(11):1218-25.
9. Gali JC, Oliveira HC, Ciâncio BA, Palma MV, Kobayashi R, Caetano EB. O comprimento dos túneis femorais varia com a flexão do joelho na reconstrução anatômica do ligamento cruzado anterior. *Rev Bras Ortop.* 2012;47(2):246-50.
10. Zantop T, Ferretti M, Bell KM, Brucker PU, Gilbertson L, Fu FH. Effect of tunnel-graft length on the biomechanics of anterior cruciate ligament-reconstructed knees: intra-articular study in a goat model. *Am J Sports Med.* 2008;36(2):2158-66.
11. Mae T, Shino K, Nakata K, Toritsuka Y, Otsubo H, Fujie H. Optimization of graft fixation at the time of anterior cruciate ligament reconstruction. Part II: effect of knee flexion angle. *Am J Sports Med.* 2008;36(6):1094-100.