



Case Report

Femoral pseudoaneurysm as a complication of slipped capital femoral epiphysis treatment[☆]



Carlos Roberto Schwartzmann^{a,b,*}, João Pedro Farina Brunelli^b,
Gabriel Severo da Silva^b, Silvio Coelho^b

^a Departamento de Ortopedia e Traumatologia, Universidade Federal de Ciências da Saúde de Porto Alegre, Porto Alegre, RS, Brazil

^b Serviço de Ortopedia e Traumatologia, Santa Casa de Porto Alegre, Porto Alegre, RS, Brazil

ARTICLE INFO

Article history:

Received 24 January 2017

Accepted 6 March 2017

Available online 6 December 2017

Keywords:

Aneurysm/etiologia

Orthopedic pinning/adverse effects

Slipped epiphysis

Femoral artery/injuries

Femur head/surgery

ABSTRACT

Slipped capital femoral epiphysis is a very frequently seen condition in orthopedics centers worldwide. Even in successfully treated cases, complications related either with the pathology *per se* or with the chosen synthesis method are not rare.

This report presents a case of bilateral slipped capital femoral epiphysis treated with pinning, in which one of the limbs developed a very rare condition: the formation of a femoral pseudoaneurysm that ruptured.

© 2017 Sociedade Brasileira de Ortopedia e Traumatologia. Published by Elsevier Editora Ltda. This is an open access article under the CC BY-NC-ND license (<http://creativecommons.org/licenses/by-nc-nd/4.0/>).

Pseudoaneurisma femoral como complicação do tratamento cirúrgico de epifisiólise proximal do fêmur

RESUMO

A epifisiólise proximal da cabeça femoral é uma patologia frequentemente tratada em centros de ortopedia. Mesmo nos casos de tratamento bem-sucedido, complicações relacionadas tanto ao fenômeno em si quanto à síntese escolhida não são raras. Os autores relatam um caso de epifisiólise da cabeça femoral bilateral, submetido a pinagem, que evoluiu com uma complicação raríssima em um dos membros: a formação de um pseudoaneurisma femoral, com posterior rotura.

© 2017 Sociedade Brasileira de Ortopedia e Traumatologia. Publicado por Elsevier Editora Ltda. Este é um artigo Open Access sob uma licença CC BY-NC-ND (<http://creativecommons.org/licenses/by-nc-nd/4.0/>).

Palavras-chave:

Aneurisma/etiologia

Pinos ortopédicos/efeitos adversos

Epífise deslocada

Artéria femoral/lesões

Cabeça do fêmur/cirurgia

[☆] Study conducted at the Serviço de Ortopedia e Traumatologia, Santa Casa de Porto Alegre, Porto Alegre, RS, Brazil.

* Corresponding author.

E-mail: schwartzmann@santacasa.tche.br (C.R. Schwartzmann).

<https://doi.org/10.1016/j.rboe.2017.11.012>

2255-4971/© 2017 Sociedade Brasileira de Ortopedia e Traumatologia. Published by Elsevier Editora Ltda. This is an open access article under the CC BY-NC-ND license (<http://creativecommons.org/licenses/by-nc-nd/4.0/>).

Introduction

Complications of treatment for proximal epiphysiolysis of the femoral head are frequent.¹

These include osteonecrosis (directly associated with the degree of stability of the lesion and with the surgical procedure), chondrolysis (a multifactorial and not fully understood condition, which can occur whether or not the disease is treated), femoroacetabular impact, and fixation failure with progression of the epiphyseal displacement.^{1,2}

The authors report a very rare complication that required a rapid and effective approach – the formation of a pseudoaneurysm associated with epiphyseal perforation by the screw, with injury and partial traumatic rupture of the femoral artery forming an extensive pulsatile hematoma in the thigh.

Case report

A 14-year-old male patient admitted to this hospital's emergency room reported pain, inability to ambulate, and increased volume in the upper right thigh (Fig. 1).

Symptoms began two weeks prior, with no history of trauma.

A progressive worsening of the condition was observed during that period. The patient's medical history indicated that he had undergone surgical treatment for proximal

femoral epiphysiolysis on the left side three years before. On the right side, the same procedure had been performed four months previously: single screw pinning.

On physical examination, an extensive volume increase in the proximal region of the right thigh was observed. It was warm on palpation, and at first it was thought to be an abscess. Upon closer examination, it was observed that the mass was pulsatile, and there was a tremor on palpation and bruit on auscultation.

A puncture was made with a 7-gauge needle, and a strong stream of arterial blood was observed (Fig. 2).

After tamponading the bleeding, the vascular surgery team of the hospital was immediately called. The patient was admitted to hospital and prepared for surgical exploration of the hematoma by the orthopedic and vascular teams. In the intraoperative period, the head of the partially extruded screw of the epiphysis could be observed in the middle of the hematoma, together with lesion and formation of a femoral pseudoaneurysm. The screw was removed and the vascular lesion was repaired, with satisfactory results and without complications (Fig. 3). The patient returned to the outpatient clinic several times; after six weeks, he was capable of normal and painless gait, and presented normal peripheral pulses (Figs. 4 and 5).

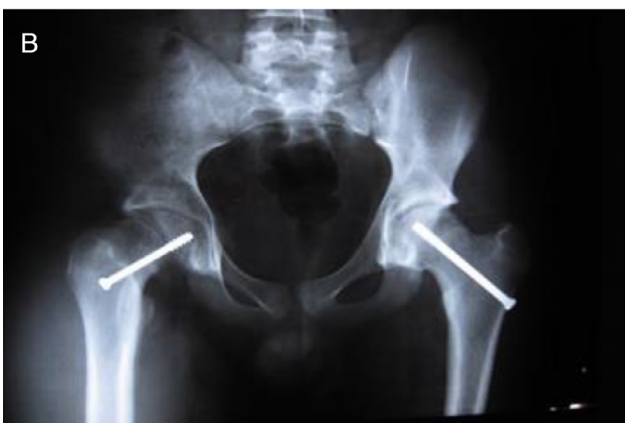
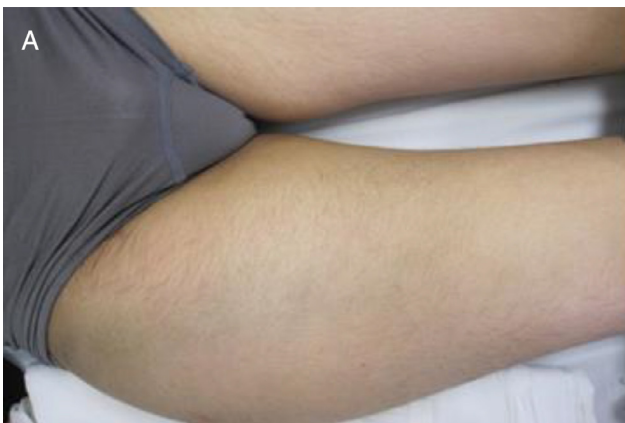
Fig. 1 – (A) Initial clinical image of the patient showing volume increase in the upper thigh; (B) radiographic image of the pelvis on admission to hospital.

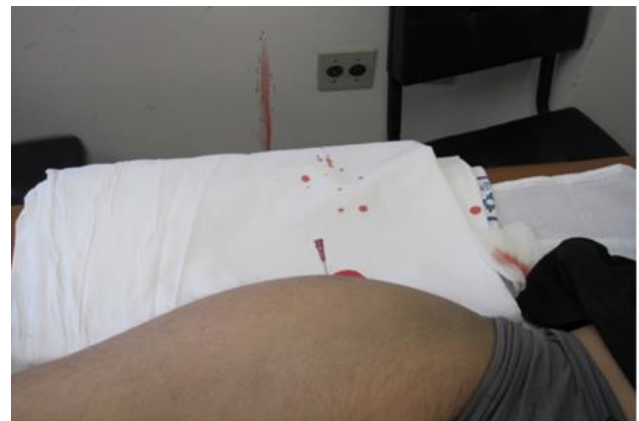

Fig. 2 – Thigh puncture, with a large quantity of blood freed under pressure.

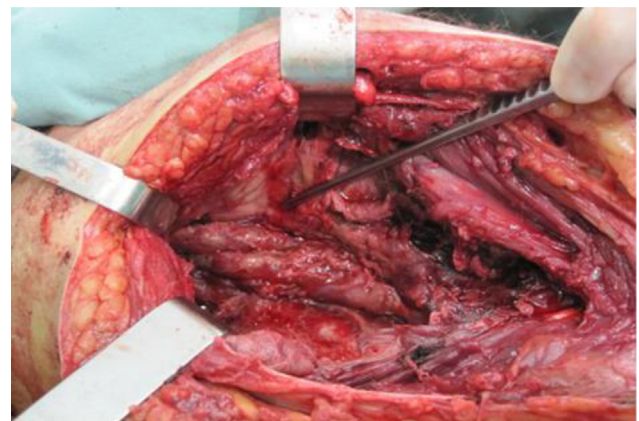


Fig. 3 – Intraoperative image showing the tip of the screw that perforated the articular cartilage and injured the femoral artery, and also shows the formation of pseudoaneurysm.

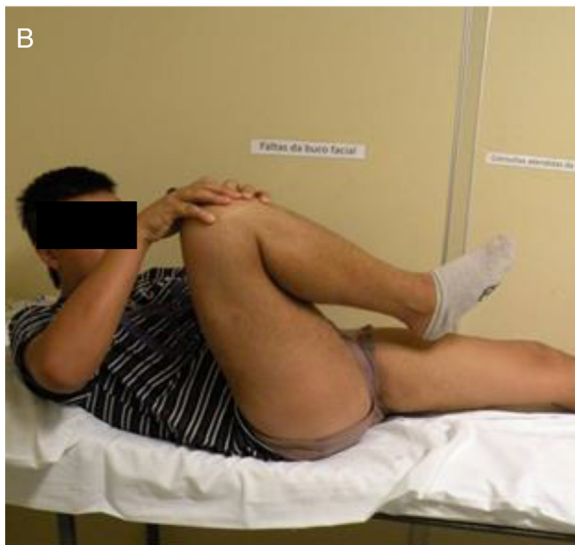
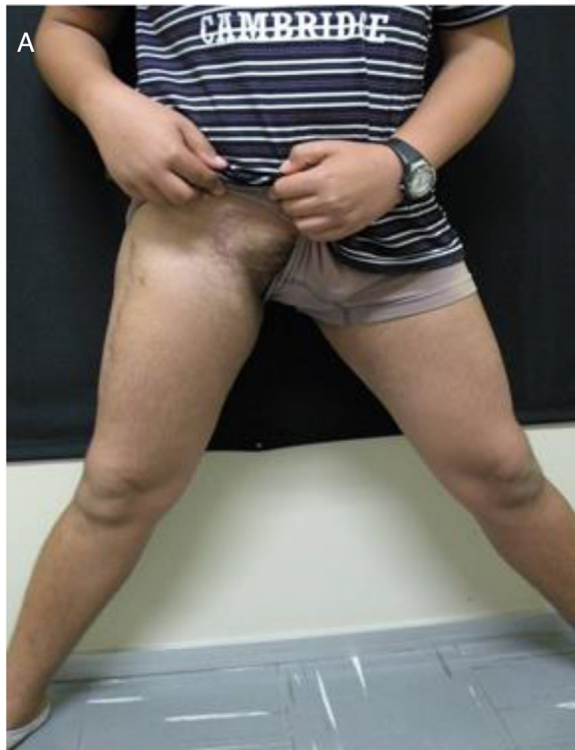
Fig. 4 – (A) Clinical aspect of the patient after six weeks, showing normal abduction; (B) hip flexion with a positive Drehmann's sign.

Discussion

The primary goals of the treatment of proximal femoral epiphysiolysis are to eliminate pain, maintain the anatomical relationship of the femoral neck and head, prevent future slip progression, and promote epiphysiodesis.^{1,2}

The secondary objectives are to avoid the complications inherent to the pathology and to reduce the risks of early degenerative alterations.

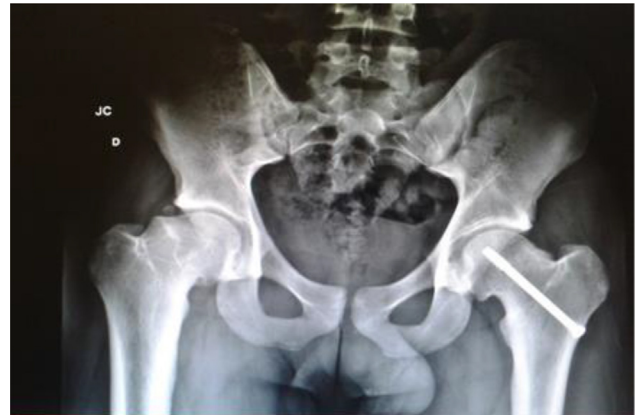

Fig. 5 – Radiographic image of the pelvis six weeks after arterial repair and screw removal.

The gold standard of treatment is *in situ* fixation with a single screw.³ Biomechanical studies have demonstrated that the use of two screws leads to a more stable fixation; However, most orthopedic surgeons prefer to use of a single screw to avoid the risk of head perforation and subsequent chondrolysis.^{3,4}

Femoral neck osteotomy (Dunn) is able to perfectly restore hip anatomy, but the risk of necrosis can be over 20%.^{5,6}

Other controversies in treatment regard contralateral fixation and the period of time until weight-bearing is allowed.^{1,3}

The most common complications are chondrolysis, osteonecrosis, femoroacetabular impingement, and secondary arthrosis.³

The present report demonstrated a very rare complication: the formation of pseudoaneurysm of the femoral artery by a screw used *in situ* fixation.

Conflicts of interest

The authors declare no conflicts of interest.

REFERENCES

- Loder RT, Dietz FR. What is the best evidence for the treatment of slipped capital femoral epiphysis? *J Pediatr Orthop.* 2012;32 Suppl. 2:S158-65.
- Senthi S, Blyth P, Metcalfe R, Stott NS. Screw placement after pinning of slipped capital femoral epiphysis: a postoperative CT scan study. *J Pediatr Orthop.* 2011;31(4):388-92.
- Johari AN, Pandey RA. Controversies in management of slipped capital femoral epiphysis. *World J Orthop.* 2016;7(2):78-81.
- Jones JR, Paterson DC, Hillier TM, Foster BK. Remodeling after pinning for slipped capital femoral epiphysis. *J Bone Jt Surg Br.* 1990;72(4):568-73.
- Sankar WN, Vanderhave KL, Matheney T, Herrera-Soto JA, Karlen JW. The modified Dunn procedure for unstable slipped capital femoral epiphysis: a multicenter perspective. *J Bone Jt Surg Am.* 2013;95(7):585-91.
- Slongo T, Kakaty D, Krause F, Ziebarth K. Treatment of slipped capital femoral epiphysis with a modified Dunn procedure. *J Bone Jt Surg Am.* 2010;92(18):2898-908.