



Thoracoscopic Surgery in the Management of Idiopathic Scoliosis: Systematic Literature Review according to the Prisma Protocol

Cirurgia toracoscópica na abordagem da escoliose idiopática: Revisão sistemática de literatura

Rodrigo Ibrahim Aziz¹ Juliano Boemo Blattes¹

¹ Resident doctor at the Nossa Senhora das Graças Hospital, Canoas, Rio Grande do Sul, Brazil

Address for correspondence Rodrigo Ibrahim Aziz, Rua Lagunenses 101, Apartamento 101, Torre A. Canoas, Rio Grande do Sul (e-mail: docroaziz@gmail.com).

Rev Bras Ortop 2023;58(6):e833–e838.

Abstract

Idiopathic scoliosis is a three-dimensional spinal deformity with axial rotation and lateral inclination with an angle greater than 10° per the Cobb method. The approach to idiopathic scoliosis can be conservative or surgical, depending on the degree of angulation, musculoskeletal development, and age of the child or adolescent. It also depends on the functional impairment resulting from the condition. This study aimed to analyze the impact of video-assisted thoracoscopic surgery in idiopathic scoliosis management. This systematic literature review followed the Preferred Reporting Items for Systematic Reviews and Meta-Analyses (PRISMA) protocol, and its PROSPERO registration number is CRD42022351466. Studies queries occurred from August to September 2022 in the bibliographic databases MEDLINE, The Cochrane Library, and Web of Science. The video-assisted thoracoscopic surgery is a minimally invasive alternative to thoracotomy with significant evolution in recent years. Its main advantages include lower blood loss during the procedure, shorter hospital stays, and improved post-surgical esthetics. Authors mentioned its disadvantages as greater complexity and technological requirement, longer surgical time, and the need for careful selection of the patients per vertebral deviation degree. The use of analgesic and anti-inflammatory drugs was not significantly different between traditional procedures (thoracotomy) and thoracoscopic surgery.

Keywords

- ▶ scoliosis
- ▶ thoracoscopic
- ▶ minimally invasive surgery

Study developed at the Nossa Senhora das Graças Hospital, Canoas, RS, Brazil.

received
September 6, 2022
accepted
November 23, 2022

DOI <https://doi.org/10.1055/s-0043-1776885>.
ISSN 0102-3616.

© 2023. Sociedade Brasileira de Ortopedia e Traumatologia. All rights reserved.

This is an open access article published by Thieme under the terms of the Creative Commons Attribution-NonDerivative-NonCommercial-License, permitting copying and reproduction so long as the original work is given appropriate credit. Contents may not be used for commercial purposes, or adapted, remixed, transformed or built upon. (<https://creativecommons.org/licenses/by-nc-nd/4.0/>)

Thieme Revinter Publicações Ltda., Rua do Matoso 170, Rio de Janeiro, RJ, CEP 20270-135, Brazil

Resumo

A escoliose idiopática é caracterizada por um quadro de deformidade tridimensional da coluna vertebral com rotação axial e inclinação lateral com angulação maior que 10° segundo o Método de Cobb. Sua abordagem pode se dar de maneira conservadora ou cirúrgica, a depender do grau de angulação, desenvolvimento osteomuscular e idade da criança ou adolescente acometido, ou ainda, a depender do comprometimento funcional advindo da condição. O objetivo deste estudo foi analisar o impacto da videotoracoscopia na abordagem da escoliose idiopática. Trata-se de uma revisão sistemática de literatura, construída conforme protocolo *Preferred Reporting Items for Systematic Reviews and Meta-Analyses (PRISMA)* e registrada no PROSPERO sob número CRD42022351466. A busca por estudos foi realizada entre agosto de 2022 e setembro do mesmo ano, em bancos de dados bibliográficos incluindo MEDLINE, *The Cochrane Library* e *Web of Science*. A técnica é uma alternativa minimamente invasiva à toracotomia que apresentou grande evolução nos últimos anos. Destacam-se como principais vantagens a menor perda sanguínea durante procedimento, menor tempo de internação e melhora da estética pós-cirúrgica. Uma das desvantagens citadas pelos autores é a maior complexidade e exigência tecnológica, maior tempo cirúrgico e necessidade de seleção criteriosa dos pacientes, conforme graus de desvio vertebral. O uso de analgésicos e anti-inflamatórios não teve diferença significativa entre os procedimentos tradicionais (toracotomia) ou videotoracoscopia.

Palavras-chave

- ▶ escoliose
- ▶ toracoscopia
- ▶ cirurgia minimamente invasiva

Introduction

The Scoliosis Research Society (SRS) defines scoliosis as the lateral curvature of the spine with a Cobb angle greater than 10° in an anteroposterior radiograph with the patient in orthostasis.^{1,2}

Idiopathic scoliosis has a multifactorial etiology involving deficits in postural control by the central nervous system (CNS), hormonal components, polygenic inheritance, biomechanical spinal disorders, anomalous skeletal muscle conditions, and collagen disturbances.^{3,4} The therapeutic management of idiopathic scoliosis is extremely complex. The medical approach selection relies on the angular values of the spinal curvatures, progressiveness level, and skeletal maturation. Curvatures between 10° and 25° are described as “observational;” those ranging from 25° to 40° usually require a cast or corrective orthoses,¹ and curvatures higher than 40° to 45° are eligible for surgical approach.^{5,6}

Historically, the surgical approach is instrumented arthrodesis, with fixation of each vertebral segment by the posterior bone consolidation per se. Although there are several available methods, the Lea Plaza framework stands out. This method has been used for over 20 years and allows a three-dimensional and segmental correction. The Lea Plaza framework brings each vertebra to the midline using wires under the deviated vertebral lamina which are tethered to the implants. Next, arthrodesis is performed with a bone graft in the entire area to be fused with an iliac crest autograft or allograft.⁷

The advancement of surgical techniques resulted in several new approaches proposed to manage idiopathic scoliosis, such as magnetically controlled growth rods⁶ and

minimally invasive surgeries that seek to increase the quality of life, individualize treatment, and reduce the risks associated with traditional surgery.⁸⁻¹⁰

Mack et al.¹¹ were the first to describe video-assisted thoracoscopy, or video-assisted thoracic surgery, in 1993 to approach injuries in the thoracic spinal segments. According to these authors, the patients receive endotracheal anesthesia with a double-lumen tube for ipsilateral lung collapse. Next, patients are put in lateral recumbency and undergo unilateral mechanical ventilation. A 10-mm incision is made in the midaxillary line. The incision's height varies according to the spinal level accessed at the initial exploratory thoracoscopy. Then, a second trocar is placed. Most surgeries use three to four open trocars, not requiring carbon dioxide insufflation. At the end of the procedure, the lung is expanded under direct visualization, and radiography assesses lung expansion and the chest drain location.

The technique is a minimally invasive alternative to thoracotomy, and it may be performed with posterior and anterior spinal fusion at the same surgical time or in a staged manner.^{12,13} This study analyzes the impact of video-assisted thoracoscopy in idiopathic scoliosis management.

Materials and Methods

This systematic literature review followed the Preferred Reporting Items for Systematic Reviews and Meta-Analyses (PRISMA) protocol, and its PROSPERO registration number is CRD42022351466.

Studies queries occurred between August and September 2022 in the bibliographic databases MEDLINE, The Cochrane Library, and Web of Science.

We selected studies published from January 2017 to August 2022 in English, Portuguese, and Spanish. Before the final analysis, we redid the queries to identify any other studies for potential inclusion. Unpublished studies were not included. The condition or domain studied was idiopathic scoliosis and its correction by video-assisted thoracoscopy.

The main questions of the study were the following:

- Which is the impact of thoracoscopy in approaching idiopathic scoliosis?
- Which are the risks associated with thoracoscopy for idiopathic scoliosis?
- Which are the advantages of thoracoscopy for idiopathic scoliosis?
- Which are the disadvantages of thoracoscopy for idiopathic scoliosis?

Inclusion criteria were studies on constructs for children and adolescents with idiopathic scoliosis treated with thoracoscopic surgical procedures. Studies addressing scoliosis in adults and elderlies were excluded from the search.

We analyzed the applicability of thoracoscopy in idiopathic scoliosis management, eligibility criteria for the procedure, associated risks and benefits, a correlation between the procedure and postoperative functionality, and postoperative length of stay.

Two independent reviewers applied the eligibility criteria and selected the studies for inclusion in the systematic review. The researchers were blinded to the decisions of their peer. We gathered information on study design, study methodology, participant demographics (age, gender), and baseline characteristics (scoliosis degree, previous surgeries).

We used the Systematic Review Data Repository-Plus software and the Cochrane risk of bias tool to improve reliability. Outcomes synthesis was qualitative, including a combination of data from individual studies on benefits, risks, or both associated with thoracoscopy for idiopathic scoliosis correction.

Results

The search criteria and study selection identified 15 constructs for discussion. ►**Fig. 1** shows the process of study screening following the PRISMA methodology.

Discussion

It is a consensus in the literature that the development of new surgical techniques resulted in excellent outcomes in idiopathic scoliosis management. Surgical indication relies on a pathological curvature above 45°, functional restriction, and pain complaints.¹⁴

The standard thoracotomy approach consists of a posterolateral incision extending from the anterior axial line to the scapular region. In addition, the technique involves the division of the serratus anterior and latissimus dorsi muscles, which can lead to long thoracic nerve injury and muscle atrophy.^{15,16} Although modern thoracotomy techniques in the pediatric population try to spare critical muscles and not

resect the costal arches, functional and operative risks remain significant aspects to consider when selecting a procedure.¹⁷

Thus, the traditional surgical techniques for idiopathic scoliosis include release and open anterior instrumentation, posterior instrumentation, and thoracoscopic approaches.¹⁸ The magnitude, flexibility, and type of curvature determine the selection for thoracoscopic instrumentation. In all these surgeries, patients were in lateral recumbency, with the convex side of the thoracic curve placed superiorly. The authors used three to six portals to access the spine, performing a previous discectomy for subsequent screw insertion. The incisions were usually 2 to 3 cm long in the midaxillary line over the 3rd, 5th, 7th, and 9th ribs, or the 4th, 6th, 8th, and 10th ribs, depending on rib inclination and the trajectory of the instrumented vertebrae.^{17–20}

In skeletally immature children and a high degree of curvature, a major challenge is to perform surgery for scoliosis correction without limiting growth. In these cases, spinal fusion is not ideal, as it would limit thoracic growth and contribute to long-term lung impairment. Spinal fusion surgeries are often described in adolescents. Other options, such as magnetically controlled growth rods and expandable prostheses, have been described in younger children, even though adolescents may also benefit from such technologies.^{18,21} A retrospective cohort study assessed the impact of thoracoscopic surgery on 28 female adolescents with idiopathic scoliosis. The authors point out that, in addition to the biomechanical results, a significant aesthetic concern for patients is the anterior chest wall deformity. The thoracoscopic procedure improved the scoliotic condition, resulting in a lower anterior chest wall deformity. This study considered the following deformity parameters: the Cobb angle, rib hump, chest wall angle, and posterior apical deformity angle.¹⁹

Most studies described successful vertebral fusion and instrumentation performed thoracoscopically for idiopathic scoliosis management. However, Wong et al.²⁰ described a thoracoscopic technique for anterior vertebral body tethering, performing scoliosis correction with no need for vertebral fusion. The patients ($n = 5$) were 9 to 12 years old and had a mean preoperative main thoracic Cobb angle of 40.1°. Magnetic resonance imaging showed improvement in periapical disc wedge morphology and a 55% improvement in rotation in 3 years. However, two patients required a new corrective procedure with posterior spinal fusion, also thoracoscopically. It is worth noting that the authors considered the thoracoscopic method safe, both for the vertebral fusion technique and the vertebral body tethering.^{17,19,20}

Crawford e Lenke²² described the vertebral body tethering in 2010 resulting in growth modulation and progressive correction of the juvenile idiopathic scoliosis. Costanzo et al.²³ indicated the video-assisted thoracoscopy for vertebral body tethering in pre-adolescents with a scoliosis degree above 40°. All patients presented scoliosis reduction and significant functional gains.

In a retrospective study comparing posterior spinal fusion with anterior vertebral body tethering via thoracoscopic approach, both techniques resulted in postoperative correction; however, 2 years after the procedure, the scoliosis

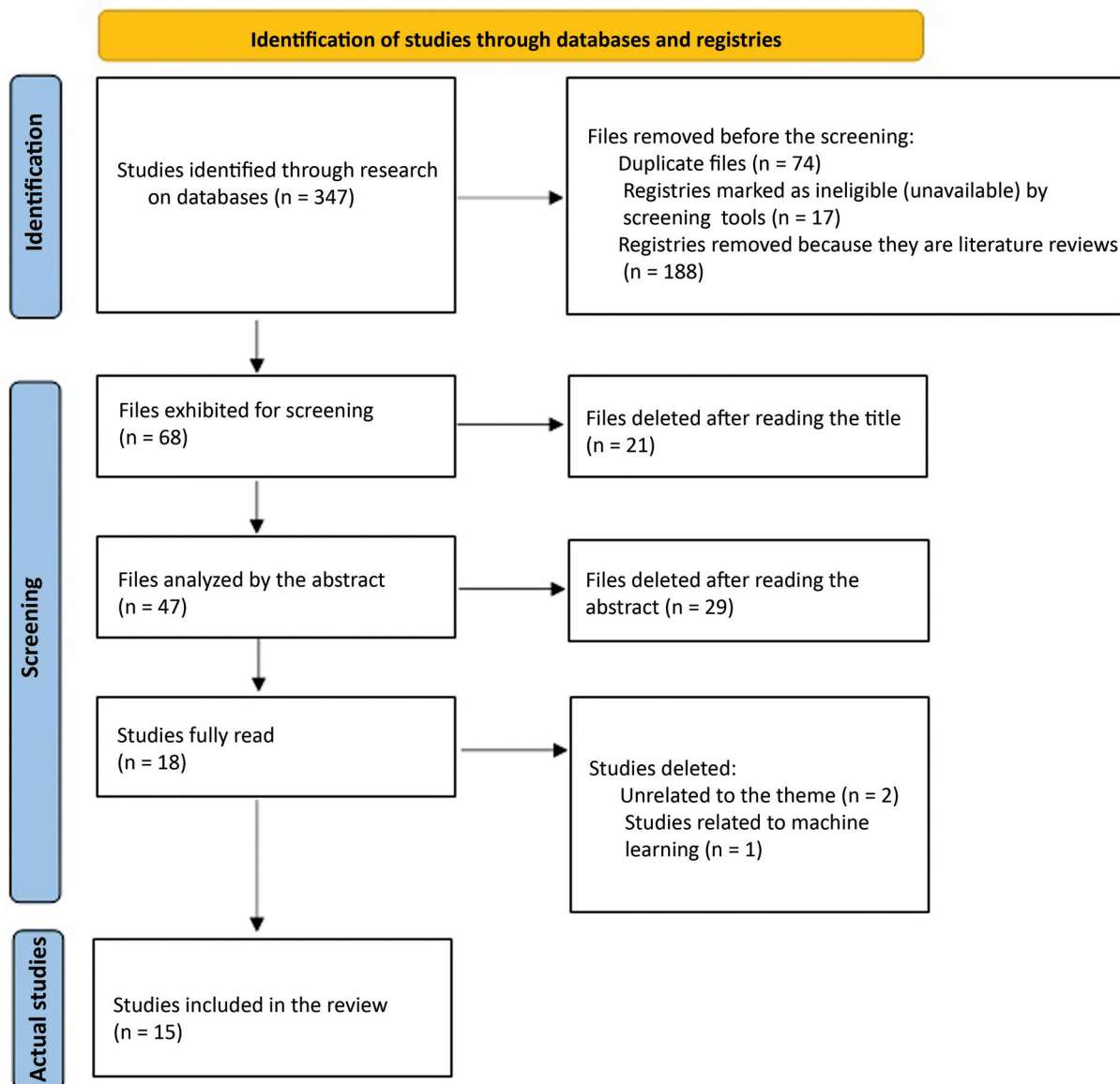


Fig. 1 Study selection process following the PRISMA protocol.

outcome was better in the group undergoing spinal fusion. It is worth noting patients undergoing thoracoscopic surgery and vertebral bodies tethering could postpone the posterior spinal fusion. This can be extremely beneficial in younger patients with immature skeletal development although the posterior vertebral fusion, even in an open surgery, is the gold standard for the definitive treatment of scoliosis with an angle greater than 45° .²⁴

In skeletally immature individuals with idiopathic scoliosis, the thoracoscopic vertebral body tethering results in a satisfactory deformity correction and has an acceptable rate of complications.²⁵ In a study with 57 patients with a mean age of 12.7 years, the revision surgery rate was 15.8%. Patients with a coronal Cobb angle greater than 35° were considered clinical successes; their average curvature was 51° preoperatively and 24.6° at the first follow-up visit post-surgery. These subjects presented an average curvature of 16.3° 1 year after the procedure.²⁶

Rushton et al.²⁷ obtained similar results when 112 patients with a mean age of 12.7 ± 1.4 years underwent thoracoscopy and vertebral body tethering. The average curvature before the procedure was $50.8^\circ \pm 10.2$, whereas the average postoperative curvature was $26.6^\circ \pm 10.1$. In this study, the revision surgery rate was 13%. The main complication was tethering rupture (22%), leading the authors to emphasize the need to develop better implants and improve the criteria for patient selection.

In a retrospective analysis of 5 years, including 20 patients aged 9 to 17 years old, the success rate was high (95%) after the follow-up period. The last Cobb angle on radiography at a mean follow-up of 5 years was 19.4° ; in contrast, the average angle before the procedure was 47.4° (40° to 58°). Although the sample was small, the study reports that 5% of the patients required posterior fusion, which would be an extremely acceptable rate and validate the thoracoscopic vertebral body tethering.²⁸ A similar study with 27 patients

Table 1 Advantages and disadvantages listed in the literature for the surgical techniques for idiopathic scoliosis correction.

	Thoracoscopy	Thoracotomy
Advantages	<ul style="list-style-type: none"> - Lower bleeding and exposure to infections - Provides surgical access for definite interventions, including vertebral fusion or vertebral body wiring. - Effective scoliosis correction - Higher anterior and lateral lumbar flexibility and better truncal flexion compared with vertebral fusion 	<ul style="list-style-type: none"> - Remains the gold standard in idiopathic scoliosis with an angle higher than 45° - Lower rate of revision surgeries - Effective scoliosis correction
Disadvantages	<ul style="list-style-type: none"> - Longer surgical time - May require procedural revision and evolution to open surgery 	<ul style="list-style-type: none"> - Higher bleeding - Higher risk of infections - Small children may not be candidates for the procedure due to skeletal immaturity

Source: Authors (2022).

undergoing a thoracoscopic procedure and vertebral body tethering had a success rate of 74%, with an overall revision rate of 21%. Tethering rupture was the main documented complication; in addition, it was suspected in 48% of the subjects. However, in some cases, the tethering rupture was not decisive to compromise the outcomes, and the scoliosis angle satisfactorily regressed. Spinal fusion was avoided in 93% of patients.²⁹ On the other hand, Hegde et al.³⁰ used thoracoscopy and vertebral body tethering in skeletally mature children with a mean age of 14.9 ± 2.7 years at the time of surgery. The mean preoperative Cobb angle was 52.0° ± 11.6° and 15.9° ± 6.8° on the first postoperative radiograph. There were no complications or the need for further surgical intervention. These outcomes suggested that the technique is an alternative to fusion for stabilizing progressive idiopathic scoliosis in skeletally mature children.

Pehlivanoglu et al.³¹ conducted another study supporting the relevance of thoracoscopy and vertebral body tethering. These authors compared scoliosis correction and the functional degree of patients undergoing vertebral fusion by thoracotomy or vertebral bodies tethering via thoracoscopy. Both techniques were effective in correcting adolescent idiopathic scoliosis. However, the thoracoscopy group showed an improved superior lumbar range of motion, superior anterolateral lumbar flexion flexibility, superior trunk flexor and extensor resistance, and superior mean motor strength of trunk muscles with a high statistical significance compared with those who underwent a spinal fusion, directly affecting the quality of life and functionality.

► **Table 1** summarizes the advantages and disadvantages of the thoracoscopic and thoracotomy approaches. It is worth noting that the thoracoscopic approach is a surgical approach to address scoliosis using bone grafts with subsequent vertebral fusion but may also be an approach for vertebral body tethering; this second technique was the most frequently mentioned.

Final Considerations

Posterior spinal fusion is the gold standard technique for the surgical correction of idiopathic scoliosis. It is worth noting that surgical management is indicated in severe cases, characterized by an angle greater than 45° in the postural

deviation. However, this technique is controversial because it limits growth and movement, and there are reports in the literature addressing chronic pain years after the correction.

With the advancement of surgical techniques, thoracoscopy has emerged as a therapeutic option for scoliotic patients. It allows the placement of a bone graft for fusion and vertebral body tethering, which would be better for younger children still presenting bone growth.

Most studies reported the thoracoscopic approach as safe and effective in idiopathic scoliosis. Vertebral body tethering would be a viable option for younger subjects; in contrast, the spinal fusion technique would be suitable for skeletally mature adolescents.

The thoracoscopic approach also has an advantage when analyzing bleeding risks, infection risks, and lengths of stay. However, surgical time tends to be longer than open surgery. This is especially true in vertebral body tethering, which is associated with a higher number of reinterventions and the need for future open surgery.

Note

The paper “Thoracoscopic Surgery in the Management of Idiopathic Scoliosis: Systematic Literature Review according to the Prisma Protocol” is a systematic review using the PRISMA protocol, so it did not require a submission to the research ethics committee.

Financial Support

This study received no specific financial support from public, commercial, or non-profit sources.

Conflict of Interests

The authors declare no conflict of interests.

References

- 1 Li X, Huo Z, Hu Z, et al. Which interventions may improve bracing compliance in adolescent idiopathic scoliosis? A systematic review and meta-analysis. *PLoS One* 2022;17(07):e0271612
- 2 Kaya MH, Erbahçeci F, Alkan H, et al. Factors influencing of quality of life in adolescent idiopathic scoliosis. [published online ahead of print, 2022 Jul 19] *Musculoskelet Sci Pract* 2022;62: 102628
- 3 van Es LJM, van Royen BJ, Oomen MWN. Clinical significance of concomitant pectus deformity and adolescent idiopathic

- scoliosis: systematic review with best evidence synthesis. *N Am Spine Soc J* 2022;11:100140
- 4 Liu Z, Hai Y, Li Z, Wu L. Zebrafish and idiopathic scoliosis: the 'unknown knowns'. *Trends Genet* 2022;38(06):524–528
 - 5 Abdelaal A, Munigangaiha S, Davidson N, Trivedi J. Early-onset scoliosis: challenges and current management options. *Orthop Trauma* 2020;34(06):. Doi: 10.1016/j.mporth.2020.09.009
 - 6 Stuecker S, Mladenov K, Kunkel P, Hagemann C, Freiwald E, Stuecker R. Vertebral column growth in children with early onset scoliosis treated with magnetically controlled growing rods - Effects of distraction on vertebral and disc morphology. *Surgeon* 2021
 - 7 Karsacian M, Cúneo A, Severo SR, Schimchak M, Wodowóz O, Álvarez I. Corrección instrumentada de la escoliosis idiopática del adolescente y artrodesis conaloinjerto de banco. *Rev Med Urug (Montev)* 2007;23(04):351–359
 - 8 Bakaloudis G, Gioia G, Corti G, Isidori A, Ramieri A. The role of less invasive surgery in the treatment of adolescent idiopathic scoliosis and adult spinal deformity. *Orthop Trauma* 2021;35(Suppl 4). Doi: 10.1016/j.mporth.2021.09.008
 - 9 Fiore M, Ruffilli A, Virolì G, Barile F, Manzetti M, Faldini C. Minimally invasive surgery using posterior-only Pedicle screw fixation in treatment of Adolescent Idiopathic Scoliosis: A Systematic Review and Meta-Analysis. *J Clin Neurosci* 2022; 99:317–326
 - 10 Bomback DA, Charles G, Widmann R, Boachie-Adjei O. Video-assisted thoracoscopic surgery compared with thoracotomy: early and late follow-up of radiographical and functional outcome. *Spine J* 2007;7(04):399–405
 - 11 Mack MJ, Regan JJ, Bobechko WP, Acuff TE. Application of thoracoscopy for diseases of the spine. *Ann Thorac Surg* 1993;56(03): 736–738
 - 12 Son-Hing JP, Blakemore LC, Poe-Kochert C, Thompson GH. Video-assisted thoracoscopic surgery in idiopathic scoliosis: evaluation of the learning curve. *Spine* 2007;32(06):703–707
 - 13 Puentes EB, del Curto D, Ueta RHS, Martins Filho DE, Wajchenberg M. Resultados imediatos da correção cirúrgica de escoliose idiopática do adolescente por via posterior com instrumentação após liberação anterior por videotoracoscopia. *Coluna/Columna* 2009; 8(04):363–367
 - 14 Dittmar-Johnson HM, Cruz-López F, González-Camacho E, et al. Surgical correction of juvenile idiopathic scoliosis. Our patients' perception of their quality of life. *Coluna/Columna* 2022;21(01): e259475
 - 15 Pérez-Caballero Macarrón C, Burgos Flores J, Martos Sánchez I, et al. Early postoperative complications of thoracoscopy versus thoracotomy in pediatric idiopathic scoliosis. *An Pediatr (Engl Ed)* 2006;65(06):569–572
 - 16 Feiz HH, Afrasiabi A, Parvizi R, Safarpour A, Fouladi RF. Scoliosis after thoracotomy/sternotomy in children with congenital heart disease. *Indian J Orthop* 2012;46(01):77–80
 - 17 Lawal TA, Gosemann JH, Kuebler JF, Glüer S, Ure BM. Thoracoscopy versus thoracotomy improves midterm musculoskeletal status and cosmesis in infants and children. *Ann Thorac Surg* 2009;87 (01):224–228
 - 18 Alkhalife YI, Padhye KP, El-Hawary R. New Technologies in Pediatric Spine Surgery. *Orthop Clin North Am* 2019;50(01): 57–76
 - 19 Little JP, Loch-Wilkinson TJ, Sundberg A, et al. Quantifying Anterior Chest Wall Deformity in Adolescent Idiopathic Scoliosis: Correlation With Other Deformity Measures and Effects of Anterior Thoracoscopic Scoliosis Surgery. *Spine Deform* 2019;7(03): 436–444
 - 20 Wong HK, Ruiz JNM, Newton PO, Gabriel Liu KP. Non-Fusion Surgical Correction of Thoracic Idiopathic Scoliosis Using a Novel, Braided Vertebral Body Tethering Device: Minimum Follow-up of 4 Years. *JBJS Open Access* 2019;4(04):e0026
 - 21 Green DW, Lawhorne TW 3rd, Widmann RF, et al. Long-term magnetic resonance imaging follow-up demonstrates minimal transitional level lumbar disc degeneration after posterior spine fusion for adolescent idiopathic scoliosis. *Spine* 2011;36(23): 1948–1954
 - 22 Crawford CH 3rd, Lenke LG. Growth modulation by means of anterior tethering resulting in progressive correction of juvenile idiopathic scoliosis: a case report. *J Bone Joint Surg Am* 2010;92 (01):202–209
 - 23 Costanzo S, Pansini A, Colombo L, et al. Video-assisted thoracoscopy for vertebral body tethering of juvenile and adolescent idiopathic scoliosis: tips and tricks of surgical multidisciplinary management. *Children (Basel)* 2022;9(01):74
 - 24 Newton PO, Bartley CE, Bastrom TP, Kluck DG, Saito W, Yaszay B. Anterior Spinal Growth Modulation in Skeletally Immature Patients with Idiopathic Scoliosis: A Comparison with Posterior Spinal Fusion at 2 to 5 Years Postoperatively. *J Bone Joint Surg Am* 2020;102(09):769–777
 - 25 Baker CE, Milbrandt TA, Larson AN. Anterior vertebral body tethering for adolescent idiopathic scoliosis: early results and future directions. *Orthop Clin North Am* 2021;52(02):137–147
 - 26 Miyanji F, Pawelek J, Nasto LA, Rushton P, Simmonds A, Parent S. Safety and efficacy of anterior vertebral body tethering in the treatment of idiopathic scoliosis. *Bone Joint J* 2020;102-B(12): 1703–1708
 - 27 Rushton PRP, Nasto L, Parent S, Turgeon I, Aldebeyan S, Miyanji F. Anterior Vertebral Body Tethering for Treatment of Idiopathic Scoliosis in the Skeletally Immature: Results of 112 Cases. *Spine* 2021;46(21):1461–1467
 - 28 Rushton PRP, Nasto L, Parent S, Turgeon I, Aldebeyan S, Miyanji F. Anterior Vertebral Body Tethering for Treatment of Idiopathic Scoliosis in the Skeletally Immature: Results of 112 Cases. *Spine* 2021;46(21): 1461–1467
 - 29 Bernard J, Bishop T, Herzog J, et al. Dual modality of vertebral body tethering : anterior scoliosis correction versus growth modulation with mean follow-up of five years. *Bone Jt Open* 2022;3(02): 123–129
 - 30 Hoernschemeyer DG, Boeyer ME, Robertson ME, et al. Anterior Vertebral Body Tethering for Adolescent Scoliosis with Growth Remaining: A Retrospective Review of 2 to 5-Year Postoperative Results. *J Bone Joint Surg Am* 2020;102(13):1169–1176
 - 31 Pehlivanoglu T, Oltulu I, Erdag Y, et al. Comparison of clinical and functional outcomes of vertebral body tethering to posterior spinal fusion in patients with adolescent idiopathic scoliosis and evaluation of quality of life: preliminary results. *Spine Deform* 2021;9(04):1175–1182