



Technical Note

Total arthroplasty in displaced dysplastic hips with acetabular reconstruction and femoral shortening – technical note^{☆,☆☆}

Paulo Silva^a, Leandro Alves de Oliveira^a, Danilo Lopes Coelho^a, Rogério Andrade do Amaral^a, Percival Rosa Rebello^a, Frederico Barra de Moraes^{b,*}

^a Hospital Geral de Goiânia, Goiânia, GO, Brazil

^b Clínica de Ortopedia e Traumatologia, Goiânia, GO, Brazil

ARTICLE INFO

Article history:

Received 3 April 2013

Accepted 13 May 2013

Keywords:

Arthroplasty, replacement, hip

Bone diseases, developmental

Osteotomy

Transplantation, autologous

Palavras-chave:

Artroplastia de quadril

Doenças do desenvolvimento ósseo

Osteotomia

Transplante autólogo

ABSTRACT

To describe a new procedure of total hip replacement in patient with severe developmental dysplasia of the left hip, using technique of acetabular reconstruction with autogenous bone grafts and subtrochanteric shortening femoral osteotomy. Total hip replacement done in January of 2003. The Eftekhar's classification was used and included type D, neglected dislocations. Bone graft incorporated in acetabular shelf and femoral osteotomy. Our contribution is the use of an Allis plate to better fix acetabular grafts, avoiding loosening, and cerclage around bone graft in femoral osteotomy site, which diminish pseudoarthrosis risk. This technique shows efficiency, allowing immediately resolution for this case with pain and range of motion of hip improvement. It also allows the acetabular dysplasia reconstruction, equalization of the limb length (without elevated risk of neurovascular lesion) and repairs the normal hip biomechanics due to the correction of the hip's center of rotation.

© 2014 Sociedade Brasileira de Ortopedia e Traumatologia. Published by Elsevier Editora Ltda. All rights reserved.

Artroplastia total em quadris displásicos luxados com reconstrução acetabular e encurtamento femoral

RESUMO

Descrever contribuições à técnica da cirurgia de artroplastia total em displasias do desenvolvimento do quadril grave, por meio da reconstrução acetabular com o uso de enxerto autólogo e encurtamento femoral feito com osteotomia subtrocantérica em V invertido. Paciente submetido a artroplastia total do quadril esquerdo em janeiro de 2003. Foi usada a classificação de Eftekhar e o paciente era do tipo D, luxação inveterada. Incorporação do enxerto no teto acetabular e osteotomia femoral. Acrescentamos a fixação do enxerto da cabeça femoral no acetábulo com placa do tipo Allis, que contribui para maior resistência do sistema, e a cerclagem com fio de aço no enxerto ósseo junto à osteotomia subtrocantérica, que

[☆] Please cite this article as: Silva P, de Oliveira LA, Coelho DL, do Amaral RA, Rebello PR, de Moraes FB. Artroplastia total em quadris displásicos luxados com reconstrução acetabular e encurtamento femoral. Rev Bras Ortop. 2014;49:69-73.

^{☆☆} Study conducted at Department of Hip Surgery, Hospital Geral de Goiânia, Clínica de Ortopedia e Traumatologia de Goiânia, GO, Brazil.

* Corresponding author.

E-mail: frederico_barra@yahoo.com.br (F.B. de Moraes).

diminui o risco de pseudoartrose. Essa técnica demonstrou eficácia e permitiu a resolução imediata do caso com melhoria da dor e da amplitude de movimento do quadril. Permitiu também a reconstrução do déficit ósseo acetabular, a recomposição do comprimento do membro (sem risco aumentado de lesão neurovascular) e a recuperação da biomecânica do quadril com a reparação do centro de rotação normal.

© 2014 Sociedade Brasileira de Ortopedia e Traumatologia. Publicado por Elsevier Editora Ltda. Todos os direitos reservados.

Introduction

Since the emergence of the modern techniques of prosthetic reconstruction of the hip using the principles of Charnley et al,¹ a disease continues to challenge hip orthopedic surgeons: developmental dysplasia of the hip (DDH). In DDH the anatomy is altered. The dysplastic acetabulum is vertical, shallow and with proximal migration, and has poor bone quality and superolateral coverage deficit. The proximal femur is narrow, with small femoral head; and the short neck and trochanter are located posteriorly. Changes in the soft parts also occur, with flattening of the abductor muscles, joint capsule thickening and redundant, hypertrophy of iliopsoas muscle and shortening of the sciatic nerve.²

Because of these changes, Charnley et al. and Feagin et al. discouraged the practice of total hip arthroplasty (THA) in patients with DDH.³ Subsequently, other authors have published studies using bone graft, with the goal of reconstructing the acetabulum and promoting an increase in the coverage of the prosthetic component. Hasting et al. and Parker et al.,⁴ in 1975, were the first to use autograft of the femoral head, with good results. Harris, in 1977, demonstrated the incorporation of cortico-cancellous grafts,⁵ and Azuma et al.,⁶ in 1994, reviewed the graft incorporation by radiographic studies. These studies encouraged the practice of acetabular reconstruction and adopted the incorporation of the graft into the acetabular bed with increased bone stock, which results in increased survival of the hip arthroplasty.

Apart from the difficulties imposed by acetabular dysplasia, other important obstacles are the changes of the proximal femur and the lower limb dysmetria. In these patients, the ectopy of the femoral head, more proximally located, leads to the formation of a false acetabulum and to the soft tissue changes already mentioned. In patients with bilateral involvement, the two surgeries should be made with little delay between the procedures, so there is no detrimental effect on the patient's gait rehabilitation.² In those people in whom the affection is unilateral, one should try to restore the limb length. The femoral shortening should be made to avoid an exaggerated limb lengthening and to protect the sciatic nerve.

The aim of this study was to describe the surgical steps of a total hip arthroplasty in patients with DDH with dislocated hip, through an acetabular reconstruction with bone grafting of the femoral head and fixation with plate for added strength, and femoral shortening with osteotomy in inverted-V, with addition of bone graft cerclage into the osteotomy, to prevent nonunion.

Technical note

Female patient, 44 years old, submitted to THA in January 2003, with clinical presentation of DDH and stubborn dislocation of left hip. The patient was operated by a group of hip surgeons in the General Hospital of Goiânia (GO). The classification of DDH of Eftekhari⁷ was used: type D (stubborn dislocation), in which, besides the need for acetabular reconstruction, femoral shortening osteotomy was also made.

In the preoperative planning, we requested AP radiographs of the pelvis, including the proximal third of femur, hip profile, and orthoradiographic profile of the lower limbs. An assessment with the use of templates was performed. The goal was the normal biomechanics of the hip to be operated (Fig. 1).

The patient underwent spinal anesthesia and was positioned in lateral recumbency. The procedure started with an extensive posterolateral approach and posterior capsulectomy (via Kocher-Langenbeck). Following the osteotomy of the femoral neck, the femoral head is reserved to be used as a graft to the acetabulum. After locating the true acetabulum (to restore the biomechanics of the hip and give durability to the implant; one must be careful not to put the implant into the false acetabulum), this structure was prepared to receive the graft of femoral head fragment, and an osteotomy of the femoral neck was performed. The femoral head is kept to be used as graft of the acetabulum, which is positioned so as to increase the superolateral coverage of acetabulum, and for correction of dysplasia. To obtain a good integration, the recipient bed was scarified till bleeding and the graft is fixed with an Allis plate and screws for small fragments,

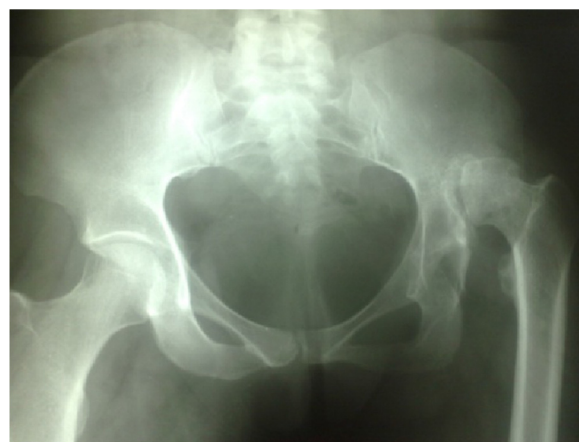

Fig. 1 – Radiography of pelvis in the anteroposterior view in the preoperative planning that highlights the developmental dysplasia of the left hip with stubborn dislocation.

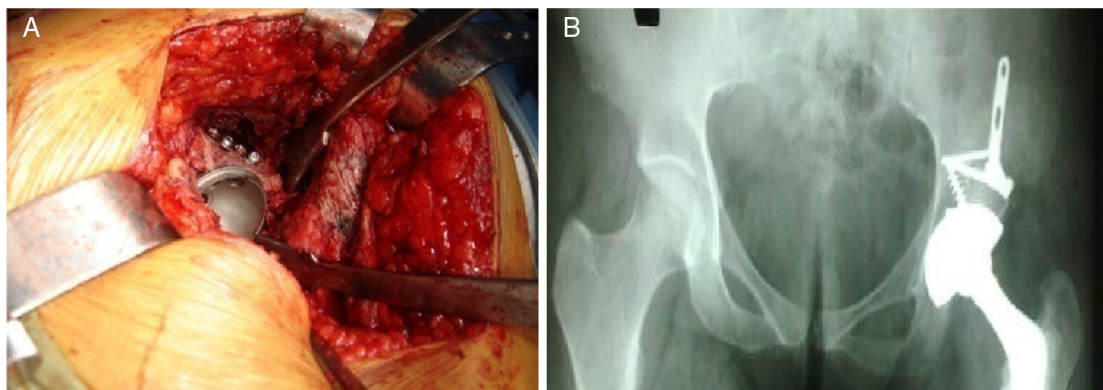


Fig. 2 – Rigid fixation of the autograft for acetabular reconstruction with Allis plate, showing intraoperative image (A) and pelvic X-ray in post-operative anteroposterior view, showing acetabular reconstruction (B).

providing rigid stability to the system. Following that, the reaming of the acetabular bed was made, and the prosthetic component was applied, now under an appropriate coverage (Fig. 2).

The next step is to prepare the femoral canal. We must be careful with the femoral anteversion and anterior angulation of the femur. After the reaming of the femoral canal, the subtrochanteric osteotomy of the femur in an inverted-V was made, with shortening of the bone. The osteotomy in V facilitates the reduction, increases the contact surface of the osteotomy and decreases the percentage of pseudoarthrosis (Fig. 3). With the osteotomy reduction done, we applied an implant -test into the femoral canal and did the fixation with DCP for little fragments, avoiding the femoral canal. After this, an autograft with steel wire cerclage at the osteotomy site with the osteotomized bone itself was done, also to prevent nonunion. Then, definitive implant and interchangeable femoral head were applied, and the hip reduction was done (Fig. 4). After stability testing of the hip and lower limb length has been made, we proceeded with the percutaneous adductor tenotomy.

In the post-operative follow-up, orthoradiography or telerradiography of lower limbs was taken, to assess limb length discrepancy. AP and lateral radiographs of the operated hips were also obtained, to assess the osteointegration of the graft in the acetabular bed and the consolidation of femoral osteotomy (Fig. 5).

A gain in length of the operated limb was obtained, in spite of the femoral shortening, because the acetabular implant is always positioned in the true acetabulum, to the restoration of the proper center of rotation and its hip biomechanics. Thus, femoral shortening was essential for the non-occurrence of vascular complications and especially of any neurological injury postoperatively. The consolidation of the osteotomy occurred in six months after surgery.

The results of post-operative orthoradiography or telerradiography also showed equalization of the lower limbs. This fact, together with the retensioning of the abductor muscles caused by the correction of the hip center of rotation, was responsible for improving gait and quality of life of the patient. There was also improvement in pain and in range of motion in the operated hip.

Discussion

Patients with sequelae of DDH have, as an option in adulthood, the prosthetic hip reconstruction to improve gait and quality of life. We must remember that these are young and autonomous patients. The arthroplasty for hips with stubborn dislocation presents a special problem, because of the peculiar surgical technique; its practice was even discouraged by Charnley and Feagin³ More recently, studies have demonstrated the effective incorporation of the bone graft in the

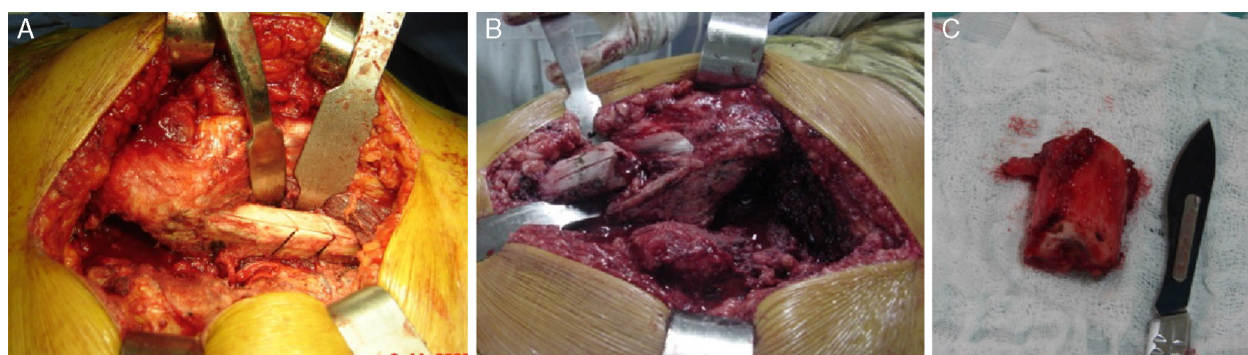


Fig. 3 – Shortening femoral osteotomy in inverted-V showing (A) the removal of the bone fragment (B) and the 2-cm fragment (C).

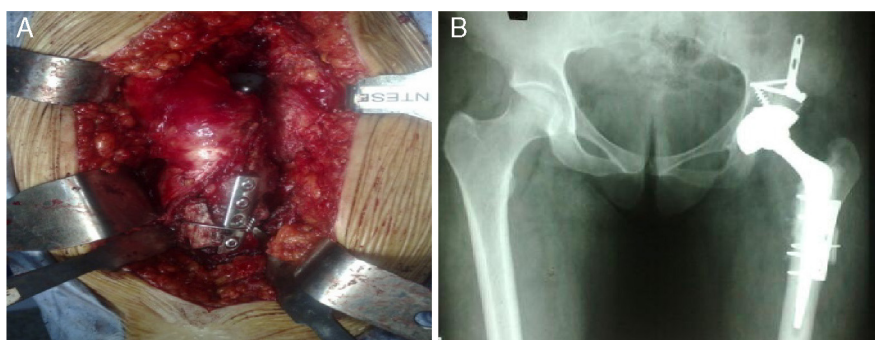


Fig. 4 – Intraoperative image in which femoral osteotomy in inverted-V and rigid fixation with DCP plate (A) were performed and pelvic X-ray in anteroposterior view showing the attachment after shortening and application of graft cerclage into the osteotomy (B).

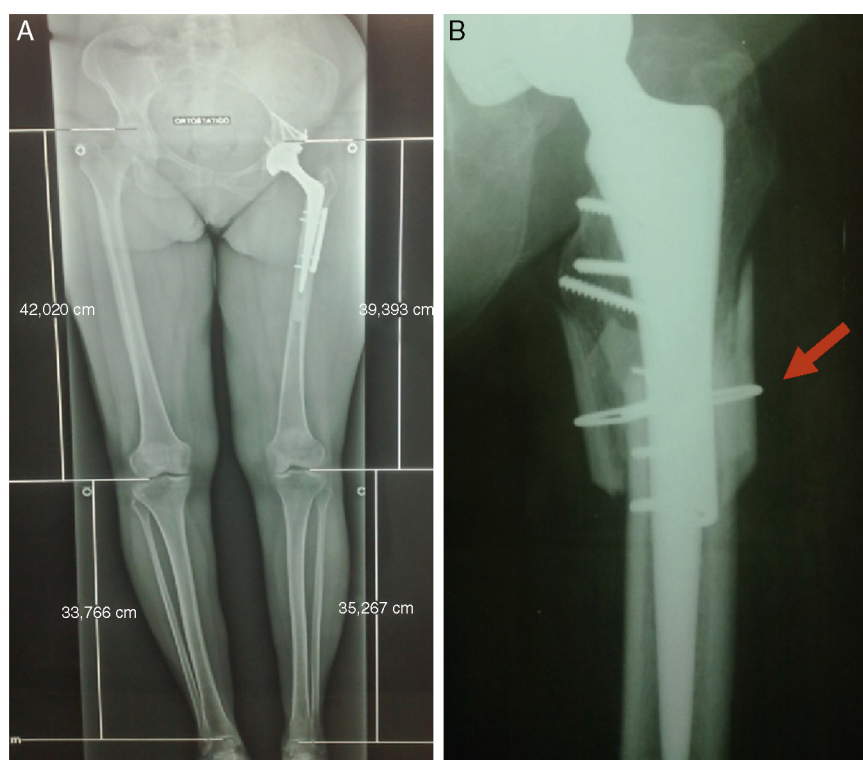


Fig. 5 – Radiographic control in the postoperative period of length discrepancy through orthoradiography of the lower limbs (A); X-ray showing autologous bone graft taken from the osteotomy fragment placed in the subtrochanteric region with cerclage by steel wire (arrow) (B).

acetabular roof, with midterm results that encouraged the procedure.⁴⁻⁸

The first obstacle to good functional outcome of THA in cases of DDH is: lowering of the center of rotation, remaking of the acetabular coverage and correction of the dysplasia. The implantation of the acetabular dome into the false acetabulum is associated with shorter survival of the implant. Linde et al.⁹ reported 42% of loosening when the dome was placed in the false acetabulum; and Stans et al.¹⁰ demonstrated an index of acetabular loosening of 83% in a follow-up of 16 years.

For the reconstruction of the acetabular roof the use of autologous femoral head is recommended, as described by

Harris et al.⁵ in 1977. In their study, these authors guide the graft fixation on the acetabular roof with screws. But they had 20% of loosening in seven years.⁵ We believe that, to get a good result in the consolidation of the graft so there's no reabsorption, there is need for a proper preparation of the host bed (which is critical), as described by Chandler and Penneberg,¹¹ and a stable fixation.

To the techniques available, we added the use of a plate for graft fixation in the acetabulum, which makes the system more stable and less prone to loosening. For the assessment of graft incorporation onto the acetabular roof, we used radiography, as advocated by Azuma et al.⁶ Gonçalves et al.¹²

concluded that the best method for the evaluation of this incorporation is the histological one; however, the procedure is difficult and causes morbidity for the patient. Hence, radiography is the technique most used.

The second obstacle is the shortening of the limb to be operated. In cases of stubborn dislocation and high position, correction of lower limb dysmetria is the goal to be achieved, since its correction will benefit the gait and quality of life of the patient. As in these cases the center of rotation of the hip is high, the femoral reduction in the true acetabulum may cause excessive prolongation of the member, and hence, possible neurological damage.

Thus, we made a femoral shortening subtrochanteric osteotomy in inverted-V, as described by Becker and Gustilo,¹³ with fixation with DCP for small fragments. This osteotomy facilitates reduction, promotes rotational stability and increases the contact surface. Our contribution to the existing techniques is the use of bone graft generated by the osteotomy itself around the inverted-V, with a steel wire cerclage, which reduces the risk of femur nonunion.

Conclusion

The technique of acetabular reconstruction and femoral shortening in patients with DDH classified as Eftekhari type D was very efficient, with immediate resolution of the defect and pain. Fixation of the femoral head graft into the acetabulum with plate Allis was done, which contributes to greater resistance of the system, and cerclage with steel wire in the bone graft next to the subtrochanteric osteotomy, which reduces the risk of nonunion.

Conflicts of interest

The authors declare no conflicts of interest.

REFERENCES

1. Charnley J. Low friction arthroplasty of the hip: theory and practice. New York: Springer-Verlag; 1979.
2. Canale ST. Cirurgia ortopédica de Campbell. 10ª ed. São Paulo: Manole; 2006.
3. Charnley J, Feagin JA. Low-friction arthroplasty in congenital subluxation of the hip. *Clin Orthop Relat Res.* 1973;(91):98-113.
4. Hastings DE, Parker SM. Protrusio acetabuli in rheumatoid arthritis. *Clin Orthop Relat Res.* 1975;(108):76-83.
5. Harris WH, Crothers O, Oh I. Total hip replacement and femoral-head bone-grafting for severe acetabular deficiency in adults. *J Bone Joint Surg Am.* 1977;59(6):752-9.
6. Azuma T, Yasuda H, Okagaki K, Sakai K. Compressed allograft chips for acetabular reconstruction in revision hip arthroplasty. *J Bone Joint Surg Br.* 1994;76(5):740-4.
7. Eftekhari N. Principles of total hip arthroplasty. St Louis: CV Mosby; 1978.
8. Sponseller PD, McBeath AA. Subtrochanteric osteotomy with intramedullary fixation for arthroplasty of the dysplastic hip. A case report. *J Arthroplasty.* 1988;3(4):351-4.
9. Linde F, Jensen J. Socket loosening in arthroplasty for congenital dislocation of the hip. *Acta Orthop Scand.* 1988;59(3):254-7.
10. Stans AA, Pagnano MW, Shaughnessy WJ, Hanssen AD. Results of total hip arthroplasty for Crowe Type III developmental hip dysplasia. *Clin Orthop Relat Res.* 1998;(348):149-57.
11. Chandler HP, Penenberg BL. Bone stock deficiency in total hip replacement: classification and management. Thorofare, NJ: Slack; 1989.
12. Gonçalves HR, Honda EK, Ono NK. Análise da incorporação do enxerto ósseo acetabular. *Rev Bras Ortop.* 2003;38(4):139-60.
13. Becker DA, Gustilo RB. Double-chevron subtrochanteric shortening derotational femoral osteotomy combined with total hip arthroplasty for the treatment of complete congenital dislocation of the hip in the adult Preliminary report and description of a new surgical technique. *J Arthroplasty.* 1995;10(3):313-8.