



Original Article

Functional assessment of endoprosthesis in the treatment of bone tumors[☆]



Denis Kiyoshi Fukumothi, Hiran Pupo, Luciano Augusto Reganin*,
Silvia Raquel Fricke Matte, Bruno Spagnuolo de Lima, Carlos Augusto de Mattos

Pontifícia Universidade Católica de Campinas (PUC-Campinas), Hospital e Maternidade Celso Pierro, Serviço de Ortopedia e Traumatologia, Campinas, SP, Brazil

ARTICLE INFO

Article history:

Received 20 October 2015

Accepted 7 January 2016

Available online 30 August 2016

Keywords:

Bone neoplasms

Reconstructive surgical procedures

Joint prosthesis

Limb salvage

ABSTRACT

Objectives: Evaluate the functional grade of these patients and to identify the types of complications found that influenced the average life span of endoprostheses the functions of the operated limb.

Methods: We analyzed 14 post-operative cases of endoprosthesis, patients with malignant bone tumors and aggressive benign bone tumors submitted to surgery between 2004 and 2014. The evaluation system used was proposed by Enneking, recommended by the Musculoskeletal Tumor Society (MSTS), in addition to the radiologic evaluation.

Results: Endoprosthesis are excellent choices for the treatment of bone tumors with limb preservation in relation to pain, strength, and patient's emotional acceptance. Another factor for good results is the immediate weight-bearing capacity, generating a greater independence.

Conclusion: The authors conclude that all patients classified the therapy as excellent/good, regardless of the type of prosthesis used, extent of injury, and/or type of tumor resection performed.

© 2016 Published by Elsevier Editora Ltda. on behalf of Sociedade Brasileira de Ortopedia e Traumatologia. This is an open access article under the CC BY-NC-ND license (<http://creativecommons.org/licenses/by-nc-nd/4.0/>).

Avaliação funcional das endopróteses no tratamento de tumores ósseos

RESUMO

Objetivo: Avaliar o grau funcional desses pacientes e identificar os tipos de complicações encontradas e que influenciaram na sobrevida das endopróteses e na função do membro operado.

Métodos: Foram analisados 14 pós-operatórios de endopróteses em pacientes portadores de tumores ósseos malignos e benignos agressivos com cirurgia entre 2004 e 2014. O sistema

Palavras-chave:

Neoplasias ósseas

Procedimentos cirúrgicos

reconstrutivos

[☆] Study carried out at the Pontifícia Universidade Católica de Campinas (PUC-Campinas), Hospital e Maternidade Celso Pierro, Serviço de Ortopedia e Traumatologia, Campinas, SP, Brazil.

* Corresponding author.

E-mail: lucianoreganin@uol.com.br (L.A. Reganin).

<http://dx.doi.org/10.1016/j.rboe.2016.08.012>

2255-4971/© 2016 Published by Elsevier Editora Ltda. on behalf of Sociedade Brasileira de Ortopedia e Traumatologia. This is an open access article under the CC BY-NC-ND license (<http://creativecommons.org/licenses/by-nc-nd/4.0/>).

Prótese articular
Salvamento de membro

de avaliação foi o proposto por Enneking, preconizado pela Musculoskeletal Tumor Society (MSTS), além da avaliação radiográfica.

Resultados: As endopróteses são ótimas opções no tratamento de tumores ósseos com preservação do membro, em relação à dor, força e aceitação emocional do paciente. Outro fator para bons resultados é a capacidade de suporte de peso imediato, que gera uma independência maior.

Conclusão: Todos os pacientes classificaram a terapia como excelente/boa, indiferentemente do tipo de prótese, extensão da lesão, tipo de tumor e ressecção feita.

© 2016 Publicado por Elsevier Editora Ltda. em nome de Sociedade Brasileira de Ortopedia e Traumatologia. Este é um artigo Open Access sob uma licença CC BY-NC-ND (<http://creativecommons.org/licenses/by-nc-nd/4.0/>).

Introduction

With advances in protocols and treatment of cancer patients and consequent increase in survival, the number of patients with bone metastases has increased, as well as the incidence of complications.¹⁻⁴ One of the complications often found in these patients are pathological fractures, especially in the lower limbs, which invariably affect the meta-epiphyseal region of the bone and requires joint reconstruction. Regarding primary bone tumors, these have also had better outcomes after use of multidrug therapy, resulting in limb salvage possibility; that, in most cases, is only obtained with large bony resections, leading to the need for reconstruction of this bone segment, which in most cases can be attained with non-conventional endoprosthesis.

Metastatic bone disease is the most common bone malignancy,¹ primarily affecting the axial skeleton, pelvis and femur.^{5,6} Metastatic involvement of the lower limbs is associated with a greater number of pathological fractures and promotes increased morbidity / mortality due to prolonged bed rest, increased risk of pneumonia and thromboembolic events.⁶ Under these circumstances, replacement of the bone segment can be attained with an endoprosthesis, which rapidly rehabilitates this patient, who becomes an ambulatory patient.^{1,7-9}

Regarding primary bone tumors, osteosarcoma and Ewing's sarcoma, as well as giant cell tumors (GCT) of the bone, also occur more often in the lower limbs, with the distal femur and proximal tibia being the preferred locations, affecting the joint region while resulting in the need for joint replacement. As in the upper limbs, these tumors not infrequently affect the proximal humerus.^{2,7}

For primary malignant and aggressive benign tumors, a wide resection to achieve necessary safety margin results in large bony resections and, therefore, the need for local reconstruction.^{8,10}

Among the techniques based on limb salvage principle, one that has been recommended for treating bone metastases in the lower limbs and the proximal humerus, due to better response and effectiveness, is lesion resection and replacement of the resected segment by an unconventional endoprosthesis,^{5,11,12} the method of choice in our service.

For malignant primary bone tumors (osteosarcoma, Ewing's sarcoma, chondrosarcoma) and aggressive benign tumors (Enneking's B3) obtaining a broad or radical margin invariably results in large meta-epiphyseal bone loss,

requiring biological or prosthetic reconstruction.¹³ Large bone resections occurring during surgical revisions of conventional arthroplasties are another condition that requires the use of endoprostheses.

In such cases, the biological reconstructions can be performed with autologous bone graft, free or vascularized, homologous graft (tissue bank) or other autograft methods. Although more natural, biological reconstruction shows severe limitations in most cases.¹³

Prosthetic reconstructions are performed with non-conventional endoprostheses, which replace bones and joints. They are of easy access, provides anatomical reconstruction of the limb, functionally and fast, resulting in early ambulation recovery. However, they also have a high number of complications within short- and long-term follow-up. Postoperative complications of bone tumor resections and replacement of the resected segment by an endoprosthesis are: infection, aseptic implant loosening, periprosthetic fracture, implant fracture and tumor recurrence.^{1,7,14}

These complications can be responsible for the functional impairment of the affected limb, implant loss and even the amputation of the affected limb.

The purpose of this study is to identify the types of complications found that influenced the average life span of the endoprostheses and function of the operated limb of our patients, according to the functional analysis of the MSTS. These data can be used to improve implant manufacturing and surgical techniques, as the improvement of orthopedic implants and techniques used in bone defect replacement after neoplastic resection is crucial to achieve greater durability, with fewer complications and increased functionality of the operated limb.^{5,12-15}

Material and methods

This is a retrospective study with 14 patients with malignant and aggressive benign (Enneking's B3) tumors, who required reconstructive surgery with non-conventional endoprosthesis. Patients with incomplete medical records that would not allow assessment and those who died or were transferred to another service before completing one year of follow-up were excluded. Patients who did not sign an Informed Consent Form were also excluded.

Mean age of patients was 56 years, with the youngest being 19 and the oldest 66 years of age. Five patients were males and nine were females. As for the tumor site, one (7%) was

Table 1 – Patient data.

Patient	Gender	Age	Surgery	Site	Primary tumor	Amputation
1	M	41	2004	Knee	GCT	No
2	M	52	2008	Hip	Chondrosarcoma	No
3	F	61	2008	Knee	Chondrosarcoma	Yes
4	F	66	2008	Knee	Chondrosarcoma	No
5	M	58	2010	Knee	Chondrosarcoma	Yes
6	F	81	2011	Knee	Metastasis	No
7	F	28	2012	Knee	GCT	No
8	F	60	2013	Knee	Metastasis – Breast	No
9	F	74	2013	Knee	Chondrosarcoma	Yes
10	M	65	2014	Shoulder	Chondrosarcoma	No
11	F	56	2014	Hip	Metastasis – Kidney	No
12	M	19	2014	Knee	Ewing Sarcoma	No
13	F	49	2014	Knee	Multiple Myeloma	No
14	F	31	2014	Knee	GCT	No

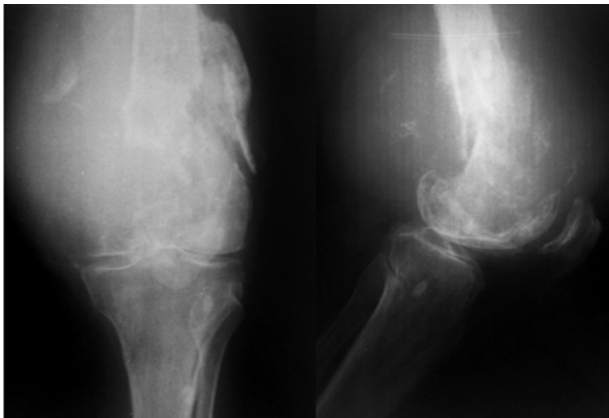


Fig. 1 – Preoperative radiographies of one of the study patients, diagnosed with GCT in the left distal femur.

located in the shoulder, two (14%) in the hip and 11 (78%) in the knee (Fig. 1). Considering tumor type, one (7%) was a myeloma, one (7%) an Ewing's tumor, three (21%) were bone metastases and six (42%) were chondrosarcomas. All surgeries

were performed between 2004 and 2014 (Fig. 2). Three patients underwent amputation due to late complications of the endoprosthesis primary procedure. These data are shown in Table 1.

Functional assessment was performed according to the classification recommended by Enneking, adopted by the Musculoskeletal Tumor Society (MSTS), whose parameters are mobility, pain, function, emotional acceptance, supports, walking, gait, range of motion (ROM) and strength. Each functional assessment parameter was evaluated with six scoring levels, with the highest score being five and the lowest, zero. Radiographic imaging was also evaluated regarding the endoprosthesis stability, as shown in Table 2.

Using the R and Excel software programs, the exploratory data analysis was carried out with 11 patients (three were excluded from the data analysis due to amputation) submitted to endoprosthesis treatment. This work aims to evaluate whether the endoprosthesis is an effective treatment. Using a QQ plot of the mean scores, the assumption of normality of scores was confirmed, that is, as the points are close to the line, the t-test can be used to compare the means of the data, as shown in Table 3 and Fig. 3.

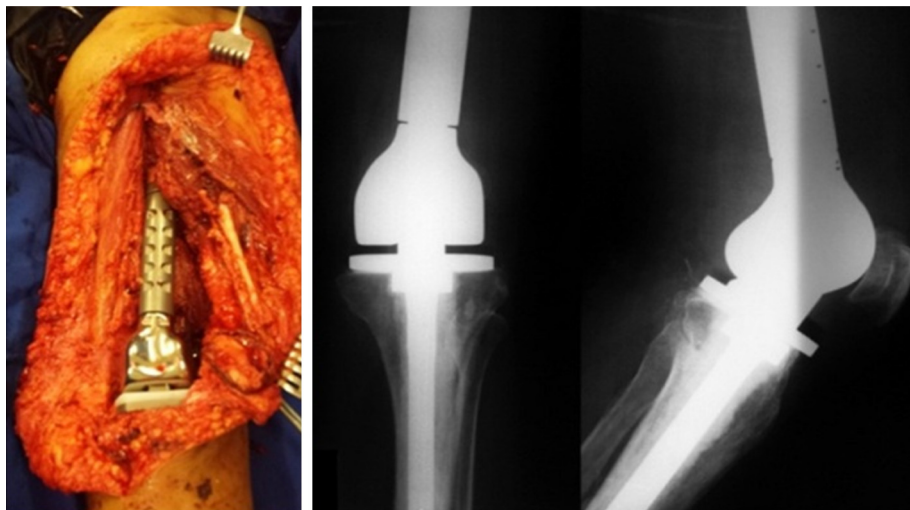


Fig. 2 – Intraoperative and postoperative radiographic images of the same patient, who was submitted to unconventional modular endoprosthesis of the distal femur with articulated knee.

Table 2 – Questionnaire results.

Patient	Pain	Function	Emotional acceptance	Supports	Walking	Gait	Strength	ROM
1	3	5	4	6	5	4	6	2
2	6	5	6	2	4	3	6	5
3	-	-	-	-	-	-	-	-
4	4	4	6	1	3	2	4	6
5	-	-	-	-	-	-	-	-
6	6	2	6	2	3	2	6	3
7	6	5	4	6	6	4	6	5
8	6	2	6	1	2	2	6	6
9	-	-	-	-	-	-	-	-
10	4	1	4	6	-	-	0	0
11	4	3	5	1	3	2	6	4
12	5	5	4	6	5	5	6	4
13	4	3	2	3	4	3	6	5
14	3	3	6	6	6	2	6	2

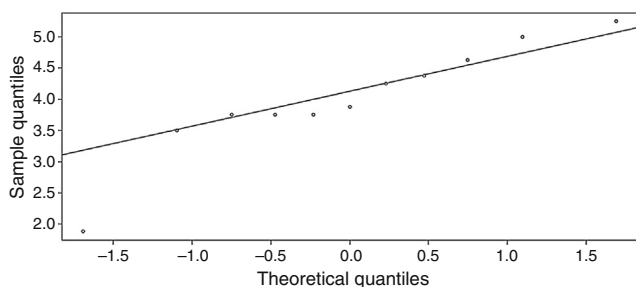


Fig. 3 – Q-Q plot of the mean total scores.

Results

The score value for each patient may vary from eight to 48 and the mean value obtained was 32. Half of the patients who answered the questionnaire had a score between 30 and 36. The lowest observed score was 15 and the highest was 42.

In the overall analysis of the endoprosthesis effectiveness and after establishing that mean scores higher than three is considered a good result and using Student's t-test (comparison of means) to determine the mean scores, a *p* value = 0.002 was obtained, a statistically significant result.

All variables were also analyzed separately, using the same Student's t method, considering a response higher than three a satisfactory result. The results ranged from 0.005 *p* to 0.8. Pain, emotional acceptance and strength were statistically

Table 3 – Mean of total scores of questions per patient.

Patient	Mean of scores
1	4.375
2	4.625
4	3.75
6	3.75
7	5.25
8	3.875
10	1.875
11	3.5
12	5
13	3.75
14	4.25

significant and showed a *p* value <0.05. As for function, supports, walking, gait and ROM, they all showed a *p* value >0.05.

Regarding radiographies, all prostheses were stable, with no apparent signs of loosening or infection, except for the patients who underwent amputation due to postoperative complications or tumor recurrence. All radiographies were performed in the same service.

Discussion

The current literature is scarce regarding functional results after limb salvage surgery in patients with malignant and aggressive benign tumors, most likely due to the rarity of primary bone tumors. In recent decades, treatment of bone tumors went through changes, since the previously preferred treatment for most cases was amputation. In the beginning of this century, limb salvage surgery became predominant among surgeons, and amputations become only an option, or the treatment of complications after limb salvage surgeries.^{15,16}

In a study carried out at Centro Infantil Boldrini published in 2008, authors compared two groups of patients with bone sarcomas in the distal end of the femur, one with total and another with partial endoprostheses, there was no influence on the overall functional outcome and a statistically significant difference was observed only regarding stability.¹⁷

In general, non-conventional endoprostheses are excellent devices in the reconstruction of large bone resections; however, they have mechanical limitations, which must be considered before their indication.

This study agrees with the current literature and obtained the same results, showing that the endoprosthesis is an excellent option in the treatment of bone tumors with limb salvage, especially in relation to pain, strength and patient emotional acceptance, according to the results shown in Table 4. During the interview, all patients emphasized emotional improvement after surgery, mainly due to pain improvement. Another factor that contributes to the good results demonstrated in this study is the immediate load-bearing capacity, which results in greater patient independence.

However, it is known that the range of motion (ROM) shows limitation in relationship to the contralateral limb, mainly due to loss of muscle mass, either because of age, non-use or

Table 4 – Results of tests, their efficacy and respective p-value.

Results of the mean comparison test		
Variable	Effective	p-Value
Pain	Yes	0.001
Function	No	0.150
Emotional acceptance	Yes	0.005
Supports	No	0.200
Walking	No	0.100
Gait	No	0.800
Strength	Yes	0.001
ROM	No	0.090
Total	Yes	0.002

resection during surgery. This loss of muscle mass also worsens ambulation capacity and increases the need for assistance during gait. As a consequence of limb deterioration, limb function becomes limited, which again demonstrates the results shown in this study.

Conclusion

All patients classified the therapy as excellent/good, regardless of the prosthesis type, lesion extension, tumor type and resection performed.

Most patients with bone tumors with limb salvage indication had a life prognosis below that found in the general population, so the early return to everyday activities, independence and ambulation capacity are the treatment goals, making endoprosthesis a viable and effective option for these patients.

Despite the limited study sample, the results obtained from the questionnaire support the current literature. Given the limitation of patients that are adequate for this sample and the fact that it is a current issue, we believe that the endoprosthesis is currently an excellent choice.

Conflicts of interest

The authors declare no conflicts of interest.

REFERENCES

1. Finn HA. General considerations. In: Simon MA, Springfield D, editors. *Surgery for bone and soft tissue tumors*. Philadelphia: Lippincott-Raven; 1998. p. 609-13.
2. British Orthopaedic Association and the British Orthopaedic Oncology Society. *Metastatic bone disease: a guide to good practice*; 2001.
3. Eilber FR, Grant TT, Eckhardt J, Morton DL. Prosthetic replacement after segmental bone and joint resection for malignant bone tumors. In: Chao EY, Ivins JC, editors. *Tumor prosthesis for bone and joint reconstruction*. New York: Thieme-Stratton; 1983. p. 321-7.
4. Teixeira LEM, Miranda RH, Ghedini DF, Aguilar RB, Novais ENV, Silva GMA, et al. Complicações precoces no tratamento ortopédico das metástases ósseas. *Rev Bras Ortop*. 2009;44(6):519-23.
5. Capanna R, Campanacci DA. The treatment of metastases in the appendicular skeleton. *J Bone Joint Surg Br*. 2001;83(4):471-81.
6. Silverberg E. Cancer statistics. *CA Cancer J Clin*. 1986;36(1):9-25.
7. Wedin R, Bauer HC. Surgical treatment of skeletal metastatic lesions of the proximal femur: endoprosthesis or reconstruction nail? *J Bone Joint Surg Br*. 2005;87(12):1653-7.
8. Ahlmann ER, Menendez LR, Kermani C, Gotha H. Survivorship and clinical outcome of modular endoprosthetic reconstruction for neoplastic disease of the lower limb. *J Bone Joint Surg Br*. 2006;88(6):790-5.
9. Kawai A, Muschler GF, Lane JM, Otis JC, Healey JH. Prosthetic knee replacement after resection of a malignant tumor of the distal part of the femur. *J Bone Joint Surg Am*. 1998;80(5):636-47.
10. Mirels H. Metastatic disease in long bones. A proposed scoring system for diagnosing impending pathologic fractures. *Clin Orthop Relat Res*. 1989;(249):256-64.
11. Sharma S, Turcotte RE, Isler MH, Wong C. Experience with cemented large segment endoprostheses for tumors. *Clin Orthop Relat Res*. 2007;459:54-9.
12. Orlic D, Smerdelj M, Kolundzic R, Bergovec M. Lower limb salvage surgery: modular endoprosthesis in bone tumour treatment. *Int Orthop*. 2006;30(6):458-64.
13. Malawer MM, Chou LB. Prosthetic survival and clinical results with use of large-segment replacements in the treatment of high-grade bone sarcomas. *J Bone Joint Surg Am*. 1995;77(8):1154-65.
14. Healey JH, Brown HK. Complications of bone metastases: surgical management. *Cancer*. 2000;88 12 Suppl.:2940-51.
15. Torbert JT, Fox EJ, Hosalkar HS, Ogilvie CM, Lackman RD. Endoprosthetic reconstructions: results of long-term followup of 139 patients. *Clin Orthop Relat Res*. 2005;438:51-9.
16. Park DH, Jaiswal PK, Al-Hakim W, Aston WJ, Pollock RC, Skinner JA, et al. The use of massive endoprostheses for the treatment of bone metastases. *Sarcoma*. 2007;2007:621-51.
17. Mendonça SMH, Cassone AE, Brandalise SR. Avaliação funcional dos pacientes portadores de sarcomas ósseos submetidos a tratamento cirúrgico utilizando a endoprótese total ou parcial, na substituição da extremidade distal do fêmur. *Acta Ortop Bras*. 2008;16(1):13-8.