

Sagittal Plane Alignment and Functional Outcomes Following Surgery for Scheuermann Kyphosis*

Alinhamento do plano sagital e resultados funcionais após cirurgia para a cifose de Scheuermann

Luísa Vital¹  Bernardo Nunes¹ Sara Almeida Santos¹ Vitorino Veludo² Francisco Serdoura² André Pinho³

¹Department of Orthopedics and Traumatology, Centro Hospitalar Universitário de São João, Porto, Portugal

²Centro Hospitalar Universitário de São João, Porto, Portugal

³Anatomy Unit, Centro Hospitalar Universitário de São João, Porto, Portugal

Address for correspondence Luísa Vital, Department of Orthopedics and Traumatology, Centro Hospitalar Universitário de São João, Alameda Professor Hernâni Monteiro, Porto, Portugal (e-mail: luisavital1203@gmail.com).

Rev Bras Ortop 2021;56(4):446–452.

Abstract

Objective To evaluate and correlate the pelvic parameters, the sagittal balance (SB), and the functional outcome of the patients submitted to surgical treatment for Scheuermann hyperkyphosis (SK).

Methods Patients submitted to surgery between January 2005 and December 2016 were included. The following radiographic measurements were obtained: thoracic kyphosis (TK); lumbar lordosis (LL); SB; pelvic incidence (PI); pelvic tilt (PT); and sacral slope (SS). Complications during the follow-up period were recorded.

Results A total of 19 patients were included (16 males): the mean preoperative kyphosis was of 83°, and the postoperative kyphosis was of 57°. The mean preoperative lumbar lordosis was of 66°, with a postoperative spontaneous correction of 47°. Regarding the preoperative pelvic parameters, the average PI, PT and SS were of 48°, 10° and 39° respectively. In the postoperative period, these values were of 50°, 16° and 35° respectively. The preoperative SB was neutral, and it was maintained after the surgical correction. Concerning complications during the follow-up period, three junctional kyphosis were observed—two requiring revision surgery, one nonunion, and one dehiscence of the surgical wound. Regarding the functional results, the average score on the Scoliosis Research Society-22 (SRS-22) patient questionnaire was of 4.04, and we verified that the SB obtained in the postoperative period had no influence on the functional outcome ($p=0.125$) nor on the postoperative LL ($p=0.851$).

Keywords

- ▶ Scheuermann disease
- ▶ spine
- ▶ thoracic vertebrae
- ▶ spinal fusion
- ▶ kyphosis

* Work developed at Centro Hospitalar Universitário de São João, Porto, Portugal.

received
June 26, 2020
accepted
September 16, 2020

DOI <https://doi.org/10.1055/s-0041-1724078>.
ISSN 0102-3616.

© 2021. Sociedade Brasileira de Ortopedia e Traumatologia. All rights reserved.

This is an open access article published by Thieme under the terms of the Creative Commons Attribution-NonDerivative-NonCommercial-License, permitting copying and reproduction so long as the original work is given appropriate credit. Contents may not be used for commercial purposes, or adapted, remixed, transformed or built upon. (<https://creativecommons.org/licenses/by-nc-nd/4.0/>)

Thieme Revinter Publicações Ltda., Rua do Matoso 170, Rio de Janeiro, RJ, CEP 20270-135, Brazil

Conclusion We verified a spontaneous improvement in the lumbar hyperlordosis at levels not included in the fusion after correction of the TK. Although the postoperative functional results were globally high, we did not find any statistically significant relationship with TK nor LLs. high PI is associated with a greater rate of complications regarding the proximal junctional kyphosis (PJK), and these pelvic parameters should be considered at the time of the SK surgical treatment.

Resumo

Objetivo Avaliar e correlacionar os parâmetros pélvicos, o equilíbrio sagital (SB), e o resultado funcional dos pacientes submetidos ao tratamento cirúrgico da hiperlordose de Scheuermann (SK).

Métodos Foram incluídos pacientes submetidos à cirurgia entre janeiro de 2005 e dezembro de 2016. Foram obtidas as seguintes medidas radiográficas: cifose torácica (TK); lordose lombar (LL); SB; incidência pélvica (PI); inclinação pélvica (PT); e inclinação sacral (SS). Complicações foram registradas durante o período de seguimento.

Resultados Foram incluídos 19 pacientes (16 homens): a cifose pré-operatória média foi de 83°, e, após a cirurgia, de 57°. A LL média pré-operatória foi de 66°, com uma correção espontânea pós-operatória de 47°. Quanto aos parâmetros pélvicos pré-operatórios, as médias de PI, PT e SS foram de 48°, 10° e 39°, respectivamente. No pós-operatório, esses valores foram de 50°, 16° e 35°, respectivamente. O SB pré-operatório foi neutro e mantido após correção cirúrgica. Quanto às complicações durante o período de seguimento, foram observadas três cifoses juncionais – duas necessitando de cirurgia de revisão, uma má consolidação, e uma deiscência de sutura. Em relação aos resultados funcionais, a pontuação média no questionário de 22 itens da Scoliosis Research Society (SRS-22) foi de 4,04, e verificou-se que o SB no pós-operatório não teve influência no desfecho funcional ($p=0,125$), nem na LL pós-operatória ($p=0,851$).

Palavras-chave

- ▶ doença de Scheuermann
- ▶ coluna vertebral
- ▶ vértebras torácicas
- ▶ fusão espinhal
- ▶ cifose

Conclusão Verificamos uma melhora espontânea da hiperlordose lombar em níveis não incluídos na fusão após a correção da TK. Embora os resultados funcionais pós-operatórios tenham sido globalmente elevados, não encontramos nenhuma relação estatisticamente significativa com a TK nem com a LL. A PI elevada está associada a maior complicação da cifose juncional proximal (PJK), e esses parâmetros pélvicos devem ser considerados no momento do tratamento cirúrgico da cifose de Scheuermann.

Introduction

Scheuermann hyperkyphosis (SK) is a deformity in the sagittal plane with an incidence that ranges from 0.4% to 8%, with a slightly higher male prevalence, and it is currently the most common cause of rigid hyperkyphosis in the pediatric population.^{1,2}

The diagnosis is often made in adolescents presenting with chronic symptoms of mild back pain and a typical cosmetic deformity of the thoracic or thoracolumbar spine. According to Sorensen,³ the radiographic criteria for diagnosis include thoracic kyphosis (TK) > 40° or thoracolumbar kyphosis (TLK) > 30°, and at least 3 consecutive vertebral bodies with a minimum of 5° of wedging.

The goal of the surgical treatment in cases of SK is not only the correction of deformity, but also a symptomatic and cosmetic improvement. A large number of studies report

radiographic outcomes, but most of them focus mainly on spinal parameters without including the pelvic assessment and its relationship with the sagittal balance (SB) and quality of life. The pelvic incidence (PI) is a key characteristic of the pelvis, which is defined as an anatomical feature unique to each individual that becomes set at the end of growth and that determines the relative position of the sacral plate in relation to the femoral heads. The sacral slope (SS) is the angle of the sacral plateau to the horizontal plane, and it determines the position of the lumbar spine since the sacral plateau forms the base of the spine. The pelvic tilt (PT) is defined by the angle between a vertical line through the femoral head and a line from the mid-sacral plateau and femoral head, and it determines the spatial orientation of the pelvis. The PT is a positional parameter, as well as the SS. The possibility of rotation of the pelvis around the axis of the femoral heads is one of the best mechanisms of regulation of the SB.⁴

Clinical expertise and current literature⁵ suggest that the reestablishment of a physiological SB is extremely important and should guide the surgical corrections. The understanding of spinopelvic parameters and their importance in spine biomechanics has gained relevance, and several articles⁶ have tried to describe them and their relationship, but there is limited data regarding the response of spinopelvic parameters and sagittal plane alignment of the spine to surgical treatment for SK. The aim of the present study is to evaluate and correlate the pelvic parameters, the SB and the functional outcome of the patients submitted to surgical treatment for SK.

Material and Methods

The records of patients submitted to SK correction at our institution between January 2005 and December 2016 were retrieved from our database. The diagnosis was based on the radiological criteria provided by Sorensen.³ Patients with congenital spine deformities, neuromuscular or syndromic disease, previous spine surgery, spine tumor, postural kyphosis or primary deformity of scoliosis, spondylolisthesis, or spondylolysis were excluded. The indication for surgery was a TK or TLK with a curve $> 70^\circ$ with persistent back pain, with no satisfactory response to the conservative management. To be included in the study, all the patient parameters had to be available, and the follow-up had to be complete. All patients underwent a posterior-only correction procedure with periapical osteotomies and pedicle-screw fixation by the same surgical team consisting of two senior surgeons. The upper limit of instrumentation was the proximal-end Cobb vertebra and the lower instrumented vertebra was the sagittal stable vertebra or the first lordotic vertebra, according to a previously discussed decision. During surgery, care was taken to preserve the supraspinous and interspinous ligaments, the spinous processes of the upper limit of instrumentation, and the level immediately above it. Ambulation without a brace is accomplished on the first or second day after surgery.

Radiographic measurements were obtained through longstanding spine radiographs before surgery and throughout the follow-up. In each patient the following parameters were measured: TK; lumbar lordosis (LL); SB; PI; PT; SS. All measurements were performed by two physicians, and their mean values were recorded (► Fig. 1).

The other imaging parameters recorded were the number of instrumented vertebrae, the level of distal fusion, and the complications during the follow-up period, such as the radiographic junction kyphosis – defined as the caudal endplate of the uppermost instrumented vertebra (UIV) to the cephalad endplate of two suprajacent vertebrae above the UIV and the same for the last instrumented inferior vertebra.⁷

The Scoliosis Research Society-22 (SRS-22) patient questionnaire, translated to our native language, was filled out by all patients.

All statistical analyses were conducted using the Statistical Package for the Social Sciences (SPSS, IBM Corp., Armonk, NY, US) software, version 21.0 for Windows. The Student *t*-test was used to assess the differences in mean values between the groups for normally distributed continuous variables. The

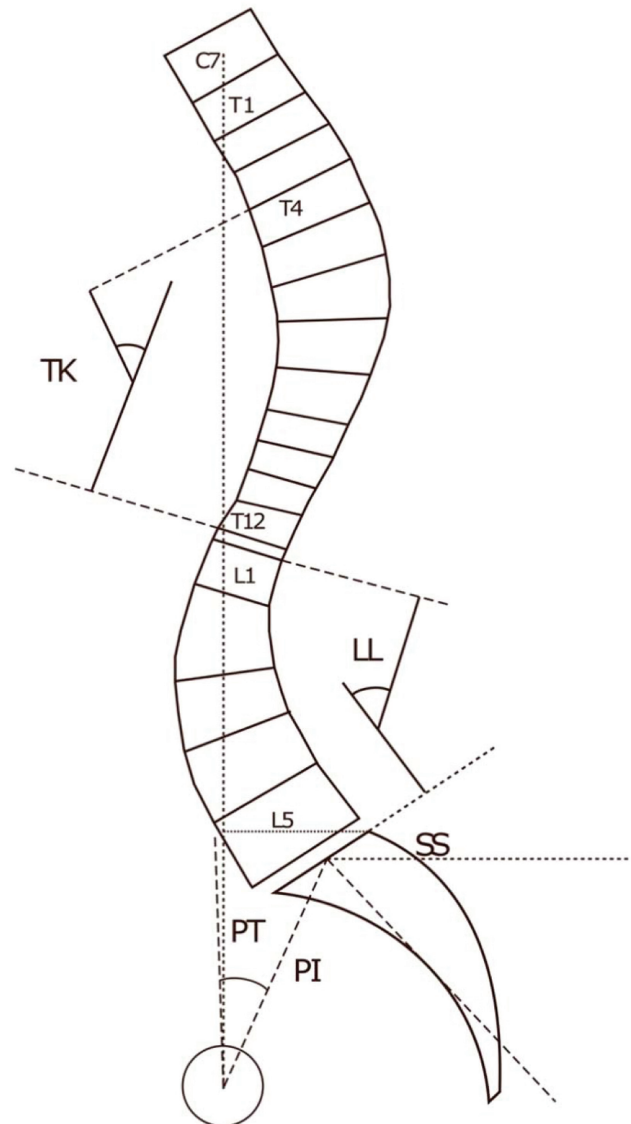


Fig. 1 Pre- and postoperative measurements: thoracic kyphosis (TK) - the angle between the superior endplate of T4 to the inferior endplate of T12; lumbar lordosis (LL) - the angle between the upper endplate of L1 and the upper endplate of S1; sagittal balance - the distance between the C7 plumb line and the posterosuperior corner of S1; pelvic incidence (PI) - the angle between the line perpendicular to the sacral endplate at its midpoint and the line connecting the point to the middle axis of the femoral heads; pelvic tilt (PT) - the angle between the line connecting the midpoint of the sacral endplate to the middle axis of the femoral heads and a vertical line; sacral slope (SS) - the angle between the sacral endplate and the horizontal plane.

statistical comparisons between the groups preoperatively and postoperatively were performed using the Mann-Whitney U test. The paired samples *t* test was used for the comparison of preoperative and postoperative measurements. Values of $p < 0.05$ were considered statistically significant.

The authors obtained approval from the institutional review board for all aspects of the present study.

Results

A total of 19 patients (3 female and 16 male patients; average age at surgery: 18.4 years) who underwent SK correction

surgery were included. The follow-up time varied from 2 to 12 years, with a mean time of 6 years. The apex of the deformity was in the thoracic spine, following this distribution: T7–6 cases; T8–9 cases; T9–4 cases. A mean of 11 levels were fused, and the level of distal fusion was L1 in 3 cases, L2 in 10 cases, L3 in 5 cases, and L4 in 1 case, and all patients underwent a posterior-only procedure. The mean preoperative kyphosis was of 83° , with a mean correction to 57° . The mean preoperative lumbar lordosis was 66° , with a postoperative spontaneous correction to 47° .

Regarding the preoperative pelvic parameters, the average PI, PT and SS were of 48° , 10° and 39° respectively, and, in the postoperative period, these values were of 50° , 16° and 35° respectively. The mean preoperative SB, assessed by the distance from the C7 plumbline to the posterosuperior S1 vertebral body was neutral (negative trend of -8mm) and it was maintained after the surgical correction (-7mm) (► Fig. 2).

Concerning the complications during the follow-up period, a total of three junctional kyphosis were observed (two proximal and one distal) – two requiring revision surgery, one nonunion, and a dehiscence of the surgical wound. The functional scores assessed by the SRS-22 questionnaire were of 4.0 on average. Relating the SRS-22 scores with the imaging parameters, we verified that the SB obtained in the postoperative period had no influence on the functional outcome ($p = 0,125$) nor on the postoperative LL ($p = 0,851$). Although there was a trend towards lower SRS-22 scores with increased postoperative kyphosis, this score did not significantly affect the functional outcome ($p = 0,079$) (► Table 1).

Discussion

The surgical treatment of SK does not consist solely in the correction of the TK, but it is rather a challenge of balance through the sagittal alignment.

Sagittal spinopelvic parameters were evaluated in many areas of spinal deformity, including early-onset scoliosis,⁸ spondylolisthesis,⁹ and adolescent idiopathic scoliosis.¹⁰ However, there is a paucity of literature on sagittal spinopelvic alignment in SK.

Sagittal spinopelvic alignment was linked to health-related quality of life, mainly because the global sagittal imbalance and its compensatory mechanisms were associated to increased energy consumption, which negatively influences the quality of life.^{11,12}

The pathological increase in TK in SK leads to a compensatory development of a lumbar hyperlordosis with the aim of reaching a new state of balance.

In the present study, the mean values of preoperative TK and LL were of 83° and 66° respectively. After surgical correction of hyperkyphosis, the mean value of LL was of 47° , so there was a spontaneous improvement in the lumbar hyperlordosis at levels not included in the fusion, as described in the literature^{13–17} and also verified by Ashraf et al.¹⁶ in a retrospective study of 18 patients submitted to surgical treatment.

We report that the mean preoperative values of PI, PT and SS were of 48° , 10° and 39° respectively. These are consistent

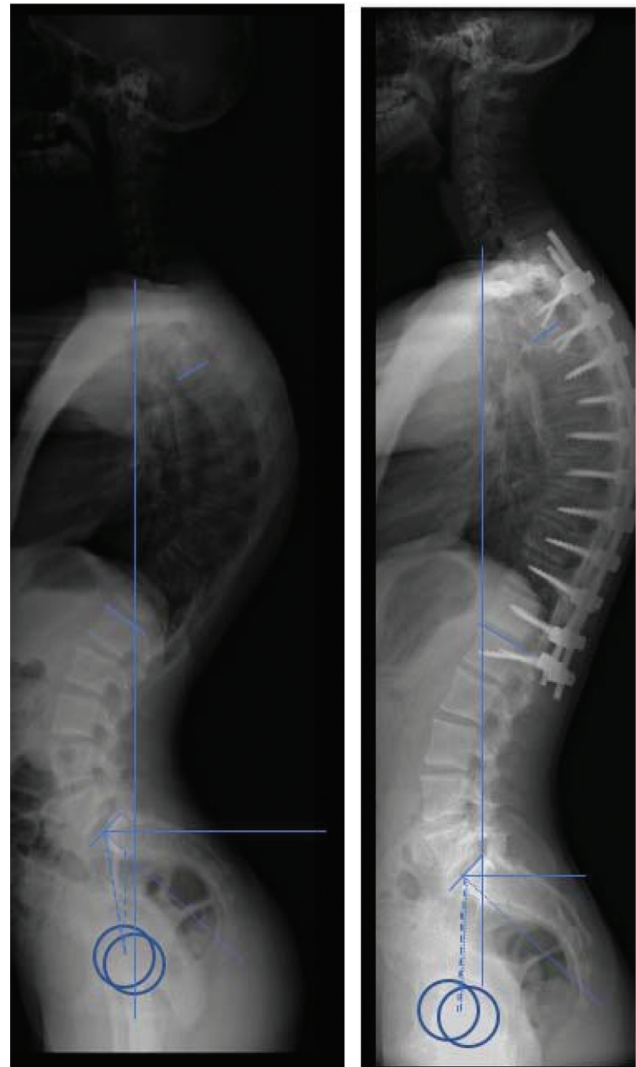


Fig. 2 Clinical case - male, 17 years old. He maintained the neutral sagittal alignment. Improvement in postoperative kyphosis and lumbar lordosis from 80° to 56° and 84° to 55° respectively.

with the previous reports by Mac-Thiong et al.,¹⁸ who described average values of PI, PT and SS as 49° , 8° and 41° respectively, for normal children and adolescents. These observations are consistent with those of the study published by Cahill et al.,¹⁹ who evaluated the differences in spinopelvic parameters among patients with SK and unaffected normal controls, allowing us to conclude that there was no statistically significant difference in the pelvic parameters. Therefore, this suggests that SK is not driven by an inherent problem in the pelvic anatomy resulting in abnormal mechanics in the thoracic or thoracolumbar spine with subsequent secondary vertebral wedging, but rather that the anatomic changes observed at the apex of the deformity in SK are in fact the primary pathologic process.¹⁹

The postoperative SB is an important predictor of functional results when depicting the muscular forces acting on the spine and the associated energy spent.²⁰ In the present study, the mean values of the SB remained within the normal range before and after surgery, which was also described by Guler et al.²¹ after surgical correction of SK.

Table 1 Distribution of postoperative sagittal balance, kyphosis and lumbar lordosis results and functional outcome

Case	Final sagittal balance	Postoperative kyphosis (degrees)	Postoperative lumbar lordosis (degrees)	SRS-22
1	Neutral	42	27	3.5
2	Negative	65	22	3.7
3	Neutral	52	47	4.12
4	Negative	51	37	4.05
5	Neutral	59	47	3.27
6	Neutral	67	45	4
7	Neutral	67	21	4.63
8	Negative	30	23	4.5
9	Positive	69	68	4.2
10	Neutral	41	47	3.8
11	Neutral	74	56	4.05
12	Negative	63	52	4.5
13	Neutral	56	55	4.27
14	Positive	51	62	4.45
15	Negative	67	49	4.1
16	Neutral	69	45	3.2
17	Negative	49	68	4.4
18	Neutral	60	71	4.8
19	Positive	53	64	3.27

Abreviatura: SRS-22, Scoliosis Research Society-22 patient questionnaire.

In the postoperative period, the mean values of the pelvic parameters were of 50° for PI, 16° for PT, and 35° for SS. Although PI is a morphological parameter and therefore should not change, this difference is acceptable, and it can be explained by the subjectivity of the measurements on the radiographs. Regarding PT, it ranges from 0° to 25°, which can justify the increase of pre- to postoperative values, and can be due to the inclusion of patients who had some complications during follow-up. Ultimately, in the postoperative period, the mean values remained within normal limits, which enables the described ratio of pelvic incidence to remain equal to the sum of the PI tilt and the SS.⁴ Other formulas attempt to correlate the sagittal spinal and pelvic parameters in SK. For instance, Berderman et al.²² described a new correlation between parameters such as TK or TLK, PI and LL, and concluded that $(TK - 45^\circ) + (TLK - 0^\circ) + (PI - LL)$, if kept within $\pm 10^\circ$, is a valuable formula to evaluate the global SB in patients with skeletally-mature SK.

The level of distal fusion in SK is a controversial topic, and there must be a balance between minimizing the risk of developing distal junctional problems and preserving the levels of motion.²³ Besides the usual discussion between extending the fusion to the sagittal stable vertebra or the first lordotic vertebra, Zhu et al.²⁴ suggest the type of SK curve should also be considered, stating that the biomechanics of each curve is different. These authors²⁴ suggest that in the thoracolumbar curve type, a shorter fusion should be performed, while in the thoracic one, this instrumentation should be extended until the sagittal stable vertebra. In the

present study, only the thoracic curves were included, and the level of distal fusion mostly coincided with the sagittal stable vertebra (15 versus 4 cases).

The occurrence of complications regarding the surgical treatment of SK has been the object of study of several published works,²⁵ in which a global rate of 14% was reported.

Besides the choice of fusion level, prevention of the development of junctional kyphosis includes, nowadays, the study of spinopelvic parameters, whose results may explain this development.

Junctional kyphosis has incidences that can reach 30%, depending on the study population,²⁶ and although proximal junctional kyphosis (PJK) is more common, distal junctional kyphosis (DJK) is more often implicated in the revision surgery.

While relating the development of DJK with the spinopelvic parameters, Ghasemi et al.²⁷ suggested that there is an increased risk of developing DJK among younger patients, and concluded that patients with higher degrees of TK correction and with more negative absolute SB values had a higher risk of developing this developing complications. However, in the case of DJK in the present study, we did not observe any of these conditions, as this patient had a TK within the preoperative mean values (80°) and a normal SB (+ 10mm), and, regarding his age at the time of surgical correction, he was also close the mean value (18 years).

Concerning PJK, Sardar et al.²⁸ report that a larger TK both before surgery and at the final follow-up tend to be associated with the development of PJK, and this complication was also

found to be directly correlated with the magnitude of the PI.²⁸ In the two cases of PJK in the present study, we found high PI values (59° and 60°), which is in agreement with previously described.

Scheuermann hyperkyphosis is associated with worsening of the quality of life and diminished SRS-22 scores in all domains when compared with other spine deformities, such as adolescent idiopathic scoliosis, as reported by Lonner et al.²⁹ This impairment can be explained by the energy-consuming and often painful compensatory mechanisms while trying to preserve an adequate global SB.¹¹ Glassman et al.³⁰ found that positive SB was linearly correlated with the severity of the back pain, and is the radiographic measurement most frequently associated with adverse outcomes. Moreover, they also state that a successful long-term outcome after TK correction surgery may be more accurately predicted by the restoration of the sagittal plane alignment rather than through an isolated correction of the TK. The mean score of the patients included in the present study was 4 (maximum score: 5), which revealed a good overall functional result. However, when trying to relate these SRS-22 scores with the SB, no statistically significant relationship was established, even though these scores were within the normal range. The SRS-22 scores were not influenced by TK nor LL, albeit we report a trend to lower scores on the SRS-22 with higher degrees of postoperative TK.

There are some limitations to the present study. Firstly, the small sample. Secondly, the retrospective character of the analysis made. Thirdly, all procedures were performed in the same hospital and by the same surgical team.

Conclusion

The surgical treatment of SK aims not only to correct the deformity but also to achieve a global spine balance. We verified a spontaneous improvement in lumbar hyperlordosis at levels not included in the fusion after correction of the TK. Although the postoperative functional results were globally high, we did not find any statistically significant relationship with TK nor LL, even though we reported a trend towards lower scores on the SRS-22 with higher degrees of postoperative TK. Postoperative complications like junctional kyphosis are related not only to factors that are already known – such as the magnitude of curve correction and the selection of fusion levels – but also to new parameters such as sagittal plane alignment. High PI is associated with greater complications regarding the PJK, and these pelvic parameters should be considered at the time of SK surgical treatment, as we concluded. Nevertheless, further studies are needed in this field.

Financial Support

There was no financial support from public, commercial, or non-profit sources.

Conflict of Interests

The authors have no conflict of interests to declare.

References

- Wood KB, Melikian R, Villamil F. Adult Scheuermann kyphosis: evaluation, management, and new developments. *J Am Acad Orthop Surg* 2012;20(02):113–121
- Damborg F, Engell V, Andersen M, Kyvik KO, Thomsen K. Prevalence, concordance, and heritability of Scheuermann kyphosis based on a study of twins. *J Bone Joint Surg Am* 2006;88(10):2133–2136
- Sorensen K. Scheuermann's Juvenile Kyphosis: Clinical Practice, Appearances, Radiography, Aetiology and Prognosis. Philadelphia: Lippincott Williams & Wilkins; 2001
- Le Huec J, Aunoble S, Philippe L, Nicolas P. Pelvic parameters: origin and significance. *Eur Spine J* 2011;20(Suppl 5):564–571
- Lonner BS, Newton P, Betz R, et al. Operative management of Scheuermann's kyphosis in 78 patients: radiographic outcomes, complications, and technique. *Spine (Phila Pa 1976)* 2007;32(24):2644–2652
- Tyrakowski M, Mardjetko S, Siemionow K. Radiographic spinopelvic parameters in skeletally mature patients with Scheuermann disease. *Spine (Phila Pa 1976)* 2014;39(18):E1080–E1085
- Kim YJ, Bridwell KH, Lenke LG, Gattes CR, Rhim S, Cheh G. Proximal junctional kyphosis in adult spinal deformity after segmental posterior spinal instrumentation and fusion: minimum five-year follow-up. *Spine (Phila Pa 1976)* 2008;33(20):2179–2184
- El-Hawary R, Sturm PF, Cahill PJ, et al. Sagittal spinopelvic parameters of young children with scoliosis. *Spine Deform* 2013;1(05):343–347
- Roussouly P, Gollogly S, Berthonnaud E, Labelle H, Weidenbaum M. Sagittal alignment of the spine and pelvis in the presence of L5-s1 isthmus lysis and low-grade spondylolisthesis. *Spine (Phila Pa 1976)* 2006;31(21):2484–2490
- Tanguay F, Mac-Thiong JM, de Guise JA, Labelle H. Relation between the sagittal pelvic and lumbar spine geometries following surgical correction of adolescent idiopathic scoliosis. *Eur Spine J* 2007;16(04):531–536
- Lafage V, Schwab F, Patel A, Hawkinson N, Farcy JP. Pelvic tilt and trunca inclination: two key radiographic parameters in the setting of adults with spinal deformity. *Spine (Phila Pa 1976)* 2009;34(17):E599–E606
- Schwab F, Lafage V, Patel A, Farcy J-P. Sagittal plane considerations and the pelvis in the adult patient. *Spine (Phila Pa 1976)* 2009;34(17):1828–1833
- Hosman AJ, Langeloo DD, de Kleuver M, Anderson PG, Veth RP, Slot GH. Analysis of the sagittal plane after surgical management for Scheuermann's disease: a view on overcorrection and the use of an anterior release. *Spine (Phila Pa 1976)* 2002;27(02):167–175
- Poolman RW, Been HD, Ubags LH. Clinical outcome and radiographic results after operative treatment of Scheuermann's disease. *Eur Spine J* 2002;11(06):561–569
- de Jonge T, Illés T, Bellyei A. Surgical correction of Scheuermann's kyphosis. *Int Orthop* 2001;25(02):70–73
- Ashraf A, Noelle Larson A, Polly DW, Ferski G, Guidera KJ, Mielke CH. Change in Sagittal Plane Alignment Following Surgery for Scheuermann's Kyphosis. *Spine Deform* 2014;2(05):404–409
- Lonner BS, Parent S, Shah SA, et al. Reciprocal Changes in Sagittal Alignment With Operative Treatment of Adolescent Scheuermann Kyphosis-Pro prospective Evaluation of 96 Patients. *Spine Deform* 2018;6(02):177–184
- Mac-Thiong JM, Labelle H, Berthonnaud E, Betz RR, Roussouly P. Sagittal spinopelvic balance in normal children and adolescents. *Eur Spine J* 2007;16(02):227–234
- Cahill PJ, Steiner CD, Dakwar E, et al; Harms Study Group. Sagittal spinopelvic parameters in Scheuermann's kyphosis: a preliminary study. *Spine Deform* 2015;3(03):267–271
- Lamartina C, Berjano P. Classification of sagittal imbalance based on spinal alignment and compensatory mechanisms. *Eur Spine J* 2014;23(06):1177–1189

- 21 Guler O, Akgul T, Korkmaz M, et al. Postoperative changes in sacropelvic junction in short-segment angular kyphosis versus Scheuermann kyphosis. *Eur Spine J* 2017;26(03):928–936
- 22 Bederman SS, Farhan S, Hu X, et al. Sagittal Spinal and Pelvic Parameters in Patients With Scheuermann's Disease: A Preliminary Study. *Int J Spine Surg* 2019;13(06):536–543
- 23 Yanik HS, Ketenci IE, Coskun T, Ulusoy A, Erdem S. Selection of distal fusion level in posterior instrumentation and fusion of Scheuermann kyphosis: is fusion to sagittal stable vertebra necessary? *Eur Spine J* 2016;25(02):583–589
- 24 Zhu W, Sun X, Pan W, et al. Curve patterns deserve attention when determining the optimal distal fusion level in correction surgery for Scheuermann kyphosis. *Spine J* 2019;19(09):1529–1539
- 25 Coe JD, Smith JS, Berven S, et al. Complications of spinal fusion for scheuermann kyphosis: a report of the scoliosis research society morbidity and mortality committee. *Spine (Phila Pa 1976)* 2010;35(01):99–103
- 26 Denis F, Sun EC, Winter RB. Incidence and risk factors for proximal and distal junctional kyphosis following surgical treatment for Scheuermann kyphosis: minimum five-year follow-up. *Spine (Phila Pa 1976)* 2009;34(20):E729–E734
- 27 Ghasemi A, Stubig T, A Nasto L, Ahmed M, Mehdian H. Distal junctional kyphosis in patients with Scheuermann's disease: a retrospective radiographic analysis. *Eur Spine J* 2017;26(03):913–920
- 28 Sardar ZM, Ames RJ, Lenke L. Scheuermann's Kyphosis: Diagnosis, Management, and Selecting Fusion Levels. *J Am Acad Orthop Surg* 2019;27(10):e462–e472
- 29 Lonner B, Yoo A, Terran JS, et al. Effect of spinal deformity on adolescent quality of life: comparison of operative scheuermann kyphosis, adolescent idiopathic scoliosis, and normal controls. *Spine (Phila Pa 1976)* 2013;38(12):1049–1055
- 30 Glassman SD, Bridwell K, Dimar JR, Horton W, Berven S, Schwab F. The impact of positive sagittal balance in adult spinal deformity. *Spine (Phila Pa 1976)* 2005;30(18):2024–2029