



## Original Article

# Acromioclavicular dislocation: postoperative evaluation of the coracoclavicular ligaments using magnetic resonance<sup>☆</sup>



Rafael Salomon Silva Faria, Fabiano Rebouças Ribeiro, Bruno de Oliveira Amin\*, Antonio Carlos Tenor Junior, Miguel Pereira da Costa, Cantídio Salvador Filardi Filho, Cleber Gonçalves Batista, Rômulo Brasil Filho

Hospital do Servidor Público Estadual Francisco Morato de Oliveira, São Paulo, SP, Brazil

## ARTICLE INFO

## Article history:

Received 11 September 2013

Accepted 13 March 2014

Available online 24 April 2015

## Keywords:

Acromioclavicular joint

Ligaments

Magnetic resonance imaging

## ABSTRACT

**Objective:** To radiologically evaluate the healing of the coracoclavicular ligaments after surgical treatment for acromioclavicular dislocation.

**Methods:** Ten patients who had undergone surgical treatment for acromioclavicular dislocation via a posterosuperior route at least one year earlier were invited to return for radiological assessment using magnetic resonance. This evaluation was done by means of analogy with the scale described in the literature for studying the healing of the anterior cruciate ligament of the knee and for measuring the healed coracoclavicular ligaments.

**Results:** A scar structure of fibrous appearance had formed in 100% of the cases. In 50% of the cases, the images of this structure had a good appearance, while the other 50% were deficient.

**Conclusion:** Late postoperative evaluation using magnetic resonance, on patients who had been treated for acute acromioclavicular dislocation using a posterosuperior route in the shoulder, showed that the coracoclavicular ligaments had healed in 100% of the cases, but that this healing was deficient in 50%.

© 2014 Sociedade Brasileira de Ortopedia e Traumatologia. Published by Elsevier Editora Ltda. All rights reserved.

## Luxação acromioclavicular: avaliação pós-operatória dos ligamentos coracoclaviculares por ressonância magnética

## RESUMO

## Palavras chave:

Articulação acromioclavicular

**Objetivo:** Avaliar radiologicamente a cicatrização dos ligamentos coracoclaviculares após o tratamento cirúrgico para luxação acromioclavicular.

<sup>☆</sup> Work developed in the Shoulder and Elbow Group of the Department of Orthopedics and Traumatology, Hospital do Servidor Público Estadual Francisco Morato de Oliveira, São Paulo, SP, Brazil.

\* Corresponding author.

E-mail: [bruno.amin@hotmail.com](mailto:bruno.amin@hotmail.com) (B.d.O. Amin).

<http://dx.doi.org/10.1016/j.rboe.2015.04.007>

2255-4971/© 2014 Sociedade Brasileira de Ortopedia e Traumatologia. Published by Elsevier Editora Ltda. All rights reserved.

Ligamentos  
Imagem por ressonância  
magnética

**Métodos:** Foram convocados 10 pacientes submetidos ao tratamento cirúrgico para luxação acromioclavicular pela via posterossuperior, com tempo de pós-operatório mínimo de um ano, para avaliação radiológica por ressonância magnética. Essa avaliação foi feita por meio de analogia com a escala descrita na literatura para estudo da cicatrização do ligamento cruzado anterior do joelho e pela aferição das medidas dos ligamentos coracoclaviculares cicatrizados.

**Resultados:** Houve formação de estrutura cicatricial aparentemente fibrosa em 100% dos casos. Em 50% dos casos, a imagem dessa estrutura era de bom aspecto à ressonância nuclear magnética e 50% deficiente.

**Conclusão:** A avaliação por ressonância nuclear magnética dos pacientes em pós-operatório tardio de cirurgia para tratamento da luxação acromioclavicular aguda, pela via posterossuperior do ombro, mostrou a cicatrização dos ligamentos coracoclaviculares em 100% dos casos, sendo 50% deficiente.

© 2014 Sociedade Brasileira de Ortopedia e Traumatologia. Publicado por Elsevier Editora Ltda. Todos os direitos reservados.

## Introduction

Acromioclavicular dislocation (ACD) is a traumatic pathological condition of the shoulder that predominantly occurs in young adults. The anatomical and biomechanical alterations caused by the tearing of the coracoclavicular ligaments are a crucial factor in deciding whether to treat the injury surgically or non-surgically.<sup>1-3</sup>

The well-established radiographic classification system described by Rockwood<sup>1</sup> uses the contralateral shoulder as a comparison parameter, as follows: no abnormality of the coracoclavicular distance (ACD grade I); change to the coracoclavicular distance, but less than 25% (ACD grade II); coracoclavicular distance increased by 25–100% (ACD grade III); posterior displacement of the clavicle (ACD grade IV); coracoclavicular space increased by 100–300% (ACD grade V); and coracoclavicular space diminished or inverted (ACD grade VI).

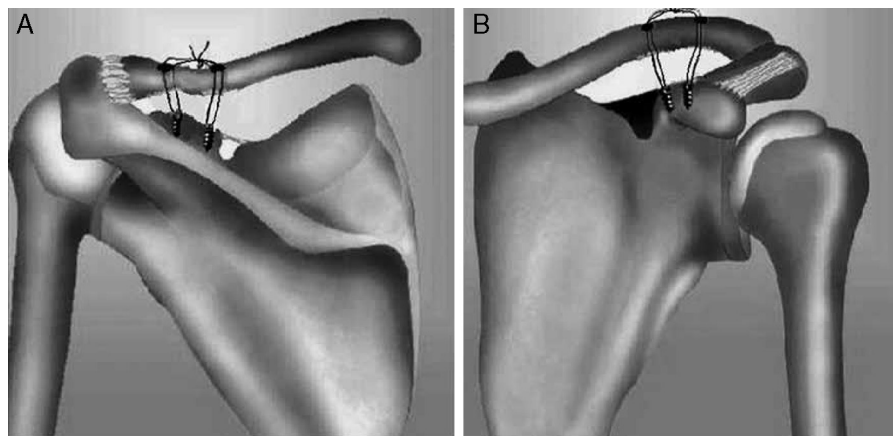
The coracoclavicular ligaments are the main stabilizers of the acromioclavicular joint and the main supports for the upper limbs.<sup>1-3</sup> Nevertheless, little is known about their healing after surgical treatment for ACD.

## Materials and methods

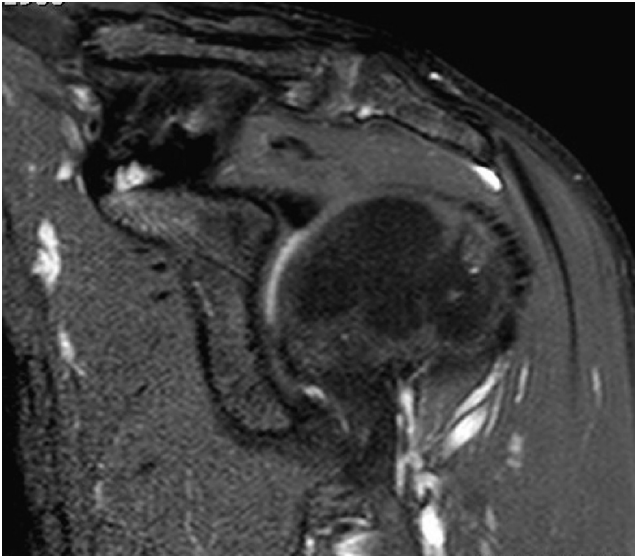
Magnetic resonance imaging (MRI) on 10 patients aged 20 to 50 years (both men and women), with initial diagnoses of ACD grades III to V, was evaluated. These patients were selected randomly (drawn) from among our population. All of them had been operated by the same team and with the same surgical technique: binding of the clavicle to the coracoid process using two metal anchors (5 mm in diameter, with non-absorbable threads), by means of a posterossuperior access in the shoulder<sup>4</sup> (Fig. 1A and B). The minimum postoperative follow-up was one year.

The exclusion criteria were as follows: treatment performed using a closed manner; surgical treatment in which other techniques were used (such as transfer of the coracoclavicular ligaments to the distal clavicle); and age less than 20 or more than 50 years.

The patients who were drawn were asked to come for an MRI examination using a 1.5 T machine, within the standards described in the literature for coracoclavicular ligament evaluation (Fig. 2). Slices were produced in planes parallel to a



**Fig. 1** – Schematic drawing demonstrating the positioning of the anchors and holes drilled in the clavicle, in (A) posterior view and (B) anterior view.



**Fig. 2 – MRI using the standards described for viewing the coracoclavicular ligaments of a patient who underwent surgical treatment for ACD.**

line that was traced out between the apex of the coracoid process and the apex of the lesser tubercle of the humerus. The slices were of thickness 3.5 mm, T1 and T2-weighted, and were produced with the patient in the neutral position. The imaging parameters were as follows: field of view from 145 mm × 145 mm to 150 mm × 150 mm; matrix size of 353 × 512 or 256 × 512; and section thickness of 3.5 mm.<sup>5</sup> The examinations were evaluated jointly by an orthopedist who was a specialist in shoulder and elbow surgery and a trainee physician in the hospital's shoulder and elbow group.

To evaluate the presence and quality of healing of the coracoclavicular ligaments, a scale previously described in the literature was used.<sup>6</sup> This was a scale for evaluating the healing of grafts from the flexor tendons of the knee, which are used in reconstructions following anterior cruciate ligament injury. This scale grades the image of the ligament that was obtained using MRI, into four stages according to their size and signs of homogeneity (Table 1). Ligaments classified as grades I and II correlate with good stability and can therefore be considered to have healed, while those graded as III and IV are considered to present deficient healing or absence of healing.

The geometry of the scar tissue encountered (neoligament) was evaluated using the Impax 6.3 client software.

**Table 1 – Grading for evaluating ligament healing by means of MRI.**

Grade I: Well-defined straight band of normal size with homogenous low-intensity signal.
Grade II: Well-defined straight band with low-intensity signal and points showing high-intensity signal.
Grade III: Thin band with low-intensity signal containing mass with high-intensity signal.
Grade IV: A band with dark indiscernible signal.

Source: Ihara et al.<sup>6</sup>

The following measurements were made: length, measured along the direction of the fibers of the neoligament, from the midpoint of the origin in the clavicle to the midpoint of the insertion in the coracoid process; width, in the coronal plane in its proximal portion (origin in the clavicle) and distal portion (insertion in the coracoid process); angle, measured between the line along which the length was measured and a straight line along the lower edge of the distal clavicle (Fig. 3A-C).

## Results

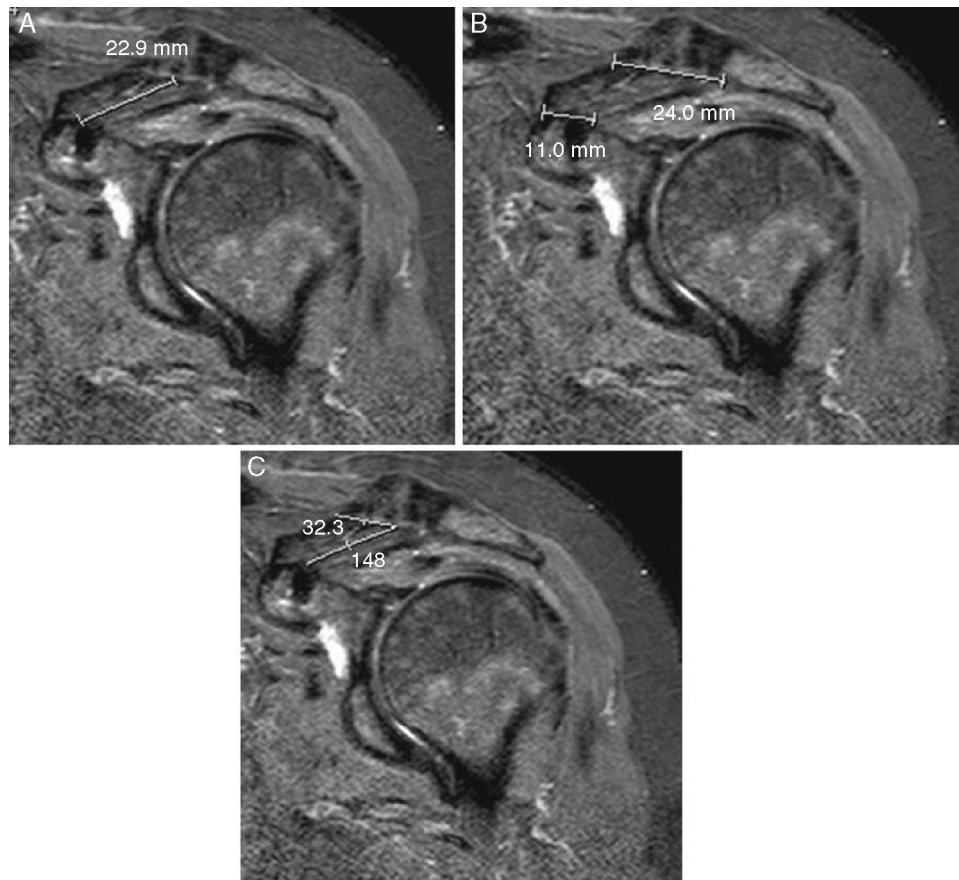
It was observed that in the MRI examination, all the patients presented an image of scar tissue of fibrous appearance that connected the distal clavicle to the coracoid process. In five examinations that were classified as grade II, it was considered that good ligament healing had been achieved. The other five examinations showed deficient healing. Three were classified as grade III and two as grade IV.

Regarding the geometry of the healed coracoclavicular ligaments, no distinction was observed between the two ligaments (conoid and trapezoid). Only a single scar structure was observed, with variation in measurements between the patients (Table 2). However, in most cases, the new ligament was seen to have maintained the trapezoidal appearance of the coracoclavicular ligaments, such that their clavicular portion was wider than their distal portion at the coracoid process. The examinations on the patients classified as grade IV (two cases) did not allow effective measurements, because of their anatomical irregularities.

## Discussion

To evaluate the healing of the coracoclavicular ligaments, anatomical parameters that had previously been established for knee ligament injuries were used in the present study, given that no preestablished parameters for the coracoclavicular ligaments were encountered in the literature. The time period taken into consideration for healing to take place among the patients who were treated surgically for ACD was determined based on the minimum postoperative time needed for the anterior cruciate ligament of the knee, reconstructed using a graft from the flexor tendons, to achieve a histological state similar to the original. This ranges from 30 to 52 weeks, according to the literature consulted.<sup>7</sup> In a study conducted by Clayer et al.,<sup>8</sup> using sequential MRI examinations on six patients who underwent surgical treatment for ACD, in which an absorbable loop was used for coracoclavicular fixation, it was observed that six months after the operation, a structure of fibrous appearance connecting the coracoid process to the clavicle could already be seen.

MRI is an efficient and accurate examination for detailed evaluations on the ligament structures of the joints of the human body, such as the shoulder and knee.<sup>9</sup> Nemec et al.<sup>10</sup> compared MRI to radiography for classifying ACD that occurred in 44 patients, using Rockwood's system. The examinations were concordant for the classification of the injury in only 52.2% of the cases, which demonstrates that MRI is a more specific examination.



**Fig. 3** – Parameters used for measuring the neoligament between the coracoid process and the clavicle, in a patient at a late postoperative time after surgical treatment for ACD. A, length; B, width at the origin in the clavicle and insertion in the coracoid process; C, angle in relation to the distal clavicle.

In our study, a structure of scar tissue characteristics was observed using MRI in 100% of the cases operated. It had a fibrous appearance, with trapezoidal format and coracoclavicular ligature. However, there were signs of deficient healing in 50% of the cases. These findings were compatible with those of the study by Clayer et al.,<sup>8</sup> in which formation

of an anatomical structure of fibrous appearance was also observed in the regions of the coracoclavicular ligaments, which suggests that these ligaments had healed.

In an anatomical study on the coracoclavicular ligaments, Harris et al.<sup>11</sup> made measurements on 24 shoulders of cadavers and found the following means: length of the conoid

**Table 2** – Results from late postoperative MRI evaluations on patients who were treated surgically for ACD.

Patients	Healing classification	Longitudinal length of coracoclavicular neoligament	Width of neoligament (clavicular)	Width of neoligament (coracoid)	Angle of neoligament
1	Grade II	23.7 mm	23.9 mm	14.3 mm	44°
2	Grade IV	n.m.	n.m.	n.m.	n.m.
3.	Grade II	23.0 mm	31.9 mm	22.4 mm	61°
4	Grade III	10.5 mm	27.6 mm	12.8 mm	69°
5	Grade II	29.1 mm	34.2 mm	25.4 mm	48°
6	Grade III	13.3 mm	29.5 mm	17.0 mm	20°
7	Grade II	15.4 mm	18.6 mm	17.3 mm	29°
8	Grade IV	n.m.	n.m.	n.m.	n.m.
9	Grade II	17.0 mm	32.4 mm	20.2 mm	75°
10	Grade III	23.2 mm	20.1 mm	12.3 mm	74°
Mean	-	19.3 mm	27.3 mm	17.7 mm	52°

n.m., not measurable.

ligament, 19.4 mm; length of the trapezoid ligament, 19.3 mm; width of the origin of the conoid ligament on the clavicle, 20.6 mm; width of the insertion of the conoid ligament in the coracoid process, 10.6 mm; width of the origin of the trapezoid ligament on the clavicle, 21.7 mm; and width of the insertion of the trapezoid ligament in the coracoid process, 14.0 mm. In our study using MRI, similar means for the length of the neoligament that formed after the operation were obtained. The means for the widths could not be compared because of the differences in shape between the coracoclavicular ligaments and the neoligament.

No clinical and biomechanical correlations were made in relation to the findings of this study, because of the small sample space.

---

## Conclusion

The late postoperative MRI evaluations on patients who were treated surgically for acute ACD by means of a posterolateral access in the shoulder showed healing of the coracoclavicular ligaments in 100% of the cases, although 50% were deficient.

---

## Conflicts of interest

The authors declare no conflicts of interest.

---

## REFERENCES

- Collins DN. Disorders of acromioclavicular joint. In: Rockwood CA Jr, Matsen FA 3rd, Wirth MA, Lippitt SB, editors. *The shoulder*. 4th ed. Philadelphia: Saunders Elsevier; 2009. p. 453-526.
- Costic RS, Vangura A, Fenwick JA, Rodosky MW, Debski RE. Viscoelastic behavior and structural properties of the coracoclavicular ligaments. *Scand J Med Sci Sports*. 2003;13(5):305-10.
- Dawson PA, Adamson GJ, Pink MM, Kornswiet M, Lin S, Shankwiler JA, Lee TQ. Relative contribution of acromioclavicular joint capsule and coracoclavicular ligaments to acromioclavicular stability. *J Shoulder Elbow Surg*. 2009;18(2):237-44.
- Dal Molin DC, Ribeiro FR, Brasil Filho R, Filardi Junior CS, Tenor Junior AC, Stipp WN, et al. Via de acesso cirúrgico posterossuperior para o tratamento das luxações acromioclaviculares: resultados de 84 casos operados. *Rev Bras Ortop*. 2012;47(5):563-7.
- Alyas F, Curtis M, Speed C, Saifuddin A, Connell D. MR imaging appearances of acromioclavicular joint dislocation. *Radiographics*. 2008;28(2):463-79.
- Ihara H, Miwa M, Deya K, Torisu K. MRI of anterior cruciate ligament healing. *J Comput Assist Tomogr*. 1996;20(2):317-21.
- Fu FH, Bennett CH, Lattermann C, Ma CB. Current trends in anterior cruciate ligament reconstruction. Part I: Biology and biomechanics of reconstruction. *Am J Sports Med*. 1999;27(6):821-30.
- Clayer M, Slavotinek J, Krishnan J. The results of coraco-clavicular slings for acromio-clavicular dislocation. *Aust N Z J Surg*. 1997;67(6):343-6.
- Cohen M, Marcondes FB. Lesões ligamentares. In: Cohen M, Mattar Júnior R, Garcia Filho RJ, editors. *Tratado de ortopedia*. Roca: São Paulo; 2007. p. 401-11.
- Nemec U, Oberleitner G, Nemec SF, Gruber M, Weber M, Czerny C, Krestan CR. MRI versus radiography of acromioclavicular joint dislocation. *AJR Am J Roentgenol*. 2011;197(4):968-73.
- Harris RI, Vu DH, Sonnabend DH, Goldberg JA, Walsh WR. Anatomic variance of the coracoclavicular ligaments. *J Shoulder Elbow Surg*. 2001;10(6):585-8.