



## Original article

# Measurement of the tendon of the biceps brachii after tenotomy: study on cadavers<sup>☆</sup>



Anderson Cunha Machado, Fabiano Rebouças Ribeiro, Samuel Machado Martins\*, Rômulo Brasil-Filho, Antonio Carlos Tenor-Junior, Miguel Pereira da Costa

Hospital do Servidor Público Estadual de São Paulo, São Paulo, SP, Brazil

## ARTICLE INFO

## Article history:

Received 28 April 2014

Accepted 29 July 2014

Available online 3 July 2015

## Keywords:

Shoulder joint

Glenoid cavity

Tenotomy

## ABSTRACT

**Objective:** To evaluate the influence of elbow and forearm range of motion on the distal excursion of the long head of the biceps (LHB).

**Methods:** The distal excursion of the LHB after tenotomy of the shoulders of eight cadavers was ascertained by measuring the distance between a point marked out on the LHB, 3 cm from the anterolateral border of the acromion, and its position at different degrees of elbow flexion, using a digital pachymeter. The measurements at elbow flexion of 135°, 90°, 45° and 0° were noted: these angles were established using a goniometer. The measurements were made with the forearm in neutral, supination and pronation positions.

**Results:** Differences between the mean measurements of the distal excursion of the LHB (total sample) were observed between the degrees of elbow flexion ( $p < 0.01$ ). However, no statistical differences were observed between the different forearm positions, between the sides, genders and ages of the cadavers studied.

**Conclusion:** Progressive extension of the elbow caused progressive distal excursion of the LHB, but without interference in the forearm position, gender, side or age of the cadavers studied.

© 2014 Sociedade Brasileira de Ortopedia e Traumatologia. Published by Elsevier Editora Ltda. All rights reserved.

## Mensuração do tendão do bíceps braquial após tenotomia: estudo em cadáveres

## RESUMO

**Objetivo:** Avaliar a influência da amplitude de movimento do cotovelo e do antebraço na excursão distal da cabeça longa do bíceps (CLB).

**Métodos:** Verificou-se a excursão distal da cabeça longa do bíceps (CLB) após tenotomia em ombros de oito cadáveres, por meio da aferição da distância entre um ponto demarcado na cabeça longa do bíceps (CLB) a 3 cm da borda anterolateral do acrômio em flexão máxima e

## Palavras-chave:

Articulação do ombro

Cavidade glenoide

Tenotomia

<sup>☆</sup> Work performed within the Shoulder and Elbow Group, Orthopedics and Traumatology Service, Hospital do Servidor Público Estadual, São Paulo, SP, Brazil.

\* Corresponding author.

E-mail: [samuellmm1@hotmail.com](mailto:samuellmm1@hotmail.com) (S.M. Martins).

<http://dx.doi.org/10.1016/j.rboe.2015.06.012>

2255-4971/© 2014 Sociedade Brasileira de Ortopedia e Traumatologia. Published by Elsevier Editora Ltda. All rights reserved.

sua posição em diferentes graus de flexão do cotovelo, com o uso de um paquímetro digital. Foram anotadas as medidas nos graus de flexão do cotovelo 135°, 90°, 45° e 0°, estabelecidas com o uso de um goniômetro. As medidas foram tomadas com o antebraço em posição neutra, supinação e pronação.

**Resultados:** Observou-se diferença entre as médias das medidas da excursão distal da cabeça longa do bíceps (CLB) (amostra total) entre os graus de flexão do cotovelo ( $p < 0,01$ ). Todavia, não foi encontrada diferença estatística entre diferentes posições do antebraço, entre os lados, gêneros e idades dos cadáveres estudados.

**Conclusão:** A extensão progressiva do cotovelo ocasionou a excursão distal progressiva da cabeça longa do bíceps (CLB), mas sem interferência da posição do antebraço, gênero, lado e idade dos cadáveres estudados.

© 2014 Sociedade Brasileira de Ortopedia e Traumatologia. Publicado por Elsevier Editora Ltda. Todos os direitos reservados.

## Introduction

The long head of the tendon of the biceps brachii muscle (LHB) is developed at around the seventh to eighth week of gestation and it becomes differentiated starting from the mesoderm. It is described as continuous with the labrum of the glenoid and the supraglenoid tubercle, and it passes anteriorly and superiorly to the head of the humerus before entering the bicipital groove.<sup>1,2</sup> It is intra-articular and extrasynovial and slides passively over the head of humerus during abduction or rotation. Its length is 9 cm and its diameter is 5–6 mm. Its innervation is through a network of sensory fibers of the sympathetic nervous system.<sup>3–5</sup>

The biceps extends from the scapula to the forearm and has functions relating to the shoulder and elbow. Its function relating to the elbow has been well established and includes both flexion and supination. On the other hand, in relation to the shoulder, although several functions have been attributed, the exact role of the LHB remains a matter of controversy.<sup>6</sup> Electromyographic analyses have shown that the LHB serves as a stabilizer in unstable joints, but not in stable shoulders.<sup>7</sup> Biomechanical studies have demonstrated that the tendon acts as a dynamic depressor of the head of the humerus, but this has not been proven clinically.<sup>8,9</sup> Kuhn et al.<sup>10</sup> demonstrated its importance as a restrictor of external rotation of the abducted arm.

Lesions of the superior glenoid that involve the LHB are called SLAP lesions (superior labrum, anterior and posterior). They were first described at the beginning of the 1990s by Snyder et al.<sup>11</sup> The conservative or surgical treatment for these lesions has been well established, but there has never been a consensus regarding the postoperative rehabilitation treatment. There are protocols described in the current literature,<sup>12,13</sup> in which early mobility of the extended elbow is avoided because of doubts regarding the consequent tensioning of the proximal LHB and superior glenoid labrum, which were reinserted during the operation. These actions could cause failure of healing and a new injury.<sup>12,13</sup>

The objective of this study was to evaluate the influence of the range of motion of the elbow and forearm on the distal excursion of the LHB.

## Methods

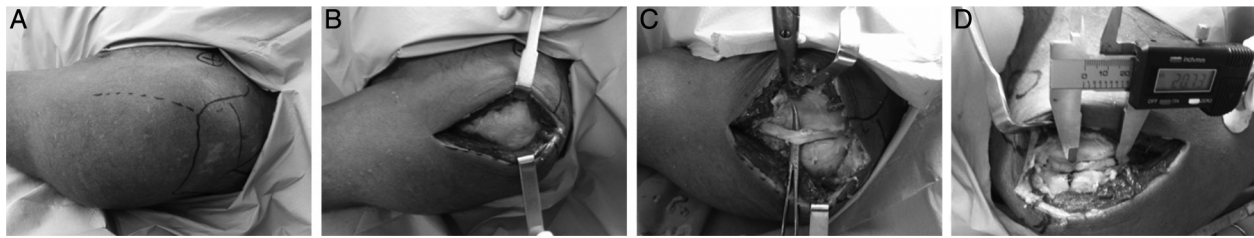
This study was approved by our institution's research ethics committee (number: CAAE 19893114.6.0000.5463). Sixteen shoulders of eight cadavers obtained from the Death Verification Service of the University of São Paulo (SVOC-USP) were dissected. None of these cadavers presented any fractures of the upper limbs, local deformities or scarring. The dissections were performed by means of an anterolateral access measuring 10 cm (Fig. 1A), followed by dissection between the anterior and lateral deltoid muscle (Fig. 1B) so as to approach and dissect the LHB (Fig. 1C).

Using a surgical pen, a line perpendicular to the LHB was marked out, 3 cm distally to the anterolateral border of the acromion. Tenotomy of the LHB was performed at its origin in the supraglenoid tubercle, with the elbow at maximum flexion. The distal excursion of the LHB was verified by measuring the distance between the line marked out on the bicipital tendon and needles placed at the edge of the line previously established on the LHB, using a digital pachymeter (Lee Tools, Houston, USA) (Fig. 1D), as the elbow was extended. Measurements were noted at the following degrees of elbow flexion: 135°, 90°, 45° and 0°, which were established using a goniometer. The measurements were made with the forearm in the neutral, supination and pronation positions.

## Statistical analysis

To compare the results from the measurements on the distal excursion of the LHB, the Friedman test was used. To determine the measurements between which statistically significant differences occurred, the Wilcoxon test was used. For all the tests, the rejection level for the hypothesis of nullity was 0.05 (significance level of 95%).

The Friedman and Wilcoxon tests were also used to compare the results from the measurements on the excursion of the LHB separately and on the entire sample. To compare the results from the measurements according to sex and side studied, the Mann-Whitney test was used. To evaluate the relationship between age and the results from the measurements made, the Spearman correlation was used.



**Fig. 1 – Tenotomy procedure on a cadaver. (A) Marking out the bone anatomical parameters and access route; (B) access via anterolateral route; (C) dissection of the LHB from its groove to its origin in the glenoid; (D) measurement of the excursion of the LHB after proximal tenotomy, with elbow flexion at 135°, 90°, 45° and 0°.**

## Results

Among the eight cadavers dissected, five were female and three were male. There were eight right shoulders and eight left shoulders (Table 1). The mean value for the distal excursion of the LHB with the forearm in the neutral position and at 135° of elbow flexion was 1.41 mm; at 90°, 13.97 mm; at 45°, 18.01 mm; and at 0°, 22.53 mm (Table 2). When these measurements were made with the forearm moved into pronation and

supination positions, there were no differences in relation to the above measurements.

Comparisons between the measurements on the distal excursion of the LHB showed significant differences ( $p < 0.001$ ), considering the entire sample, at all degrees of elbow flexion (Table 2). On the other hand, there were no statistical differences between the right and left sides (Table 3), between the male and female sexes (Table 4) or between the ages (Table 5), among the cadavers studied.

**Table 1 – Measurements (in mm, using a digital pachymeter) of the distal excursion at elbow flexions of 135°, 90°, 45° and 0° (angles obtained by means of a goniometer).**

Cadaver	Age	Sex	Side	Excursion at 135°	Excursion at 90°	Excursion at 45°	Excursion at 0°
1	76	F	R	1.51	17.59	19.08	25.62
			L	1.45	15.16	21.16	25.76
2	72	F	R	1.88	12.15	17.53	21.13
			L	0.99	12.84	18.32	21.06
3	64	M	R	1.25	13.13	19.06	23.07
			L	1.66	14.25	20.15	23.99
4	75	F	R	1.58	12.88	16.5	22.54
			L	1.57	11.98	15.84	21.4
5	58	M	L	1.48	14.85	16.41	21.63
			R	1.52	14.23	17.02	20.73
6	72	F	R	1.6	17.9	19.76	26.43
			L	1.51	16.9	19.6	26.12
7	69	M	R	1.27	12.14	17.16	21.19
			L	1.5	13.13	18	21.77
8	88	F	R	1.15	13	16.49	19.18
			L	1.16	11.31	16.02	18.85

**Table 2 – Statistical analysis on the measurements of the distal excursion of the LHB in relation to the total sample.**

Total sample	General			
	135°	90°	45°	0°
Mean	1.44	13.97	18.01	22.53
Median	1.51	13.13	17.77	21.70
Standard deviation	0.22	2.03	1.64	2.41
Q1	1.27	12.67	16.50	21.11
Q3	1.57	14.93	19.21	24.40
N	16	16	16	16
IC	0.11	1.00	0.80	1.18
p value	<0.001			

**Table 3 – Statistical analysis on the measurements of the distal excursion of the LHB in relation to the sides.**

Side	Mean	Median	Standard deviation	Q1	Q3	N	IC	p value
Excursion at 135°								
Right	1.47	1.52	0.24	1.27	1.59	8	0.16	0.495
Left	1.42	1.49	0.22	1.38	1.53	8	0.16	
Excursion at 90°								
Right	14.13	13.07	2.33	12.70	15.07	8	1.61	0.875
Left	13.80	13.69	1.84	12.63	14.93	8	1.27	
Excursion at 45°								
Right	17.83	17.35	1.29	16.89	19.07	8	0.89	0.916
Left	18.19	18.16	2.00	16.31	19.74	8	1.39	
Excursion at 0°								
Right	22.49	21.87	2.49	21.03	23.71	8	1.72	0.834
Left	22.57	21.70	2.50	21.32	24.43	8	1.73	

**Table 4 – Statistical analysis on the measurements of the distal excursion of the LHB in relation to sex.**

Sex	Mean	Median	Standard deviation	Q1	Q3	N	IC	p value
Excursion at 135°								
Female	1.44	1.51	0.26	1.23	1.58	10	0.16	0.914
Male	1.45	1.49	0.16	1.32	1.52	6	0.13	
Excursion at 90°								
Female	14.17	12.94	2.49	12.32	16.47	10	1.54	0.828
Male	13.62	13.68	1.00	13.13	14.25	6	0.80	
Excursion at 45°								
Female	18.03	17.93	1.83	16.49	19.47	10	1.14	1.000
Male	17.97	17.58	1.41	17.06	18.80	6	1.13	
Excursion at 0°								
Female	22.81	21.97	2.93	21.08	25.73	10	1.82	0.828
Male	22.06	21.70	1.23	21.30	22.75	6	0.98	

**Table 5 – Statistical analysis on the measurements of the distal excursion of the LHB in relation to age.**

	Age	
	Corr	p value
Excursion at 135°	-21.6%	0.422
Excursion at 90°	-19.7%	0.466
Excursion at 45°	-12.2%	0.653
Excursion at 0°	-8.9%	0.742

## Discussion

This study is in agreement with the study conducted by Gramstad et al.,<sup>14</sup> with evidence of increasing distal excursion of the LHB as the elbow is extended. On the other hand, according to those authors, not only elbow extension but also pronation of the forearm was associated with increased tension on the LHB, and on the superior labrum of the glenoid. In our observations, no differences in distal excursion of the LHB were seen with regard to the positioning of the forearm (pronation or supination). This difference in results can possibly be explained by the fact that those authors made their measurements with the shoulder abducted at 60°, whereas in our study, the measurements were made with the shoulder adducted against the body.

According to Wilk et al.,<sup>13</sup> in postoperative treatment for SLAP lesions, active and passive elbow extension exercises are indicated starting in the first ten days after the operation, only for patients who underwent simple debridement (types I and III of Snyder's classification). However, among patients who underwent repairs to SLAP lesions (types II and IV of Snyder's classification), early complete extension of the elbow and the consequent proximal bicipital tensioning should be avoided. This guidance is concordant with the findings from our study, since greater distal excursion of the LHB after tenotomy at its origin was demonstrated as the elbow was progressively extended.

## Conclusions

After tenotomy at the origin of the LHB, progressive extension of the elbow caused progressive distal excursion of the LHB, but without interference from the position of the forearm or from the sex, side or age of the cadavers studied.

## Conflicts of interest

The authors declare no conflicts of interest.

---

## Acknowledgements

The authors thank the orthopedics team at Hospital do Servidor Público Estadual, São Paulo, and the team of the Death Verification Service for their support in carrying out this study.

## REFERENCES

---

- Gardner E, Gray DJ. Prenatal development of the human shoulder and acromioclavicular joints. *Am J Anat.* 1953;92(2):219-76.
- Jobe C. Gross anatomy of the shoulder. In: Rockwood C, editor. *The shoulder.* Philadelphia: Elsevier; 2009.
- Hitchcock HH, Bechtol CO. Painful shoulder: observations on the role of the tendon of the long head of the biceps brachii in its causation. *J Bone Joint Surg Am.* 1948;30(2):263-73.
- Alpantaki K, McLaughlin D, Karagogeos D, Hadjipavlou A, Kontakis G. Sympathetic and sensory neural elements in the tendon of the long head of the biceps. *J Bone Joint Surg Am.* 2005;87(7):1580-3.
- Bey MJ, Elders GJ, Huston LJ, Kuhn JE, Blasler RB, Soslowsky LJ. The mechanism of creation of superior labrum, anterior, and posterior lesions in a dynamic biomechanical model of the shoulder: the role of inferior subluxation. *J Shoulder Elbow Surg.* 1998;7(4):397-401.
- Sethi N, Wright R, Yamaguchi K. Disorders of the long head of the biceps tendon. *J Shoulder Elbow Surg.* 1999;8(6):644-54.
- Kim SH, Ha KI, Kim HS, Kim SW. Electromyographic activity of the biceps brachii muscle in shoulders with anterior instability. *Arthroscopy.* 2001;17(8):864-8.
- Kumar VP, Satku K, Balasubramaniam P. The role of the long head of biceps brachii in the stabilization of the head of the humerus. *Clin Orthop Relat Res.* 1989;244:172-5.
- Warner JJ, McMahon PJ. The role of the long head of the biceps brachii in superior stability of the glenohumeral joint. *J Bone Joint Surg Am.* 1995;77(3):366-72.
- Kuhn JE, Huston LJ, Soslowsky LJ, Shyr Y, Blasler RB. External rotation of the glenohumeral joint: ligament restraints and muscle effects in the neutral and abducted positions. *J Shoulder Elbow Surg.* 2005;14 1 Suppl S:39S-48S.
- Snyder SJ, Karzel RP, Del Pizzo W, Ferkel RD, Friedman MJ. SLAP lesions of the shoulder. *Arthroscopy.* 1990;6(4):274-9.
- Andrews JR, Carson WG, McLeod WD. Glenoid labrum tears related to the long head of the biceps. *Am J Sports Med.* 1985;13(5):337-41.
- Wilk KE, Reinold MM, Dugas JR, Arrigo CA, Moser MW, Andrews JR. Current concepts in the recognition and treatment of superior labral (SLAP) lesions. *J Orthop Sports Phys Ther.* 2005;35(5):273-91.
- Gramstad GG, Sears BW, Marra G. Variation of tension in the long head of the biceps tendon as a function of limb position with simulated biceps contraction. *Int J Shoulder Surg.* 2010;4(1):8-14.