


Acute Normovolemic Hemodilution in Spinal Deformity Surgery

Hemodiluição normovolêmica aguda em cirurgias de deformidade da coluna

Marianna Fergutz Santos Batista¹  Caroline Oliveira Costa¹ Emiliano Neves Vialle¹
Joana Bretas Rondon Cabral Guasque¹ Joana Zulian Fiorentin¹ Camila Santiago Souza¹

¹Orthopedics and Traumatology Service, Hospital Universitário Cajuru, Pontifícia Universidade Católica do Paraná (PUC-PR), Curitiba, PR, Brazil

Address for correspondence Marianna Fergutz Santos Batista, MD, Serviço de Ortopedia e Traumatologia, Hospital Universitário Cajuru, Pontifícia Universidade Católica do Paraná (PUC-PR), Curitiba, PR, Brasil (e-mail: mari_fbatista@hotmail.com).

Rev Bras Ortop 2019;54:516–523.

Abstract

Objective To prospectively compare the clinical and laboratorial aspects of patients undergoing spine deformity surgery, using the acute normovolemic hemodilution technique with tranexamic acid, versus a control group with tranexamic acid alone, and to evaluate the influence of hemodilution in intraoperative bleeding and the need for homologous transfusion.

Materials and Methods Comparative prospective study with patients aged between 12 and 65 years undergoing spine deformity surgery with the acute normovolemic hemodilution technique associated with tranexamic acid versus a control group to which only tranexamic acid (15 mg/kg) was administered. Laboratorial exams were performed and analyzed in three different moments.

Results A total of 30 patients were included in the present study: 17 in the hemodilution group, and 13 in the control group. The mean duration of the surgery in the hemodilution group was longer. The number of levels submitted to surgery ranged from 7 to 16 in the hemodilution group, and from 4 to 13 in the control group. Osteotomy, predominantly of the posterior kind, was performed in 20 patients. There was more intraoperative bleeding in the control group. All patients were stable during the procedures. Only 6 participants needed homologous blood transfusion, mostly from the control group ($p > 0.05$).

Conclusion There was no significant difference between the two groups regarding the need for blood transfusion and intraoperative bleeding. The severity of the deformity was the main determinant for homologous blood transfusion.

Keywords

- ▶ hemodilution/ methods
- ▶ bleeding
- ▶ autologous blood transfusion
- ▶ spine
- ▶ scoliosis

Resumo

Objetivo Comparar de modo prospectivo os parâmetros clínicos e laboratoriais dos pacientes submetidos a hemodiluição normovolêmica aguda associada ao ácido tranexâmico com um grupo de controle que recebeu apenas ácido tranexâmico, durante cirurgia de correção de deformidades da coluna, e avaliar a influência da técnica de hemodiluição no sangramento perioperatório e a necessidade de transfusão de sangue homólogo.

* Originally Published by Elsevier Editora Ltda.

received
December 10, 2017
accepted
February 21, 2018

DOI <https://doi.org/10.1016/j.rbo.2018.02.004>.
ISSN 0102-3616.

Copyright © 2019 by Sociedade Brasileira de Ortopedia e Traumatologia. Published by Thieme Revinter Publicações Ltda, Rio de Janeiro, Brazil

License terms



Palavras-chave

- ▶ hemodiluição/ métodos
- ▶ sangramento
- ▶ transfusão de sangue autóloga
- ▶ coluna vertebral
- ▶ escoliose

Materiais e Métodos Estudo prospectivo comparativo, com pacientes entre 12 e 65 anos submetidos a cirurgia para correção de deformidades da coluna vertebral, com a técnica de hemodiluição normovolêmica aguda associada ao ácido tranexâmico, versus grupo de controle com ácido tranexâmico isolado na dose de 15 mg/kg. Exames laboratoriais foram feitos e analisados em três momentos de avaliação diferentes.

Resultados Participaram deste estudo 30 pacientes: 17 no grupo de hemodiluição e 13 no grupo de controle. O tempo médio de cirurgia foi maior para o grupo de hemodiluição. O número de níveis operados variou entre 7 e 16 no grupo de hemodiluição, e entre 4 e 13 no grupo de controle. Fez-se osteotomia, predominantemente posterior, em 20 pacientes. O valor médio de sangramento intraoperatório foi maior no grupo de controle. Os parâmetros clínicos se mantiveram estáveis durante todos os procedimentos. Apenas 6 pacientes necessitaram de transfusão sanguínea homóloga, a maioria dos quais pertencia ao grupo de controle ($p > 0,05$).

Conclusão Não houve diferença significativa entre os dois grupos quanto à necessidade de transfusão e sangramento intraoperatório. A gravidade da deformidade foi o principal fator determinante da transfusão.

Introduction

Major surgeries, such as corrections of spinal deformities, can lead to increased bleeding. In order to control hemostasis, antifibrinolytic agents may be used, as well as intravenous volemic replacement with acellular solutions or with homologous or autologous blood derivatives.¹

The homologous transfusion exposes the patient to the risk of pulmonary, allergic, hemolytic, immuno-allergic reactions and acquisition of infectious-contagious diseases.² Autologous transfusion can be obtained with a low operational cost by previous donations, reutilization of the perioperative blood or acute normovolemic hemodilution (ANH), with which complications are avoided.³

The ANH technique consists of blood withdrawal immediately before or after anesthetic induction,³ followed by dilution with colloids and/or crystalloids without reducing the circulating volume.⁴ Its use has been indicated for surgeries with increased risk of bleeding.⁵

The objective of the present study was to prospectively compare the clinical and laboratory parameters of patients submitted to ANH associated with tranexamic acid with a control group using tranexamic acid alone, during corrective surgery of spinal deformities, in order to evaluate the influence of this technique in bleeding, the necessity of homologous transfusion and to identify adverse reactions and complications.

Materials and Methods

The present study was approved by the Ethics Committee of our institution through "Plataforma Brasil" with the number of the Certificate of Presentation for Ethical Appreciation (CAAE- 47883615.0.0000.0020).

A total of 30 patients undergoing elective surgery to correct deformities in the spine were included. They were aged between 12 and 65 years, and were divided according to the

classification of the American Society of Anesthesiology (ASA) as ASA I, II or III, without contraindications to the proposed anesthetic/surgical technique. The exclusion criteria were increased risk of coronary artery disease, cerebrovascular disease and valvulopathy, and patients with acute renal failure, bronchopneumonia and coagulopathies.

The patients were divided randomly between the ANH and control groups. All patients underwent total venous general anesthesia with remifentanil (0.1-0.3 mcg/kg/min), propofol (100-200 mcg/kg/min) and cisatracurium (attack: 0.15 mg/kg; maintenance: 0.3 mg/kg) when the potential evoked was not monitored. After anesthetic induction, every patient received 15 mg/kg of tranexamic acid and 0.1 mg/kg of morphine. The use of adjuvant drugs, as it did not interfere in the results, was left at the discretion of the anesthesiologist. The heart rate, neuromuscular blockade (train of four), pulse oximetry, cardioscopy, ST segment variation, invasive blood pressure and probe diuresis were monitored.

Laboratory tests (hemoglobin [Hb], hematocrit [Ht], prothrombin activation time [PAT], activated partial thromboplastin time [APTT], sodium, potassium, magnesium, ionic calcium, arterial blood gas, and lactate) were performed shortly after the anesthetic induction, after the blood collection for ANH, in the immediate postoperative period, and 24 hours later.

The ANH was performed in 17 patients, based on the Gross formula (▶ Fig. 1), with collection between 80% and 100% of the volume to be withdrawn via peripheral artery or vein (maximum of 500 mL per bag collected).^{4,5} In case of hemodynamic

$$V = EBV \times \frac{H_{to} - H_{tf}}{H_{tm}}$$

Fig. 1 Gross formula. Abbreviations: V, volume of blood to be withdrawn; EBV, estimated blood volume (65 mL/kg in women, and 70 mL/kg in men); H_{to}, initial hematocrit; H_{tf}, final hematocrit; H_{tm}, mean hematocrit (difference between H_{to} and H_{tf}).

instability, the ANH would be suspended. The bags were identified according to the order of collection, stored in a thermal box, and reinfused in the reverse order of collection. The hemodilution was performed in a 3:1 ratio with 0.9% saline solution and Ringer lactate. The additional volemic replacement was calculated to cover preoperative fasting, surgical loading (6 mL/kg/h)^{4,5} while the volume loss in the perioperative (3:1 ratio), was answer only if the urinary output < 0.5–1.0 mL/kg/h, and/or in case of hemodynamic instability.

As for the surgical technique, the decision between pedicle instrumentation or association with osteotomies (of posterior elements, pedicle subtraction, or vertebral body resection [VCR]) was determined according to the deformity.

Homologous blood transfusion was performed only if the levels of Hb were < 7 mg/dL (or 9 mg/dL in the case of elderly patients or low cardiovascular reserve), with hemodynamic changes or persistence of bleeding.

The data were tabulated using the Microsoft Excel 2016 (Microsoft Corp., Redmond WA, US) software. For the comparison of the quantitative variables, the Student *t*-test or the nonparametric Mann-Whitney test were used. For the categorical variables, the Fisher exact test was used. The normality condition of the variables was evaluated using the Kolmogorov-Smirnov test. Values of $p < 0.05$ indicated statistical significance. The data were analyzed with the Statistical Package for the Social Sciences (SPSS, IBM Corp., Armonk, NY, US), version 20. The quantitative variables were described by means, medians, minimums, maximums and standard deviations. The qualitative variables were described by frequencies and percentages. After this analysis, a comparison was made with data from the literature.

Results

The sample consisted of 30 patients aged between 12 and 61 years (mean of 27.1 for the ANH group and of 21.2 for the control group; $p > 0.05$), predominantly female (76.6%). The main etiologies were adolescent idiopathic scoliosis (AIS) and congenital scoliosis (CS), as shown in ►Figure 2. Most patients denied comorbidities (76.6%). A mean of 622.6 mL of blood was withdrawn for hemodilution (400–940 mL). The clinical parameters remained stable during all of the procedures. The mean time of surgery for the ANH group was of 5.2 h, whereas for the control group it was of 4.4 h ($p > 0.05$). The number of levels operated ranged from 7 to 16 (mean: 10.7) for the ANH group, and from 4 to 13 for the control group (mean: 9.58). As for the number of instrumented levels, it ranged from 6 to 14 (mean 9.82) for the ANH group, and from 4 to 13 for the control group (mean: 9.66).

Twenty patients underwent osteotomy, as described in ►Table 1. For the purpose of analysis, each type of osteotomy was graded by magnitude: 0 for none; 1 point for each posterior osteotomy; 2 points for pedicle subtraction, and 3 points for each RCV, then they were divided between groups with scores ≤ 2 or > 3 . In the isolated comparison between the groups, there was a greater mean of bleeding in the control group, but with greater variation, as evidenced in ►Figure 3. There was greater bleeding in both

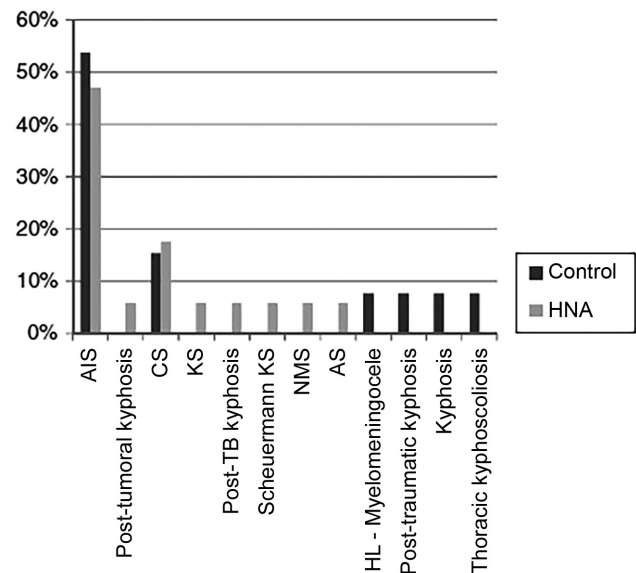


Fig. 2 Etiology of spinal deformities submitted to surgery and their frequency. Abbreviations: AIS, adolescent idiopathic scoliosis; CS, congenital scoliosis; NMS, neuromuscular scoliosis; AS, adult scoliosis; KS, kyphoscoliosis; HL, hyperlordosis; TB, tuberculosis.

Table 1 Mean bleeding by osteotomy; comparison between the groups

	n		Mean bleeding in mL	p-value ^a
No OTT	5	ANH	450	0.161
	5	Control	737.75	
OTT Weight ≤ 2	6	ANH	816.6	0.412
	3	Control	633.3	
OTT Weight > 3	6	ANH	591	0.175
	5	Control	880 ^a	
OTT Total	12	ANH	704.16	0.339
	8	Control	772.2	

Abbreviations: ANH, acute normovolemic hemodilution; OTT, osteotomy.

Note: ^aOne patient in the group underwent 3 vertebral body resection osteotomies and presented high bleeding.

groups when the osteotomy was performed, with no statistical significance.

Regarding the number of operated levels, it was divided between groups with a limit higher or lower than 10. More bleeding occurred in the control group, with more levels (594 × 920 mL; $p = 0.095$), whereas in the case of less levels, the bleeding was lower and similar between both groups, which suggests that ANH would be effective in reducing bleeding in larger surgeries. The density of the implant (number of screws per level operated) was calculated, with 1 standing for the instrumentation of all operated pedicles, and 0 representing a surgery without instrumentation (►Table 2). In the control group, the patients who were submitted to posterior osteotomy, had an increased need of

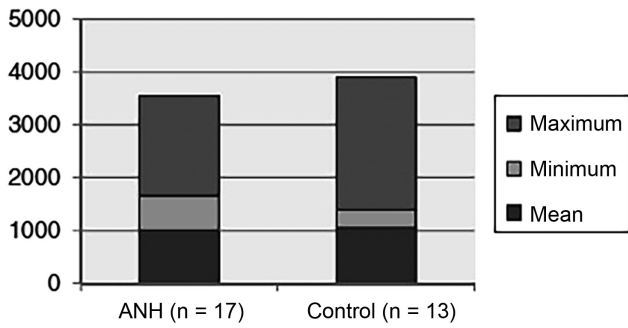


Fig. 3 Intraoperative bleeding between groups. Non-parametric Mann-Whitney test ($p = 0.934$). Abbreviation: ANH, acute normovolemic hemodilution.

transfusion ($p > 0.05$). The analysis of the ANH group showed that most of the patients did not require transfusion even after undergoing osteotomy ($p > 0.05$) (►Table 3). The patients who were transfused had a higher mean of operated levels, especially in the control group ($p > 0.05$) (►Table 4).

The mean value of intraoperative bleeding was of 629.4 mL, and, postoperatively, it was of 379.11 mL for the ANH group, compared to 754.2 mL and 296.2 ml respectively for the control group, but without statistical significance. There was a lower perioperative-postoperative bleeding reduction in the ANH group, with $p < 0.05$ (►Fig. 4).

The laboratory tests were compared before and after surgery and between the groups, as represented in ►Table 5.

The coagulation profile was analyzed, and in both groups there was a widening of the PAT – with a greater difference before and after surgery in the ANH group ($p = 0.014$) –, and a decrease in the APTT, with a greater decrease in the control group ($p = 0.793$) (►Figs. 5 and 6).

There was a greater need for the use of local hemostatics in the control group compared to the ANH group (30.8% versus 5.9% respectively; $p > 0.05$). There was no statistical relevance

for the need for transfusion according to the method applied, as shown in ►Figure 7. In general, patients requiring blood products had more severe deformities in 75% of the cases, and, consequently they had more levels to be addressed (7-14, mean: 11.1), plus osteotomies (1-9; mean: 4 versus 0-5; mean: 1.56; $p < 0.05$). This group also had high rates of perioperative bleeding (600-2,000 mL; mean: 1,050 mL), which was statistically significant ($p = 0.007$) when compared to the mean bleeding of the patients who did not receive transfusions (593.6 mL). For the purpose of comparison, the patients were divided into a group with AIS and a second group with other diagnoses. In this second group, the surgical time was longer ($p < 0.05$), there was higher implant density ($p = 0.07$) and almost double the amount of posterior osteotomies performed ($p > 0.05$) (►Table 6).

Discussion

Bleeding control should be part of the initial surgical planning. The application of techniques can prevent the need for transfusion in patients undergoing AIS surgery.⁶ The evolution of the surgical techniques enabled better results on terms of esthetics and function, but, the longer the procedure, the greater the perioperative bleeding⁷⁻⁹ and fibrinolysis, with consequent increase in hemorrhage, which generates a vicious circle that increases the morbimortality.⁹

In neuromuscular scoliosis (NMS) surgery, there is greater blood loss compared to AIS surgery,¹⁰⁻¹² mainly due to the greater extent of the arthrodesis,¹¹ with possible relation with the use of anticonvulsants and malnutrition. The estimated blood loss in the AIS surgery is of 1,300-2,200 mL, compared to 2,000-4,000 mL for the NMS surgery.¹² In addition to hypotension, anemia and coagulopathy due to depletion, blood loss leads to an increase in the number of transfused units.¹⁰ In the present study, patients with AIS had a mean bleeding of 561 mL, while in other deformities it

Table 2 Density of the implant (number of screws in relation to the number of levels operated); comparison between the groups ($p > 0.05$)

		n	Mean	Median	Minimum	Maximum	Standard deviation	p-value ^a
Density of the implant	ANH	17	0.815	0.792	0.625	1	0.141	0.146
	Control	13	0.739	0.722	0.545	1	0.131	

Abbreviation: ANH, acute normovolemic hemodilution.
Note: ^a $p > 0.05$.

Table 3 Osteotomy versus need for transfusion; comparison between the groups

Transfusion	Osteotomies - ANH		Osteotomies - Control		Posterior OTT - Control		Posterior OTT - ANH	
	None	At least one	None	At least one	None	At least one	None	At least one
No	5 (100%)	10 (83.3%)	5 (100%)	4 (50%)	7 (100%)	2 (33.3%)	7 (87.5%)	8 (88.9%)
Yes	0	2 (16.7%)	0	4 (50%)	0	4 (66.7%)	1 (12.5%)	1 (11.1%)
Total	5	12	5	8	7	6	8	9
p-value	1		0.105		0.021 ^a		1	

Abbreviations: ANH, acute normovolemic hemodilution; OTT, osteotomy.
Note: ^a p -value calculated using the Fisher exact test ($p < 0.05$).

Table 4 Number of levels operated versus need for transfusion; comparison between the groups

	Transfusion	Levels operated						
		n	Mean	Median	Minimum	Maximum	Standard deviation	
ANH	No	15	10.7	11	7	16	2.7	$p > 0.05$
	Yes	2	10.5	10.5	7	14	4.9	
Control	No	9	8.9	9	4	11	2.1	$p = 0.020$
	Yes	4	11.5	11	11	11	1.0	

Abbreviation: ANH, acute normovolemic hemodilution.

Note: Non-parametric Mann-Whitney test ($p < 0.05$).

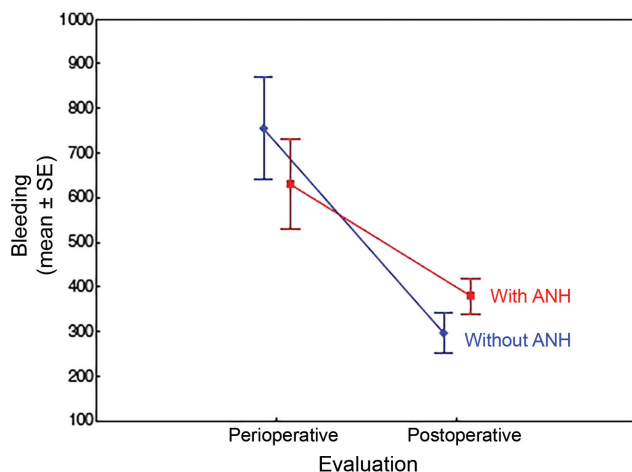


Fig. 4 Evaluation of perioperative bleeding versus postoperative: comparison between the groups. Abbreviation: ANH, acute normovolemic hemodilution; SE, standard error.

was up to 2,000 mL (mean: 806 mL). Only one patient with AIS required transfusion.

Postoperative PAT and APTT prolongation is expected due to a dysfunction in platelet aggregation, which, especially in cases of NMS,^{10,13} indicates coagulation overregulation in response to surgical stress and consumption of coagulation factors.¹³ In the present study, there was a decrease in the APTT and prolongation of the PAT in all patients, with no clinical repercussions, as verified by Oppitz and Stefani.⁵

Bleeding in deformity corrections is high because of the rich local vascularity, wide exposure and prolonged surgical time. The estimated blood loss is of 10-30 mL/kg.^{11,14} There was a great deal of variability in the values found in the present study (200-2,000 mL), a fact that can be attributed to the etiology, the severity of the deformity, the operated levels, the osteotomies and the surgical time. Sex, advanced age, cardiovascular disease, extensive laminectomies and low Ht in the preoperative period^{15,16} did not result in increased bleeding.

Osteotomies are eventually needed to correct more severe deformities, especially in adults.¹⁷ Pedicle subtraction is associated with higher levels of blood loss (up to 3 L) due to the dissection of large-caliber epidural veins¹⁸ and increased surgical time.⁸ The VCR is an option for severe and/or rigid deformities.¹⁷ Posterior osteotomies (also known as Smith Petersen osteotomies), which are considered easier and faster,

have limited correction power (5°-20°), whereas pedicle subtraction can correct 30°-40° per level.^{7,19} There are reports of higher bleeding rates with the posterior approach than with the anterior approach.¹² All patients in the present study had the procedure performed by the posterior approach.

In the present study, the patients submitted to osteotomies had a higher average bleeding rate, which is in line with the literature, but the only statistically relevant data was the increased need for transfusion in the control group when the osteotomies by the posterior approach were performed. The ANH was not proven effective to avoid transfusion when the osteotomy was performed, but a trend towards statistical relevance was noticed in proportion to the increase in the aggressiveness of the approach.

Identifying risk factors, discontinuing medications such as acetylsalicylic acid, anti-inflammatory drugs and anticoagulants,^{1,20} and even preoperative embolization of the vertebral body²¹ reduces hospitalization time, costs and bleeding. Thorough dissection of the periosteum and the use of electrocautery and hemostatic agents^{1,6} may be adjuvants of autologous donation, ANH or hypotensive anesthesia.⁶ Although Szpalski et al²² and Urban et al²³ have shown that adequate evidence exists for their use, controlled hypotension is controversial in spinal surgery because it does not reduce intraoperative blood loss,¹⁴ and because of the risk of spinal cord injury due to reduced flow.^{7,24} They also mention that the use of systemic and local hemostatic agents would be controversial.²²

The use of fibrinolytics gained popularity in the 1990s.^{18,25} In children with NMS, their use was effective in reducing bleeding and transfusion.^{10,26} Aprotinin inhibits anticoagulant enzymes, as well as the intrinsic pathway of coagulation and platelet aggregation.^{9,25} Its use has been discontinued^{9,10} due to increased mortality from acute myocardial infarction⁹ and acute renal failure,²⁵ although previous studies have shown reduced transfusion in heart, knee and hip surgeries^{9,18,25} and also despite the fact that they have been considered superior to tranexamic acid in pedicle osteotomy.¹⁸

Tranexamic acid was administered to all patients in this study. It acts through the reversible binding of plasminogen with lysine,²⁴ it is considered safe, and is widely used in cardiac and urogynecological surgeries. In a retrospective study,²⁴ its use in AIS resulted in less bleeding and transfusion,²⁴ but it was not effective in cases of pedicle subtraction in adults.¹⁸ Its use does not increase the morbimortality and the incidence of thromboembolic events.²⁷

Table 5 Mean values compared between the groups at different instances of evaluation

n		15	2	9	4	30	30
HB	Preoperative	13.7	14.4	13.5	12.5	13.6	13.1
	Postoperative	10.8	7.8	11.9	10.4	11.1	9.5
	After 24 h	9.6	6.0	10.3	10.4	9.8	8.9
	Post-pre	-2.9	-6.7	-1.8	-2.1	-2.6	-3.6
	24 h after-pre	-4.1	-8.5	-3.4	-2.1	-3.9	-4.2
HT	Preoperative	40.8	43.3	40.4	37.7	40.6	39.6
	Postoperative	32.2	23.0	35.7	32.7	33.3	29.4
	After 24 h	28.6	18.0	30.7	30.8	29.3	26.5
	Post-pre	-8.6	-20.3	-5.0	-5.0	-7.5	-10.1
	After 24 h-pre	-12.2	-25.3	-10.3	-6.9	-11.5	-13.0
PAT	Preoperative	12.5	11.9	14.0	12.4	13.0	12.2
	After 24 h	14.5	14.0	14.9	14.6	14.6	14.4
	After 24 h-pre	2.0	2.1	1.0	2.3	1.7	2.2
APTT	Preoperative	32.7	31.3	29.7	25.3	31.6	27.3
	After 24 h	30.9	32.9	26.9	24.7	29.6	27.4
	After 24 h-pre	-1.7	1.6	-2.5	-0.6	-2.0	0.1

Abbreviations: ANH, acute normovolemic hemodilution; APTT, activated partial thromboplastin time, in seconds; HB, serum hemoglobin in g/dL; HT, hematocrit in %; PAT, prothrombin activation time, in seconds.
 Note: $p > 0.05$ for all groups.

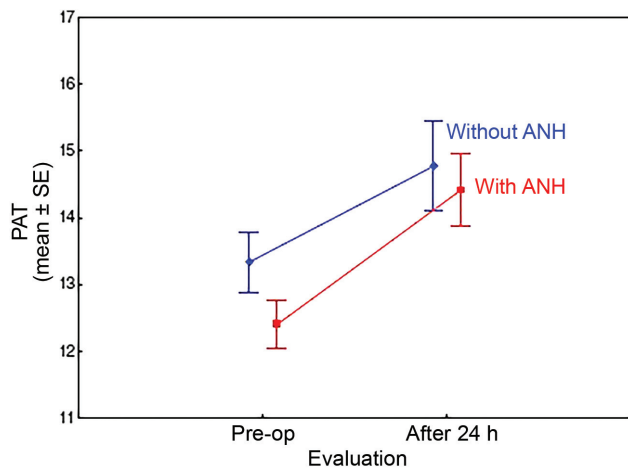


Fig. 5 Prolongation of prothrombin activation time values in both groups in 24 h after surgery ($p > 0.05$). Abbreviations: ANH, acute normovolemic hemodilution; Pre-op, preoperative period; SE, standard error; PAT, prothrombin activation time.

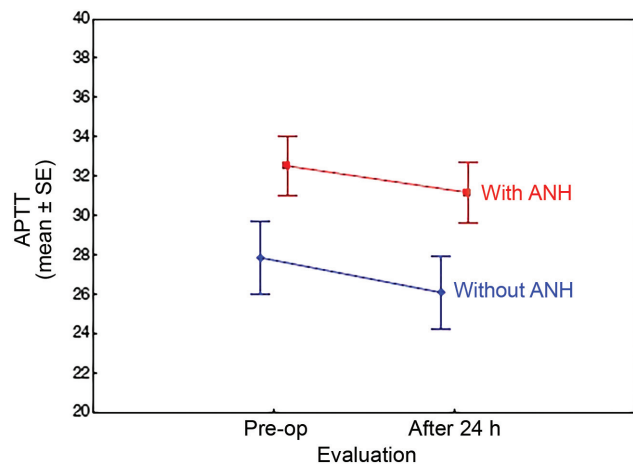


Fig. 6 Drop in the values of activated partial thromboplastin time in both groups 24 h after surgery ($p > 0.05$). Abbreviations: ANH, acute normovolemic hemodilution; Pre-op, preoperative period; SE, standard error; APTT, activated partial thromboplastin time.

In the present study, the rate of homologous blood transfusion was of 20%, which is within the range of 8-36% reported by Purvis et al,²⁸ who described multiple possible complications (increased mortality, hospital infections, prolonged hospitalization, besides the high cost),^{7,16,20,29} although no complications were reported. It was not possible to isolate a factor responsible for transfusion, but a variable association between operated levels, severity of the deformity, surgical time and osteotomies.

Autologous transfusion is considered safer,³ and should be performed with donation prior to surgery (3 to 5 weeks,

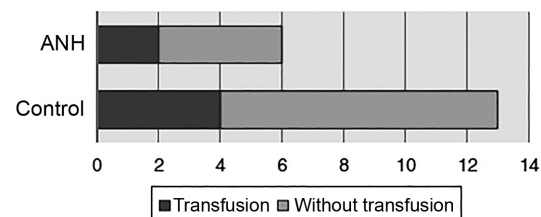


Fig. 7 Need for transfusion compared to hemodilution ($p = 0.360$). Abbreviation: ANH, acute normovolemic hemodilution.

Table 6 Comparison between relevant parameters of patients diagnosed with adolescent idiopathic scoliosis versus other deformities

	Adolescent idiopathic scoliosis (n = 14)	Other deformities (n = 16)	p-value
Surgical time (mean)	4.29 h	5.45 h	0.002
Density of the implant (mean)	0.74	0.82	0.07
Osteotomies (mean)	0.92	1.86	> 0.05
Bleeding (mean)	561 mL	806 mL	0.058

with limitations in the case of elderly and anemic patients),⁷ normovolemic hemodilution, cell preservation (high cost),^{7,16,28} or hypervolemic hemodilution, which reduces the need for allogeneic transfusion¹⁴ by dilution in plasma or in macromolecule solutions, with increasing circulating volume.⁴ It is considered quick, easier, more stable and cheaper than the ANH.

In the ANH, the collected blood is diluted with acellular fluid in the ratio of 2-4:1,^{7,16} leading to a reduction in perioperative blood loss with maintenance of the flow.³⁻⁵ Many studies show that ANH reduces the need for homologous transfusion between 18% and 90%;^{5,29} however, in the present study, there was no statistical significance regarding this, perhaps due to the number of cases. The ANH is considered safe and effective in spinal surgery when there is an estimated loss higher than 1 L or 20% of blood volume.^{16,29} There is a risk of extreme hemodilution (Ht < 20%), with risk of tissue ischemia, which is reversed with infusion of fresh plasma, according to McLaughlin.¹⁴ Its use in the pediatric population was tested in a 2004 prospective randomized study³⁰ with children undergoing posterior arthrodesis, which proved that the ANH is safe and able to reduce the need for transfusion without the complications related to anemia.³⁰ Tse et al³¹ have shown in their review that ANH, tranexamic acid, intrathecal morphine and modification of the operative techniques seem to be the best options to reduce perioperative bleeding and allogeneic blood transfusion. The use of ANH in this study aided in the control of bleeding, but not to the point of avoiding transfusion in an isolated manner.

Conclusion

The ANH technique associated with tranexamic acid has not been proven effective in reducing the need for homologous blood transfusion in corrective surgeries of spinal deformities, despite its tendency to reduce intraoperative bleeding, especially in cases that are considered more complex. The combined effect of the severity of the deformity, the osteotomies, and the number of operated/instrumented levels is a determinant for the need for transfusion, and the association

of preoperative and intraoperative measures to control the bleeding should be considered in these cases. It is believed that a larger casuistry could prove its efficacy in comparison with isolated fibrinolytics.

Conflicts of Interest

The authors have none to declare.

References

- Baird EO, McAnany SJ, Lu Y, Overley SC, Qureshi SA. Hemostatic agents in spine surgery: A critical analysis review. *JBJS Rev* 2015;3(01):x
- Maxwell MJ, Wilson MJA. Complications of blood transfusion. *BJA Educ* 2006;6(06):225-229
- Walunj A, Babb A, Sharpe R. Autologous blood transfusion. *BJA Educ* 2006;6(05):192-196
- Oriani G, Pavesi M, Oriani A, Bollina I. Acute normovolemic hemodilution. *Transfus Apheresis Sci* 2011;45(03):269-274
- Oppitz PP, Stefani MA. Acute normovolemic hemodilution is safe in neurosurgery. *World Neurosurg* 2013;79(5-6):719-724
- Verma RR, Williamson JB, Dashti H, Patel D, Oxborrow NJ. Homologous blood transfusion is not required in surgery for adolescent idiopathic scoliosis. *J Bone Joint Surg Br* 2006;88(09):1187-1191
- Kim KT, Park KJ, Lee JH. Osteotomy of the spine to correct the spinal deformity. *Asian Spine J* 2009;3(02):113-123
- Liu H, Yang C, Zheng Z, et al. Comparison of Smith-Petersen osteotomy and pedicle subtraction osteotomy for the correction of thoracolumbar kyphotic deformity in ankylosing spondylitis: a systematic review and meta-analysis. *Spine* 2015;40(08):570-579
- Khurana A, Guha A, Saxena N, Pugh S, Ahuja S. Comparison of aprotinin and tranexamic acid in adult scoliosis correction surgery. *Eur Spine J* 2012;21(06):1121-1126
- Dhawale AA, Shah SA, Sponseller PD, et al. Are antifibrinolytics helpful in decreasing blood loss and transfusions during spinal fusion surgery in children with cerebral palsy scoliosis? *Spine* 2012;37(09):E549-E555
- Modi HN, Suh S-W, Hong J-Y, Song S-H, Yang J-H. Intraoperative blood loss during different stages of scoliosis surgery: A prospective study. *Scoliosis* 2010;5(01):16-16
- Shapiro F, Sethna N. Blood loss in pediatric spine surgery. *Eur Spine J* 2004;13(Suppl 1):S6-S17
- Bosch P, Kenkre TS, Londino JA, Cassara A, Yang C, Waters JH. Coagulation Profile of Patients with Adolescent Idiopathic Scoliosis Undergoing Posterior Spinal Fusion. *J Bone Joint Surg Am* 2016;98(20):e88
- El-Dessouky MI, Waly SH, Nasr YM. Acute normovolemic hemodilution in spinal fusion surgery. *Egypt J Anaesth* 2011;31:249-254
- Epstein NE. Bloodless spinal surgery: a review of the normovolemic hemodilution technique. *Surg Neurol* 2008;70(06):614-618
- Stehling L, Zauder HL. Acute normovolemic hemodilution. *Transfusion* 1991;31(09):857-868
- Enercan M, Ozturk C, Kahraman S, Sarier M, Hamzaoglu A, Alanay A. Osteotomies/spinal column resections in adult deformity. *Eur Spine J* 2013;22(Suppl 2):S254-S264
- Baldus CR, Bridwell KH, Lenke LG, Okubadejo GO. Can we safely reduce blood loss during lumbar pedicle subtraction osteotomy procedures using tranexamic acid or aprotinin? A comparative study with controls. *Spine* 2010;35(02):235-239
- Hyun S-J, Rhim S-C. Clinical outcomes and complications after pedicle subtraction osteotomy for fixed sagittal imbalance patients : a long-term follow-up data. *J Korean Neurosurg Soc* 2010;47(02):95-101
- Blanchette CM, Wang PF, Joshi AV, Asmussen M, Saunders W, Kruse P. Cost and utilization of blood transfusion associated with spinal surgeries in the United States. *Eur Spine J* 2007;16(03):353-363

- 21 Tuchman A, Mehta VA, Mack WJ, Acosta FL Jr. Novel application of pre-operative vertebral body embolization to reduce intraoperative blood loss during a three-column spinal osteotomy for non-oncologic spinal deformity. *J Clin Neurosci* 2015;22(04):765–767
- 22 Szpalski M, Gunzburg R, Sztern B. An overview of blood-sparing techniques used in spine surgery during the perioperative period. *Eur Spine J* 2004;13(Suppl 1):S18–S27
- 23 Urban MK, Beckman J, Gordon M, Urquhart B, Boachie-Adjei O. The efficacy of antifibrinolytics in the reduction of blood loss during complex adult reconstructive spine surgery. *Spine* 2001;26(10):1152–1156
- 24 Yagi M, Hasegawa J, Nagoshi N, et al. Does the intraoperative tranexamic acid decrease operative blood loss during posterior spinal fusion for treatment of adolescent idiopathic scoliosis? *Spine* 2012;37(21):E1336–E1342
- 25 Tayyab NA, Marillier MM, Rivlin M, et al. Efficacy of aprotinin as a blood conservation technique for adult deformity spinal surgery: a retrospective study. *Spine* 2008;33(16):1775–1781
- 26 Cole JW, Murray DJ, Snider RJ, Bassett GS, Bridwell KH, Lenke LG. Aprotinin reduces blood loss during spinal surgery in children. *Spine* 2003;28(21):2482–2485
- 27 da Rocha VM, de Barros AGC, Naves CD, et al. Use of tranexamic acid for controlling bleeding in thoracolumbar scoliosis surgery with posterior instrumentation. *Rev Bras Ortop* 2015;50(02):226–231
- 28 Purvis TE, Goodwin CR, De la Garza-Ramos R, et al. Effect of liberal blood transfusion on clinical outcomes and cost in spine surgery patients. *Spine J* 2017;17(09):1255–1263
- 29 Fischer ST, Schuroff AA, Vialle LR. Hemodiluição isovolumétrica no tratamento cirúrgico da escoliose idiopática. *Rev Bras Ortop* 1994;29(03):107–110
- 30 Oliveira GS, Tenório SB, Cumino DO, et al. Acute normovolemic hemodilution in children submitted to posterior spinal fusion. *Rev Bras Anesthesiol* 2004;54(01):84–90
- 31 Tse EY, Cheung WY, Ng KF, Luk KD. Reducing perioperative blood loss and allogeneic blood transfusion in patients undergoing major spine surgery. *J Bone Joint Surg Am* 2011;93(13):1268–1277