


Superficial Acral Fibromyxoma: Literature Review*

Fibromixoma superficial acral: Revisão da Literatura

Bruno Eiras Crepaldi¹ Ruan Dalbem Soares¹  Fábio Duque Silveira¹ Raul Itocazo Taira¹
Celso Kiyoshi Hirakawa¹ Marcelo Hide Matsumoto¹

¹Group of Hand Surgery and Microsurgery, Hospital Santa Marcelina de Itaquerá, São Paulo, SP, Brazil

Rev Bras Ortop 2019;54:491–496.

Address for correspondence Ruan Dalbem Soares, MD, Grupo de Cirurgia da Mão e Microcirurgia, Hospital Santa Marcelina de Itaquerá, Rua Gonçalo da Cunha, 43, Apto 56, Chácara Inglesa, São Paulo, 04140-040, SP, Brazil (e-mail: ruansoares1@hotmail.com).

Abstract

Superficial acral fibromyxoma is a benign and rare tumor of the soft tissues. It usually manifests itself through a painless mass of slow growth that affects mainly males in the fifth decade of life. It usually affects the distal region, with a polypoid or dome-shaped appearance. The histological appearance is of a dermal mass without capsule, with spindle-shaped fibroblasts in a storiform or fasciculated pattern in the myxocollagenous stroma. The immunohistochemical evaluation of superficial acral fibromyxoma is usually positive for CD34 and CD99, with variable positivity for epithelial membrane antigen. The treatment consists of complete excision of the tumor mass.

A review of the current literature on superficial acral fibromyxoma was performed, with an emphasis on the number of cases reported, location, diagnostic methods, histological characteristics, differential diagnoses and treatment.

A total of 314 reported cases of superficial acral fibromyxoma with variable locations were found in the current literature, mainly in the toes (45.8%) and fingers (39.1%). It has a slightly superior incidence in men (61%) and enormous variability in the age range of occurrence.

Keywords

- ▶ soft-tissue neoplasms
- ▶ fibroma/pathology
- ▶ fibroma/therapy
- ▶ skin neoplasms

Superficial acral fibromyxoma is a single soft-tissue tumor that should enter the differential diagnosis of periungual and subungual acral lesions; the treatment consists of simple excision. More studies are needed to better understand this pathology, which was first described in 2001.

Introduction

Superficial acral fibromyxoma (SAF) is a myxoid tumor described in 2001 by Fetsch et al,¹ which affects preferentially the subungual or periungual regions. It usually manifests itself through a painless mass of slow growth that affects mainly males in the fifth decade of life. It is usually located in the acral region of the hands and feet, but it can affect the region of

the heel and ankle.^{2–7} History of associated trauma is rare, and most tumors grow asymptotically. Regarding the histological analysis, it presents as a neoplasia of difficult delineation, which is composed of spindle- or star-shaped cells with varying degree of pleomorphism. It presents cells arranged in the myxoid and collagenous stroma, with immunoreactivity for CD34, CD99, vimentin and focally for the epithelial membrane antigen (EMA). Blood vessels predominate in the myxoid area, and mast cells are usually distributed throughout the lesion. The treatment typically consists of complete mass excision in order to avoid relapses or malignization, although the tumor does not present aggressive

* Work developed at the Group of Hand Surgery and Microsurgery, Hospital Santa Marcelina de Itaquerá, São Paulo, SP, Brazil
Published Originally by Elsevier Editora Ltda.



behavior, despite the presence of cellular atypia in some cases. To date, the occurrence of malignancy has not been reported in the literature. The postoperative follow-up should be performed because of the recurrence rate of 10 to 24%.⁶⁻⁸ The present work aims to review the current literature on SAF, with an emphasis on the number of cases reported, gender distribution, location, lesion characteristics, diagnostic methods, histological characteristics, differential diagnoses and treatment.

Casuistry and Methods

The present study, which is a review of the literature on the tumor described by Fetsch et al¹ as superficial acral fibromyxoma, is focused on studying the number of cases reported, their location, the main histological characteristics, their differential diagnoses, and the treatment. A bibliographic search was carried out in the PubMed database, in which 58 papers were found through the descriptors: “*superficial AND acral AND fibromyxoma*.” The inclusion and exclusion criteria are as follows:

Inclusion Criteria

- Works written in Portuguese and/or English.
- Complete works.
- Articles that presented diagnostic techniques, differential diagnoses, surgical techniques or case reports about the pathology in question.

Exclusion Criteria

- Articles without abstracts.
- Works written in languages other than those mentioned in the inclusion criteria.
- Works whose theme differed from that presented in the research.

Six articles were excluded from this review because they did not have summaries; four were excluded because they were not written in Portuguese or English; and three were excluded because they did not add information about reported accidents, location, histological characteristics, differential diagnoses and/or pathology treatment.

Results

We found in the literature 314 cases of SAF with varied locations, as shown in ►Table 1.^{1,3-38}

The mean age at which the diagnosis was made was 47 years and 7 months, but with a large variance; there were cases in people aged between 4 and 91 years.

Out of the 306 cases in which information on gender was available, we found: 61% of cases in men, while women accounted for only 39% of the cases (►Fig. 1).

Regarding location, we found an almost exclusive incidence in the hands and feet, most commonly in the regions of the fingers (chirodactyls) and toes (pododactyls). However, cases in which the tumor affected the calf and thigh have also been described.⁸

The main location of the tumor (►Fig. 2) was the pododactyls, which were responsible for 45.8% of the cases; the chirodactyls represented 39.1% of the cases. In 19 cases (6%) information on the location was not available (►Fig. 2).

Typically, SAF is a slow-growing, solitary, usually painless lesion with a consistency between gelatinous and firm, and size between 0.5 and 5 cm.¹⁻⁸

In the histological examination, SAF is found as an unencapsulated dermis tumor that can extend itself to the subcutaneous tissue, the underlying fascia or the periosteal layer.¹ It is composed of star- or spindle-shaped fibroblast tumor cells in a variable degree of mixed myxoid or collagen matrices. As the tumor persists, the collagen matrix tends to become predominant over the myxoid matrix.¹ The neoplasia often shows marked microvascularization and mast cells. In almost every case, mitotic figures are infrequent, and nuclear atypia, if present, is mild to moderate.¹⁰

Immunohistochemically, the tumor cells in SAF show immunoreactivity for CD34, EMA and CD99. In the study by Fetsch et al,¹ the positivity was of: 21/23 (91.3%) for CD34; 18/25 (72%) for EMA; and 11/13 (84.6%) for CD99. In the study by Hollmann et al,⁸ the positivity was of only: 42/61 (68.8%) for CD34 and 3/40 (7.5%) for EMA. No positivity is observed for actin, desmin or cytokeratins.¹¹

The main differential diagnoses found in the literature are described in ►Table 2.

The treatment of these tumors typically involves complete excision to prevent malignancy and recurrence, according to 10 studies.^{1,4,6,8,12,22,26,28,30,35}

Discussion

Superficial acral fibromyxoma (SAF) is a benign, distinctive, soft, slow-growing tumor with a predilection for the periungual and subungual regions of the hands and feet.³⁹

The tumor is an entity that is difficult to diagnose due to the characteristics it has in common with many different pathologies, which causes a delay in the definitive diagnosis, with cases reported in which the interval between the beginning of the symptomatology and the final diagnosis was superior to 10 years.^{9,10} The late diagnosis is also due to its indolent nature and to the fact that it generally presents low morbidity to the patient. The fact that it is a relatively recently described pathology (2001) that has few cases in the literature helps delay the diagnosis and contributes to the possibility of underdiagnosis.

Regarding the gender of the patients, there is a predominance of approximately 2:1 of males in most of the studies evaluated;⁴⁰ in the present review, it was of 1.59:1: we found 61% of incidence in males, 39% in females, in a population of 306 cases in which information on gender was available (►Fig. 1).

To date, no other risk factors have been reported.³⁹

Regarding location, there is a predominance of the acral regions of the hands and feet, but SAF can be found in other places, such as the legs, thighs and ankles, as reported in three works.^{7,8,25}

Due to the heterogeneity in presentation and clinical and histological characteristics, SAF should always be part of the

Table 1 Distribution of cases of superficial acral fibromyxoma by article, number of cases and location

References	Cases reported	Location	N of cases	References	Cases reported	Location	N of cases
Fetsch et al ¹ Hum Pathol. 2001	37	Pododactyls Chirodactyls Palm	20 13 4	Kazakov et al ¹⁴ Dermatology. 2002	2	Pododactyls	2
Meyerle et al ¹³ J Am Acad Dermatol. 2004	1	Second chirodactyl (subungual)	1	André et al ¹⁰ Am J Dermatopathol. 2004	1	Hallux	1
Quaba et al ⁹ Br J Plast Surg. 2005	1	Fourth chirodactyl	1	Abou-Nukta et al ¹² J Hand Surg Br. 2006	1	Thumbnail	1
Oteo-Alvaro et al ¹¹ Arch Orthop Tra Surg. 2008	1	Pododactyl	1	Misago et al ¹⁷ J Eur Acad Derma. Venereol. 2008	1	Tip of the hallux	1
Varikatt et al ¹⁸ Skeletal Radiol. 2008	2	Tip of the second chirodactyl	2	Al-Daraji and Miettinen ⁷ J Cutan Pathol. 2008	32	Pododactyls Chirodactyls Heel	15 13 4
Al-Daraji and Miettinen ⁷ Dermatol Online J. 2008	2	Hallux Chirodactyl	1 1	Prescott et al ⁶ Br J Dermatol. 2008	41	Pododactyls Chirodactyls Palm	29 11 1
Tadio et al ¹⁵ Am J Dermatopathol. 2008	4	Hallux Palm Thumb Chirodactyl	1 1 1 1	Luzar and Calonje ²⁰ Histopathology. 2009	14	Hallux ?	8 6
Pasquinelli et al ¹⁶ Ultrastruct Pathol. 2009	1	Second chirodactyl	1	Wang et al ¹⁹ Zhonghua Bing Li Xue Za Zhi 2009	1	Third chirodactyl	1
Goo et al ²² Ann Dermatol. 2010	1	Second chirodactyl (subungual)	1	Chattopadhyay et al ²¹ Clin Exp Dermatol. 2010	1	Second chirodactyl (subungual)	1
Cogrel et al ²⁹ Ann Dermatol Vereol. 2010	3	Chirodactyl Hallux Pododactyl	1 1 1	Fanti et al ²³ G Ital Dermatol Venereol. 2011	12	Chirodactyls Pododactyls	? ?
Messeguer et al ⁴ Actas Dermosifiliogr. 2012	1	Second chirodactyl	1	Bem Brahim et al ³⁸ Tunis Med. 2012	1	Pododactyls	1
Wakabayashi et al ³ Acta Dermatovenerol Croat. 2012	1	Hallux	1	Wei and Fleegler ⁵ Eplasty. 2013	1	Thumb	1
Kwok et al ³⁷ Clin Exp Dermato. 2013	1	Pododactyl	1	Hwang et al ³⁶ Arch of Plast Surg. 2013	1	Second pododactyl	1
Chabbab et al ³³ Anales de Derma. 2014	3	Subungual	3	Garcia et al ³⁵ Anais Br de Derma. 2014	1	Fifth pododactyl	1
Park et al ²⁴ Annals of Derma. 2014	1	Palm	1	Carranza et al ²⁷ The Am Journ of Derma. 2015	1	Hallux	1
Schwager et al ³⁴ Cutis. 2015	3	Hallux Fourth pododactyl Fifth pododactyl	1 1 1	Raghupathi et al ³² Journal of Cytol. 2015	1	Hallux (subungual)	1
Grigore et al ²⁶ Clujul Med. 2016	1	Hallux (subungual)	1	Ramya et al ³¹ India Jour of Derma. 2016	1	Thumb (subungual)	1
Sundaramurthy et al ³⁰ Journ Clin Diag Rese. 2016	1	Second chirodactyl	1	DeFroda et al ²⁸ Journ of Ortopae. 2016	1	Thumb	1
Agaimy et al ²⁵ Hum Pathology. 2016	11	Chirodactyls Pododactyls Heel Calf ?	5 3 1 1 1	Hollmann et al ⁸ The American Journal of Surgical. 2012	124	Chirodactyls Palm Back of the hand Feet Other	60 3 1 56 4

differential diagnosis when evaluating a lesion in the acral regions of the hands and feet.

The diagnosis is of clinical suspicion and histopathological confirmation, but other diagnostic methods have been

described as auxiliary, such as simple radiography, ultrasonography and nuclear magnetic resonance (NMR).^{8,41,42}

Simple radiography of the site has been useful in determining bone involvement (36% of cases in the study by Hollmann

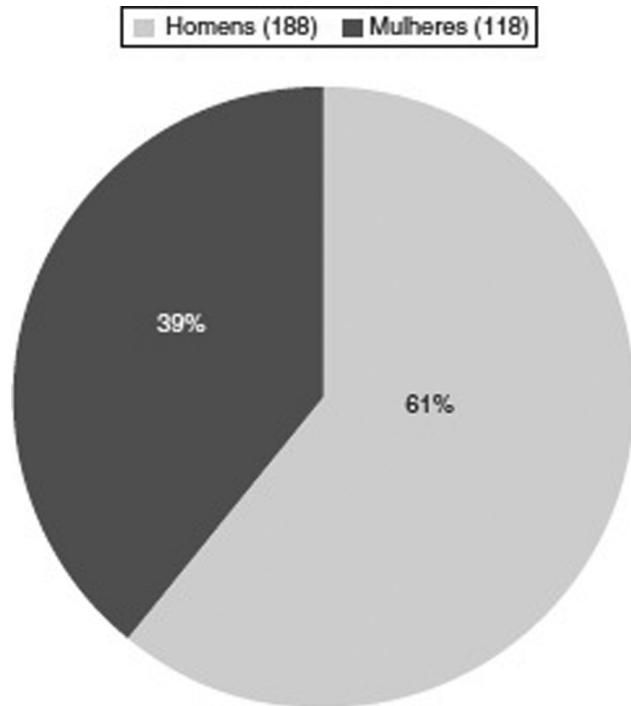


Fig. 1 Percentage of gender in the published cases: men, 188 cases (61%); women, 118 cases (39%). 1- Men (188). 2- Women (118).

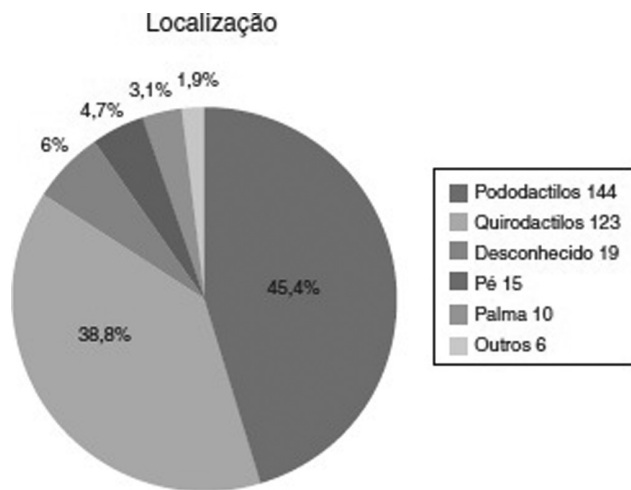


Fig. 2 Location of the tumor in the 314 reported cases: pododactyls, 144 cases (45.4%); chirodactyls, 123 cases (38.8%); unknown, 19 cases (6%); feet, 15 cases (4.7%); palm, 10 cases (3.1%); other, 6 cases (1.9%). 1- Location. 2- Pododactyls 144. 3- Chirodactyls 123. 4- Unknown 19. 5- Feet 15. 6- Palm 10. 7- Other 6.

et al⁸ presented erosive or lytic bone lesions).⁸ Soft-tissue masses usually do not present calcification on single radiographs. However, they are responsible for the erosion of the underlying cortical bone, which may be present. In the diagnostic suspicion, complementation with simple radiographs is imperative, since bone involvement may alter the estimated extent of the lesion as well as the therapeutic planning, as observed by Varikatt et al.¹⁸

Ultrasound examination can add important information about tumor mass size, location, shape and mass content. Associated with complementation through the vascular

Table 2 Main differential diagnoses and their positivity for CD34

CD34+Neoplasms	CD 34-Neoplasms	Other Lesions
Myxoid neurofibroma	Giant-cell tumor of the tendon sheath	Fibroma of the tendon sheath
Superficial angiomyxoma	Glomus tumor	Onicocryptosis
Dermatofibrosarcoma protuberans	Sclerosing perineurioma	Cutaneous myxoma
Sclerotic fibroma	Benign fibrous histiocytoma	
Acral myxoinflammatory Spindle cell lipoma	Acral fibrokeratoma	

study provided by color Doppler, the vascular pattern can be defined as aiding in the therapeutic decision. The ultrasound also has its use associated to the monitoring and relapses of surgically-treated lesions.⁴¹

On magnetic resonance imaging, SAF classically demonstrates homogeneous hyperintensity in T2-weighted images and increased contrast to normal tissue on postcontrast magnetic resonance imaging.⁴²

Histopathologically, SAF is described in most studies as a well-circumscribed, unencapsulated dermal tumor composed of star- or spindle-shaped cells in a loose fascicular arrangement embedded in a myxoid, myxocollagenous, or collagen-only stroma. It usually occupies the entire dermis, and can extend to the subcutaneous tissue or occasionally into the fascia and bones.¹⁰

Tumor cells in SAF show immunoreactivity for CD34, EMA and CD99.¹ Although the immunoreactivity is diffuse and relatively strong for CD34 and CD99, in the case of EMA it is somewhat more variable. Recently, some tumors have also shown focal reactivity to smooth-muscle actin and desmin, although this is not considered a general characteristic.^{1,8,43}

The differential diagnosis includes a variety of fibromyxoid or myxoid proliferations. Dermatofibrosarcoma protuberans (DFSP) may have extensive myxoid areas that may mimic SAF. This fact, in combination with the expression of CD34 and EMA by both entities, makes it a differential diagnostic challenge.⁴⁴

Other myxoid sarcomas, such as myxofibrosarcoma, may be distinguished by the presence of greater cytologic atypia, larger numbers of mitotic cells, and atypical mitotic forms.⁸

Myxoid neurofibroma usually has a neural appearance, without increased vascularization. The tumors are characterized by cells that are positive for S100 mixed with CD34-positive fibroblastic cells, which differs from SAFs, which are S100-negative and have concentrated microvasculature.^{10,11}

Fibroma of the tendon sheath is a solitary, slow-growing, subcutaneous tumor with a predilection for the fingers, hands and wrists of middle-aged adults. It is more common in men. In general, the tumors are grayish-white, well-circumscribed, and attached to a tendon sheath. In contrast to the cell proliferation of star- or spindle-shaped cells like fibroblasts, as observed in SAF, this tumor presents sparse star-shaped cells embedded in a fibrocollagenous matrix with dilated or slit-like vascular channels.⁴⁵

Giant-cell tumor of the tendon sheath is a slow growing benign tumor with a predilection for the dorsal surface of the finger, near the distal interphalangeal joint in young adults. The tumors are lobulated, grayish-brown, and are usually attached to a tendon sheath. Histologically, they are spindle-shaped and are mixed in a collagen stroma. Multinucleated giant cells are characteristic. Hemosiderin pigment, xanthoma cells and chronic inflammatory cells are also a common finding. Mononuclear cells show immunoreactivity for CD68, but not for EMA, CD34 or smooth-muscle actin.⁴⁵

Glomus tumor is an extremely painful, solitary, subcutaneous mass that involves the fingers and toes in middle-aged adults. The subungual region may be affected. The tumor cells show immunoreactivity to vimentin and smooth-muscle actin in the cytoplasm.⁴⁵

In short, SAF should be included in the differential diagnosis of any slow-growing mass or nodule located in the periungual or subungual regions of the fingers and toes, as recommended in the studies evaluated in the present review.^{4,8,10,11,22,34,35,42}

The treatment of these tumors involves surgical excision to prevent malignancy and recurrence. Although the tumor does not show evidence of aggressive behavior, the presence of cytologic atypia in a small number of cases makes the malignant transformation potential unclear.¹

No cases of malignancy have been reported in the literature.¹⁰

Regular follow-up after excision is justified, as the reported recurrence rate may reach 24%, mainly due to incomplete excision.⁵⁻⁸

Conclusion

Superficial acral fibromyxoma is a single soft-tissue tumor with a predilection for the periungual and subungual acral regions. It presents a clinical picture and histopathological characteristics like other dermatological conditions, which makes its final diagnosis difficult.

The methods described in the literature that support the diagnostic definition are imaging tests, histopathological evaluations, and immunohistochemical studies.

Currently, the treatment for SAF is limited to simple excision, with a significant relapse rate and unknown malignancy.

Conflicts of Interest

The authors have none to declare.

References

- Fetsch JF, Laskin WB, Miettinen M. Superficial acral fibromyxoma: a clinicopathologic and immunohistochemical analysis of 37 cases of a distinctive soft tissue tumor with a predilection for the fingers and toes. *Hum Pathol* 2001;32(07):704-714
- Ashby-Richardson H, Rogers GS, Stadecker MJ. Superficial acral fibromyxoma: an overview. *Arch Pathol Lab Med* 2011;135(08):1064-1066
- Wakabayashi Y, Nakai N, Takenaka H, Katoh N. Superficial acral fibromyxoma of the great toe: case report and mini-review of the literature. *Acta Dermatovenereol Croat* 2012;20(04):263-266
- Messeguer F, Nagore E, Agustí-Mejías A, Traves V. Fibromixoma acral superficial, un tumor periungueal CD34 positivo. *Actas Dermosifiliogr* 2012;103(01):67-69
- Wei C, Fleegler EJ. Superficial acral fibromyxoma of the thumb. *Eplasty* 2013;13:ic13
- Prescott RJ, Husain EA, Abdellaoui A, et al. Superficial acral fibromyxoma: a clinicopathological study of new 41 cases from the U.K.: should myxoma (NOS) and fibroma (NOS) continue as part of 21st-century reporting? *Br J Dermatol* 2008;159(06):1315-1321
- Al-Daraji WI, Miettinen M. Superficial acral fibromyxoma: a clinicopathological analysis of 32 tumors including 4 in the heel. *J Cutan Pathol* 2008;35(11):1020-1026
- Hollmann TJ, Bovée JV, Fletcher CD. Digital fibromyxoma (superficial acral fibromyxoma): a detailed characterization of 124 cases. *Am J Surg Pathol* 2012;36(06):789-798
- Quaba O, Evans A, Al-Nafussi AA, Nassan A. Superficial acral fibromyxoma. *Br J Plast Surg* 2005;58(04):561-564
- André J, Theunis A, Richert B, de Saint-Aubain N. Superficial acral fibromyxoma: clinical and pathological features. *Am J Dermatopathol* 2004;26(06):472-474
- Oteo-Alvaro A, Meizoso T, Scarpellini A, Ballestín C, Pérez-Espejo G. Superficial acral fibromyxoma of the toe, with erosion of the distal phalanx. A clinical report. *Arch Orthop Trauma Surg* 2008;128(03):271-274
- Abou-Nukta F, Fiedler P, Parkash V, Arons J. Superficial acral fibromyxoma of the distal phalanx of the thumb. *J Hand Surg [Br]* 2006;31(06):619-620
- Meyerle JH, Keller RA, Krivda SJ. Superficial acral fibromyxoma of the index finger. *J Am Acad Dermatol* 2004;50(01):134-136
- Kazakov DV, Mentzel T, Burg G, Kempf W. Superficial acral fibromyxoma: report of two cases. *Dermatology* 2002;205(03):285-288
- Tardío JC, Butrón M, Martín-Fragueiro LM. Superficial acral fibromyxoma: report of 4 cases with CD10 expression and lipomatous component, two previously underrecognized features. *Am J Dermatopathol* 2008;30(05):431-435
- Pasquinelli G, Foroni L, Papadopoulos F, Dicandia L, Bisceglia M. Superficial acral fibromyxoma: immunohistochemical and ultrastructural analysis of a case, with literature review. *Ultrastruct Pathol* 2009;33(06):293-301
- Misago N, Ohkawa T, Yanai T, Narisawa Y. Superficial acral fibromyxoma on the tip of the big toe: expression of CD10 and nestin. *J Eur Acad Dermatol Venereol* 2008;22(02):255-257
- Varikatt W, Soper J, Simmons G, Dave C, Munk J, Bonar F. Superficial acral fibromyxoma: a report of two cases with radiological findings. *Skeletal Radiol* 2008;37(06):499-503
- Wang QF, Pu Y, Wu YY, Wang J. [Superficial acral fibromyxoma of finger: report of a case with review of literature]. *Zhonghua Bing Li Xue Za Zhi* 2009;38(10):682-685
- Luzar B, Calonje E. Superficial acral fibromyxoma: clinicopathological study of 14 cases with emphasis on a cellular variant. *Histopathology* 2009;54(03):375-377
- Chattopadhyay M, Farrant P, Higgins E, Hay R, Calonje E. A nodular lesion of the toe. Superficial acral fibromyxoma (SAF). *Clin Exp Dermatol* 2010;35(07):807-809
- Goo J, Jung YJ, Kim JH, Lee SY, Ahn SK. A case of recurrent superficial acral fibromyxoma. *Ann Dermatol* 2010;22(01):110-113
- Fanti PA, Dika E, Piraccini BM, Infusino SD, Baraldi C, Misciali C. Superficial acral fibromyxoma: a clinicopathological and immunohistochemical analysis of 12 cases of a distinctive soft tissue tumor with a predilection for the fingers and toes. *G Ital Dermatol Venereol* 2011;146(04):283-287
- Park SW, Kim JH, Shin HT, et al. Superficial acral fibromyxoma on the palm. *Ann Dermatol* 2014;26(01):123-124
- Agaimy A, Michal M, Giedl J, Hadravsky L, Michal M. Superficial acral fibromyxoma: clinicopathological, immunohistochemical, and molecular study of 11 cases highlighting frequent Rb1 loss/deletions. *Hum Pathol* 2017;60:192-198

- 26 Grigore LE, Baican CI, Botar-Jid C, et al. Clinico-pathologic, dermoscopic and ultrasound examination of a rare acral tumour involving the nail - case report and review of the literature. *Clujul Med* 2016; 89(01):160-164
- 27 Carranza C, Molina-Ruiz AM, Pérez de la Fuente T, Kutzner H, Requena L, Santonja C. Subungual acral fibromyxoma involving the bone: a mimicker of malignancy. *Am J Dermatopathol* 2015; 37(07):555-559
- 28 DeFroda SF, Starr A, Katarincic JA. Superficial acral fibromyxoma: A case report. *J Orthop* 2016; 14(01):23-25
- 29 Cogrel O, Stanislas S, Coindre JM, et al. [Superficial acral fibromyxoma: three cases]. *Ann Dermatol Venereol* 2010; 137(12):789-793
- 30 Sundaramurthy N, Parthasarathy J, Mahipathy SR, Durairaj AR. Superficial acral fibromyxoma: a rare entity - A case report. *J Clin Diagn Res* 2016; 10(09):PD03-PD05
- 31 Ramya C, Nayak C, Tambe S. Superficial acral fibromyxoma. *Indian J Dermatol* 2016; 61(04):457-459
- 32 Raghupathi DS, Krishnamurthy J, Kakoti LM. Cytological diagnosis of superficial acral fibromyxoma: A case report. *J Cytol* 2015; 32(01):39-41
- 33 Chabbab F, Metz T, Saez Beltran L, Theunis A, Richert B. [Superficial acral fibromyxoma in a sub-matrical location: An unusual variant]. *Ann Dermatol Venereol* 2014; 141(02):94-105
- 34 Schwager ZA, Mannava KA, Mannava S, Telang GH, Robinson-Bostom L, Jellinek NJ. Superficial acral fibromyxoma and other slow-growing tumors in acral areas. *Cutis* 2015; 95(02):E15-E19
- 35 García AM, Mendonça FM, Cejudo MP, Martínez FM, Martín JJ. Superficial Acral Fibromyxoma involving the nail's apparatus. Case report and literature review. *An Bras Dermatol* 2014; 89(01):147-149
- 36 Hwang SM, Cho KH, Lim KR, Jung YH, Kim Song J. Superficial acral fibromyxoma on the second toe. *Arch Plast Surg* 2013; 40(04): 477-479
- 37 Kwok C, Merchant WJ, Hussain W. Superficial acral fibromyxoma presenting as a haemorrhagic pigmented streak on the toenail. *Clin Exp Dermatol* 2013; 38(05):553-554
- 38 Ben Brahim E, Bouabdellah M, Khanchel F, Jouini R, Abdelmoula S, Chadli-Debbiche A. Superficial acral fibromyxoma. *Tunis Med* 2012; 90(04):340-341
- 39 Sawaya JL, Khachemoune A. Superficial acral fibromyxoma. *Int J Dermatol* 2015; 54(05):499-508
- 40 Ashby-Richardson H, Rogers GS, Stadecker MJ. Superficial acral fibromyxoma: an overview. *Arch Pathol Lab Med* 2011; 135(08): 1064-1066
- 41 Baek HJ, Lee SJ, Cho KH, et al. Subungual tumors: clinicopathologic correlation with US and MR imaging findings. *Radiographics* 2010; 30(06):1621-1636
- 42 Bindra J, Doherty M, Hunter JC. Superficial acral fibromyxoma. *Radiol Case Rep* 2015; 7(03):751
- 43 Durda J, Kazlouskaya V, Blochin E, Maguire CA, Elston D. Derm-path quiz. *Indian Dermatol Online J* 2013; 4(03):244-245
- 44 Mentzel T, Schärer L, Kazakov DV, Michal M. Myxoid dermatofibrosarcoma protuberans: clinicopathologic, immunohistochemical, and molecular analysis of eight cases. *Am J Dermatopathol* 2007; 29(05):443-448
- 45 Weedon D. *Skin pathology*. 2nd ed. London: Elsevier Science Ltd; 2002