



## Original Article

# Overdiagnosing of femoroacetabular impingement: correlation between clinical presentation and computed tomography in symptomatic patients<sup>☆</sup>



Richard Prazeres Canella<sup>a,\*</sup>, Guilherme Pradi Adam<sup>b</sup>, Roberto André Ulhôa de Castillo<sup>c</sup>, Daniel Codonho<sup>a</sup>, Gerson Gandhi Ganev<sup>d</sup>, Luiz Fernando de Vicenzi<sup>a</sup>

<sup>a</sup> Imperial Hospital de Caridade, Florianópolis, SC, Brazil

<sup>b</sup> Clínica Imagem, Florianópolis, SC, Brazil

<sup>c</sup> Hospital Governador Celso Ramos, Florianópolis, SC, Brazil

<sup>d</sup> Centro de Pesquisas Oncológicas (CEPON), Florianópolis, SC, Brazil

## ARTICLE INFO

## Article history:

Received 24 March 2015

Accepted 12 May 2015

Available online 16 February 2016

## Keywords:

Hip

Femoroacetabular impingement

X-ray computed tomography

## ABSTRACT

**Objective:** To correlate the angles between the acetabulum and the proximal femur in symptomatic patients with femoroacetabular impingement (FAI), using computed tomography (CT).

**Methods:** We retrospectively evaluated 103 hips from 103 patients, using multislice CT to measure the acetabular age, acetabular version (in its supraequatorial portion and in its middle third), femoral neck version, cervical-diaphyseal and alpha angles and the acetabular depth. For the statistical analysis, we used the Pearson correlation coefficient.

**Results:** There were inverse correlations between the following angles: (1) acetabular coverage versus alpha angle ( $p=0.019$ ); (2) acetabular version (supraequatorial) versus alpha angle ( $p=0.049$ ). For patients with femoral anteversion lower than 15 degrees: (1) acetabular version (supraequatorial) versus alpha angle ( $p=0.026$ ); (2) acetabular version (middle third) versus alpha angle ( $p=0.02$ ). For patients with acetabular version (supraequatorial) lower than 10 degrees: (1) acetabular version (supraequatorial) versus alpha angle ( $p=0.004$ ); (2) acetabular version (middle third) versus alpha angle ( $p=0.009$ ).

**Conclusion:** There was a statistically significant inverse correlation between the acetabular version and alpha angles (the smaller the acetabular anteversion angle was, the larger the alpha angle was) in symptomatic patients, thus supporting the hypothesis that FAI occurs when cam and pincer findings due to acetabular retroversion are seen simultaneously, and that the latter alone does not cause FAI, which leads to overdiagnosis in these cases.

© 2015 Sociedade Brasileira de Ortopedia e Traumatologia. Published by Elsevier Editora Ltda. All rights reserved.

<sup>☆</sup> Work performed in the Imperial Hospital de Caridade, Florianópolis, SC, Brazil.

\* Corresponding author.

E-mail: [rpcanella@md.aaos.org](mailto:rpcanella@md.aaos.org) (R.P. Canella).

<http://dx.doi.org/10.1016/j.rboe.2016.02.001>

2255-4971/© 2015 Sociedade Brasileira de Ortopedia e Traumatologia. Published by Elsevier Editora Ltda. All rights reserved.

## Sobrediagnóstico do impacto femoroacetabular: correlação entre a clínica e a tomografia computadorizada em pacientes sintomáticos

### R E S U M O

#### Palavras-chave:

Quadril  
Impacto femoroacetabular  
Tomografia computadorizada  
por raios X

**Objetivo:** Correlacionar, por tomografia computadorizada (TC), os ângulos entre o acetábulo e o fêmur proximal em pacientes sintomáticos com impacto femoroacetabular (IFA).

**Métodos:** Avaliamos, retrospectivamente, 103 quadris (103 pacientes) e medimos por TC multislice os ângulos de cobertura acetabular, de versão acetabular (em sua porção supraequatorial e no seu terço médio), de versão do colo femoral, cervicodifásario, alfa e de profundidade acetabular. Para análise estatística, usamos o coeficiente de correlação de Pearson.

**Resultados:** Houve correlação inversa entre os ângulos: 1) cobertura acetabular versus ângulo alfa ( $p=0,019$ ); 2) versão acetabular (supraequatorial) versus ângulo alfa ( $p=0,049$ ). Para pacientes com anteversão femoral menor do que  $15^\circ$ : 1) versão acetabular (supraequatorial) versus ângulo alfa ( $p=0,026$ ); 2) versão acetabular (terço médio) versus ângulo alfa ( $p=0,02$ ). Para pacientes com versão acetabular (supraequatorial) menor do que  $10^\circ$ : 1) versão acetabular (supraequatorial) versus ângulo alfa ( $p=0,004$ ); 2) versão acetabular (terço médio) versus ângulo alfa ( $p=0,009$ ).

**Conclusão:** Há correlação inversa estatisticamente significativa entre os ângulos de versão acetabular e o ângulo alfa (quanto menor o ângulo de anteversão acetabular, maior o ângulo alfa femoral) em pacientes sintomáticos. Isso reforça a hipótese de que o IFA ocorre quando há simultaneamente os achados de *cam* e *pincer* por retroversão acetabular e que esse não causa o IFA isoladamente, o que leva a sobrediagnóstico nesses casos.

© 2015 Sociedade Brasileira de Ortopedia e Traumatologia. Publicado por Elsevier Editora Ltda. Todos os direitos reservados.

## Introduction

Recent advances in understanding the anatomy and biomechanics of the coxofemoral joint have shown that morphological alterations to the hip or activities with excessive range of motion that lead to repetitive contact between the femoral neck and the acetabular rim may lead to a progressive degenerative process and early osteoarthritis of the hip.<sup>1</sup>

Reinhold Ganz<sup>2,3</sup> was the main author responsible for describing femoroacetabular impingement (FAI) and its two subtypes: *cam* and *pincer*. *Cam*-like impingement is caused by a bone prominence at the cervicocapital junction, which leads to loss of the normal sphericity of the femoral head. *Pincer*-like impingement is caused by excessive acetabular roof or by acetabular retroversion. According to Beck et al.,<sup>4</sup> both subtypes are present in 86% of the patients diagnosed with FAI.

So far, little is known about the cause and natural history of these anatomical alterations.<sup>5</sup> It is understood that there is a dynamic interaction between the proximal femur and the acetabulum,<sup>6,7</sup> which begins at the embryonic stage<sup>8</sup> with endochondral ossification regulated by intrauterine pressure and continues until adulthood. The joint remodeling depends on the mechanical stress to which the hip is exposed.<sup>9</sup> Thus, variations in the acetabular angle<sup>10,11</sup> and/or the angle of the proximal femur<sup>12,13</sup> would lead to early joint damage.

However, it has recently been suggested that *pincer*-like FAI is diagnosed excessively.<sup>14,15</sup> In a study in which the angular relationship between the acetabulum and proximal femur was correlated among asymptomatic patients, the presence of posterior angling of the acetabulum was thought to be

present due to compensation of the femoral anatomy during hip development.<sup>15</sup> In an analysis on hips presenting the *cam* and *pincer* types, it was observed that there was no significant difference in acetabular version in comparison with normal hips. This suggests that acetabular retroversion would not be the only cause of FAI.<sup>14</sup>

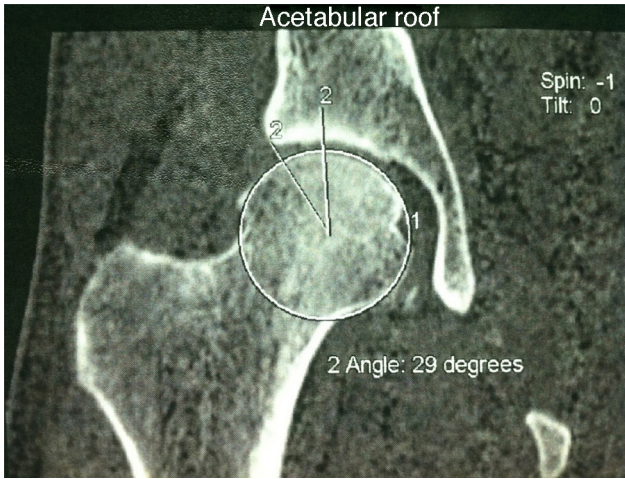
Our study had the aim of using multislice computed tomography (CT) to correlate the angles between the acetabulum and the proximal femur, in symptomatic patients with FAI.

## Methods

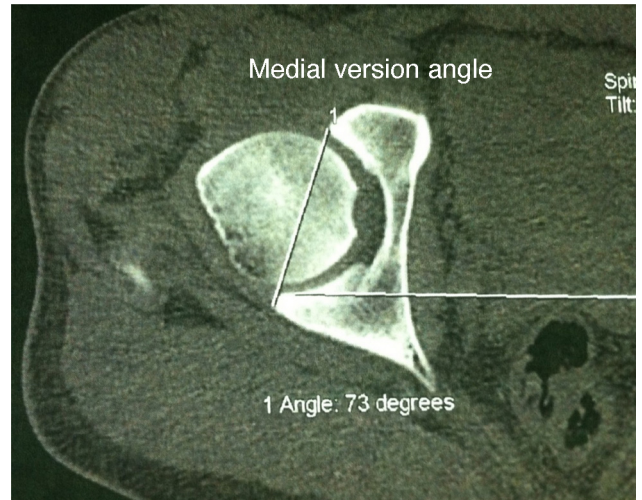
Our study was analyzed and approved by the research ethics committee of our institution. We selected 103 patients who underwent multislice CT on their hips between March and December 2010, because of clinical suspicion of femoroacetabular impingement. All of these patients presented complaints of pain in the hip joint and tested positive for anterior impact in physical examination maneuvers at 90 degrees of flexion combined with adduction and internal rotation.

Data on these patients' acetabular and femoral angles were gathered and subjected to statistical analysis. No exclusion criteria were used. The patients' mean age was 37 years (range: 16–68); 21 were men and 82 were women.

The technique consisted of producing a series of tomographic slices from the iliac crest to the knee joint line. The slices were 0.6 mm in thickness and were produced in a multislice tomography machine (GE Sigma Excite). The multislice CT images were used to perform guided puncture in order to inject 18 ml of physiological serum with 0.4 ml



**Fig. 1 – Tomographic measurement of the acetabular roof angle using Chen’s method.**



**Fig. 3 – Tomographic measurement of the version angle in the middle third of the acetabulum.**

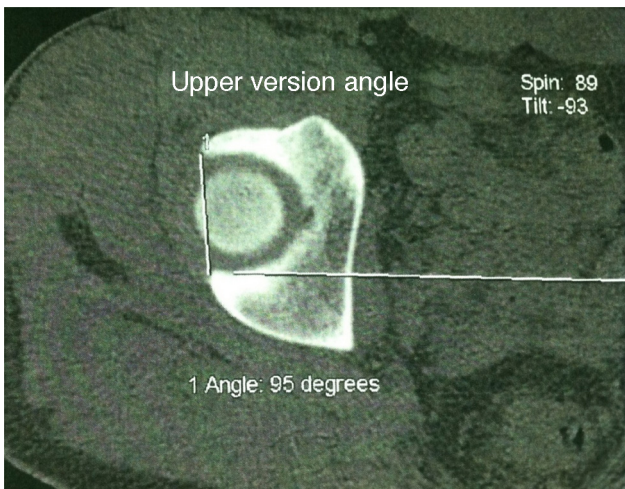
of gadoteric acid. Following this, magnetic resonance imaging (MRI) was also performed, using a GE Infinity machine. Axial T1 sequences with fat saturation in the femoral neck, sagittal and coronal sequences of thickness 0.3 cm, coronal STIR sequences of thickness 0.5 cm and axial proton density sequences with fat saturation were produced. The following angles were measured: acetabular roof angle using Chen’s method (Fig. 1); acetabular version angle in its cranial or supraequatorial portion (Fig. 2) and in its middle third (Fig. 3); alpha angle of the cervicocapital junction of the femur (Fig. 4); cervicodiaphyseal angle (Fig. 5); acetabular depth (Fig. 6); and femoral neck version angle (Fig. 7).

The measurements were made on the multislice tomography images, in an ADW 4.3 workstation. The alpha angle of the cervicocapital junction of the femur was evaluated by means of an oblique axial plane that crossed the center of the femoral neck, using coronal reformatting as the reference. Measurements of the alpha angle and the middle third of the acetabular version were then made on the image obtained, in accordance with the study by Kamath et al.<sup>16</sup> However, we

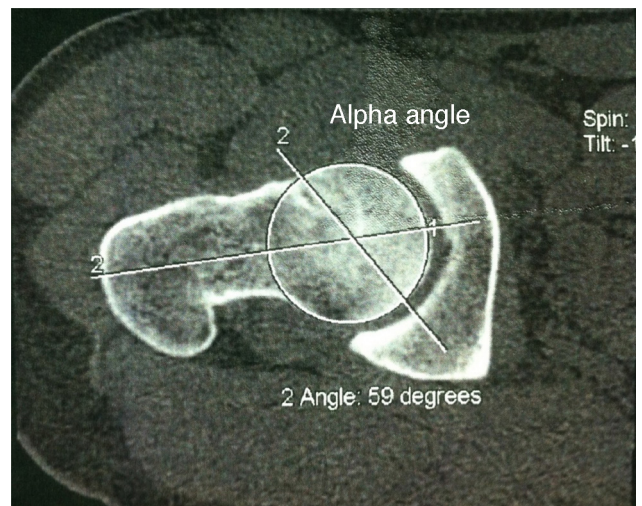
also included measurements of the angle of version of the cranial portion of the acetabulum, because of the importance of this location in the genesis of the impact and for differentiation of the overall retroversion of the acetabulum from the retroversion of its cranial portion alone.

To measure the acetabular anteversion, images in the axial plane were used, with correction of possible pelvic tilt, and lines tangential to the anterior and posterior borders of the acetabulum were traced out at the levels of the center of the femoral head and the top of the femoral head. The angle between these lines and the sagittal plane was measured.

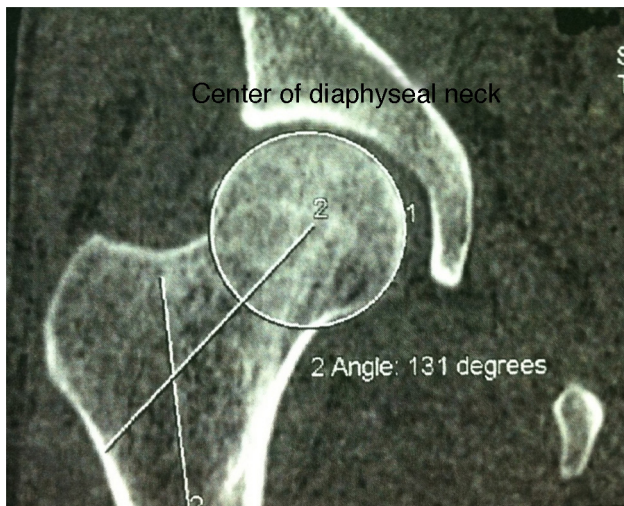
To measure the acetabular roof angle, the technique described by Chen et al. was used.<sup>17</sup> This involved using an image in the coronal plane that crossed the acetabula, in which the fundus of the acetabulum took on a “teardrop” appearance. On this image, two lines meeting at the center of the femoral head were traced out: one originating at the border of the acetabulum and the other parallel to the axial axis of the pelvis.



**Fig. 2 – Tomographic measurement of the version angle in the cranial or supraequatorial portion of the acetabulum.**



**Fig. 4 – Tomographic measurement of the alpha angle of the cervicocapital junction of the femur.**



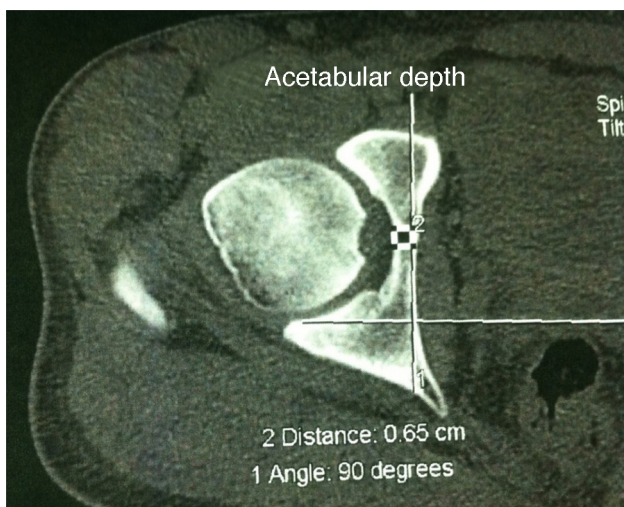
**Fig. 5 – Tomographic measurement of the cervicodiaphyseal angle.**

The angle of femoral neck version was measured by means of 3D reconstruction of the femur. Viewing from above, two lines were traced out: one crossing the center of the femoral neck and the other, tangential to the posterior portion of the femoral condyles. The cervicodiaphyseal angle was measured on the 3D reconstruction using an anterior view. In a manner similar to measurements on radiographs, one line was traced out along the axis of the femoral diaphysis and another along the axis of the femoral neck, and the angle between them was measured.

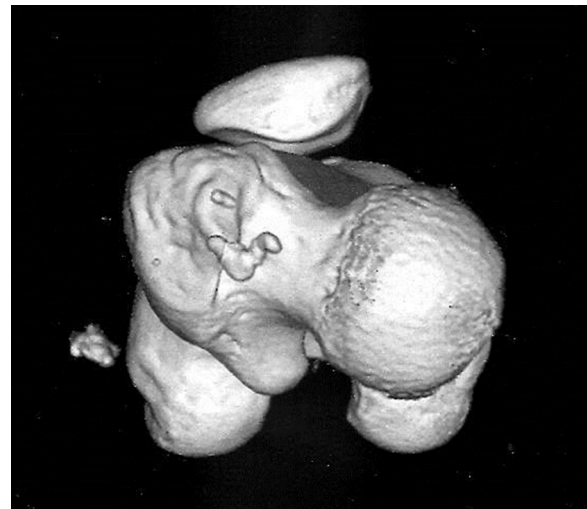
To analyze the data obtained by means of descriptive statistics, we used Pearson's correlation coefficient, taking  $p < 0.05$  as significant.

## Results

Table 1 presents the analysis on all the patients studied. From this, a statistically inverse correlation ( $p < 0.05$ ) was observed



**Fig. 6 – Tomographic measurement of the acetabular depth.**



**Fig. 7 – Three-dimensional reconstruction of the femur, with subtraction of the remainder of the bone structures in order to measure the femoral neck version.**

through cross-correlating the values of the acetabular roof angle versus the alpha angle and angle of version of the cranial or supraequatorial portion of the acetabulum versus the alpha angle. No statistical correlation was observed upon cross-correlating the remaining values.

In Table 2, only the patients with femoral anteversion less than 15 degrees were selected. Once again, a statistically significant inverse correlation ( $p < 0.05$ ) was observed upon cross-correlating the values of the angle of version of the cranial or supraequatorial portion of the acetabulum versus the alpha angle. In this evaluation, there was also an inverse cross-correlation between the angle of version of the middle third of the acetabulum and the alpha angle. The other numbers evaluated did not present statistical value.

In Table 3, only the patients with version of less than 10 degrees in the cranial or supraequatorial portion of the acetabulum were selected. In relation to Table 2, we observed a stronger statistically inverse correlation ( $p < 0.005$ ) upon cross-correlating the values of the angle of version of the cranial or supraequatorial portion of the acetabulum versus the alpha angle and angle of version of the middle third of the acetabulum versus the alpha angle. The other numbers evaluated did not present statistical value.

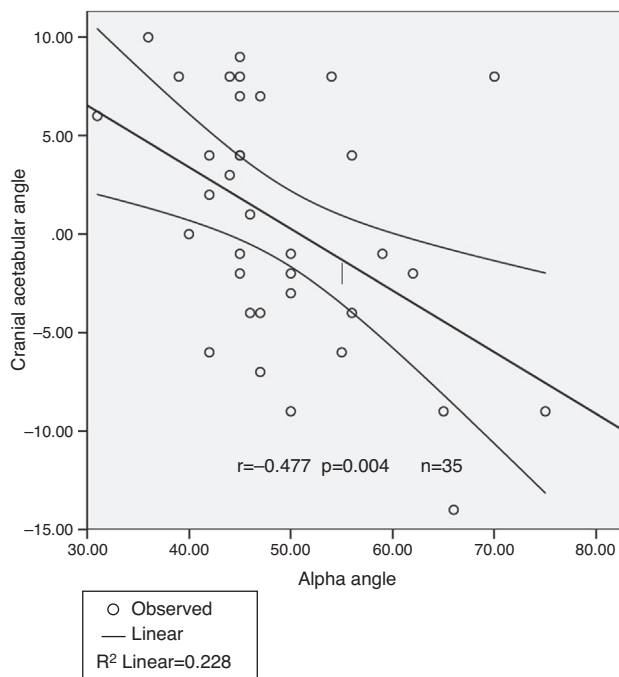
Fig. 8 shows the statistically significant inverse correlation between the supraequatorial acetabular version and the alpha angle among the patients selected in Table 3, in graph form. In other words, the smaller the angle of acetabular anteversion was, the larger the femoral alpha angle was, in symptomatic patients.

## Discussion

Moynihan et al.<sup>18</sup> warned about the potential for overdiagnosing various diseases and the potential deleterious consequences (both physical and psychological) for asymptomatic patients who might be subjected to unnecessary or excessive treatments.

**Table 1 – Statistical analysis on 103 patients, in which  $n$  = number of patients analyzed and  $p < 0.05$  suggests statistical significance.**

	Center-edge angle (Chen)	Acetabular depth	Cranial acetabular version	Middle-third acetabular version	Cervicodiaphyseal angle	Alpha angle	Femoral version angle
<i>Center-edge angle (Chen)</i>							
Pearson's correlation	1	-0.159	0.45	0.097	-0.046	-0.231	-0.029
$p$		0.109	0	0.328	0.646	0.019	0.775
$n$	103	103	103	103	103	103	103
<i>Acetabular depth</i>							
Pearson's correlation	-0.159	1	-0.352	-0.377	0.274	0.14	0.025
$p$	0.109		0	0	0.005	0.159	0.8
$n$	103	103	103	103	103	103	103
<i>Cranial acetabular version</i>							
Pearson's correlation	0.45	-0.352	1	0.493	-0.103	-0.194	-0.001
$p$	0	0		0	0.302	0.049	0.989
$n$	103	103	103	103	103	103	103
<i>Middle-third acetabular version</i>							
Pearson's correlation	0.097	-0.377	0.493	1	0.06	-0.183	0.089
$p$	0.328	0	0		0.547	0.065	0.372
$n$	103	103	103	103	103	103	103
<i>Cervicodiaphyseal angle</i>							
Pearson's correlation	-0.046	0.274	-0.103	0.06	1	0.099	-0.019
$p$	0.646	0.005	0.302	0.547		0.318	0.846
$n$	103	103	103	103	103	103	103
<i>Alpha angle</i>							
Pearson's correlation	-0.231	0.14	-0.194	-0.183	0.099	1	0.104
$p$	0.019	0.159	0.049	0.065	0.318		0.294
$n$	103	103	103	103	103	103	103
<i>Femoral version angle</i>							
Pearson's correlation	-0.029	0.025	-0.001	0.089	-0.019	0.104	1
$p$	0.775	0.8	0.989	0.372	0.846	0.294	
$n$	103	103	103	103	103	103	103

**Fig. 8 – Correlation between supraequatorial acetabular version and alpha angle in the selected patients of Table 3.**

There is a fundamental aim to discriminate better between benign “abnormalities” and those that will progress and cause harm. Like in the spine, there is high prevalence of “abnormalities” in the hip region. MRI may show alterations that are not clinically important, thus also leading to overdiagnosis.<sup>19</sup>

Most cases of femoroacetabular impingement (FAI) are considered to be primary, i.e. of unknown cause. Hips with symptomatic FAI differ from “normal” hips due to a combination of factors such as morphology, vulnerability of the labrum and cartilage and demands placed on the hips, in relation to activity level and range of motion.<sup>19</sup>

Cam-like FAI is recognized as a factor that causes early osteoarthritis of the hip, through injury to the joint cartilage and labrum, which leads to functional incapacity in young adult patients with an active lifestyle.<sup>20</sup>

Abnormalities at the head-neck junction in skeletally mature individuals have been correlated with hip osteoarthritis. This has been demonstrated in cases of proximal epiphyseal slippage of the femur and in cases of fracturing of the femoral neck with consolidation presenting slight rotational deformity.<sup>12,21</sup> The origin of these morphological alterations remains unknown,<sup>19</sup> but some studies<sup>15,22</sup> have suggested that they may occur while the individual is still in the intrauterine period, such that the acetabulum would adapt its format and version according to its contact with the proximal femur and according to the positioning of the fetal limbs.

**Table 2 – Statistical analysis with selection of the patients with femoral anteversion of less than 15 degrees.**

	Center-edge angle (Chen)	Acetabular depth	Cranial acetabular version	Middle-third acetabular version	Cervicodiaphyseal angle	Alpha angle	Femoral version angle
<i>Center-edge angle (Chen)</i>							
Pearson's correlation	1	-0.187	0.333	0.067	0.054	-0.176	-0.212
<i>p</i>		0.219	0.025	0.661	0.727	0.248	0.161
<i>n</i>	45	45	45	45	45	45	45
<i>Acetabular depth</i>							
Pearson's correlation	-0.187	1	-0.443	-0.409	0.164	0.238	0.017
<i>p</i>	0.219		0.002	0.005	0.282	0.116	0.911
<i>n</i>	45	45	45	45	45	45	45
<i>Cranial acetabular version</i>							
Pearson's correlation	0.333	-0.443	1	0.49	-0.003	-0.331	0.018
<i>p</i>	0.025	0.002		0.001	0.983	0.026	0.906
<i>n</i>	45	45	45	45	45	45	45
<i>Middle-third acetabular version</i>							
Pearson's correlation	0.067	-0.409	0.49	1	-0.003	-0.346	0.04
<i>p</i>	0.661	0.005	0.001		0.984	0.02	0.794
<i>n</i>	45	45	45	45	45	45	45
<i>Cervicodiaphyseal angle</i>							
Pearson's correlation	0.054	0.164	-0.003	-0.003	1	-0.009	-0.034
<i>p</i>	0.727	0.282	0.983	0.984		0.954	0.827
<i>n</i>	45	45	45	45	45	45	45
<i>Alpha angle</i>							
Pearson's correlation	-0.176	0.238	-0.331	-0.346	-0.009	1	0.002
<i>p</i>	0.248	0.116	0.026	0.02	0.954		0.992
<i>n</i>	45	45	45	45	45	45	45
<i>Femoral version angle</i>							
Pearson's correlation	-0.212	0.017	0.018	0.04	-0.034	0.002	1
<i>p</i>	0.161	0.911	0.906	0.794	0.827	0.992	
<i>n</i>	45	45	45	45	45	45	45

*n*, number of patients analyzed.  
*p* < 0.05 suggests statistical significance.

Hogervorst<sup>21</sup> suggested that these alterations occurred at the end of growth.

Computed tomography is useful for evaluating FAI because it enables measurement of angles with clear anatomical references and reduces the interobserver discrepancies. Measurement of femoral version is done more easily and precisely through tomography than through conventional radiography. Tomography also enables correlation of positioning errors during the post-processing. Another advantage of tomography is the 3D reconstructions that can be made, which provide detailed models that are very useful for preoperative planning. The main problem in making evaluations using tomography is the fact that patients are evaluated in the decubitus position and there may be changes to pelvic tilt in relation to the upright standing position.<sup>23,24</sup>

In our study, we reproduced our daily practice regarding investigation of FAI. CT is requested and the following are routinely measured: acetabular roof angle using Chen's method; angle of version of the cranial or supraequatorial portion of the acetabulum and in the middle third; alpha angle of the cervicocapital junction of the femur; cervicodiaphyseal angle; acetabular depth; and angle of version of the femoral neck.

Buller et al.<sup>15</sup> evaluated 230 hips of 115 asymptomatic patients by means of 3D reconstruction software. The angle of version of the femoral neck, cervicodiaphyseal angle, angle of version and inclination of the acetabulum and center-edge angle were measured. They showed that there was a positive correlation between the angles of femoral and acetabular version and concluded that compensation between the femur and acetabulum occurred during joint formation. The present study suggests that in some patients in whom it was believed that pathological retroversion of the acetabulum (pincer action) was occurring, the proximal femur would compensate for this. These patients were thus wrongly being diagnosed with FAI. The difference between Buller's study and ours is that we evaluated a symptomatic population, i.e. all of our patients had undergone examination due to clinical suspicion of FAI.

Tönnis and Heinecke<sup>22</sup> demonstrated the relationship between acetabular and femoral version and the range of motion of the hip. In this, increased anteversion leads to increased range of motion, while decreased physiological anteversion causes decreased range of motion, due to the impact of the proximal femur on the anterior wall of the

**Table 3 – Statistical analysis with selection of the patients with version of the cranial or supraequatorial acetabulum of less than 10 degrees.**

	Center-edge angle (Chen)	Acetabular depth	Cranial acetabular version	Middle-third acetabular version	Cervicodiaphyseal angle	Alpha angle	Femoral version angle
<i>Center-edge angle (Chen)</i>							
Pearson's correlation	1	-0.236	0.25	0.14	0.043	-0.151	-0.334
p		0.172	0.148	0.423	0.807	0.387	0.05
n	35	35	35	35	35	35	35
<i>Acetabular depth</i>							
Pearson's correlation	-0.236	1	-0.305	-0.266	0.146	0.227	0.051
p	0.172		0.074	0.122	0.402	0.189	0.769
n	35	35	35	35	35	35	35
<i>Cranial acetabular version</i>							
Pearson's correlation	0.25	-0.305	1	0.146	-0.043	-0.477	-0.175
p	0.148	0.074		0.402	0.807	0.004	0.314
n	35	35	35	35	35	35	35
<i>Middle-third acetabular version</i>							
Pearson's correlation	0.14	-0.266	0.146	1	0.038	-0.434	-0.007
p	0.423	0.122	0.402		0.828	0.009	0.967
n	35	35	35	35	35	35	35
<i>Cervicodiaphyseal angle</i>							
Pearson's correlation	0.043	0.146	-0.043	0.038	1	0.053	-0.135
p	0.807	0.402	0.807	0.828		0.764	0.439
n	35	35	35	35	35	35	35
<i>Alpha angle</i>							
Pearson's correlation	-0.151	0.227	-0.477	-0.434	0.053	1	0.045
p	0.387	0.189	0.004	0.009	0.764		0.799
n	35	35	35	35	35	35	35
<i>Femoral version angle</i>							
Pearson's correlation	-0.334	0.051	-0.175	-0.007	-0.135	0.045	1
p	0.05	0.769	0.314	0.967	0.439	0.799	
n	35	35	35	35	35	35	35

n, number of patients analyzed.  
p < 0.05 suggests statistical significance.

acetabulum. In addition, they noted that normal or increased femoral anteversion was generally compensated for, through diminished acetabular version, and vice versa.

Nepple et al.<sup>25</sup> observed that the general prevalence of coxa profunda was 55% among hips in four groups (dysplastic hips, hips with residual deformities from Legg-Calvé-Perthes disease, hips with FAI and asymptomatic hips) and concluded that coxa profunda was a nonspecific radiological finding and that it could be considered to be a normal finding, at least among women.

In 2008, Ganz et al.<sup>2</sup> questioned the notion that all patients with morphological abnormalities indicative of FAI would develop arthrosis and contraindicated treatment for asymptomatic patients. A study by Hartofilakidis et al.<sup>26</sup> showed that most (82.3%) of the patients with radiological evidence of FAI remained asymptomatic and free from osteoarthritis for a mean of 18.5 years, and that the only significant predictor of osteoarthritis was the presence of idiopathic osteoarthritis in the contralateral hip. This suggests that systemic pathological factors may have greater influence than minimal morphological alterations and would contraindicate surgical treatment for asymptomatic patients with radiographic evidence of FAI.

Arthroscopic treatment of cam-like impact has shown good results, especially among patients placing high demand on the joints. Javed and O'Donnell<sup>27</sup> evaluated the results from treating cam-like FAI by means of arthroscopic femoral osteochondroplasty in patients over the age of 60 years. They reported a high satisfaction rate (75%), without any cases of complications and with evaluation to total hip arthroplasty in 17% of the cases.

In the orthopedic literature, several treatments for pincer-like FAI have been described, including periacetabular osteotomy<sup>1,2</sup> and rim trimming with labral repair.<sup>28</sup> However, there are no randomized prospective studies with measurement of objective data, for example regarding the result from physiotherapeutic treatment for patients with pincer-like FAI alone. The cam and pincer components rarely occur separately,<sup>1,4</sup> but it has still not been investigated whether it is necessary to deal with cam and pincer deformities in the same hip, or just on one side of the joint.<sup>19</sup>

Siebenrock et al.<sup>24</sup> warned that in hips with coxa profunda or acetabular protrusion that undergo realignment by means of periacetabular osteotomy, an increase in posterior roof may lead to posteroinferior impact. Palmer suggested that the short-term improvement perceived after acetabular

reconstruction for treating FAI might, in reality, be the result from concomitantly dealing with labral or chondral lesions.<sup>29</sup>

Arthroscopic treatment for the femoral component of FAI (cam), with femoral osteochondroplasty and consequent correction of the alpha angle, followed by repair of chondral and labral lesions, has shown excellent clinical results.<sup>20</sup> We believe that this technique, which is not greatly aggressive toward the acetabular roof, could be indicated for the vast majority of patients with real indications for orthopedic surgical treatment.

## Conclusion

Our findings, supported by the presence of a statistically significant inverse correlation between the angle of acetabular version and the alpha angle in symptomatic patients, reinforce the hypothesis that pincer action due to acetabular retroversion is not the sole cause of FAI, given that in asymptomatic individuals, there is acetabular retroversion that is compensated by the femur. In symptomatic patients, this correlation is inverse, i.e. the smaller the acetabular anteversion is, the larger the alpha angle of the femur is.

This may aid orthopedists in making therapeutic decisions regarding the various clinical presentations of FAI and also provide a warning to them regarding the existence of overdiagnosis.

## Conflicts of interest

The authors declare no conflicts of interest.

## REFERENCES

- Crawford JR, Villar RN. Current concepts in the management of femoroacetabular impingement. *J Bone Joint Surg Br.* 2005;87(11):1459-62.
- Ganz R, Leunig M, Leunig-Ganz K, Harris WH. The etiology of osteoarthritis of the hip: an integrated mechanical concept. *Clin Orthop Relat Res.* 2008;466(2):264-72.
- Ganz R, Parvizi J, Beck M, Leunig M, Nötzli H, Siebenrock KA. Femoroacetabular impingement: a cause for osteoarthritis of the hip. *Clin Orthop Relat Res.* 2003;417:112-20.
- Beck M, Kalhor M, Leunig M, Ganz R. Hip morphology influences the pattern of damage to the acetabular cartilage: femoroacetabular impingement as a cause of early osteoarthritis of the hip. *J Bone Joint Surg Br.* 2005;87(7):1012-8.
- Haviv B, Burg A, Velkes S, Salai M, Dudkiewicz I. Trends in femoroacetabular impingement research over 11 years. *Orthopedics.* 2011;34(5):353.
- Beaupre GS, Orr TE, Carter DR. An approach for time-dependent bone modeling and remodeling: theoretical development. *J Orthop Res.* 1990;8(5):651-61.
- McKibbin B. Anatomical factors in the stability of the hip joint in the newborn. *J Bone Joint Surg Br.* 1970;52(1):148-59.
- Carter DR, Orr TE, Fyhrie DP, Schurman DJ. Influences of mechanical stress on prenatal and postnatal skeletal development. *Clin Orthop Relat Res.* 1987;(219):237-50.
- Carter DR. Mechanical loading history and skeletal biology. *J Biochem.* 1987;20(11-12):1095-109.
- Dora C, Zurbach J, Hersche O, Ganz R. Pathomorphologic characteristics of posttraumatic acetabular dysplasia. *J Orthop Trauma.* 2000;14(7):483-9.
- Reynolds D, Lucas J, Klaue K. Retroversion of the acetabulum: a cause of hip pain. *J Bone Joint Surg Br.* 1999;81(2):281-8.
- Leunig M, Casillas MM, Hamlet M, Hersche O, Nötzli H, Slongo T, et al. Slipped capital femoral epiphysis: early mechanical damage to the acetabular cartilage by a prominent femoral metaphysis. *Acta Orthop Scand.* 2000;71(4):370-5.
- Ito K, Minka MA, Leunig M, Werlen S, Ganz R. Femoroacetabular impingement and the cam-effect: a MRI-based quantitative anatomical study of the femoral head-neck offset. *J Bone Joint Surg Br.* 2001;83(2):171-6.
- Cobb J, Logishetty K, Davda K, Iranpour F. Cams and pincer impingement are distinct, not mixed: the acetabular pathomorphology of femoroacetabular impingement. *Clin Orthop Relat Res.* 2010;468(8):2143-51.
- Buller LT, Rosneck J, Monaco FM, Butler R, Smith T, Barsoum WK. Relationship between proximal femoral and acetabular alignment in normal hip joints using 3-dimensional computed tomography. *Am J Sports Med.* 2012;40(2):367-75.
- Kamath S, Narayanaswamy S. Computed tomography assessment of hip joints in asymptomatic individuals in relation to femoroacetabular impingement. *Am J Sports Med.* 2010;38(8):NP1.
- Chen L, Boonthathip M, Cardoso F, Clopton P, Resnick D. Acetabulum protrusio and center edge angle: new MR-imaging measurement criteria - a correlative study with measurement derived from conventional radiography. *Skeletal Radiol.* 2009;38(2):123-9.
- Moynihan R, Doust J, Henry D. Preventing overdiagnosis: how to stop harming the healthy. *Br Med J.* 2012;344:19-23.
- Pollard TC. A perspective on femoroacetabular impingement. *Skeletal Radiol.* 2011;40(7):815-8.
- Byrd JW, Jones KS. Arthroscopic femoroplasty in the management of cam-type femoroacetabular impingement. *Clin Orthop Relat Res.* 2008;467(3):739-46.
- Hogervorst T, Bouma H, de Boer SF, de Vos J. Human hip impingement morphology: an evolutionary explanation. *J Bone Joint Surg Br.* 2011;93(6):769-76.
- Tönnis D, Heinecke A. Acetabular and femoral anteversion. Relationship with osteoarthritis of the hip. *J Bone Joint Surg Am.* 1999;81(12):1747-70.
- Konishi N. The three-dimensional acetabular coverage and its positional change due to change of pelvic tilt. *Hip Joint.* 1993;19:423-7.
- Siebenrock KA, Schoeniger R, Ganz R. Anterior femoro-acetabular impingement due to acetabular retroversion: treatment with periacetabular osteotomy. *J Bone Joint Surg Am.* 2003;85(2):278-86.
- Nepple JJ, Lehmann CL, Ross JR, Schoenecker PL, Clohisy JC. Coxa profunda is not a useful radiographic parameter for diagnosing pincer-type femoroacetabular impingement. *J Bone Joint Surg Am.* 2013;95(5):417-23.
- Hartofilakidis G, Bardakos NV, Babis GC, Georgiades G. An examination of the association between different morphotypes of femoroacetabular impingement in asymptomatic subjects and the development of osteoarthritis of the hip. *J Bone Joint Surg Br.* 2011;93(5):580-6.
- Javed A, O'Donnell JM. Arthroscopic femoral osteochondroplasty for cam femoroacetabular impingement in patients over 60 years of age. *J Bone Joint Surg Br.* 2011;93:326-31.
- Philippon MJ, Schenker ML. A new method for acetabular rim trimming and labral repair. *Clin Sports Med.* 2006;25(2):293-7.
- Palmer WE. Femoroacetabular impingement: caution is warranted in making imaging-based assumptions and diagnoses. *Radiology.* 2010;257(1):4-7.