

Secondary tics and tourettism

Tiques secundários e touretismo

Nicte I Mejia,¹ Joseph Jankovic¹

Original version accepted in English

Abstract

Motor and phonic tics are most frequently due to Tourette syndrome, but there are many other causes of tics. We analyzed data on 155 patients with tics and co-existent disorders (101M/54F; mean age 40.5 ± 20.2 years). Fourteen (9.0%) patients had tics associated with an insult to the basal ganglia, such as head trauma ($N = 4$, 2.5%), stroke ($N = 2$, 1.2%), encephalitis ($N = 3$, 1.9%) and other causes. In addition, certain drugs, toxins, and post-infectious causes were associated with tics. Rarely, peripheral injury can cause movement disorders, including tics ($N = 1$, 0.6%). Pervasive developmental disorders, including Asperger's syndrome ($N = 13$, 8.3%), mental retardation ($N = 4$, 2.5%), autism ($N = 3$, 1.9%), and Savant's syndrome ($N = 1$, 0.6%), also may be associated with tics, as noted in 21 of the 155 patients (13.5%). Genetic and chromosomal disorders, such as Down's syndrome 5 (3.2%), neuroacanthocytosis ($N = 2$, 1.2%), and Huntington's disease ($N = 1$, 0.6%), were associated with tics in 16 patients (10.3%). We have also examined the co-existence of tics and other movement disorders such as dystonia ($N = 31$, 20.0%) and essential tremor ($N = 17$, 10.9%). Sixteen (10.3%) patients presented psychogenic tics, and one (0.6%) psychogenic tics and dystonia; conversely, Tourette syndrome preceded the onset of psychogenic dystonia ($N = 1$, 0.6%), and psychogenic tremor ($N = 1$, 0.6%) in two patients. Finally, 12 (7.7%) patients had tics in association with non-movement related neurological disorders, such as static encephalopathy ($N = 2$, 1.2%) and seizures ($N = 3$, 1.9%). To understand the physiopathology of tics and Tourette syndrome, it is important to recognize that these may be caused or associated with other disorders.

Keywords: Tics; Tourette syndrome; Basal ganglia; Adult

Resumo

Tiques motores e fônicos são usualmente sintomas da síndrome de Tourette idiopática; entretanto, existem muitas causas orgânicas conhecidas para os tiques. Analisando os prontuários de 155 pacientes (101 homens/54 mulheres; idade média $40,5 \pm 20,2$ anos) com tiques e transtornos comórbidos encontramos que: 14 (9,0%) pacientes tinham tiques secundários a lesão dos gânglios da base, decorrentes de trauma craniano ($N = 4$; 2,5%), acidente vascular cerebral ($N = 2$; 1,2%), encefalite ($N = 3$; 1,9%) ou outras causas. Além disso, certas drogas, toxinas e complicações pós-infecciosas puderam ser etiologicamente associadas aos tiques. Raramente, lesões periféricas estiveram associadas a transtornos do movimento, incluindo tiques ($N = 1$; 0,6%). Transtornos globais do desenvolvimento, incluindo síndrome de Asperger ($N = 13$; 8,3%), retardo mental ($N = 4$; 2,5%), autismo ($N = 3$; 1,9%) e síndrome de Savant ($N = 1$; 0,6%), também podem estar associados a tiques, como observado em 21 dos 155 pacientes (13,5%). Doenças genéticas e cromossômicas, como a síndrome de Down ($N = 5$; 3,2%), a neuroacantocitose ($N = 2$; 1,2%) e a doença de Huntington ($N = 1$; 0,6%) estavam associadas a tiques em 16 pacientes (10,3%). Também examinamos a comorbidade de tiques com outros transtornos de movimento como distonia ($N = 31$; 20,0%) e tremor essencial ($N = 17$; 10,9%). Dezesesseis (10,3%) pacientes apresentaram tiques psicogênicos e um (0,6%), tiques psicogênicos e distonia; ao contrário, síndrome de Tourette precedeu o início de distonia psicogênica ($N = 1$; 0,6%) e tremor psicogênico ($N = 1$; 0,6%) em dois pacientes. Finalmente, 12 (7,7%) pacientes tinham tiques associados a transtornos neurológicos não relacionados ao movimento, como encefalopatia estática ($N = 2$; 1,2%) e convulsões ($N = 3$; 1,9%). Para entender a fisiopatologia dos tiques e da síndrome de Tourette é importante reconhecer que esses podem ser causados por ou associados a outros transtornos.

Descritores: Tiques; Síndrome de Tourette; Gânglios da base; Adulto

¹ Parkinson's Disease Center and Movement Disorders Clinic, Department of Neurology, Baylor College of Medicine, Houston, Texas, USA

Correspondence

Joseph Jankovic
Department of Neurology Baylor College of Medicine
6550 Fannin, Suite 1801
Houston, TX 77030
Phone: 713-798-5998 Fax: 713-798-6808.
E-mail: josephj@bcm.tmc.edu

Financing and conflict
of interests: non-existent
Submitted: 20 October 2004
Accepted: 15 December 2004

Introduction

Tics are characterized by abrupt, repetitive movements (motor tics) or sounds (phonic tics), that are commonly preceded by a premonitory sensation of an urge, tension, discomfort, or other sensory phenomena.¹⁻² Although Tourette syndrome (TS)³ is the most frequent cause of tics, there are many other causes of tics, such as insults to the brain, particularly the basal ganglia, due to infection, stroke, or head trauma; certain toxins or drugs can also cause tics.⁴⁻⁵ A variety of sporadic, genetic, and neurodegenerative disorders may also exhibit tics. We review all cases of tics associated with other disorders (sometimes termed "tourettism") that have presented to our clinic, in a belief that a study of secondary cases of tics may provide insight into the pathogenesis of primary tics and TS. We also differentiate from other movement disorders that may exhibit similarities to tics, thus termed "tic mimickers".

Methods

We selected patients with tics and associated disorder(s) that have presented to the Baylor College of Medicine Movement Disorders Clinic. Tics were defined as abrupt, repetitive movements or sounds, commonly preceded by premonitory phenomena. Data such as age of onset of tics and the co-existent disorders was documented. The characteristics of tics, such as their type, location, means of onset, and course were also included. The existence of sensory phenomena; obsessive-compulsive behaviors (OCB); attention-deficit, behavioral, and sleep problems; as well as a family history of tics, were also ascertained. Imaging, laboratory, treatment, and outcome data were included when available.

Results

We have evaluated 1452 patients with tics at Baylor College of Medicine since 1981, of whom, 1138 (78.3%) have met the diagnostic criteria for TS, without having a co-existent disorder other than the commonly associated behavioral and psychiatric co-morbidities, such as attention deficit disorder (ADD) and obsessive-compulsive disorder (OCD). Complete information was available for 159 of the 314 (50.6%) patients with tics who did not meet TS criteria or had tics and co-existent disorder(s). We analyzed data in 155 patients who had tics but did not fulfill the diagnostic criteria for TS, "transient tic disorder" of childhood, "chronic multiple tic disorder", or "chronic single tic disorder" as this separation of tics, viewed as variants of TS, seems artificial because all can occur in the same family and probably represent a variable expression of the same genetic defect.⁶ Of the 155 patients (mean age 40.5 ± 20.2 years), 101 (65.1%) were male, and 54 (34.8%) female; it is unclear why males had a higher incidence of tics. Sixty (38.7%) had a first-degree relative with tics; although a family history of OCD may also be associated with the development of tics, we did not have documentation of this in our series.

Tics and the associated diagnoses occurred concomitantly in 35 (22.5%) patients. Tics preceded the co-existent disorders in 71 (45.8%) patients; the latency between diagnoses was 24.5 ± 17.4 years for 32 (20.6%) patients and unknown for the other 39 (25.1%). Finally, tics were preceded by the co-existent disorders in 49 (31.6%) patients; in 38 (24.5%) of whom the latency between diagnoses was 8.7 ± 6.8 years, while in the remaining 11 (7.0%) the time difference was unknown. Most tics were focal (N = 85, 54.8%), simple motor (N = 51, 32.9%), with a gradual onset (N = 69,

44.5%), and a progressive course (N = 80, 51.6%). Similar to TS, the majority of the patients with secondary tics had obsessive-compulsive features (N = 81, 52.2%), in contrast to TS, only a minority had attention deficit (N = 54, 34.8%), behavioral (N = 31, 20%), or sleep (N = 8, 5.1%) problems. We were able to obtain adequate follow-up on only about a third of the patients (N = 52, 33.5%). Of those who had follow-up data (N = 52, 33.5%), 43 (27.7%) had symptomatic improvement, 3 (1.9%) did not notice a change in symptoms, and 6 (3.8%) had worsening of symptoms.

Insults to the basal ganglia, documented by imaging or laboratory data, were associated with the onset of tics in 14 (9.0%) of the 155 patients. Four (2.5%) patients presented head trauma and tics; in two the head trauma preceded the onset of tics; the other two patients, previously reported by us,⁷ had an initial diagnosis of tics, which were markedly exacerbated after the traumatic insult. Three (1.9%) patients presented tics after an infectious process. One female patient developed severe complex motor and vocal tics, as well as inability to walk, abruptly after a rubella virus (German measles) infection at age 8; her brain "magnetic resonance image (MRI)" at age 48 showed bilateral lesions in the putamen and globus pallidus. Another 4-year-old female patient had sudden onset of simple motor and vocal tics during and after what seemed to be an unspecified viral infection, characterized by 3 weeks of fever up to 104F, without clear respiratory, gastrointestinal or other neurological signs. The third patient with tics associated with an infectious process was an 18-year-old male who developed sudden ataxia and simple motor tics after a *Mycoplasma pneumoniae* infection; a brain MRI taken during the infectious period showed diffuse right basal ganglia hyperdensities, predominantly in the striatum, but was found to be normal one week after its resolution. We previously described⁸ two (1.2%) male patients in this series, both of whom developed hemidystonia, tics, and behavioral comorbidities after suffering a subcortical stroke. One suffered a hemorrhagic stroke in the right caudate and putamen, while assisting his father to unload wood boards, and six months later developed tics, attention deficit hyperactivity disorder (ADHD) and compulsive type behaviors; the other had tics in association with a ischemic stroke in the distribution of the right middle cerebral artery, which affected the head of the right caudate, and two weeks later caused left upper extremity dystonia, followed by facial tics. One female patient (0.6%) with recurrent GABHS (Group A Beta Hemolytic Streptococcus) infections since 8 months of age, was diagnosed with PANDAS (Autoimmune Neuropsychiatric Disorder Associated with Streptococcal infection) when she was 8 years old, and two years later developed simple motor tics; she was also diagnosed with severe obsessive-compulsive disorder and self-injurious behavior, such as picking at scabs until bleeding. A 29-year-old (N = 1, 0.6%) patient had acute onset of incapacitating simple motor tics after exposure to toluene, xylene and carbon monoxide. Finally, tics were caused by exposure to dopamine receptor blocking drugs (neuroleptics) in 3 patients treated for psychiatric conditions (1.9%); these "tardive tourettism" cases were associated with drugs such as clozapine, fluphenazine, and buspirone.

Tics were associated with pervasive developmental disorder (PDD) in 21 of the 155 patients (13.5%) [Figure 1]. Asperger's syndrome, an autistic disorder with impairment in reciprocal social interaction, circumscribed interest in one topic, verbal and nonverbal communication problems, motor clumsiness,

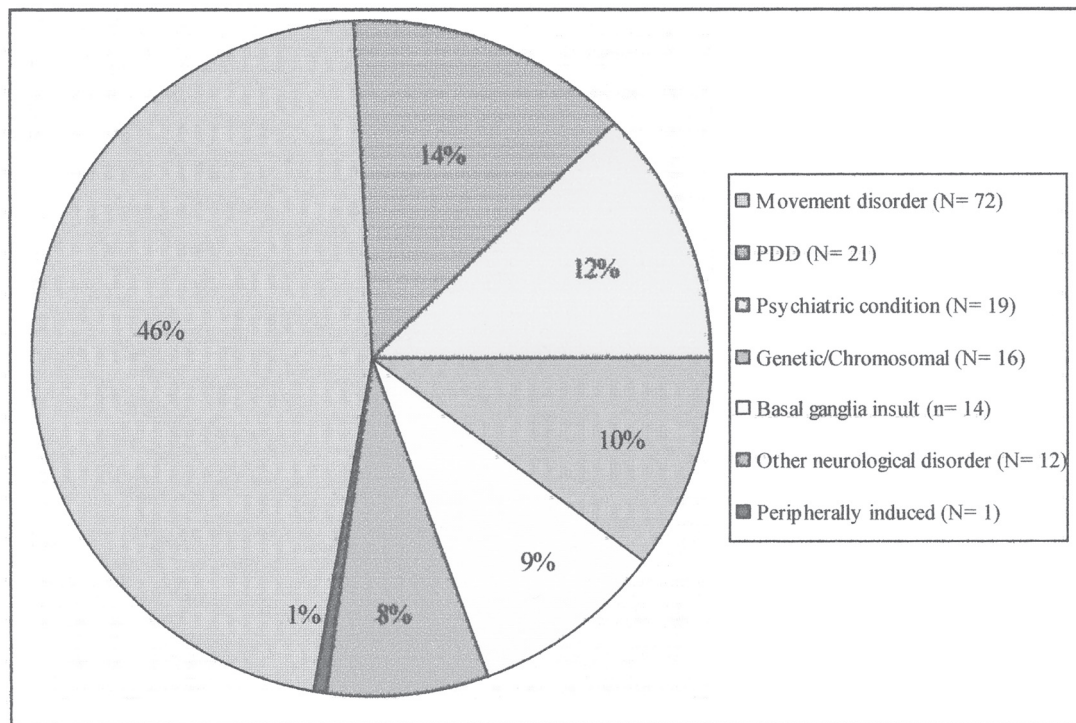


Figure 1 – Associated diagnoses in 155 patients with tics and co-existent disorders

repetitive behavior, and rigid thinking, was the most common PDD associated with tics (N = 13; 8.3%). We previously reported seven of the Asperger syndrome patients in our series, 6 of whom met the diagnostic criteria for TS.⁹ We also observed tics in patients with mental retardation (N = 4; 2.5%), autism (N = 3; 1.9%), and Savant's syndrome (N = 1; 0.6%), a unique type of autism in which extraordinary skills and talents such as musical or mathematical exist.¹⁰

Several genetic and chromosomal disorders were found to be associated with tics in 16 patients (10.3%). Five patients (3.2%) had co-existent tics and Down's syndrome. Neuroacanthocytosis, an autosomal recessive disorder linked to chromosome 9q21 and homozygous mutations in the CHAC (chorea-acanthocytosis) gene,¹¹⁻¹² was the associated diagnosis for 2 (1.2%) patients; this disorder is typically manifested by chorea (58%), stereotypy (53%), dystonia (47%), parkinsonism (34%), involuntary vocalizations (47%), and self-mutilatory behaviors such as lip and tongue biting.¹³ Also, our series included one (0.6%) previously reported case,¹⁴ a 40 year-old man who had tics as the presenting symptom of Huntington disease; his movements included facial grimacing, head jerking, sniffing, and coughing. Due to a history of depression, a family history of a neurodegenerative disorder, and MRI evidence of caudate and cortical atrophy, he underwent DNA analysis, which confirmed the diagnosis of this autosomal dominant neurodegenerative disorder. Other genetic and chromosomal disorders associated with tics were corpus callosum dysgenesis (N = 1; 0.6%), mental retardation due to craniosynostosis (N = 1; 0.6%), Arnold-Chiari malformation (N = 1; 0.6%), Klinefelter's disease (N = 1; 0.6%), neurofibromatosis (N = 1; 0.6%), congenital heart disease (N = 1; 0.6%), and Sandifer syndrome (N = 1; 0.6%), flexion movement involving chiefly the neck and trunk, associated

with either esophageal reflux or hiatus hernia. Finally, one (0.6%) of our patients, with progressive myoclonus epilepsy of Unverricht-Lundborg type (EPM1), an autosomal recessive type of progressive myoclonus epilepsy,¹⁵ initially presented with the diagnosis of facial tic, possibly secondary to TS.

A variety of other movement disorders were found to co-exist with tics in 72 (46.4%) patients [Figure 1]. Dystonia, characterized by involuntary, sustained, patterned and repetitive muscle contractions of opposing muscles, causing twisting movements, abnormal postures, or both,¹⁶ was the associated disorder in 31 (20.0%) patients. Of these, 24 (15.4%) initially met the diagnostic criteria for TS, and later in life were found to develop dystonia. In contrast, primary dystonia preceded the onset of tics in 3 (1.9%) patients. Three (1.9%) additional patients had co-existent dystonia and tics without a clear understanding of which occurred first, while 1 (0.6%) other patient had onset of tics and dystonia at the same time. Essential tremor (ET), a postural and kinetic tremor, co-existed with tics in 17 (10.9%) patients. In our series of patients with childhood ET, tics associated with TS were present in 23.1% of patients.¹⁷ Three (1.9%) patients initially diagnosed with TS developed Parkinson's disease (PD) later in life. Restless legs syndrome (RLS), a syndrome of spontaneous, continuous leg movements associated with urge to move and unpleasant paresthesias, co-existed with tics in 5 (3.2%) patients. Myoclonus, a lightning-like movement produced by a sudden and brief contraction (positive myoclonus) or a muscle inhibition (negative myoclonus), was the associated disorder in 1 (0.6%) patient who was previously diagnosed with TS. Of the patients initially diagnosed with TS, 4 (2.5%) later developed dystonia and ET, 2 (1.2%) developed ET and PD, 1 developed ET and akathisia, and 1 (0.6%) other developed dystonia and segmental myoclonus. Three (1.9%) patients

presented with dystonia and RLS, without a clear understanding of which disease occurred initially. One other (0.6%) patient had onset of myoclonus, tics and ET at the same time, without a clear etiologic relationship between these diagnoses. Other movement disorders associated with tics were Roussy-Levy syndrome (the combination of postural tremor and hereditary motor-sensory neuropathy; N = 1, 0.6%), post-traumatic hemiparkinsonism (N = 1, 0.6%) and stiff-person syndrome (progressive, usually symmetric rigidity of the axial muscles with superimposed painful spasms precipitated by different stimuli; N = 1, 0.6%). Sixteen (10.3%) patients were found to develop psychogenic tics, defined according to published criteria¹⁸ (Figure 1). Some of the stressors related with the onset of tics were medical or surgical procedures (N = 3; 1.9%), such as the removal of a breast implant; work-related incidents (N = 2; 1.2%), like falling from a furniture tractor; a death in the family (N = 1, 0.6%); leaving home (N = 1; 0.6%); sport tournaments (N = 1; 0.6%); and motor vehicle accidents (N = 1; 0.6%). One (0.6%) patient had tics as part of a panic attack in the emergency room, while another (N = 1, 0.6%) had onset of tics while meditating. Two (1.2%) patients had no apparent stressors, but had family members with TS or attention-deficit disorder. There were no apparent precipitating stressors identified in additional 3 (1.9%) patients, all with onset after age 21. One other (0.6%) patient developed psychogenic dystonia and tics. The diagnosis of TS preceded the onset of psychogenic dystonia (N = 1, 0.6%), and psychogenic tremor (N = 1, 0.6%) in two patients.

Twelve (7.7%) patients had tics in association with non-movement related neurological disorders (Figure 1), such as static encephalopathy (N = 2, 1.2%), seizures (N = 3, 1.9%), headaches (N = 3, 1.9%), dementia (N = 1, 0.6%), narcolepsy (N = 1, 0.6%), optic neuritis (N = 1, 0.6%), and dysautonomy associated with a probable myopathy (N = 1, 0.6%). Finally, one (0.6%) 41 year-old patient who dislocated his left shoulder after a motorcycle accident developed scapular rotational tics after the peripheral injury; the tics worsened after re-injuring his shoulder while lifting a trashcan, producing him to have the scapular movements almost every day. Although his "jerking" movements mimicked myoclonus, his feeling of discomfort and tightness before the rotational movement indicated it to be a tic.

Discussion

Our report draws attention to the broad range of causes of tics, beyond TS, the most recognized cause, particularly in children and adolescents. Although the specific etiology and pathogenesis of tics cannot be always determined, in many cases of tics not related to TS, clear anatomical-clinical relationship can be established. For example, the association of tics with well documented lesions involving the basal ganglia suggests that these subcortical structures play an important role in the genesis of not only secondary tics (tourettism), but also in primary tics (TS).⁴ As demonstrated in our series, tourettism may occur with insults to the basal ganglia, and may be a feature of other disorders such as PDD, movement, chromosomal or genetic disorders.

Stroke and other insults to the basal ganglia have been reported to produce symptoms otherwise typical of TS.^{8,19-21} The two previously reported boys⁸ in this series, who two weeks after suffering right hemispheric basal ganglia strokes at age eight, presented with hemidystonia, cranial-cervical

tics, ADHD and OCD, strongly demonstrated a cause and effect relationship, especially because of the temporal relationship between the stroke and subsequent TS-like symptoms, as well as the absence of phonic tics and family history of TS. One of the earliest reports of stroke related tourettism is that of a 43-year-old man who developed tics including tongue clicking and protrusion, eye closure, sniffing, and frowning, as well as palilalia after a four-artery angiography, which presumably caused a stroke involving the basal ganglia.¹⁹ Another case is that of a 62-year-old woman who presented with an acute onset of dysphasia and a suppressible "urge" to shake her right arm was found to have lacunar infarcts in the right superior cerebellar peduncle and left basal ganglia.²⁰ Masso and Obe-so also reported a 66-year-old man with post-anoxic hemiballism and coprolalia, but without motor tics.²¹

Only a few reports of tics after closed head injuries exist. A 27-year-old man without a family history of tics developed multiple motor tics following closed head trauma with loss of consciousness.²² Majumdar et al²³ reported a seven-year-old girl who developed motor and phonic tics fifteen months after being struck by a car and sustaining a severe head injury; her MRI later showed encephalomalacia in the left putamen, globus pallidus, head of the caudate, and the internal capsule. We previously reported⁷ 2 of the 4 patients included in this series who presented with motor and vocal tics associated to closed craniocerebral trauma.

The encephalitic lethargica pandemic that occurred in Europe between 1916 and 1927 provided evidence that infectious process involving the brain, particularly the subcortical structures may lead to simple and complex motor and phonic tics, such as complex vocalizations, blocking tics, compulsive shouting (klazomania), echolalia, palilalia, and oculogyric crises. Autopsy examinations in these cases showed neurofibrillary tangles and neuronal loss in the globus pallidus, hypothalamus, midbrain tegmentum, periaqueductal gray matter, striatum and the substantia nigra.²⁴⁻²⁵ Dale and colleagues reported a 4-year-old who developed motor tics, palilalia, and ADHD shortly after developing acute varicella zoster striatal encephalitis.²⁶ Herpes simplex and human immunodeficiency virus encephalitis, mycoplasma pneumoniae, and lyme infections have also been reported to be associated with motor and phonic tics.⁵ Besides specific brain infections, there are post-infectious disorders that can be associated with a variety of movement disorders, including, tics. Group A beta-hemolytic Streptococcus (GABHS) infections and complications such as Sydenham's chorea (SC)²⁷ and Pediatric Autoimmune Neuropsychiatric Disorders Associated with Streptococcal infection (PANDAS) has also been reported to co-exist with TS and OCD,²⁸⁻²⁹ even though the lack of disease- and severity-specific anti-neuronal antibodies, as well as other inconsistencies, have cast doubt on the pathogenic relationship between PANDAS and TS.³⁰

Amphetamines, cocaine, heroin, methylphenidate, pemoline, levodopa, anti-depressants, carbamazepine, phenytoin, phenobarbitol, lamotrigine, dextroamphetamine, and other dopamine blocking agents (DRBD, neuroleptics) have been reported to induce or exacerbate tics.⁵ We reported a 22-year-old patient with TS who had been in remission until age 20 and later had recurrence of tics due to cocaine.³¹ Tardive tourettism due to exposure to dopamine receptor blocking drugs (DRBD) or neuroleptics has been also reported. Bharucha and Sethi³² described a 45-year-old schizophrenic man who developed after a 10-year treatment with DRBD

(fluphenazine, perphenazine, thiothixene). There have been other cases of DRBD-related tics (tardive tourettisms).⁵ Finally, tics have been reported as a result of exposure to certain toxins such as carbon monoxide, wasp venom and mercury.⁵

Twenty-one (13.5%) of the patients in our series had tics and a co-existent PDD. PDD such as infantile autism, Asperger syndrome, Rett syndrome, and mental retardation, may have a variety of features typically associated with TS, such as attention deficit hyperactivity disorder (ADHD), disinhibition, poor impulse control and obsessive-compulsive features.⁵ Comings, in his series of 41 patients with PDD, reported 16 (39.0%) later developed TS symptoms.³³ Besides tics, Asperger syndrome has also been observed to co-exist with stereotypies.^{9,34} In a series of 31 male patients diagnosed with TS, we found no mutations in the *MECP2* gene on chromosome X28, responsible for Rett syndrome, another PDD that may manifest tics in addition to other movement disorders.³⁵⁻³⁶

We and others also found numerous genetic and chromosomal disorders that may be associated with tics. We first drew attention to the occurrence of both motor and phonic tics in over 40% of patients with neuroacanthocytosis,¹³ the co-existent disorder for 2 (1.2%) of our patients. Several cases of adult-onset tics have also been reported to be the presenting or co-existing feature of HD. Before our case of HD-related tourettism,¹⁴ a 40-year-old man with childhood-onset TS who eventually evolved into HD was reported by Kerbeshian and colleagues in 1991.³⁷ It should be recognized that the diagnosis of tics in HD patients may be difficult because of overlapping phenomenology of tics and chorea (both are abrupt, brief, jerk-like and multifocal movements), and because TS and HD, particularly in early stages, share common features such as involuntary vocalizations, disinhibitive and impulsive behaviors, affective disorders, poor attention, obsessive-compulsive features and family history.⁵ Besides the multiple genetic and chromosomal disorders associated with tics in our series, others previously shown to be related with tics include X-linked mental retardation (MRX23), Albright hereditary osteodystrophy, Duchenne muscular dystrophy, factor VIII hemophilia, fragile X syndrome, Lesch-Nyhan syndrome, triple X and 9P mosaicism, 47 XXY karyotype, partial trisomy 16, 9p monosomy, Beckwith-Wiedemann syndrome, tuberous sclerosis, congenital adrenal hyperplasia secondary to 21-hydroxylase deficiency, phenylketonuria, and Neurodegeneration with Brain Iron Accumulation (NBIA).⁵ Although not included in our series of patients, NBIA (previously termed Hallervorden-Spatz disease), a severely incapacitating neurodegenerative disorder that presents usually in the second or third decade of life with progressive dementia, dystonia, rigidity, and spasticity, may also exhibit simple and complex tics, stereotypies, self-mutilatory behavior, and OCD.³⁸ The NBIA gene was originally linked to 20p12.3-p13³⁹ and later a 7-bp deletion and various missense mutations were identified in PANK-2 gene, which codes for pantothenate kinase (essential for the regulation of coenzyme A biosynthesis).⁴⁰ The disorder with the clinical phenotype of NBIA associated with mutations in the PANK-2 gene is now referred to as pantothenate kinase associated neurodegeneration (PKAN).⁴¹ The diagnosis of NBIA is aided with MRI, which may show marked hypointensity (deposition of iron) surrounded by an area of hyperintensity (gliosis and axonal spheroids) in the globus pallidus internal segment ("eye-of-the-tiger" sign) and hypointensity of substantia nigra reticulata on T2-weighted images.⁴² Case studies have found tics to be a rare presenting symptom of NBIA; a 20-

year-old male with NBIA who initially developed generalized seizures, anxiety, cognitive and memory impairment was later found to have multiple complex motor tics (such as leg crossing) and vocal tics.⁴³

The majority of patients in our series (N = 72; 46.4%) had tics associated with another movement disorder, such as dystonia. Both dystonia and tics may share clinical phenomenology in that both may be rapid, patterned and repetitive. When present in the setting of TS, the term "dystonic tic" has been used to characterize tics that are transiently sustained, such as oculogyric tics, blepharospasm, and rotatory movements of the scapula; indeed, dystonic movements of the scapula are nearly always due to tics.⁴⁴ Dystonic movements as a manifestation of dystonia may not be easily differentiated from dystonic tics in patients with TS, but the latter are typically preceded by premonitory sensations.⁴⁵ The differentiation between dystonia and tics is further complicated by the occasional co-existence of both in the same individual. We initially reported nine patients in whom motor tics preceded the onset of their primary dystonia.⁴⁶ Families affected with TS and dystonia have also been described; Nemeth and colleagues reported a three-generation family in which 5 patients presented with dystonia and 3 also had TS, manifested chiefly by facial tics.⁴⁷ In addition to primary dystonia, tics may be associated with a variety of secondary dystonias.⁴⁸ For example, three members of a large Danish family with dopa-responsive dystonia and the X251R mutation in the GCH1 gene were also affected with TS.⁴⁹ Myoclonus, associated with tics in some of our patients, may be caused by a variety of genetic and secondary causes. We have excluded mutations in the SGCE gene, responsible for the dystonia-myoclonus syndrome, which shares some clinical features with TS, in a population of well-defined TS.⁵⁰

Finally, it is important to recognize that some movement disorders, termed "tic mimickers", may be difficult to differentiate from tics. Many patients with dystonia, chorea and myoclonus are initially thought to have tics and, on the other hand, tics have been wrongly diagnosed in some of our patients as one of these hyperkinetic movement disorders. Similar to a tic, myoclonus is a jerk-like movement, but in contrast to tics it is usually not suppressible and it is not preceded by premonitory sensations. Progressive myoclonus epilepsy of Unverricht Lundborg type (EPM1), one of the major types of progressive myoclonus epilepsy, is an autosomal recessive disorder with onset between 6-15 years, characterized by stimulus sensitive myoclonus and tonic clonic seizures.⁵¹ One (0.6%) of our patients, with EPM1 initially presented with the diagnosis of facial tic, possibly secondary to TS. Similar to juvenile myoclonic epilepsy, EPM1 is also frequently exacerbated by phenytoin. The gene responsible for EPM1 is localized to 21q22.3, and encodes cystatin B, a cysteine protease inhibitor.¹⁵ Interestingly, cystatin B mutations are now known to account for both Mediterranean myoclonus and for "Baltic" myoclonus, which were previously thought to represent separate entities. Myoclonus is also exhibited in Lafora's disease, an autosomal recessive form of progressive myoclonus epilepsy caused by several different mutations in the EPM2A gene, which codes for laforin (a protein with unknown function, but similar to a family of enzymes known as phosphatases). This disorder, which may be rarely initially misdiagnosed as TS, is characterized clinically by the onset of myoclonic and photoconvulsive seizures in late childhood and early teens, progressively intractable seizures, dementia and death within

10 years after onset; microscopically, Lafora bodies (polyglucosan inclusions) may be found in brain tissue, staining strongly with periodic acid-Schill (PAS).⁵² Generalized and multifocal myoclonus, sometimes wrongly diagnosed as tics, may also be seen in patients with anoxic brain insult, Alzheimer's disease and Creutzfeldt-Jakob disease. Myoclonus may be a post-infectious disorder, as part of the opsoclonus-myoclonus syndrome.⁵³

Conclusion

We have reviewed cases of well-documented tics and other features of TS in association with a variety of causes and disorders. Although an association between these disorders and tics does not necessarily define a cause and effect relationship, these reports provide clues to the pathogenic mechanisms underlying idiopathic tic disorders and TS. For example, the association between subcortical lesions due to stroke, trauma, or infection, provides support for the involvement of basal ganglia in the genesis of tics and related neurobehavioral disorders.

References

- Jankovic J. Tourette's syndrome. *N Engl J Med.* 2001;345(16):1184-92. Comment in: *N Engl J Med.* 2002;346(9):710.
- Leckman JF, Peterson BS, King RA, Scahill L, Cohen DJ. Phenomenology of tics and natural history of tic disorders. *Adv Neurol.* 2001;85:1-14.
- Definitions and classification of tic disorders. The Tourette Syndrome Classification Study Group. *Arch Neurol.* 1993;50(10):1013-6.
- Jankovic J. Differential diagnosis and etiology of tics. *Adv Neurol.* 2001;85:15-29.
- Jankovic J, Kwak C. Tics in other neurological disorders. In: Kurlan R. *Handbook of Tourette's Syndrome and related Tic and behavioral disorders.* New York, NY: Marcel Dekker; 2004. (in press).
- Kurlan R, Behr J, Medved L, Como P. Transient tic disorder and the spectrum of Tourette's syndrome. *Arch Neurol.* 1988;45(11):1200-1.
- Krauss JK, Jankovic J. Tics secondary to craniocerebral trauma. *Mov Disord.* 1997;12(5):776-82.
- Kwak CH, Jankovic J. Tourettism and dystonia after subcortical stroke. *Mov Disord.* 2002;17(4):821-5.
- Ringman JM, Jankovic J. Occurrence of tics in Asperger's syndrome and autistic disorder. *J Child Neurol.* 2000;15(6):394-400.
- Heaton P, Wallace GL. Annotation: the savant syndrome. *J Child Psychol Psychiatry.* 2004;45(5):899-911.
- Rampoldi L, Danek A, Monaco AP. Clinical features and molecular basis of neuroacanthocytosis. *J Mol Med.* 2002;80(8):475-91.
- Saiki S, Hirose G, Sakai K, Matsunari I, Higashi K, Saiki M, et al. Chorea-acanthocytosis associated with tourettism. *Mov Disord.* 2004;19(7):833-6.
- Spitz MC, Jankovic J, Killian JM. Familial tic disorder, parkinsonism, motor neuron disease, and acanthocytosis: a new syndrome. *Neurology.* 1985;35(3):366-70.
- Jankovic J, Ashizawa T. Tourettism associated with Huntington's disease. *Mov Disord.* 1995;10(1):103-5.
- Di Giaimo R, Riccio M, Santi S, Galeotti C, Ambrosetti DC, Melli M. New insights into the molecular basis of progressive myoclonus epilepsy: a multiprotein complex with cystatin B. *Hum Mol Genet.* 2002;11(23):2941-50.
- Jankovic J, Fahn S. Dystonic disorders. In: Jankovic J, Tolosa E, eds. *Parkinson's Disease and movement disorders*, 4th ed Philadelphia, PA; Lippincott Williams and Wilkins; 2002. p. 331-57.
- Jankovic J, Madisetty J, Vuong KD. Essential tremor in children. *J Pediatr.* 2004 (in press).
- Thomas M, Jankovic J. Psychogenic movement disorders: diagnosis and management. *CNS Drugs.* 2004;18(7):437-52.
- Bleeker HE. Gilles de la Tourette's syndrome with direct evidence of organicity. *Psychiatr Clin (Basel).* 1979;11(3):147-54.
- Ward CD. Transient feelings of compulsion caused by hemispheric lesions: three cases. *J Neurol Neurosurg Psychiatry.* 1988;51(2):266-8.
- Martí-Massó JF, Obeso JA. Coprolalia associated with hemiballismus: response to tetrabenazine. *Clin Neuropharmacol.* 1985;8(2):189-90.
- Singer C, Sanchez-Ramos J, Weiner WJ. A case of post-traumatic tic disorder. *Mov Disord.* 1989;4(4):342-4.
- Majumdar A, Appleton RE. Delayed and severe but transient Tourette syndrome after head injury. *Pediatr Neurol.* 2002;27(4):314-7.
- Wolfhart G, Ingvar DH, Hellberg AM. Compulsory shouting (Benedek's "klazomania") associated with oculogyric spasms in chronic epidemic encephalitis. *Acta Psychiatr Scand.* 1961;36:369-77.
- Howard RS, Lees AJ. Encephalitis lethargica: a report of four recent cases. *Brain.* 1987;110(Pt 1):19-33.
- Dale RC, Church AJ, Heyman I. Striatal encephalitis after Varicella Zoster infection complicated by tourettism. *Mov Disord.* 2003;18(12):1554-6.
- Cardoso F. Infectious and transmissible movement disorders. In: Jankovic J, Tolosa E, eds. *Parkinson's disease and movement disorders.* 4th ed. Baltimore: Williams and Wilkins; 2002. p. 930-40.
- Dale RC, Church AJ, Surtees RA, Lees AJ, Adcock JE, Harding B, et al. Encephalitis lethargica syndrome: 20 new cases and evidence of basal ganglia autoimmunity. *Brain.* 2004;127(Pt 1):21-33.
- Jankovic J. Can peripheral trauma induce dystonia and other movement disorders? Yes! *Mov Disord.* 2001;16(1):7-12.
- Singer HS, Loiselle CR, Lee O, Minzer K, Swedo S, Grus FH. Anti-basal ganglia antibodies in PANDAS. *Mov Disord.* 2004;19(4):406-15.
- Cardoso FE, Jankovic J. Cocaine related movement disorders. *Mov Disord.* 1993;8(2):175-8.
- Bharucha KJ, Sethi KD. Tardive tourettism after exposure to neuroleptic therapy. *Mov Disord.* 1995;10(6):791-3.
- Comings DE, Comings BG. Clinical and genetic relationships between autism, pervasive developmental disorder and Tourette syndrome: a study of 19 cases. *Am J Med Genet.* 1991;39(2):180-91.
- Vokmar FR, Klin A, Pauls D. Nosological and genetic aspects of Asperger syndrome. *J Autism Dev Disord.* 1998;28(5):457-63.
- Rosa AL, Jankovic J, Ashizawa T. Screening for mutations in the MECP2 (Rett syndrome) gene in Gilles de la Tourette syndrome. *Arch Neurol.* 2003;60(4):502-3.
- Fitzgerald PM, Jankovic J, Glaze DG, Schultz R, Percy AK. Extrapyramidal involvement in Rett's syndrome. *Neurology.* 1990;40(2):293-5.
- Kerbeshian J, Burd L, Leech C, Rorabaugh A. Huntington's disease and childhood onset Tourette syndrome. *Am J Med Genet.* 1991;39(1):1-3.
- Nardocci N, Rumi V, Combi ML, Angelini L, Mirabile D, Bruzzone MG. Complex tics, stereotypies, and compulsive behavior as clinical presentation of a juvenile progressive dystonia suggestive of Hallervorden-Spatz disease. *Mov Disord.* 1994;9(3):369-71.
- Taylor TD, Litt M, Kramer P, Pandolfo M, Angelini L, Nardocci N, et al. Homozygosity mapping of Hallervorden-Spatz syndrome 20p12.3-p13. *Nat Genet.* 1996;14(4):479-81.
- Zhou B, Westaway SK, Levinson B, Johnson MA, Gitschier J, Hayflick SJ. A novel pantothenate kinase gene (PANK2) is defective in Hallervorden-Spatz syndrome. *Nat Genet.* 2001;28(4):345-9. Comment in: *Nat Genet.* 2001;28(4):299-300
- Thomas M, Hayflick SJ, Jankovic J. Clinical heterogeneity of neurodegeneration with iron accumulation-1 (Hallervorden-Spatz Syndrome) and Pantothenate Kinase Associated Neurodegeneration (PKAN). *Mov Disord.* 2004;19(1):36-42.
- Hayflick SJ, Westaway SK, Levinson B, Zhou B, Johnson MA, Ching KH, et al. Genetic, clinical, and radiographic delineation of Hallervorden-Spatz syndrome. *N Engl J Med.* 2003;348(1):33-40.
- Carod-Artal FJ, Vargas AP, Marinho PB, Fernandes-Silva TV, Portugal D. Tourettism, hemiballism and juvenile parkinsonism: expanding the clinical spectrum of the neurodegeneration associated to pantothenate kinase deficiency (Hallervorden-Spatz syndrome). *Rev Neurol.* 2004;38(4):327-31.

44. Jankovic J, Stone L. Dystonic tics in patients with Tourette's syndrome. *Mov Disord.* 1991;6(3):248-52.
45. Kwak C, Dat Vuong K, Jankovic J. Premonitory sensory phenomenon in Tourette's syndrome. *Mov Disord.* 2003;18(12):1530-3.
46. Stone LA, Jankovic J. The coexistence of tics and dystonia. *Arch Neurol.* 1991;48(8):862-5.
47. Nemeth AH, Mills KR, Elston JS, Williams A, Dunne E, Hyman NM. Do the same genes predispose to Gilles de la Tourette syndrome and dystonia? Report of a new family and review of the literature. *Mov Disord.* 1999;14(5):826-31.
48. Jankovic J. In: Fernandez-Alvarez E, Arzimanoglou A, Tolosa E, eds. *Paediatric movement disorders.* Montrouge, France: John Libbey Eurotext; 2004 (in press).
49. Romstad A, Dupont E, Krag-Olsen B, Ostergaard K, Guldberg P, Guttler F. Dopa-responsive dystonia and Tourette syndrome in a large Danish family. *Arch Neurol.* 2003;60(4):618-22.
50. De Carvalho Aguiar P, Fazzari M, Jankovic J, Ozelius LJ. Examination of the SGCE gene in Tourette syndrome patients with obsessive-compulsive disorder. *Mov Disord.* 2004;19(10):1237-8.
51. Lehesjoki AE, Koskiniemi M. Progressive myoclonus epilepsy of Unverricht Lundborg type. *Epilepsia.* 1999;40(Suppl 3):23-8.
52. Ianzano L, Young EJ, Zhao XC, Chan EM, Rodriguez MT, Torrado MV, et al. Loss of function of the cytoplasmic isoform of the protein laforin (EPM2A) causes Lafora progressive myoclonus epilepsy. *Hum Mutat.* 2004;23(2):170-6.
53. Pranzatelli MR, Travelstead AL, Tate ED, Allison TJ, Moticka EJ, Franz DN, et al. B- and T-cell markers in opsoclonus-myoclonus syndrome: immunophenotyping of CSF lymphocytes. *Neurology.* 2004;62(9):1526-32.