

Diectophyme renale Goeze, 1782 in a cat with a supernumerary kidney

Diectophyme renale Goeze, 1782 em gata com rim supranumerário

Daniela Pedrassani^{1*}; Hamilton Wendt²; Erley Alexandre Rennau³;
Samuel Tibes Pereira³; Simone Balão Taques Wendt²

¹Laboratório de Parasitologia Veterinária, Curso de Medicina Veterinária, Universidade do Contestado – UnC, Canoinhas, SC, Brasil

²Hospital Veterinário, Curso de Medicina Veterinária, Universidade do Contestado – UnC, Canoinhas, SC, Brasil

³Acadêmico Curso de Medicina Veterinária, Universidade do Contestado – UnC, Canoinhas, SC, Brasil

Received September 3, 2013

Accepted December 17, 2013

Abstract

This study reports a case of parasitism by *Diectophyme renale* in a supernumerary kidney and abdominal cavity of a female cat in Brazil. The three-year-old cat of indeterminate breed presented abdominal distension and was taken to the University of Contestado Veterinary Hospital in Canoinhas, state of Santa Catarina, since the owner suspected pregnancy. An ultrasound scan did not confirm pregnancy but revealed parasitism in the kidney. This case is worth reporting because domestic cats are rarely hosts of this nematode species.

Keywords: *Diectophyma renale*, diectophymosis, feline, parasitic disease, diagnosis.

Resumo

Relata-se um caso de parasitismo por *Diectophyme renale* em rim supranumerário e em cavidade abdominal de um gato do Brasil. Uma fêmea adulta, não castrada, sem raça definida e com aproximadamente três anos de idade, foi encaminhada ao Hospital Veterinário da Universidade do Contestado, em Canoinhas-SC, com aumento de volume abdominal e o proprietário suspeitava de gestação. Após ultrassonografia foi descartada a gestação e foi detectado parasitismo em rim. Como gatos domésticos são considerados hospedeiros incomuns desse parasita, relata-se o presente caso.

Palavra-chave: *Diectophyma renale*, diectofimose, felino, doença parasitária, diagnóstico.

Introduction

Diectophyme renale Goeze, 1782 is a nematode that occurs worldwide and that usually parasitizes the kidney and peritoneal cavity, and occasionally other organs of canids and mustelids (ANDERSON, 2000). In its life cycle, its eggs are eliminated through the urine of the definitive host and their development occurs in the environment. Animals and humans become infected with this nematode by ingesting raw or undercooked fish, while amphibians and aquatic annelids become infected with the larval form of the parasite (MACE; ANDERSON, 1975). After it is ingested, the nematode migrates directly through the stomach wall or bowel to the kidney, usually affecting the right one, probably due to its proximity to the duodenum (ANDERSON, 2000). Other sites of parasitism are the peritoneal cavity, bladder, urethra, cervix, ovary, mammary gland and stomach of dogs and other

animals (MEASURES, 2001). It is common to observe only one helminth in the host, and cases of highly concentrated infection are unusual (MONTEIRO et al., 2002).

Case Report

A 3-year-old stray female cat of indeterminate breed, weighing 2.8 kg and suspected of being in the final stage of pregnancy, was taken to the University of Contestado Veterinary Hospital in Canoinhas, state of Santa Catarina, Brazil by her owner who had found and adopted her three months earlier. The owner had noticed that the cat's abdomen was increasing in volume and that when she lay down in a lateral decubitus position, there was visible movement in the abdominal region, leading him to suspect pregnancy.

A clinical examination showed only swelling in the abdominal region. After taking the cat's medical history, the veterinarian proceeded with palpation, radiography and abdominal ultrasonography but found no evidence of pregnancy. During

*Corresponding author: Daniela Pedrassani
Laboratório de Parasitologia Veterinária, Curso de Medicina Veterinária,
Universidade do Contestado – UnC, R. Roberto Ehlke, 86, Centro,
CEP 89460-000, Canoinhas, SC, Brasil
e-mail: daniela@unc.br

the abdominal ultrasonography to analyze the renal architecture of what appeared to be the right kidney in cross section, the presence of a tubular structure comparable to the image of a *Dioctophyme renale* was observed (Figure 1). The left kidney was hypertrophied and regular contours were defined, with preserved architecture.

The owner was informed about the parasite and the need to remove the parasitized kidney. He agreed to the procedure and also authorized the elective spaying of the animal. The preoperative blood count showed leukocytosis (20,000/mm³), and the serum BUN and Creatinine were within the reference range (40mg/dL and 0.8 mg/dL, respectively). The cat was subjected to laparotomy and ovariectomy according to the technique described by Fossum (2002). The abdominal inspection revealed a bright red nematode unattached in the abdominal cavity above the duodenum. A dirty brown, odorless exudate of fibrinous character was observed in the abdominal cavity. The omentum was so closely attached to the intestines that it was difficult to disentangle them. The uterine body and horns were fragile. The ultrasound image also revealed the presence of another parasite in the right kidney, so a nephrectomy was also performed.

Death due to heart failure occurred during surgery and the owner authorized a necropsy of the animal, which revealed that it had a hypertrophied left kidney 4.4 cm long and 2.8 cm wide. According to Scholz and Luerssen (2001), the average size of the kidney in cats is 3.5 cm in length by 2.1 cm in width. A macroscopic examination of the bowel attached externally to the caecum revealed a mass of tissue with a solid consistency. When cut, the mass showed cortical and medullary tissue compatible with the kidney pelvis, with dimensions of 2.1 cm width and 3.1 cm length. The nature of this tissue was subsequently confirmed by histopathology. Inside this supernumerary kidney was another *D. renale*. The parasites were fixed in 70° alcohol and identified according to the method proposed by Anderson and Bain (1982). The cat suffered from peritonitis resulting from parasitism in the abdominal cavity, and renal parasitism in the supernumerary kidney.

Discussion and Conclusion

The loose nematode found in the cavity was identified as a female *Dioctophyme renale* measuring 43 cm in length with a maximum width of 0.52 cm. In 2009, the first case of domestic cat diotrophymosis in Brazil was confirmed. A cat necropsied in Rio de Janeiro after severe peritonitis showed parasitism in the abdominal cavity by a 24.9 cm long male *D. renale* (VEROCAI et al., 2009).

Domestic cats may include wild fish and frogs in their diet, and thus run the risk of infection with *D. renale*, especially feral cats or those allowed roaming freely (VEROCAI et al., 2009). There are reports of frog (*Chaunus ictericus*) hosting *D. renale* larvae (PEDRASSANI et al., 2009) in Brazil in the same municipality where the domestic feline reported in the present study lived.

Visual inspection indicated that the surface of the right kidney had an irregular contour. After incision, reduced kidney parenchyma and the presence of hemorrhagic exudates were observed, but no parasite was found. The supernumerary kidney contained a female *D. renale* measuring 19.5 cm in length with a maximum width of 0.34 cm (Figure 2). The fact that the animal's urea and

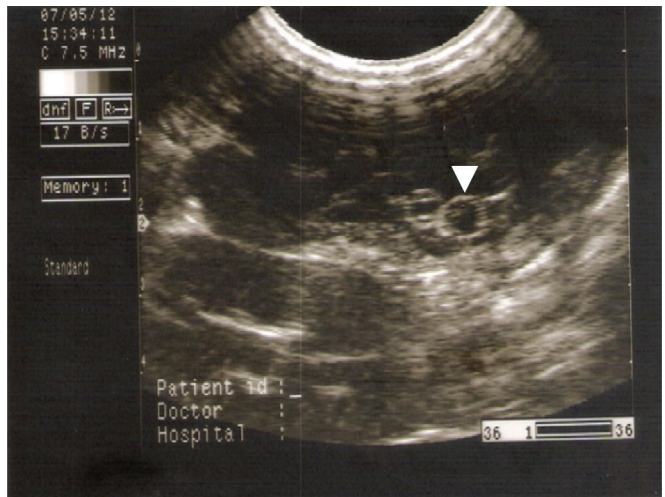


Figure 1. Ultrasound image of the feline supernumerary kidney parasitized by *D. renale* (arrow indicates cross sections of the helminth).

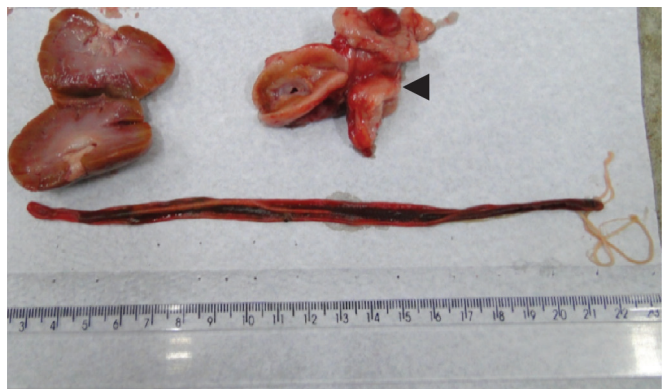


Figure 2. Right kidney (not parasitized) and supernumerary kidney (parasitized, arrow) of the female feline parasitized by a 19.5 cm long *Dioctophyme renale*.

creatinine levels had not changed was explained by the presence of three functional kidneys, although the cortical layer of the right kidney was compromised, the supernumerary kidney was parasitized, and the left kidney showed compensatory hypertrophy.

Signs of increased abdominal volume were due to ascites caused by the parasite's migration to the abdominal cavity, and according to Anderson (2000), the presence of *D. renale* females in the abdominal cavity can be followed by the presence of large numbers of eggs, which also contribute to peritonitis. According to Measures (2001), the migration of these helminths causes chronic persistent hepatitis, which affects mainly the right lobe of the liver and chronic proliferative inflammatory reactions in the peritoneum.

The diagnosis is difficult due to the non-specificity of the clinical signs, mainly in renal unilateral manifestations (KOMMERS et al., 1999). In this report, the animal presented signs of prostration. Clinical signs suggested a case of peritonitis. The hemogram revealed neutrophilia, suggesting inflammatory lesion likely due to peritonitis. For this case, ultrasonography proved to be efficient

in the auxiliary diagnosis of dioctophymosis, as demonstrated in the studies of Costa et al. (2004), Pedrassani et al. (2010) and Pereira et al. (2008).

The reason for reporting this case is the fact that dioctophymosis is uncommon in cats.

References

- Anderson RC. *Nematode parasites of vertebrates: their development and transmission*. 2nd ed. Oxon: CABI Publishing; 2000. 650 p. <http://dx.doi.org/10.1079/9780851994215.0000>
- Anderson RC, Bain O. Keys to genera of the superfamilies Rhabditoidea, Dioctophymatoidea, Trichinelloidea and Muspiceoidea, n. 9. In: Anderson RC, Chabaud AG, Willmott S. *CIH Keys to the Nematode Parasites of Vertebrates*. Wallingford: CAB International; 1982. p. 15-16.
- Costa PRS, Argolo Neto NM, Oliveira DMC, Vasconcellos RS, Menezes FS. Dioctofimose e leptospirose em um cão - Relato de caso. *Clin Vet* 2004; 51: 48-50.
- Fossum TW. *Cirurgia de Pequenos Animais*. São Paulo: Roca; 2002.
- Kommers GD, Ilha MRS, Barros CSL. Dioctofimose em cães: 16 casos. *Cienc Rural* 1999; 29(3): 517-522. <http://dx.doi.org/10.1590/S0103-84781999000300023>
- Mace TF, Anderson RC. Development of the giant kidney worm, *Dioctophyma renale* (Goeze, 1782) (Nematoda: Dioctophymatoidea). *Can J Zool* 1975; 53(11): 1552-1568. <http://dx.doi.org/10.1139/z75-190>
- Measures LN. Dioctophymatosis. In: Samuel WM, Pybus MJ, Kocan AA. *Parasitic Diseases of Wild Mammals*. 2nd ed. Iowa State University Press; 2001. p. 357-364. <http://dx.doi.org/10.1002/9780470377000.ch13>
- Monteiro SG, Sallis ESV, Stainki DR. Infecção natural por trinta e quatro helmintos da espécie *Dioctophyme renale* (Goeze, 1782) em um cão. *Revista da FZVA* 2002; 9(1): 95-99.
- Pedrassani D, Hoppe EGL, Tebaldi JH, Nascimento AA. *Chaunus ictericus* (Spix, 1824) as paratenic host of the giant kidney worm *Dioctophyme renale* (Goeze, 1782) (Nematoda: Enoplida) in São Cristóvão district, Três Barras county, Santa Catarina state, Brazil. *Vet Parasitol* 2009; 165(1-2): 74-77. <http://dx.doi.org/10.1016/j.vetpar.2009.07.017>
- Pedrassani D, Wendt SBT, Pilati C, Machado RZ, Nascimento AA. Diagnóstico ultrassonográfico de infecção intensa por *Dioctophyme renale* em rim esquerdo de cão - relato de caso. *Clin Vet* 2010; 85: 74-80.
- Pereira BJ, Holanda C, Oliveira DC, Lopes BF, Costa FS. Diagnóstico ultrassonográfico de dioctofimose em cão - relato de caso. *PUBVET* 2008; 2(47).
- Scholz S, Luerssen D. Spleen. In: Natrup CP, Tobias R, Cartee RE. *An Atlas and Textbook of Diagnostic Ultrasonography of the Dog and Cat*. London: Manson Publishing; 2001.
- Verocai GG, Measures LN, Azevedo FD, Correia TR, Fernandes JI, Scott FB. *Dioctophyme renale* (Goeze, 1782) in the abdominal cavity of a domestic cat from Brazil. *Vet Parasitol* 2009; 161(3-4): 342-344. <http://dx.doi.org/10.1016/j.vetpar.2009.01.032>