

Detection of *Toxoplasma gondii* in the reproductive system of male goats

Detecção de *Toxoplasma gondii* no sistema reprodutor de caprinos machos

Luís Fernando Santana^{1*}; Alvimar José da Costa¹; Juliana Pieroni¹; Welber Daniel Zanetti Lopes¹; Ricardo Silva Santos¹; Gilson Pereira de Oliveira¹; Rafael Paranhos de Mendonça¹; Cláudio Alessandro Massamitsu Sakamoto¹

¹Departamento de Patologia Veterinária, Centro de Pesquisas em Sanidade Animal, Universidade Estadual Paulista – UNESP

Received May 11, 2010

Accepted July 12, 2010

Abstract

Male goats of mating age serologically negative for *Toxoplasma gondii* were divided into three groups: GI – controls (placebo) (n = 2); GII – infected with 1×10^6 tachyzoites (RH strains) (n = 2); and GIII – infected with 2×10^5 oocysts (P strains) (n = 2). Clinical, hematology, parasite and serology tests and studies of parasites in the semen through bioassay and polymerase chain reaction (PCR), and in reproductive organs (bioassay) were performed to assess toxoplasma infection. Serological titers peaked at 4096 in two animal groups infected with the protozoan. The bioassays allowed an early detection of protozoa in semen samples of tachyzoite-inoculated animals. *T. gondii* DNA was identified through PCR in the semen in five (Days 5, 7, 28, 49, and 70) and two (both at day 56) different days post-inoculation in GII and GIII animals, respectively. It was also possible to detect *T. gondii* DNA in reproductive organs (prostate pool, testicles, seminal vesicle and epididymis) of goats inoculated with either tachyzoites or oocysts. The present study suggests the possibility of venereal transmission of *T. gondii* among goats and it should be further assessed.

Keywords: *Toxoplasma gondii*, goats, reproductive systems, PCR and bioassay.

Resumo

Caprinos machos, em idade reprodutiva, sorologicamente negativos para *Toxoplasma gondii* foram distribuídos em três grupos de animais: GI (n = 2) controle (placebo), GII (n = 2) - infectado com 1×10^6 taquizoítos (cepa RH) e GIII (n = 2) infectado com 2×10^5 oocistos (cepa P). Exames clínicos, hematológicos, parasitêmicos, sorológicos, pesquisa no sêmen e em tecidos do sistema reprodutor, por meio da bioprova, e da Reação em Cadeia pela Polimerase (PCR), foram conduzidas para avaliar a infecção toxoplásmica. Os títulos sorológicos alcançaram valores máximos de 4096 nos dois grupos de animais infectados. Pela técnica da bioprova, foi possível revelar precocemente a presença do coccídio nas amostras seminais dos animais inoculados com taquizoítos. Pela PCR, foi possível identificar, no sêmen, material genético de *T. gondii*, em cinco (5º, 7º, 28º, 49º e 70º) e em duas (ambos ao 56º) datas experimentais pós-inoculação dos animais pertencentes aos grupos GII e GIII, respectivamente. Por esta mesma técnica, foi possível ainda isolar material genético deste protozoário, também em amostras teciduais (pool de próstata, testículo, vesícula seminal e epidídimo) dos caprinos inoculados com taquizoítos e oocistos. A presente pesquisa sugere a possibilidade da ocorrência da transmissão sexual do *T. gondii* na espécie caprina.

Palavras-chave: *Toxoplasma gondii*, caprinos, sistema reprodutor, PCR e bioprova.

Introduction

Toxoplasma gondii is the causative agent of toxoplasmosis, a cosmopolitan zoonosis of medical and veterinary relevance leading to miscarriage and a congenital disorder in intermediary hosts (TENTER et al., 2000; MASSALA et al., 2003).

Brazil has a goat herd of over 13 million animals but little is known about the effects of toxoplasmosis among goats. Munday and Mason (1979) were the first to describe toxoplasmosis as an important cause of reproductive losses in goats. Although often unnoticed, this infection can cause significant damage in both young and adult animals (DUBEY, 1987). The main route of infection is ingestion of the parasite's sporulated oocysts present in the environment (DUBEY; BEVERLEY, 1988). Risk factors for *T. gondii* infection in goats include age, number of cats in the farm, and either no use of feeding troughs or use of wooden feeding troughs (CAVALCANTE et al., 2008).

*Corresponding author: Luís Fernando Santana

Departamento de Patologia Veterinária, Centro de Pesquisas em Sanidade Animal, Universidade Estadual Paulista – UNESP, Via de acesso Prof. Paulo Donatto Castellani, s/n, CEP 14884-900, Jaboticabal - SP, Brazil;
 e-mail: lfsantana_2000@yahoo.com.br

The objective of this study was to detect the presence of *T. gondii* in semen samples of experimentally infected goats using bioassay as well as molecular and histopathology techniques.

Material and Methods

1. Experimental infection of goats with *T. gondii*

This study used "P" (JAMRA; VIEIRA 1991) and "RH" (SABIN, 1941) *T. gondii* strains kept at the Animal Health Research Center (CPPAR), School of Agrarian and Veterinary Sciences, Universidade Estadual de São Paulo, Jaboticabal campus, São Paulo, Brazil. "P" strains were genotypically characterized by using PCR-RFLP segment of locus SAG2 located in chromosome VIII as a genetic marker and classified as Type III. (BRESCIANI et al., 2009). "RH" strains were previously characterized as Type I by using the same analysis of loci SAG1, SAG2, new SAG2, SAG3, BTUB, GRA6, c22-8, c29-2, L358, PK1 and Apico (PENA et al., 2008; HERRMANN et al., 2010).

Six male goats of undefined breed serologically negative for *T. gondii* aged between one and two years were selected. Serology titers obtained by indirect immunofluorescence (IFI) were considered positive starting at a 1:16 dilution. The animals were identified, sorted and randomized into three groups: GI – non-inoculated controls (n = 2); GII – subcutaneously infected with 1×10^6 RH strain tachyzoites per animal (n = 2); and GIII – orally infected with 2×10^5 P strain oocysts per animal (n = 2).

All goats were kept in proper individual stalls with water and food ad libitum. Serological tests were carried out during the experimental period as follows: acidified buffered antigen test (ALTON et al., 1988) for brucellosis; and microscopic agglutination test (COLE et al., 1973) for leptospirosis.

2. Clinical, hematology, serology and semen follow-up

The study animals were clinically evaluated (respiratory and heart frequency and rectal temperature) two days before inoculation and on Days 3, 5, 7, 11, 14, 21, 28, 35, 42, 49, 56, 63 and 70 post-inoculation (PI). Parasitemia was assessed using white mice according to Costa et al. (1977). Sera from blood samples collected two days before inoculation and on Days 3, 5, 7, 11 and 14 PI and then weekly until the end of the experiment from all experimentally infected goats were tested for *T. gondii* antibodies* using IFI (CAMARGO, 1964). For nearly two months, all animals were submitted to semen collection with an electroejaculator. Ejaculate samples were obtained two days before inoculation and on Days 3, 5, 7, 11 and 14 PI and then weekly until the end of the experiment. *T. gondii* presence was assessed by bioassays in mice (DUBEY; SHARMA, 1980) and positive samples were tested through PCR.

3. Molecular detection of *T. gondii* DNA

The methods as proposed by Fuentes et al. (1996) were used for semen and tissue sample standardization. RH strain *T. gondii* tachyzoites were counted on a modified Neubauer chamber in dark field microscopy (400×) with at a concentration of 10^{10} parasites.mL⁻¹. From this first dilution, 500 µL were diluted in 9.5 mL of sterile saline solution (SST), and dilutions of 10^9 , 10^8 , 10^7 , 10^6 , 10^5 , 10^4 , 10^3 , 10^2 , 10^1 and 10^0 parasites.mL⁻¹ of the sample were successively obtained. Dilutions were adjusted in 700 µL volume aliquots and DNA extracted from each sample. *T. gondii* DNA of the scales of dilution (positive control) and from semen samples for DNA detection were extracted according to the modified method as described by Teale et al. (1982). At the end of the experiment, goats were euthanized** and specimens from testes, seminal vesicles, epididymides and prostates were collected for histopathology tests and for *T. gondii* isolation by bioassay (DUBEY, 1980).

Results and Discussion

Following inoculation with *T. gondii* tachyzoites or oocysts, toxoplasma infection of goats was confirmed by parasitemia as well as seroconversion of the inoculated animals. Hyperthermia (40.65 °C) on Day 5 PI was the most remarkable clinical sign seen in the group of animals inoculated with oocysts (Figure 1). Likewise, Nishi et al. (2001) reported that temperature increase is one of the most evident clinical signs in goats orally inoculated with 10^5 oocysts of *T. gondii*. Additionally, anorexia and lethargy were seen from Day 3 to 7 PI in all inoculated animals.

Thirteen parasitemic outbreaks were detected during the experimental period: one on Days 11, 21, 28, 49, 63, two on Day 56 and 70 and four on Day 14 PI. Parasitemic outbreaks during acute stage of disease have been described from Day 7 to 14 (CHHABRA et al., 1982) and Day 5 to 12 PI (NISHI et al., 2001).

Toxoplasma infection elicited a fast immune response in goats with antibody anti-IgG detection by IFI from Day 11 PI. An early humoral response was also detected by Nishi et al. (2001) on Day 10 PI, demonstrated through IFI (anti-IgG) test.

IgG detection started on Day 11 PI in both tachyzoite-inoculated goats (titers of 256 and 1024) and one oocyst-inoculated goat (256). The peak titer (4096) was detected on Days 21 and 28 PI in all animals of GI and GII, respectively. IgG titer decreased from Day 35 PI on, but remained high (1024) in all inoculated animals until the end of the experiment.

These results are partially inconsistent with that reported by Nishi et al. (2001) who detected serological titer peaks (IFI) at a later stage (after Day 35 PI) in goats infected with a different dose and strain of *T. gondii* (10^5 oocysts and AS 28 strain). Corroborating our findings, these authors found that serological titers remained at relatively high levels until Day 56 PI. Persistently high serological (IgG) levels until Day 70 PI found in the present

* Monoclonal anti-goat/sheep IgG-FITC antibody produced in mouse – GT-34- purified immunoglobulin, buffered aqueous solution (Sigma).

** Procedures approved by the Animal Welfare and Ethics Commission (protocol number 010850-08) of School of Agrarian and Veterinary Sciences, Universidade Estadual de São Paulo (FCAV/UNESP), Jaboticabal campus, São Paulo, Brazil.

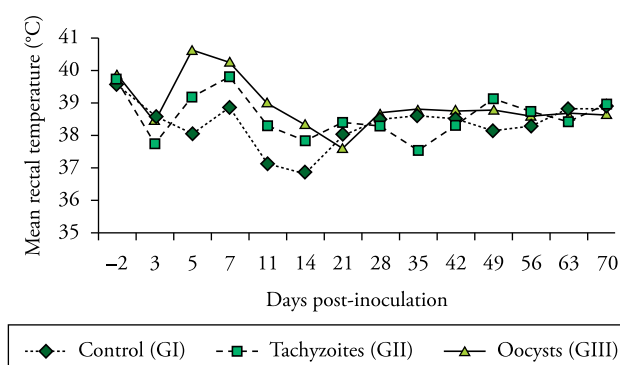


Figure 1. Mean rectal temperature in experimental goats from non-inoculated animals (controls) and inoculated animals with 1×10^6 tachyzoites and 2×10^5 oocysts of *T. gondii*.

study can be explained by the fact that in chronic infections IgG antibodies can remain “active” for a long time compared to IgM immunoglobulins, notably identified only a few weeks after infection, as described in Dubey and Towle (1986).

Dubey and Sharma (1980) used a bioassay in mice to demonstrate the presence of *T. gondii* in the semen of three goats orally inoculated with 10^4 oocysts of GT-1 strain (isolated from goats). Protozoa were detected on Day 7 PI in semen samples from two animals and from Day 12 PI on in the third animal studied. In semen samples of these animals it was possible to identify parasite excretion on Day 59 PI. Despite differences between strains studied, in this study the protozoan was detected on Days 56 PI in semen samples from oocyst-inoculated animals.

Molecular detection of *T. gondii* DNA in semen samples from tachyzoite-infected animals in more experimental days (Days 5, 7, 28, 49 and 70) is similar to that found by Dubey and Sharma (1980). This technique also allowed to detecting *T. gondii* DNA in samples from two sporulated oocysts-infected animals on Day 56 DPI.

Bioassay-positive semen samples from animal 1 on Day 63 PI, animal 11 on Days 28 and 63 PI, and animal 47 on Day 70 PI were not PCR-positive for *T. gondii* (Figure 2). PCR results supported bioassay findings and confirmed that it is a useful ancillary tool for toxoplasma infection diagnosis in semen samples.

In contrast to Pescador et al. results (2007), histopathology tests did not identify any significant change related to *T. gondii* parasitism on tissues of the reproductive system. These authors, when evaluating tissues from goat miscarriage, found significant microscopic and macroscopic alterations like enlarged pale mesenteric lymph nodes with lymphoplasma cells infiltrate in brain and lungs.

Nishi et al. (2001) successfully isolated through bioassay *T. gondii* from brain tissue, lymph nodes, liver, kidneys, skeletal and cardiac muscles but they did not find any macroscopic lesions in these tissues. Similar findings were reported by Cavalcante et al. (2007) regarding protozoan isolation in skeletal muscle samples from goats slaughtered in the State of Ceará, Brazil.

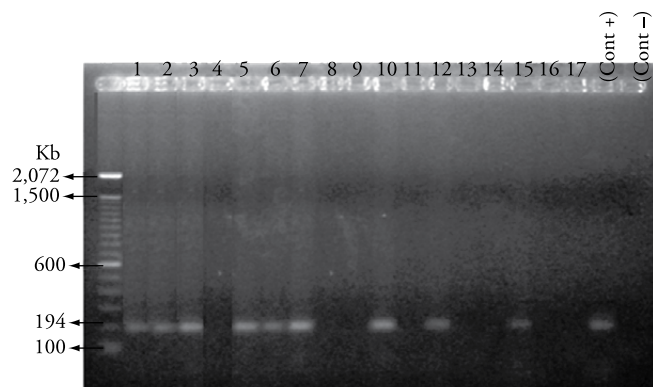


Figure 2. 2% agarose gel electrophoresis of polymerase chain reaction product from semen samples (1 to 11) and a tissue sample pool of goats euthanized after 70DPI (testes, seminal vesicle, prostate and epididymis – samples 12 to 17) of experimentally infected goat. 1) Day 5 PI (goat 1 semen); 2) Day 7 PI (goat 1 semen); 3) Day 28 PI (goat 1 semen); 4) Day 28 PI (goat 11 semen); 5) Day 49 PI (goat 1 semen); 6) Day 56 PI (goat 36 semen); 7) Day 56 PI (goat 47 semen); 8) Day 63 PI (goat 1 semen); 9) Day 63 PI (goat 11 semen); 10) Day 70 PI (goat 1 semen); 11) Day 70 PI (goat 47 semen); 12) goat 36 (oocyst inoculated); 13) goat 47 (oocyst inoculated); 14) goat 1 (tachyzoite inoculated); 15) goat 11 (tachyzoite inoculated); 16) goat 32 (control); 17) goat 41 (control).

Conclusion

T. gondii was isolated from semen samples of experimentally infected goats associated to tissue parasitism in specimens of the reproductive system diagnosed by bioassay and PCR techniques, suggesting the possibility of venereal transmission of this coccidium in goats.

Acknowledgements

This research study was partially supported by Fundação de Amparo à Pesquisa do Estado de São Paulo (FAPESP) (04/12296-2) and Centro de Pesquisa em Sanidade Animal (CPPAR), Faculdade de Ciências Agrárias e Veterinárias, UNESP-Jaboticabal, SP, Brazil.

References

- ALTON, G. G. et al. **Techniques for the brucellosis laboratory**. Paris: Institute National de la Recherche Agronomique, 1988. 190 p.
- BRESCIANI, K. D. S. et al. Transplacental transmission of *Toxoplasma gondii* in reinfected pregnant female canines. **Parasitology Research**, v. 104, n. 5, p. 1213-1217, 2009.
- CAMARGO, M. E. Improved technique of indirect immunofluorescence for serological diagnosis of toxoplasmosis. **Revista do Instituto de Medicina Tropical de São Paulo**, v. 6, n. 3, p. 117-118, 1964.
- CAVALCANTE, A. C. R. et al. Risk factors for infection by *Toxoplasma gondii* in herds of goats in Ceará, Brazil. **Arquivo Brasileiro de Medicina Veterinária e Zootecnia**, v. 60, n. 1, p. 36-41, 2008.

- CAVALCANTE, A. C. R. et al. Virulence and molecular characterization of *Toxoplasma gondii* isolated from goats in Ceará, Brazil. **Small Ruminant Research**, v. 69, n. 1-3, p. 79-82, 2007.
- CHHABRA, M. B. et al. Experimental toxoplasmosis in pregnant goats. **Indian Journal of Animal Sciences**, v. 52, p. 661-664, 1982.
- COLE, J. R.; SULZER, C. R.; PULSSELY, P. R. Improved microtechnique for the leptospiral microscopic agglutination test. **Applied Microbiology**, v. 25, n. 6, p. 976-980, 1973.
- COSTA, A. J. et al. Experimental infection of bovines with oocysts of *Toxoplasma gondii*. **Journal of Parasitology**, v. 63, n. 2, p. 212-218, 1977.
- DUBEY, J. P. Mouse pathogenicity of *Toxoplasma gondii* isolated from a goat. **American Journal of Veterinary Research**, v. 41, n. 3, p. 427-429, 1980.
- DUBEY, J. P. Toxoplasmosis in goats. **Agri-practice**, v. 8, p. 43-52, 1987.
- DUBEY, J. P.; BEVERLEY, J. K. A. **Toxoplasmosis of animals and man**. Boca Ráton: Boca Ráton Academic, 1988. 315 p.
- DUBEY, J. P.; SHARMA, S. P. Prolonged excretion of *Toxoplasma gondii* in semen of goats. **American Journal of Veterinary Research**, v. 41, n. 5, p. 794-795, 1980.
- DUBEY, J. P.; TOWLE, A. **Toxoplasmosis in sheep**. St. Albans: Common Wealt. Institute of Parasitology, 1986.
- FUENTES, I. et al. Urine sample used for congenital toxoplasmosis diagnosis by PCR. **Journal of Clinical Microbiology**, v. 34, n. 10, p. 2368-2371, 1996.
- HERRMANN, D. C. et al. Atypical *Toxoplasma gondii* genotypes identified in oocysts shed by cats in Germany. **International Journal for Parasitology**, v. 40, n. 3, p. 285-292, 2010.
- JAMRA, L. M. F.; VIEIRA, M. P. L. Isolamento do *Toxoplasma gondii* de exsudato peritoneal e órgãos de camundongos com infecção experimental. **Revista do Instituto de Medicina Tropical de São Paulo**, v. 33, n. 6, p. 435-441, 1991.
- MASSALA, G. et al. Survey of ovine and caprine toxoplasmosis by IFAT and PCR assays in Sardinia, Italy. **Veterinary Parasitology**, v. 117, n. 1-2, p. 15-21, 2003.
- MUNDAY, B. L.; MASON, R. W. Toxoplasmosis as a cause of perinatal death in goats. **Australian Veterinary Journal**, v. 55, n. 10, p. 485-487, 1979.
- NISHI, S. M.; KASAI, N.; GENNARI, S. M. Antibody levels in goats fed *Toxoplasma gondii* oocysts. **Journal of Parasitology**, v. 87, n. 2, p. 445-447, 2001.
- PENA, H. F. J. et al. Population structure and mouse-virulence of *Toxoplasma gondii* in Brazil. **International Journal for Parasitology**, v. 38, n. 5, p. 561-569, 2008.
- PESCADOR, C. A. et al. Perdas reprodutivas associadas com infecção por *Toxoplasma gondii* em caprinos no sul do Brasil. **Pesquisa Veterinária Brasileira**, v. 27, n. 4, p. 167-171, 2007.
- SABIN, A. B. Toxoplasmic encephalitis in children. **The Journal Of the American Medical Association**, v. 116, n. 9, p. 801-807, 1941
- TEALE, A. J. et al. Experimentally induced toxoplasmosis in young rams: the clinical syndrome and semen secretion of *Toxoplasma*. **The Veterinary Record**, v. 111, n. 3, p. 53-55, 1982.
- TENTER, A. M.; HECKEROTH, A. R.; WEISS, L. M. *Toxoplasma gondii*: from animals to humans. **International Journal for Parasitology**, v. 30, n. 12-13, p. 1217-1258, 2000.