

Parasitism of the nasal mite *Sternostoma tracheacolum* Lawrence, 1948 (Mesostigmata: Rhinonyssidae) in captive birds in Brazil

Parasitismo do ácaro nasal *Sternostoma tracheacolum* Lawrence, 1948 (Mesostigmata: Rhinonyssidae) em aves de cativeiro no Brasil

Ricardo Bassini-Silva¹ ; Fernando de Castro Jacinavicius^{1,2} ; Josivania Soares Pereira³ ; Karin Werther⁴ ; Greg Sherwood Spicer⁵ ; Darci Moraes Barros-Battesti^{1,4*} 

¹ Departamento de Medicina Veterinária Preventiva e Saúde Animal, Faculdade de Medicina Veterinária e Zootecnia – FMVZ, Universidade de São Paulo – USP, São Paulo, SP, Brasil

² Laboratório Especial de Coleções Zoológicas, Instituto Butantan, São Paulo, SP, Brasil

³ Laboratório de Parasitologia Animal, Departamento de Biociências, Centro de Ciências Biológicas e da Saúde, Universidade Federal Rural do Semi-Árido – UFERSA, Mossoró, RN, Brasil

⁴ Departamento de Patologia Veterinária, Faculdade de Ciências Agrárias e Veterinárias, Universidade Estadual Paulista – UNESP, Jaboticabal, SP, Brasil

⁵ Department of Biology, San Francisco State University, San Francisco, CA, USA

Received March 18, 2019

Accepted June 5, 2019

Abstract

Nasal mites (Mesostigmata: Rhinonyssidae) are obligatory endoparasites of birds, and the resulting parasitism can be harmful to the host's respiratory system. The nasal mite *Sternostoma tracheacolum* Lawrence has caused significant respiratory issues, including serious injuries that possibly cause death of the host. In this study, we report two cases of captive birds parasitized by *S. tracheacolum*. The first case is a histopathological description of *S. tracheacolum* parasitizing the Gouldian Finch (*Chloebia gouldiae*) in the southeast region of Brazil, that showed partially or totally absence of the characteristic respiratory epithelium in trachea lumen. The other describes, for the first time, the parasitism of this species in a canary (*Serinus canaria*) in the northeast region of the country.

Keywords: *Sternostoma tracheacolum*, endoparasite, *Chloebia gouldiae*, *Serinus canaria*.

Resumo

Os ácaros nasais (Mesostigmata: Rhinonyssidae) são endoparasitos obrigatórios das aves, e este parasitismo pode ser prejudicial ao sistema respiratório de seu hospedeiro. A espécie de ácaro nasal *Sternostoma tracheacolum* Lawrence tem causado importantes problemas respiratórios, incluindo lesões graves que possivelmente causam a morte do hospedeiro. Neste estudo, relatamos dois casos de aves em cativeiro parasitadas por *S. tracheacolum*. O primeiro caso é uma descrição histopatológica de *S. tracheacolum* parasitando um Diamante-de-gould (*Chloebia gouldiae*) na região sudeste do Brasil, mostrando parcial ou total ausência do epitélio respiratório característico do lúmen da traquéia. O outro descreve, pela primeira vez, o parasitismo desta espécie em um canário (*Serinus canaria*) na região nordeste do país.

Palavras-chave: *Sternostoma tracheacolum*, endoparasita, *Chloebia gouldiae*, *Serinus canaria*.

Introduction

Mites of the family Rhinonyssidae Trouessart, 1895, popularly known as nasal mites, are obligatory endoparasites of birds that specifically target the respiratory system (PENCE, 1975). This

family is organized in eight genera, about 500 species, and has been described around the world (DOMROW, 1969; PENCE, 1975; BEAULIEU et al., 2011). Six genera have already been reported in Brazil, *Larinyssus* Strandtmann, 1948, *Ptilonyssus* Berlese & Trouessart, 1889, *Rhinoecius* Cooreman, 1946, *Rhinonyssus* Trouessart, 1894, *Sternostoma* Berlese & Trouessart, 1889 and *Tinaminyssus* Strandtmann & Wharton, 1958. Of these, *Sternostoma* has sixteen

*Corresponding author: Darci Moraes Barros-Battesti. Departamento de Patologia Veterinária, Faculdade de Ciências Agrárias e Veterinárias – UNESP, R. Castellane, s/n, Via de Acesso Professor Paulo Donato Castellane, Vila Industrial, CEP 14884-900, Jaboticabal, SP, Brasil. e-mail: barros.battesti@gmail.com



species recorded parasitizing birds of the order Apodiformes, Charadriiformes, Passeriformes, Psittaciformes and Strigiformes, across the Brazilian territory, except for the northeast region (CASTRO, 1948; FAIN & BASTIN, 1959; AMARAL, 1962; 1968; FAIN & AITKEN, 1968, 1969, 1971; AMARAL & REBOUÇAS, 1974a; MASCARENHAS et al., 2011; MENDES et al., 2014; BERNARDON et al., 2017; MASCARENHAS et al., 2018; SILVA et al., 2018; SANTOS et al., 2018).

Sternostoma tracheacolum Lawrence, 1948 is spread worldwide and has been recorded in both captive and wild birds. This species resides throughout the respiratory system, ranging from the trachea to the air sacs, and is known to cause complications (MURRAY, 1966; BELL, 1996). In general, the clinical signs on the hosts are dyspnea, coughing, sneezing, and in severe infestations the host may die from asphyxiation (BYGRAVE, 1980; DIMOV, 2011).

In Brazil, *S. tracheacolum* was found parasitizing captive birds, as *Serinus canaria* (Passeriformes: Fringillidae) in Rio Grande do Sul state (FAIN & HYLAND, 1962; GUIMARÃES et al., 2012), Rio de Janeiro state (TORRES et al., 1951; AMARAL, 1962) and São Paulo state (AMARAL, 1968; AMARAL & REBOUÇAS, 1974a), and *Melospittacus undulatus* (Psittaciformes: Psittacidae) in Rio de Janeiro state (AMARAL, 1968). This mite species was also recorded parasitizing wild birds, as *Cyanerpes cyaneus* (Passeriformes: Thraupidae), without specific locality (FAIN & HYLAND, 1962), *Molothrus bonariensis* (Passeriformes: Icteridae) in Rio Grande do Sul state (AMARAL, 1968), *Dendrocicla merula* (Passeriformes: Furnariidae) and *Rhynchocyclus olivaceus* (Passeriformes: Tyrannidae) in Pará state (FAIN & AITKEN, 1971) and *Passer domesticus* (Passeriformes: Passeridae) in Rio Grande do Sul state (SANTOS et al., 2018).

The objectives of the present study are: to describe a parasitism and characterize the histopathological lesions of *S. tracheacolum* on a Gouldian Finch (*Chloebia gouldiae*) bird in the southeast region of Brazil; and to document parasitism of the same nasal mite on a canary (*S. canaria*), but in the northeast region of the country.

Materials and Methods

Morphological identification

Fifteen mite specimens were collected parasitizing the respiratory system of one *C. gouldiae* (Passeriformes: Estrildidae) found in the Ibitinga city, in the state of São Paulo, Brazil. Another ten specimens were collected parasitizing *S. canaria*, from the Mossoró city, in the state of Rio Grande do Norte, Brazil. Both birds were domestic. All the collected materials were initially preserved and stored in 100% alcohol. Later, selected materials were slide-mounted in Hoyer's medium and prepared for scanning electron microscopy (SEM) for identification, both processes according to Walter & Krantz (2009). All the material was deposited in the Acari Collection of the Instituto Butantan (IBSP), São Paulo state, Brazil. The SEM micrographs were obtained using a Digital Scanning Microscope FEI, Quanta 250, located at the Laboratório de Biologia Celular, Instituto Butantan, São Paulo state, Brazil. The figures were prepared with Adobe Photoshop v. 13.0. The specimens were identified, up to genus and species, using the keys proposed by Pence (1975).

Histopathological analysis

The trachea and lungs of the *C. gouldiae* were collected during necropsy, and the tissues were fixed in 10% buffered formalin for 24 hours. The samples were through to routine processes of dehydration in growing alcohol battery, diaphanized in xylol and paraffinized. Soon after, the materials were embedded in paraffin, cut into portions measuring 4 micrometers each, and placed individually on slides. Then, the samples were deparaffinized in xylol, rehydrated in an alcohol battery, stained with hematoxylin and eosin, and mounted with coverslips (SLAOUI et al., 2017). No material was obtained for histological sections of the host *S. canaria*.

Results

The mites were identified as *S. tracheacolum* and the specimens were deposited in the IBSP collection. These nasal mites can be identified by the following characteristics: opisthosomal shield with six setae, stigma without peritremes, gnathosoma partially ventral, sternal shield with three setae, and anal shield terminal (Figure 1).

The parasitism of the *S. tracheacolum* was only found during necropsy in the trachea of *C. gouldiae*, since it had no clinical signs in the respiratory system. According to the owner of the Gouldian Finch, before death, the bird had brownish diarrhea and dirty feathers around the cloaca, but there was no breathing difficulty. A histopathological examination was carried out in the respiratory and digestive systems to know the actual cause of death of this bird. In the histopathological of the region of the trachea and lungs of *C. gouldiae* it is possible to observe the presence of the mites in the lumen. Also, we can observe partially or totally absence of the characteristic respiratory epithelium in trachea lumen. In the lumen of primary bronchi parasitized by *S. tracheacolum* the parenchyma presented congested blood vessels (Figure 2). No inflammatory cells were associated with the local of the parasites. However, the birds showed relevant alterations at intestines, pancreas and liver. According to the report of the bird, the intestine had loss of villi; inflammatory infiltrate in the submucosa, indicating enteritis, the pancreas already had signs of multifocal degeneration/necrosis with karyolysis, whereas the liver had a cytoplasmic degeneration with moderate vacuolization (steatosis), and limited hepatocyte delimitation indicating that the organ was degenerating. The most obvious change was enteritis (inflammation of the intestine) that would directly compromise the digestion and feeding of the animal, as seen by the droplets of fat in the faces, which may be responsible for the death, confirming what the bird owner reported. Differently from the canary's case, since this bird, before death, already had shown signs of labored breathing, characterized by acute dyspnea. Possibly, it died as a consequence of the parasitism of these nasal mites, only detected after necropsy.

Material examined. 15 ♀ (IBSP 13772), Ibitinga municipality, São Paulo state, V-2018, *Chloebia gouldiae* (Passeriformes: Estrildidae), Werther K. coll.; 10 ♀ (IBSP 13379), Mossoró municipality, Rio Grande do Norte state, Brazil, 03-VII-2017, *Serinus canaria* (Passeriformes: Fringillidae), Soares J. P. coll.




Figure 1. Morphological details of *Sternostoma tracheacolum*. (A) dorsal view of the podosoma; (B) anterior view of the podosoma shield; (C) ventral view of the idiosoma; (D) gnathosoma subcapitular; (E) sternal shield; (F) genital shield. Scales: A 100 μ m; B, D-F 50 μ m; C 200 μ m.

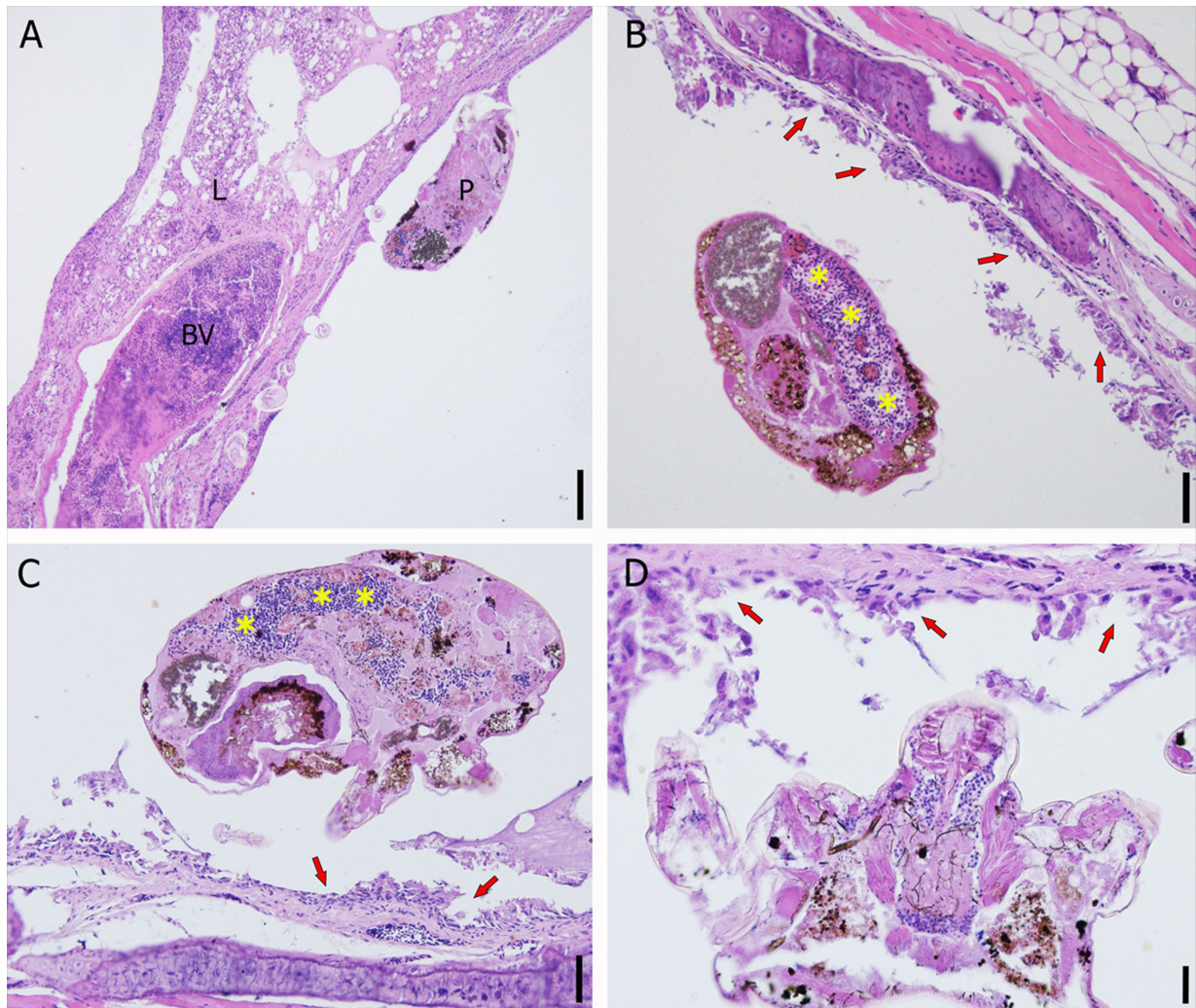


Figure 2. Histopathological images. (A) histopathological aspect of the lungs (L) of *Chloebia gouldiae* parasitized by *Sternostoma tracheacolum*. The nasal mite (P) are in the lumen of primary bronchi and the blood vessel (BV) are congest in the parenchyma; (B-D) histopathological aspect of the trachea of *Chloebia gouldiae* parasitized by *Sternostoma tracheacolum*. In the figures B, C and D, the red arrows show the partial absence of typical respiratory epithelium and in the figures B and C the “*” the presence of avian nucleated erythrocytes from the host; All images in HE stains. Scales: A 100 μ m; B and C 50 μ m; D 20 μ m.

Discussion

In general, an infestation of the species *S. tracheacolum* in the host is diagnosed late, because of the difficulty of detecting the mites. This is only possible, after the death of the hosts, through necropsy (AMARAL & REBOUÇAS, 1974b), as well as, in this study with the species *C. gouldiae*, but this does not mean that the nasal mites were the direct cause of death of the bird.

Tidemann et al. (1992) observed areas of bronchial dilatation with detritus, macrophages and lymphocytes in the lumen. In fact, in the present study, these kinds of cells are not indicated but the mite infestation caused partial absence of typical respiratory epithelium of the *C. gouldiae*. On the other hand, although a histopathological examination was not performed, there were clinical signs in *S. canaria* that corroborated with that observed by Tidemann et al. (1992).

Some authors have quoted that wild birds better survive the infestation of *S. tracheacolum* than captive birds, so the wild birds are probably the natural hosts of this mite (FAIN & HYLAND, 1962; RIFFKIN & MCCAUSLAND, 1972). Besides that, the immune system of captive birds is affected by the captivity, thus causing a greater susceptibility to infestation in these birds (FAIN & HYLAND, 1962; GUIMARÃES et al., 2012). In fact, the competence of the bird immune system is also strongly influenced by inadequate nutrition for species, breeding health problems, high numbers of birds (overpopulation) and lack of quarantine and periodic examinations. As Dimov (2011) reported in his case report, in this study the *S. canaria* also presented labored respiration, characterized by acute dyspnea.

Also, Tidemann et al. (1992) demonstrated that this nasal mite may also influence in the development of Gouldian Finch populations in Australia, and Murray (1966) had already highlighted the susceptibility of this bird to the infestation by this mite. Thus,

it is necessary to report the presence of this mite in captive birds, even if they do not present clinical signs of parasitism, since there are reports of the succession of these birds and possible injuries resulting from parasitism.

Besides that, there are several records of canaries being parasitized by *S. tracheacolum* in some states of Brazil, such as Pará, Rio de Janeiro, Rio Grande do Sul and São Paulo (AMARAL, 1962, 1968; AMARAL & REBOUÇAS, 1974a; GUIMARÃES et al., 2012). Except for the most recent study, the others are only taxonomic papers.

Here, we report the parasitism of *S. tracheacolum* in Gouldian Finch, for the first time in Brazil. We are also reporting this species parasitizing a canary in the northeast region of the country.

Acknowledgements

To Gabrielle Ribeiro de Andrade and Maria Cristina Ferreira do Rosário for technical contribution (CNPq no. 377343/2015-3 and 377342/2015-7, respectively). To Beatriz Mauricio of the Laboratory of Cellular Biology of the Butantan Institute for the images obtained through the Scanning Electron Microscopy. This work was supported by the Conselho Nacional de Desenvolvimento Científico e Tecnológico (CNPq no. 454907/2014-1 and 440639/2015-8 to DMB-B, 377976/2014-8 to FCJ), Fundação de Amparo à Pesquisa do Estado de São Paulo (FAPESP no. 2010/51875-9 to DMB-B and 2017/01416-7 to RB-S). This study was financed in part by the Coordenação de Aperfeiçoamento de Pessoal de Nível Superior - Brasil (CAPES) - Finance Code 001.

References

- Amaral V, Rebouças MM. Notas sobre ácaros rinonissídeos de aves brasileiras (Mesostigmata - Rhinonyssidae). *Biologico* 1974a; 40: 52-56.
- Amaral V, Rebouças MM. *Métodos para o estudo de ácaros rinonissídeos*. São Paulo: Instituto Biológico de São Paulo; 1974b. 31 p.
- Amaral V. Notas sobre ácaros nasais com a descrição de duas novas espécies: *Ptilonyssus zeferinoi* n. sp. e *Sternostoma clementei* n. sp. (Acarina: Rhinonyssidae). Lista das espécies descritas no Brasil e seus hospedeiros. *Arq Inst Biol (Sao Paulo)* 1968; 35(3): 107-126.
- Amaral V. *Sternostoma augei* n.sp. (Acarina: Rhinonyssidae Vitz., 1935) e identificação das espécies *Rhinoecius bisetosus* Strandtmann, 1952 e *Rhinoecius grandis* Strandtmann, 1952. *Arq Inst Biol (Sao Paulo)* 1962; 29: 69-81.
- Beaulieu F, Dowling APG, Klompen H, Moraes GJ, Walter DE. Superorder Parasitiformes Reuter, 1909. In: Zhang ZQ, editor. *Animal biodiversity: an outline of higher-level classification and survey of taxonomic richness*. Auckland: Magnolia Press; 2011. p. 123-128. (Monograph Zootaxa; vol. 3148).
- Bell PJ. The life history and transmission biology of *Sternostoma tracheacolum* Lawrence (Acari: Rhinonyssidae) associated with the Gouldian finch *Erythrura gouldiae*. *Exp Appl Acarol* 1996; 20(6): 323-341. <http://dx.doi.org/10.1007/BF00052962>.
- Bernardon FF, Müller G, Mascarenhas CS. Rhinonyssidae in *Chrysomus ruficapillus* (Vieillot, 1819) (Passeriformes: Icteridae) from Southern Brazil. *Comp Parasitol* 2017; 84(1): 67-71. <http://dx.doi.org/10.1654/1525-2647-84.1.67>.
- Bygrave AC. Respiratory acariasis in caged canaries (*Serinus canaria*). *Vet Rec* 1980; 107(14): 331. <http://dx.doi.org/10.1136/vr.107.14.331>. PMID:7467092.
- Castro MP. Reestruturação genérica de família "Rhinonyssidae Vitzthum, 1935" (Acari: Mesostigmata: Gamasides) e descrição de algumas espécies novas. *Arq Inst Biol (Sao Paulo)* 1948; 18: 253-284.
- Dimov ID. Rhinonyssidosis avium. *J VetPharma* 2011; 3-4: 88-90.
- Domrow R. The nasal mites of Queensland birds (Acari: Dermanyssidae, Ereyntidae, and Epidermoptidae). *Proc Linn Soc N S W* 1969; 93: 297-426.
- Fain A, Aitken THG. Acariens nasicoles d'oiseaux et de mammifères du Brésil. V. Nouveaux Rhinonyssidae de la région de Bélem (Nord Brésil). *Bull Ann Soc Roy Ent Belg* 1971; 107: 27-36.
- Fain A, Aitken THG. Acariens nasicoles d'Oiseaux et de Mammifères du Brésil. I. Rhinonyssidae de la région de Belém (Nord Brésil). *Bull Inst R Sci Nat Belg* 1968; 44(41): 1-28.
- Fain A, Aitken THG. Acariens nasicoles d'oiseaux et de Mammifères du Brésil. III. Nouvelles espèces de Rhinonyssidae de la région de Bélem (Nord Brésil). *Bull Ann Soc Roy Ent Belg* 1969; 105: 342-341.
- Fain A, Bastin JP. Un nouveau Rhinonyssidae parasite des fosses nasales du Colibri (Acarina: Mesostigmata). *Bull Ann Soc Roy Ent Belg* 1959; 95: 116-119.
- Fain A, Hyland KE. The mites parasitic in the lungs of birds. The variability of *Sternostoma tracheacolum* Lawrence, 1948, in domestic and wild birds. *Parasitology* 1962; 52(3-4): 401-424. <http://dx.doi.org/10.1017/S0031182000027232>.
- Guimarães LLB, Wouters ATB, Casagrande RA, Rolim VM, Wouters F, Gonçalves ICM, et al. Parasitismo pelo ácaro de sistema respiratório *Sternostoma tracheacolum* em um canário belga (*Serinus canaria domestica*). *Acta Sci Vet* 2012; 40(4): 1094.
- Mascarenhas CS, Bernardon FF, Gastal SB, Müller G. Checklist of the parasitic nasal mites of birds in Brazil. *Syst Appl Acarol* 2018; 23(8): 1672-1692. <http://dx.doi.org/10.11158/saa.23.8.15>.
- Mascarenhas CS, Coimbra MAA, Müller G, Brum JGW. Nasal Mites (Gamasida: Rhinonyssidae) of *Paroaria coronata* (Miller) (Passeriformes: Emberezidae). *Neotrop Entomol* 2011; 40(4): 507-508. <http://dx.doi.org/10.1590/S1519-566X2011000400016>. PMID:21952970.
- Mendes MM, Mascarenhas CS, Sinkoc AL, Müller G. Nasal mites of Tyrannidae (Aves) in Brazil. *Braz J Biol* 2014; 74(2): 480-482. <http://dx.doi.org/10.1590/1519-6984.12912>. PMID:25166334.
- Murray MD. Control of respiratory acariasis of Gouldian Finches caused by *Sternostoma tracheacolum* by feeding carbaryl. *Aust Vet J* 1966; 42(7): 262-264. <http://dx.doi.org/10.1111/j.1751-0813.1966.tb04718.x>. PMID:6007746.
- Pence DB. *Keys, species and host list, and bibliography for nasal mites of North American birds (Acarina: Rhinonyssinae, Turbinoptinae, Speleognathinae, and Cytotitidae)*. Lubbock: Texas Tech University; 1975.
- Riffkin GG, McCausland IP. Respiratory acariasis caused by *Sternostoma tracheacolum* in aviary finches. *N Z Vet J* 1972; 20(7): 109-112. <http://dx.doi.org/10.1080/00480169.1972.34026>. PMID:4516555.
- Santos LSS, Mascarenhas CS, Santos PRS, Farias NAR. Rhinonyssidae (Acari) in the house sparrows, *Passer domesticus* (Linnaeus, 1758) (Passeriformes: Passeridae), from southern Brazil. *Rev Bras Parasitol Vet*

2018; 27(4): 597-603. <http://dx.doi.org/10.1590/s1984-296120180064>. PMID:30427521.

Silva DS, Scheer S, Müller G. Nasal mites (Mesostigmata, Rhinonyssidae) in Sternidae (Aves: Charadriiformes) on the southern Coast of Brazil. *Rev Bras Parasitol Vet* 2018; 27(1): 109-111. <http://dx.doi.org/10.1590/s1984-29612017070>. PMID:29641787.

Slaoui M, Bauchet AL, Fiette L. Tissue sampling and processing for histopathology evaluation. In: Gautier JC. *Drug safety evaluation*. New York: Humana Press; 2017. Vol. 1641, p. 101-104. http://dx.doi.org/10.1007/978-1-4939-7172-5_4.

Tidemann SC, McOrist S, Woinarski JCZ, Freeland WJ. Parasitism of wild gouldian finches (*Erythrura gouldiae*) by the air-sac mite *Sternostoma tracheacolum*. *J Wildl Dis* 1992; 28(1): 80-84. <http://dx.doi.org/10.7589/0090-3558-28.1.80>. PMID:1548805.

Torres CM, Lent H, Moreira LF. Acarínose das vias respiratórias do canário ("Serinus canarius" L.) por "Sternostoma tracheacolum" Lawrence, 1948. *Rev Bras Biol* 1951; 11(4): 399-406.

Walter DE, Krantz GW. Collecting, rearing, and preparing specimens. In: Krantz GW, Walter DE, editors. *A manual of acarology*. Lubbock: Texas Tech University Press; 2009. p. 83-96.