



REVISTA BRASILEIRA DE REUMATOLOGIA

www.reumatologia.com.br



Case report

“Milk of calcium”: a rare presentation of calcinosis[☆]

Tania Caroline Monteiro de Castro^a, Roberto Guarnerio^b,
Maria Fernanda de Azevedo Giacomini^c, Marília Bergstron Lenzi Meneghin^c,
Guilherme Bottino Martins^c, Simone de Andrade Lotufo^c

^aHospital Infantil Municipal Menino Jesus, São Paulo, SP, Brazil

^bFaculdade de Medicina da Universidade de São Paulo, São Paulo, SP, Brazil

^cHospital Infantil Menino Jesus, São Paulo, SP, Brazil

ARTICLE INFO

Article history:

Received on 7 October 2011

Accepted on 14 May 2013

Keywords:

Calcinosis

Dermatomyositis

Resonance imaging

Systemic lupus erythematosus

Adolescent

Palavras-chave:

Calcinose

Dermatomiosite

Imagem por ressonância magnética

Lúpus eritematoso sistêmico

Adolescente

ABSTRACT

Rheumatic diseases such as juvenile dermatomyositis (JDM), juvenile systemic lupus erythematosus (JSLE) and systemic sclerosis may have calcium deposits in the subcutaneous and muscle tissues known as calcinosis. Extensive calcium-laden fluid collections referred as “milk of calcium” are rare forms of calcinosis in JDM. We describe a 15-year old patient with overlap syndrome (sclerodermatomyositis and JSLE), whose magnetic resonance imaging (MRI) showed perimusculares fluid collections in the lower limbs. During surgery, we observed the presence of whitish fluid collection suggestive of “milk of calcium”.

© 2014 Elsevier Editora Ltda. All rights reserved.

“Milk of calcium”: uma apresentação rara de calcinose

RESUMO

Algumas doenças reumáticas, como dermatomiosite juvenil (DMJ), lúpus eritematoso sistêmico juvenil (LESJ) e esclerose sistêmica (ES), podem apresentar depósitos de cálcio nos tecidos subcutâneo e muscular, lesões conhecidas como calcinose. Extensas coleções líquidas de cálcio referidas como *milk of calcium* são formas raras de calcinose presentes na DMJ. Descrevemos um paciente de 15 anos de idade, com diagnóstico de síndrome de sobreposição ou *overlap* (esclerodermatomiosite e LESJ), cuja ressonância magnética (RM) evidenciou coleções líquidas perimusculares em membros inferiores e que, durante procedimento cirúrgico, foi observada a presença de coleção líquida esbranquiçada sugestiva de *milk of calcium*.

© 2014 Elsevier Editora Ltda. Todos os direitos reservados.

[☆] Center: Hospital Infantil Municipal Menino Jesus - Instituto de Responsabilidade Social Hospital Sírio-Libanês.

* Corresponding author.

E-mail: taniacaroline@uol.com.br (T.C.M.d. Castro).

0482-5004/\$ - see front matter. © 2014 Elsevier Editora Ltda. All rights reserved.

<http://dx.doi.org/10.1016/j.rbre.2014.02.010>

Introduction

The superposition or overlap syndrome is a clinical entity in which two or more symptoms of autoimmune diseases are identified in the same patient.¹ These patients may have clinical or laboratory features of two or more of the following conditions: Juvenile dermatomyositis (JDM), juvenile systemic lupus erythematosus (JSLE), systemic sclerosis (SSc) and juvenile idiopathic arthritis (JIA). The coexistence of JSLE and esclerodermatomiositis is less frequent. These patients have heterogeneous clinical course and usually do not develop pulmonary fibrosis.² Calcinosis is a complication of some rheumatic diseases. In SSc, calcifications occur mainly in localized scleroderma.³ In JDM, these calcinosis are associated with some risk factors such as treatment delay, vasculopathy and severe disease.^{3,4} Patients with JSLE may also present dystrophic calcifications similar to those found in SSc and JDM.³ Little is known about its pathophysiology and there is no known effective treatment.⁴ A liquid collection known as "milk of calcium" is a very rare form of calcinosis. This term was originally used to characterize fluid-filled collections of calcium found in the gall bladder and kidneys.⁵ Is speculated that these fluid collections occur as a result of shearing of calcified tissues with resultant formation of pseudobursae containing liquid.^{5,6}

This paper reports the case of a patient with superposition or overlap syndrome of esclerodermatomiositis and JSLE, that presented during its evolution perimuscular fluid collections in the right and left thigh, later with surgical drainage.

Case report

EJAS, male, 15 years old, brown color, born and living in Sao Paulo.

Four years ago, the patient was affected by arthritis in the hands, elbows and ankles lasting for four months. The problem had migratory character, worsening during movement and improving with rest, being associated with loss of muscle strength in the upper limbs, sclerodactyly, Gottron's papules, ulcerated lesions on hands and feet and a convulsive episode. The patient began his monitoring at the Rheumatology Clinic of the Hospital Infantil Municipal Menino Jesus, where the following laboratory tests were performed: coarse speckled ANA 1/320, anti-SM and anti-RNP positive, CBC unchanged, CPK = 189 U/L (normal 26-190 U/L), LDH = 302 U/L (normal <480 U/L) and urine type 1 normal, ESR = 55 mm/h (normal 0-25 mm/h), PCR = 58.4 mg/L (normal <8.0 mg/L) and aldolase slightly increased to 11.9 U/L (normal up to 8.8 U/L).

Still in diagnostic investigation with a probable diagnosis of overlap (esclerodermatomiositis and JSLE), the patient was initiated on naproxen, chloroquine and corticosteroid, but remained unattended for two years. Upon return, the patient had a history of Raynaud's phenomenon, malar rash and seizures. Then, we chose to introduce methotrexate and carbamazepine, and to increase the dose of corticosteroids. Then a painless bilateral progressive increase of the thighs began, more at the left side and extending from the proximal thigh to the knee, without signs of inflammation; in this occasion,

nodules in the right arm and left arm were noted. The nail-fold capillaroscopy revealed SD pattern, with great number of ectasias and deletion III grade, compatible with JDM, mixed connective tissue disease (MCTD) or systemic sclerosis (SSc).

X-rays were obtained from elbows and lower limbs, showing radio-opaque material in the soft tissues at the elbows and along the quadriceps muscles (Fig. 1). Ultrasonography (US) was performed on the thighs, showing a bilateral anterior liquid lamina, dividing the subcutaneous muscle planes, more pronounced on the left, where were noticed debris in suspension. A needle puncture was performed and the cytology revealed granular eosinophilic material, lots of red blood cells and degenerative inflammatory cells, presence of numerous crystals, DHL = 3,463 U/L and negativity for malignancy.

Magnetic resonance imaging (MRI) of the thighs was requested. This study showed massive fluid collections in perimuscular spaces in the anterior and posterior regions of the right thigh and extensive fluid collection in perimuscular spaces in the anterior region of the left thigh plus adjacent intramuscular edema and edema of fatty planes of the medial region the of left thigh (Fig. 2). The patient was referred for surgical drainage, performed in the left thigh 3 months ago. During the procedure, there was leakage of large amounts of a milky liquid material. The microscopy revealed acellular granular eosinophilic material. The diagnosis of "milk of calcium" was established. Alendronate 70 mg /week was introduced, being in use for 2 months.

Discussion

Calcinosis or calcifications of non-articular tissues are manifestations of some rheumatic diseases, such as dermatomyositis, systemic lupus erythematosus, systemic sclerosis and MCTD; these conditions can be painful and very debilitating, sometimes resulting in functional disability.⁶ In a multicenter study conducted in Brazil with JDM and juvenile polymyositis patients, calcinosis were observed in 46 (24.3%) patients. These calcifications were localized in 29 patients, disseminated in 13, superficial in 23 and deep in 8 patients.⁷ "Milk of calcium" is a

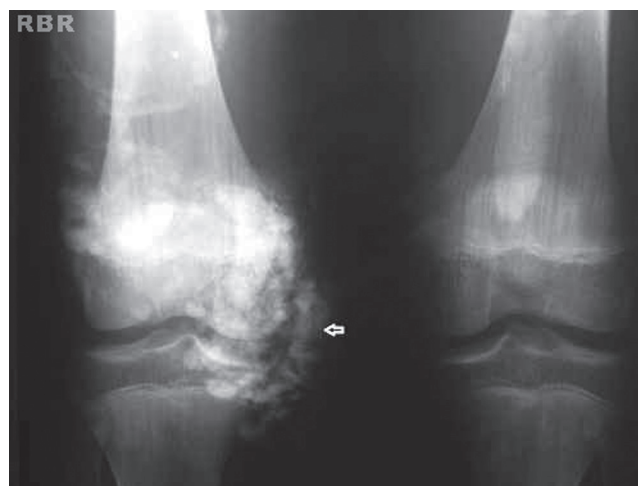

Fig. 1 – Calcinosis lesion on the right knee.

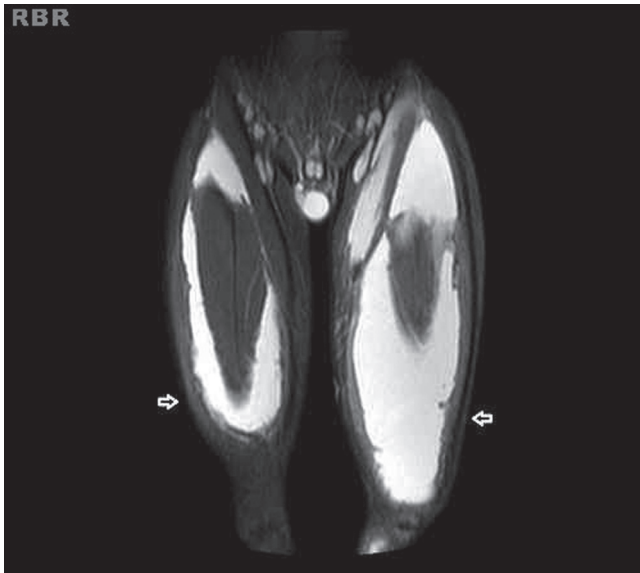


Fig. 2 - "Milk of calcium" - hyperintense on STIR image.

rare form of calcinosis found in patients with JDM. Its recognition and its differential diagnosis, especially with soft tissue infections and deep abscesses, are needed.⁶ These collections may persist for months and spontaneously drain away liquid contents through the skin.⁵ The exact mechanism of the formation of collections of "milk of calcium" in JDM is unknown. Hesla et al., who described the US findings in these fluid collections, speculated whether they are the result of the formation of pseudobursae with liquid content among the various planes of calcified tissues.⁵ These authors described two patients with severe JDM whose US results revealed extensive liquid collections filled with calcium in the subcutaneous and intermuscular tissues of thighs and calves. The authors suggest that these fluid collections are more frequent in patients with more severe involvement of the disease.⁵

Brown et al. described the findings of computed tomography (CT) and MRI of a fluid collection in the left calf region in an adolescent diagnosed with JDM. A CT scan showed extensive calcification of the subcutaneous tissues and intermuscular septum bilaterally and the presence of subcutaneous and intermuscular fluid collections in the left calf. MRI revealed subcutaneous and intermuscular fluid collections in the left calf with hypointense on T1 and hyperintense on T2.⁶ Sanson et al. described a teenager with JDM who presented fluid collection in her wrist, in MRI scan.⁸

The radiography is an important tool in the visualization of calcifications and the US scan characterizes the fluid collections in relation to their nature and their extent, but MRI can demonstrate both as well as their global relationship to the surrounding soft tissues in any plane.⁸ The dystrophic calcifications are present as hypointense on T1 and T2. The liquid collections of "milk of calcium" are demonstrated as hyperintense in T2 sequences.⁸

The differential diagnosis of fluid collections of "milk of calcium" must be done with pyomyositis, that may involve the subcutaneous tissue, deep muscle tissue and intermuscular spaces. Fever and leukocytosis are not always present at the onset of clinical manifestations of pyomyositis. In the US scan, these collections can be echolucent, hypoechoic or with the presence of debris.⁵

Many drugs have been used to treat calcinosis, such as hydroxychloroquine, intravenous immunoglobulin, cyclosporine, infliximab and alendronate. The results of these therapies have been contradictory and consistent benefits have not been observed.^{3,9} Despite the difficulty of diagnosis of this clinical case, the presence of clinical manifestations and laboratory changes of more than a rheumatic disease in the same patient suggests the diagnosis of overlap syndrome. To our knowledge, in the literature there are only three cases reported of "milk of calcium" in JDM patients and no case report in patients with overlap syndrome. Liquid collection of "milk of calcium" is a rare complication of JDM and even more rare of overlap syndrome, and its differentiation with infectious processes such as abscesses and pyomyositis should always be remembered.

Conflicts of interest

The authors declare no conflicts of interest.

REFERENCES

1. Jury EC, D' Cruz D, Morrow WJW. Autoantibodies and overlap syndromes in autoimmune rheumatic disease. *J Clin Pathol* 2001; 54(5): 340-7.
2. Rodríguez-Reyna TS, Alarcón-Segovia D. Overlap syndromes in the context of shared autoimmunity. *Autoimmunity* 2005; 38(3): 219-23.
3. Boulman N, Slobodin G, Rozenbaum M, Rosner I. Calcinosis in rheumatic diseases. *Semin Arthritis Rheum* 2005; 34(6): 805-12.
4. Mukamel M, Horev G, Mimouni M. New insight into calcinosis of juvenile dermatomyositis: A study of composition and treatment. *J Pediatr* 2001; 138(5):763.
5. Hesla RB, Karlson LK, McCauley RGK. Milk of calcium fluid collection in dermatomyositis: Ultrasound findings. *Pediatric Radiology* 1990; 20(5):344-6.
6. Brown AL, Murray JG, Robinson SP, Rooney MM. Case report: Milk of calcium complicating juvenile dermatomyositis - Imaging features. *Clin Radiol* 1996; 51(2): 147-9.
7. Sato JO, Sallum AM, Ferriani VP, Marini P, Sacchetti SB, Okuda EM e cols. A Brazilian registry of juvenile dermatomyositis: onset features and classification of 189 cases. *Clin Exp Rheumatol* 2009; 27(6): 1031-8.
8. Samson C, Soulen RL, Gursel E. Milk of calcium fluid collections in juvenile dermatomyositis: MR characteristics. *Pediatr Radiol* 2000; 30(1): 28-9.
9. Castro TCM, Yamashita E, Terrieri MTRA, Len CA, Hilário MOE. Calcinose na infância, um desafio terapêutico. *Rev Bras Reumatol* 2007; 47(1): 63-8.