

# Non operative management of renal gunshot wounds

## *Tratamento não operatório das lesões renais por arma de fogo*

BRUNA POZZI CESAR<sup>1</sup>; SIZENANDO VIEIRA STARLING, TCBC-MG<sup>2</sup>; DOMINGOS ANDRÉ FERNANDES DRUMOND, TCBC-MG<sup>3</sup>

### A B S T R A C T

**Objective:** To analyze the experience of nonoperative management (NOM) of renal injuries caused by a firearm projectiles (FAP) in the right thoraco-abdominal region in patients with hemodynamic stability and no signs of peritoneal irritation, highlighting the assessment of the safety of this approach. **Methods:** This was a prospective study with patients sustaining injuries by FAP in the right thoraco-abdominal region and kidney lesions, treated at the João XXIII Hospital (FHEMIG) in Belo Horizonte, from January 2005 to December 2012. Inclusion criteria were: hemodynamic stability, renal morphofunctional study by CT and no signs of peritoneal irritation. **Results:** A total of 128 patients met the inclusion criteria of the protocol and underwent NOM for right thoraco-abdominal injury by FAP. Of these, 37 (28.9%) had renal injuries. Trauma indexes: RTS 7.8, ISS16, and TRISS 99%. Lesions grade II and grade III were the most frequent. The most commonly associated intra-abdominal injury was of the liver, present in 81.1% of cases. Two patients (5.4%) had failed nonoperative treatment. **Conclusion:** The nonoperative treatment of such renal lesions, when properly indicated, has a high success rate, low complication rate and increases the chance of renal preservation. It is safe for well-selected patients in trauma centers with adequate infrastructure, experienced professionals and use of a specific protocol.

**Key words:** Kidney. Wounds and injuries. Wounds, penetrating. Wounds, gunshot. Critical pathways.

### INTRODUCTION

The management of penetrating renal trauma has evolved, during the last decades, from the immediate surgical exploration to attempt to preserve kidney to the non-operative treatment (NOM) in selected patients<sup>1</sup>. The advance of imaging techniques and the development of an internationally validated classification of renal trauma<sup>2</sup> improved the severity staging of lesions and facilitated monitoring. In addition, the appreciation of the hemodynamic stability of patients led to better NOM outcomes<sup>3</sup>.

Despite the supposed benefits of nonoperative treatment, a minority of penetrating renal injuries can be treated without surgery by NOM and currently the option is still controversial. However, there is increasing evidence that even high degree renal injuries can be treated safely without intervention in the hemodynamically stable patient<sup>4-6</sup>.

Although renal injuries by firearms are uncommon, they tend to produce complex lesions of the urinary system<sup>6</sup>. By contrast, there are few services that have sufficient number of patients with penetrating renal injuries, especially those by firearms, which allows the study of such cases.

The aim of this study was to analyze the NOM of patients with renal lesions caused by firearm projectiles (FAP) admitted with hemodynamic stability and no signs of peritoneal irritation, with emphasis on the evaluation of the safety of this approach.

### METHODS

We conducted a prospective study in patients victims of assault by firearm in the right thoraco-abdominal region, with kidney injury, treated at João XXIII Hospital (FHEMIG), in the period from January 2005 to December 2012. Patients who met the inclusion criteria determined by the Protocol of the Service of General Surgery and Trauma of HJXXIII took part in this study<sup>7</sup>. The study was approved by the Ethics in Research Committee under No 049/2009.

The protocol of HJXXIII for this type of approach includes injuries exclusively located in the right thoraco-abdominal region, caused by FAP, which penetrate between ribs and do not cross the midline. When admitted to the emergency room these patients must display hemodynamic stability, defined as systolic blood pressure greater than 90 mmHg and heart rate less than 110 bpm, and no signs of

Work performed at the John XXIII Hospital of the Hospital Foundation of the State of Minas Gerais – FHEMIG, Belo Horizonte, Minas Gerais State – MG, Brazil.

1. Surgeon, John XXIII Hospital, FHEMIG; 2. Chief, General Surgery and Trauma Service, John XXIII Hospital, FHEMIG.

peritoneal irritation. Filling these criteria, they are then compulsorily referred to computed tomography (CT) examination<sup>7</sup>. If there is no complication, the image control will be held two months after trauma, with the objective of analyzing the evolution of wound healing. The patient is then monitored annually for a period of five years from the date of injury.

The data analyzed were: age, gender, trauma indexes, CT result, existing lesions, clinical course, complications and their treatment, duration of hospitalization and death.

The data were stored in a database. The variables were described using measures of central tendency. To test differences in means we used Student's t test. To test differences between proportions we used the chi-square test.

## RESULTS

During the period, 128 patients met the inclusion criteria of the protocol and underwent NOM for right thoracoabdominal injury by FAP. Of these, 37 (28.9%) had renal injury. The majority (91.9%) were male and the mean age was 24 years. All patients treated conservatively were hemodynamically stable, without signs of peritonitis and underwent computed tomography. The global average of trauma indexes observed were: RTS 7.8; ISS 16; and TRISS 99%. CT findings of the lesions found are described in table 1.

The most frequent injuries were grade II and III. The classification of lesions are listed in Table 2.

Two patients (5.4%) had failed nonoperative treatment, one with grade II injury and one with grade IV injury. Both had associated liver damage and that was the direct cause of the need for laparotomy (choleperitoneum). The most commonly associated intra-abdominal injury was of the liver, present in 81.1% of cases (Figure 1). There was one case of pneumonia (2.7%), one case of urinary tract infection (2.7%) and one death (2.7%) due to associated Traumatic Brain Injury (TBI). The mean hospital stay was seven days.

## DISCUSSION

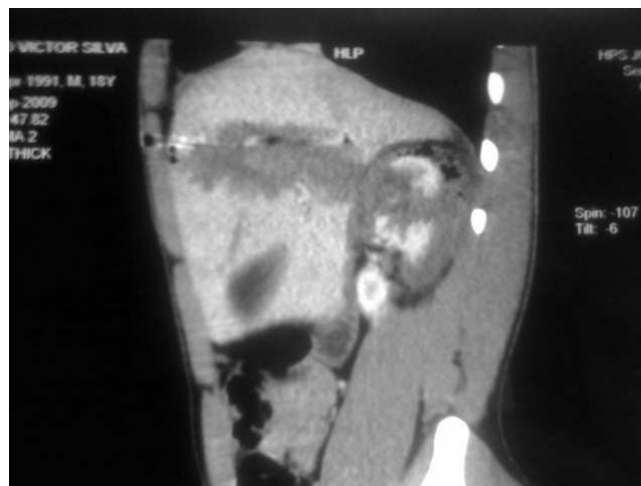
Renal lesions occur in about 1 to 5% of all traumas<sup>3,8</sup>, and in 1 to 19% of the penetrating abdominal ones<sup>8</sup>. The use of CT in trauma made its diagnosis more accurate and frequent, allowing the surgeon to study the renal function and establish the magnitude of the kidney injury. CT with intravenous contrast medium, including images of the late phase, is the best method for assessing renal lesions<sup>9</sup>. It provides important information, providing the classification of the lesion, assessing renal vascularization, verifying whether there is a ischemic segment or evidence

**Table 1** - Main associated injuries.

Injuries	Patients	Percentage
Liver + Kidney	30	81.1%
Diaphragm + Kidney	2	5.4%
Kidney	5	13.5%
Total	37	100%

**Table 2** - Stratification of renal injuries according degrees and their relation to NOM failure.

Degree	Patients	Nom Failure
I	5 (13.5%)	0
II	17 (46%)	1
III	13 (35.1%)	0
IV	2 (5.4%)	1
V	0	0
TOTAL	37 (100%)	2 (5.4%)



**Figure 1** - CT scan of patient with thoraco-abdominal wound by firearm, with degree III renal injury associated with a degree II hepatic injury.

of active bleeding, and mainly detecting the escape of contrast from the excretory system.

Bleeding and escape of urine from the excretory system are the two major difficulties in addressing renal trauma. The major renal blood flow (each kidney receives about 12% of the cardiac output, or 500 mL/min), suggests that kidney bleedings sometimes need some type of invasive procedure to stop the bleeding<sup>10</sup>. However, the bleeding arises from the renal lesion in most cases, ceasing spontaneously because it is contained in the retroperitoneum, buffered by the Gerota's fascia. With the advance in endoscopic manipulation of the urinary tract,

particularly with the placement of ureteral stent (double-J catheter) inside the renal pelvis, lesions of the excretory system could be addressed in this way, without the need for surgery, except when there is total disruption of the pielo-ureteral junction.

The anatomical location of the right kidney and its close relationship with the visceral surface of the liver explains the high frequency of simultaneous injury of these two organs (Figure 1). In this study, the frequency of this association was 81.08%. One needs to take special care when the inlet is in the dorsal region and there is concomitant liver and kidney injury. In this circumstance, it is necessary to make sure that there are no colonic lesions when electing NOM. The reconstruction of the trajectory of the projectile by axial, coronal and sagittal images in multidetector CT is essential to rule out injury to the intestine. When in doubt, surgery is the safest option.

In penetrating trauma, especially by FAP, the surgical treatment of renal lesions is the most suitable due to the high frequency of associated intra-abdominal injuries<sup>11-13</sup>. In patients with renal injury grades I and II, when surgically explored, the bleeding has ceased and there is no further need for a hemostatic procedure. Recognizing these lesions preoperatively and not manipulating them during surgery is the currently recommended conduct by the literature. This type of conduct is considered NOM by many authors<sup>1,6,14,15</sup>. In patients who have not had the chance to be submitted to imaging before surgery, it is recommended to check the presence, functionality and viability of the contralateral kidney before exploring the renal hematoma<sup>8</sup>.

Based on these assertions, NOM of isolated kidney injuries was proposed in selected cases. In penetrating trauma by stab wounds, 51-77% of patients with renal injury can be addressed without surgery, since the inclusion criteria of the protocol are followed. The success rate has reached 95%<sup>13,16</sup>. However, in penetrating injuries from firearms, the selection of patients to indicate NOM should be carefully and strictly follow the proposed inclusion criteria. It should only be adopted in patients who do not have immediate surgical indication and can be submitted to contrast-enhanced CT to confirm and study the renal injury<sup>17</sup>. With current treatment options, most of haemodynamically stable patients with renal lesions can safely be subjected to such treatment<sup>3</sup>, provided that there is no associated injury imposing surgery. The authors who propose this approach can perform it in 10-40% of renal injuries from firearms, obtaining a success rate ranging from 91 to 100%<sup>1,6,12,15,17</sup>.

In 1985, Heyns *et al.*<sup>4</sup> conducted a randomized controlled trial of mandatory surgery versus NOM in patients with renal stabbing wounds, asymptomatic, diagnosed by pyelography. They realized that the NOM reduced the number of complications and decreased the length of hospital stay when compared with mandatory surgical treatment. Exploratory laparotomy used to be

recommended for all patients who presented with renal injury by penetrating trauma. However, nowadays the non-operative treatment has been accepted with greater frequency in patients with lesions grade I, II or III by penetrating trauma, where there are no hollow viscera injuries or hemodynamic instability<sup>3</sup>.

Velmahos *et al.*<sup>18</sup> conducted a study that included 1,856 patients with abdominal injury by firearms and showed that NOM was a safe method for trauma centers and significantly reduced the rate of unnecessary laparotomy and hospital expenses.

Navsaria *et al.*<sup>17</sup> obtained a success rate of 90.9% of non-operative treatment in a study with 33 patients suffering from renal injury by firearms. In the present study, considering only the renal lesions, there was no need to operate any patient. In this sample the need for surgical intervention occurred exclusively from complications of the liver injury.

In 2010, in a retrospective study from Muir *et al.*<sup>9</sup>, one of every three patients with penetrating renal trauma underwent NOM, although one in five of these individuals needed, ultimately, angiographic or surgical treatment. Based on these data, we concluded that the routine use of angiography can reduce failures in NOM and improve the prognosis of patients undergoing this type of treatment.

Bjurlin *et al.*<sup>1</sup> carried out a comparative analysis showing that NOM of penetrating renal injuries, including those by firearms, has lower mortality, lower incidence of transfusions and a shorter stay in intensive care compared with patients undergoing nephrectomy, but rates similar to those undergoing nephrorraphy.

Persistent bleeding is a common complication in severe lacerations of the renal cortex and medulla, seen commonly in penetrating renal trauma, especially stabbing ones. It occurs in 13-25% of renal injuries grades III and IV treated conservatively. Clinically, the patient presents with persistent hematuria, low hematocrit or hemodynamic instability<sup>3</sup>. Bleeding from segmental renal artery pseudoaneurysms and traumatic arteriovenous fistulas are not uncommon findings in renal penetrating trauma<sup>1</sup>. Unfortunately, NOM of renal vascular lesions is often unsuccessful, invasive procedures being necessary in most cases. In such cases, selective embolization of segmental arteries is highly effective<sup>9</sup>. However, angiography with or without embolization remains a rarely used procedure with renal penetrating trauma<sup>9</sup>. The treatment by interventional radiology in selected patients helped reduce the need for surgical treatment<sup>3</sup>.

NOM provides a greater chance of renal preservation, decreases length of stay, cost of treatment and the rate of complications. According to Cheng *et al.*, lesions with contrast escape from the excretory system have a higher possibility of complication and NOM failure<sup>19</sup>. The Eastern Association for the Surgery of Trauma revised the available literature on the treatment of penetrating re-

nal trauma in 2010 and concluded that the evidence is not yet sufficient for the option for NOM of kidney lesions by FAP to be widely recommended and that further studies on this topic are still needed<sup>20</sup>.

The study of NOM of penetrating renal injuries is still a growing field. The present study demonstrated, once

again, that the non-operative treatment of these injuries, when properly indicated, has high success and low complication rates and increases the chance of renal preservation. It is safe for well-selected patients in trauma centers with adequate infrastructure, experienced staff and a specific protocol to accomplish it.

## R E S U M O

**Objetivo:** analisar a experiência do tratamento não operatório (TNO) das lesões renais ocasionadas por projétil de arma de fogo (PAF), na região tóraco-abdominal direita, em pacientes com estabilidade hemodinâmica e sem sinais de irritação peritoneal), com destaque para a avaliação da segurança desse tipo de abordagem. **Métodos:** estudo prospectivo, em pacientes vítimas de agressão por PAF na região tóraco-abdominal direita, com lesão renal, atendidos no Hospital João XXIII (FHEMIG), em Belo Horizonte, no período de janeiro de 2005 a dezembro 2012. Os critérios de inclusão neste estudo foram: estabilidade hemodinâmica, estudo morfofuncional renal pela tomografia e ausência de sinais de irritação peritoneal. **Resultados:** No período, 128 pacientes preencheram os critérios de inclusão do protocolo e foram submetidos à TNO de ferimento tóraco-abdominal direito por PAF. Destes, 37 (28,9%) apresentavam lesão renal. Índices de trauma: RTS 7,8; ISS 16; e TRISS 99%. As lesões grau II e grau III foram as mais frequentes. A lesão intra-abdominal associada mais comum foi a lesão hepática, presente em 81,1% dos casos. Dois pacientes (5,4%) apresentaram falha no tratamento não operatório. **Conclusão:** o tratamento não operatório dessas lesões renais, quando bem indicado, tem alto índice de sucesso, baixa taxa de complicações e aumenta a chance de preservação renal. Ele é seguro para pacientes bem selecionados, em centros de trauma com infraestrutura adequada, profissionais experientes e protocolo específico para realizá-lo.

**Descritores:** Rim. Ferimentos e lesões. Ferimentos penetrantes. Ferimentos por arma de fogo. Procedimentos clínicos.

## REFERENCES

- Bjurlin MA, Jeng EI, Goble SM, Doherty JC, Merlotti GJ. Comparison of nonoperative management with renorrhaphy and nephrectomy in penetrating renal injuries. *J Trauma*. 2011;71(3):554-8.
- Moore EE, Shackford SR, Pachter HL, McAninch JW, Browner BD, Champion HR, et al. Organ injury scaling: spleen, liver and kidney. *J Trauma*. 1989;29(12):1664-6.
- Shoobridge JJ, Corcoran NM, Martin KA, Koukounaras J, Royce PL, Bultitude MF. Contemporary management of renal trauma. *Rev Urol*. 2011;13(2):65-72.
- Heyns CF, De Klerk DP, De Kock ML. Nonoperative management of renal stab wound. *J Urol*. 1985;134(2):239-42.
- Demetriades D, Hadjizacharia P, Constantinou C, Brown C, Inaba K, Rhee P, et al. Selective nonoperative management of penetrating abdominal solid organ injury. *Ann Surg*. 2006;244(4):620-8.
- Voelzke BB, McAninch JW. Renal gunshot wounds: clinical management and outcome. *J Trauma*. 2009;66(3):593-600; discussion 600-1.
- Starling SV, Rodrigues BL, Martins MPR, Silva MSA, Drumond DAF. Tratamento não operatório do ferimento por arma de fogo na região toracoabdominal direita. *Rev Col Bras Cir*. 2012;39(4):286-94.
- Yeung LL, Brandes SB. Contemporary management of renal trauma: differences between urologists and trauma surgeons. *J Trauma Acute Care Surg*. 2012;72(1):68-75; discussion 75-7.
- Muir MT, Inaba K, Ong A, Barmparas G, Branco BC, Zubowicz EA, et al. The need for early angiography in patients with penetrating renal injuries. *Eur J Trauma Emerg Surg*. 2012;38(3):275-80.
- Peterson NE. The significance of delayed post-traumatic hemorrhage. *J Urol*. 1978;119(4):563-5.
- McAninch JW, Carroll PR, Armenakas NA, Lee P. Renal gunshot wounds: methods of salvage and reconstruction *J Trauma*. 1993;35(2):279-83; discussion 283-4.
- Wessels H, McAninch JW, Meyer A, Bruce J. Criteria for nonoperative treatment of significant penetrating renal lacerations. *J Urol*. 1997;157(1):24-7.
- Kansas BT, Eddy MJ, Mydlo JH, Uzzo RG. Incidence and management of penetrating renal trauma in patients with multiorgan injury: extended experience at an inner city trauma center. *J Urol*. 2004;172(4 Pt 1):1355-60.
- Holcroft JW, Trunkey DD, Minagi H, Korobkin MT, Lim RC. Renal trauma and retroperitoneal hematomas – indications for exploration. *J Trauma*. 1975;15(12):1045-52.
- Velmahos GC, Demetriades D, Cornwell EE 3rd, Belzberg H, Murray J, Asensio J, et al. Selective management of renal gunshot wounds. *Br J Surg*. 1998;85(8):1121-4.
- Armenakas NA, Duckett CP, McAninch JW. Indications for nonoperative management of renal stab wounds. *J Urol*. 1999;161(3):768-71.
- Navsaria PH, Nicol AJ. Selective nonoperative management of kidney gunshot injuries. *World J Surg*. 2009;33(3):553-7.
- Velmahos GC, Demetriades D, Toutouzas KG, Sarkisyan G, Chan LS, Ishak R, et al. Selective nonoperative management in 1,856 patients with abdominal gunshot wounds: should routine laparotomy still be the standard of care? *Ann Surg*. 2001;234(3):395-402; discussion 402-3.
- Cheng DL, Lazan D, Stone N. Conservative treatment of type III renal trauma. *J Trauma*. 1994;36(4):491-4.
- Como JJ, Bokhari F, Chiu WC, Duane TM, Holevar MR, Tandoh MA, et al. Practice management guidelines for selective nonoperative management of penetrating abdominal trauma. *J Trauma*. 2010;68(3):721-33.

Received on 08/08/2012

Accepted for publication 06/10/2012

Conflict of interest: none

Source of funding: none

**How to cite this article:**

César BP, Starling SV, Drumond DAF. Non operative management of renal gunshot wounds. Rev Col Bras Cir. [periódico na Internet] 2013;40(4). Disponível em URL: <http://www.scielo.br/rcbc>

**Address correspondence to:**

Sizenando Vieira Starling  
E-mail: [sizastarling@bol.com.br](mailto:sizastarling@bol.com.br)