

Preoperative laparoscopy and peritoneal lavage in gastric adenocarcinoma: can the approach be modified?

Laparoscopia e lavado peritoneal no pré-operatório do adenocarcinoma gástrico: podemos modificar a conduta?

JORGE ROBERTO MARCANTE CARLOTTO, TCBC-RS¹; FERNANDA MARCANTE CARLOTTO²; MARCOS DAL VESCO NETO³; JULIA PASTORELLO⁴; LUCAS DUDA SCHMITZ¹; JUAREZ ANTONIO DAL-VESCO¹

A B S T R A C T

Objective: to assess whether laparoscopy with peritoneal lavage is superior to computed tomography for staging gastric adenocarcinoma and whether it can modify the surgical approach. **Methods:** we conducted a retrospective study of 46 patients with gastric adenocarcinoma treated by the digestive surgery team of the Passo Fundo Clinics Hospital (RS), from January 2015 to December 2018, and submitted to laparoscopy with preoperative peritoneal lavage. All patients underwent preoperative clinical staging with computed tomography. **Results:** of the 46 patients analyzed, the majority had tumors located in the cardia (34.8%), poorly differentiated (69.6%), and subtype signet ring cells (65.2%). In 91.3%, the computed tomography scan did not identify peritoneal carcinomatosis or distant metastasis. Among these patients with negative computed tomography for distant disease, 21.8% had positive peritoneal lavage for neoplastic cells and had their therapeutic approaches modified. **Conclusion:** laparoscopy and peritoneal lavage altered the surgical decision in 21.8% of patients, providing a more reliable preoperative staging in gastric adenocarcinoma.

Keywords: Adenocarcinoma. Stomach Neoplasms. Laparoscopy. Peritoneal Lavage. Preoperative Period. Neoplasm Staging.

INTRODUCTION

Gastric cancer has been described since 3000 b.C. in hieroglyphic inscriptions and papyrus manuscripts from ancient Egypt. The first important statistical analysis of its incidence and mortality, using data collected in Verona, Italy (1760-1839), showed that gastric cancer was one of the most common and lethal at the time¹. Currently, about 22,220 patients are diagnosed each year in the United States with this type of cancer, of whom 10,990 die due to the tumor. Its incidence, however, features great geographical variability, with high incidence areas including Latin America, East Asia and parts of Europe and the Middle East². In 95% of cases, they are adenocarcinomas and most are advanced tumors at the time of diagnosis³.

In the United States and Western Europe, since the 1970s, the incidence of distal gastric tumors is decreasing, while increasing in the gastroesophageal transition and gastric cardia⁴, with worse prognosis and increased risk of peritoneal dissemination⁵.

With the confirmed diagnosis of adenocarcinoma, patients should undergo staging to evaluate the extent of disease and establish a proper approach⁶. Preoperative clinical staging includes computed tomography (CT) of the abdomen and, in locally advanced tumors, complementary staging with laparoscopy and cytology of the peritoneal lavage⁵. In addition to CT, one of the complementary diagnostic techniques that may assist in patient selection is Positron Emission Computed Tomography (PET-CT).

1 - Passo Fundo Clinics Hospital, Digestive Tract Surgery Service, Passo Fundo, RS, Brazil. 2 - Passo Fundo University, Medicine Course, Passo Fundo, RS, Brazil. 3 - Porto Alegre Clinics Hospital, General Surgery Service, Porto Alegre, RS, Brazil. 4 - Passo Fundo Clinics Hospital, Clinical Oncology Service, Passo Fundo, RS, Brazil.

However, its use has not been widespread because its specificity is not yet well defined and some histological types, such as mucinous and signet ring cell carcinomas, have low metabolic activity⁷.

Studies show that 20% to 30% of patients with negative TC have peritoneal metastasis at laparoscopy², confirming that TC is a method with low sensitivity to detect peritoneal metastasis⁷. Thus, the objective of our research is to evaluate whether laparoscopy with diagnostic peritoneal lavage (DPL) is superior to CT for gastric adenocarcinoma staging and whether it can modify the patient's surgical approach.

METHODS

We retrospectively reviewed the medical records of 46 patients with gastric adenocarcinoma treated by a digestive surgery team at the Passo Fundo Hospital Clinics - RS, from January 2015 to December 2018. The variables studied were demographic, clinical, endoscopic, surgical, and of the pathological exams. We collected the data and organized them in spreadsheets. We performed statistical analysis of the investigated data with the SPSS Statistics 20.0 (IBM). We presented quantitative variables as mean \pm standard deviation, and qualitative ones, as frequency and percentage. We compared the data with the Pearson's chi-square test. The significance level was set at 5% ($p=0.05$).

DPL was performed with the patient in the lithotomy position, under general anesthesia and pneumoperitoneum with carbon dioxide (CO₂) at 15mmHg pressure. The first 10mm trocar was introduced in the umbilicus and two trocars of 5mm were placed in the right and left flanks.

The peritoneal cavity was carefully evaluated to search for metastases, which included thorough investigation of the stomach, omentum, liver surface, both sides of the diaphragm, mesentery and the bursa, through opening of the gastro-colic ligaments. Upon negative inspection for macroscopic implants, peritoneal lavage was then performed by the instillation of 350ml of heated saline in the omental retrocavity and, after peritoneal agitation, the fluid was collected and sent for oncotic cytopathology evaluation (Figure 1).

This work was approved by the Institutional Ethics Committee with the following reference number: 2186715.

RESULTS

Most patients were men (65.2%), with a mean age of 66.6 years (± 11.31), and the main symptom was epigastric pain (69.6%). According to the Borrmann classification, most lesions were type II and III, located mainly in the proximal third, at the level of the cardia (34.8%) and with negative *Helicobacter pylori* screening in most examinations (91.3%). With respect to histological differentiation, poorly differentiated tumors (69.6%) and subtype signet ring cell (65.2%) predominated. We found that 47.8% of the patients had lymph node enlargement, mainly perigastric, at CT, and in 91.3% of them imaging did not identify distant metastasis.

In the 46 patients who underwent full-abdomen CT for stomach carcinoma staging and who underwent DPL, we found negative agreement between CT and the investigation of macroscopic and microscopic peritoneal disease in 32 patients (69.6%), those being true negatives.

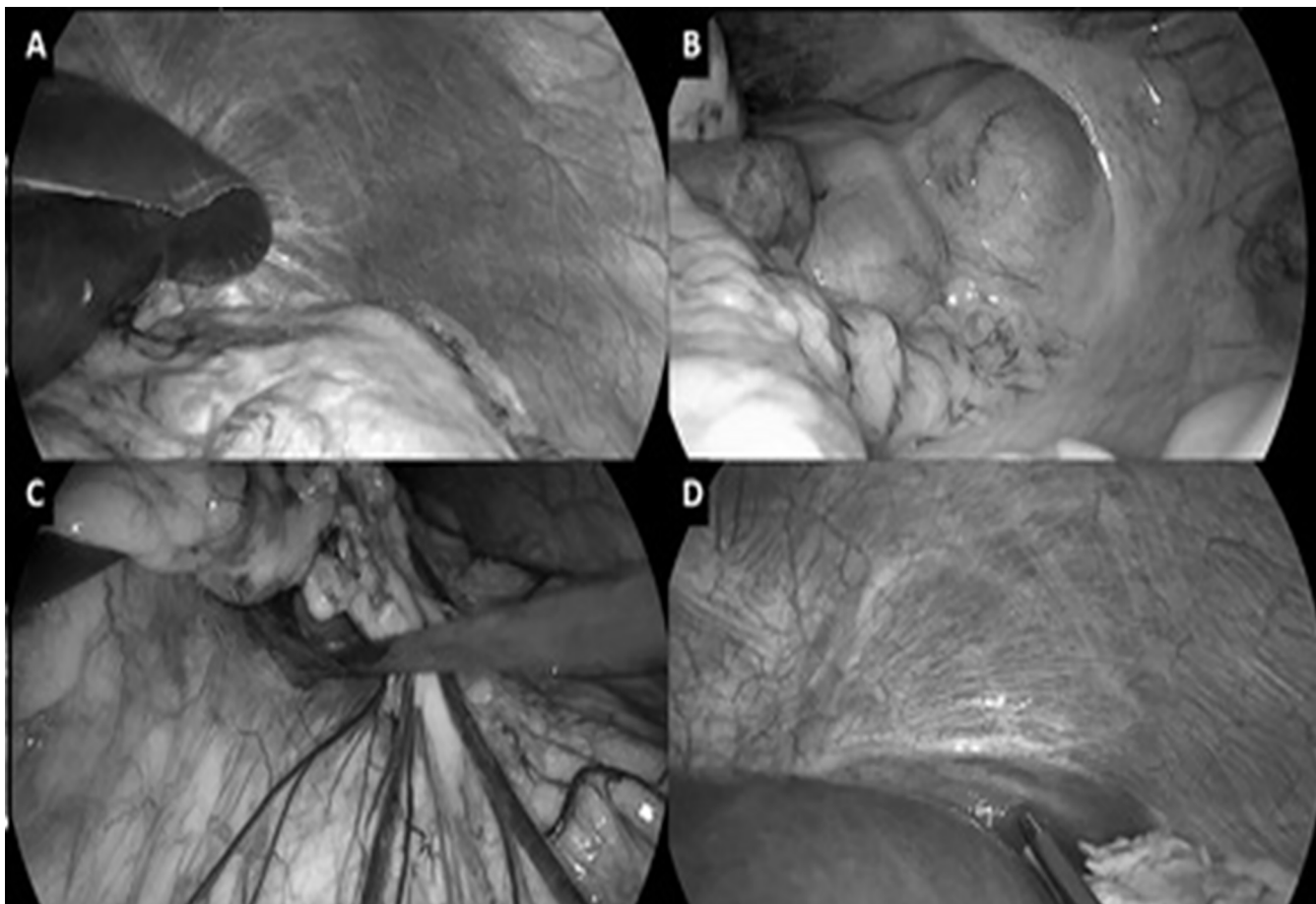


Figure 1. Diagnostic laparoscopy with peritoneal lavage. A: visualization of the visceral peritoneum of the stomach; B: peritoneal sac fundus evaluation; C: access to omental retrocavity and saline instillation; D: aspiration of the instilled serum for cytological analysis.

The concordance of positive results between the tests occurred in two patients (4.3%). Two other patients with positive CT had negative peritoneal disease (4.3%). Moreover, ten patients with negative CT had positive DPL for neoplastic cells, characterizing the occurrence of false negative results in such patients (21.8%) (Table 1).

When analyzing DPL, histological differentiation was related to its positivity ($p < 0.05$). In the 32 patients with negative DPL and CT for peritoneal disease who underwent resection (69.5%), total gastrectomy was the most performed, with a mean resection of 35.8 lymph nodes (± 21.8). The remaining 14 patients, with positive CT or peritoneal disease, underwent chemotherapy treatment (30.5%).

Table 1. Analysis of patients who underwent CT and their respective cytology results.

	CT negative (n)	CT positive (n)	Total (n)
Peritoneal disease negative (n)	32	2	34
Peritoneal disease positive (n)	10	2	12
Total (n)	42	12	46

CT: computed tomography.

DISCUSSION

Along with the development of laparoscopic surgery, the diagnosis laparoscopy peritoneal lavage in gastric cancer surgery has become more common and its viability and utility have been increasingly reported in systematic reviews. Due to the less invasive nature of this approach, DPL can be accomplished with few complications, allowing patients with peritoneal disease to recover faster and to receive appropriate treatment as early as possible⁸.

Intravenous contrast CT is the most commonly used imaging method for preoperative staging of stomach cancer. However, prospective studies have shown that 20-30% of patients considered potentially curable, based on preoperative imaging exams, have metastatic disease at surgery. A number of recent studies have confirmed that laparoscopy is extremely sensitive in detecting intra-abdominal metastases in gastric cancer patients, avoiding unnecessary surgery in 21% to 41% of patients⁹. Laparoscopy also allows peritoneal lavage and collection of material for cytological analysis, the presence of tumor cells in the peritoneal cavity, even in the absence of macroscopic metastatic disease, being a poor prognostic factor¹⁰.

The sensitivity of DPL cytology for detecting peritoneal disease varies widely in the literature, from 26% to 70.8%. However, this variability results may be related to non-standardized methods of peritoneal lavage, as well as to biases between observers and between pathologists' interpretations of the cytology analysis¹¹.

Researches suggest that DPL can be cost effective when the procedure is well indicated. Considering that its specificity for occult metastases is close to 100%, and that the probability of detection of hidden metastases by DPL after negative CT is 31%, in line with other work previously published, there is an near two-fold increase in the probability of cost-effectiveness. This result supports the use of the procedure when patients have potential risk factors for hidden disease on imaging exams¹².

A research conducted at the Japan Cancer Institute showed that cancer treatment has changed in 47.4% of patients undergoing DPL. Thus, when well indicated, it had a much greater impact on clinical decision-making when compared with those in previous prospective studies. Regarding secondary outcomes, the diagnostic accuracy of DPL reached 91.5% and the procedure's false-negative rate was 10.6%¹³.

Positron emission tomography, not evaluated in our study, has been suggested as an appropriate staging modality for distant metastases. However, the sensitivity/specificity for detecting distant metastasis was reported to be 21% and 40%, respectively. Therefore, despite these tests, patients with incurable or unresectable gastric cancer are still undergoing non-therapeutic surgery. Thus, to solve this problem, diagnostic laparoscopy has been advocated as essential in the decision-making in advanced gastric cancer. Washes obtained during diagnostic laparoscopy were used as controls and their sensitivity and specificity reached 92% and 100%, respectively¹⁴.

The 2017 National Comprehensive Cancer Network (NCCN) guidelines recommend that preoperative laparoscopy to detect occult metastatic disease should be considered in all patients at high risk of metastasis, ie with cT4 tumors, large tumors of types III and IV, in addition to tumors with lymph node metastasis², since DPL-associated laparoscopy in advanced disease can improve treatment decision-making for advanced gastric cancer and decrease unnecessary surgery¹⁴. These practices are supported by data suggesting that occult M1 disease is found in up to 40% of gastric cancer patients and that non-therapeutic surgery can be avoided in a significant subset of these patients.

A final study cohort included only patients with gastric cancer confirmed by biopsy that had an initial negative staging, laparoscopy followed by chemotherapy, or preoperative chemo-radiotherapy and attempted gastrectomy. Routine diagnostic laparoscopy at the time of definitive resection in preoperative gastric cancer patients may prevent non-therapeutic surgery in at least 12% of all patients and may offer even greater benefits for high-risk patients with poorly differentiated tumors¹⁵.

In our study, the findings of laparoscopy with DPL in our patients changed the initial therapy in ten (21.8%) of the 46 patients. We conclude that it should be performed in the preoperative staging of stomach adenocarcinoma.

R E S U M O

Objetivo: avaliar se a laparoscopia com lavado peritoneal é superior à tomografia computadorizada para o estadiamento do adenocarcinoma gástrico e se pode modificar a conduta cirúrgica do paciente. **Métodos:** estudo retrospectivo de 46 pacientes portadores de adenocarcinoma gástrico tratados pela equipe de cirurgia digestiva do Hospital de Clínicas de Passo Fundo (RS), de janeiro de 2015 a dezembro de 2018, e submetidos à laparoscopia com lavado peritoneal pré-operatório. Todos os pacientes foram submetidos ao estadiamento clínico pré-operatório com tomografia computadorizada. **Resultados:** dos 46 pacientes analisados, a maioria apresentava tumores localizados na cárdia (34,8%), pouco diferenciados (69,6%) e do subtipo células em anel de sinete (65,2%). Em 91,3% deles a tomografia computadorizada não identificou carcinomatose peritoneal ou metástases à distância. Entre estes pacientes com tomografia computadorizada negativa para doença à distância, 21,8% apresentaram lavado peritoneal positivo para células neoplásicas e tiveram suas condutas terapêuticas modificadas. **Conclusão:** a laparoscopia e o lavado peritoneal alteraram a decisão cirúrgica em 21,8% dos pacientes, proporcionando um estadiamento pré-operatório mais fidedigno no adenocarcinoma gástrico.

Descritores: Adenocarcinoma. Neoplasias Gástricas. Laparoscopia. Lavagem Peritoneal. Período Pré-Operatório. Estadiamento de Neoplasias.

REFERENCES

1. Japanese Gastric Cancer Association. Japanese Classification of Gastric Carcinoma. 2nd English Edition. Gastric Cancer. 1998;1(1):10-24.
2. Ilhan E, Alemdar A, Ureyen O, Bas K. The importance of extensive intraoperative peritoneal lavage as a promising method in patients with gastric cancer showing positive peritoneal cytology without overt peritoneal metastasis and other therapeutic approaches. J Invest Surg. 2017;30(5):318-24.
3. Luinetti O, Fiocca R, Villani L, Alberizzi P, Ranzani GN, Solcia E. Genetic pattern, histological structure, and cellular phenotype in early and advanced gastric cancers: evidence for structure-related genetic subsets and for loss of glandular structure during progression of some tumors. Hum Pathol. 1998;29(7):702-9.
4. Montori G, Coccolini F, Ceresoli M, Catena F, Colaiani N, Poletti E, et al. The treatment of peritoneal carcinomatosis in advanced gastric cancer: state of the art. Int J Surg Oncol. 2014;2014:912418.
5. Debon LM, Viola LS, Toneto MG. Carcinomatose peritoneal em câncer gástrico: diagnóstico, manejo e conduta. Acta Méd. (Porto Alegre). 2018;39(2):82-91.
6. Hosogi H, Shinohara H, Tsunoda S, Hisamori S, Sumida H, Hida K, et al. Staging laparoscopy for advanced gastric cancer: significance of preoperative clinicopathological factors. Langenbecks Arch Surg. 2017;402(1):33-9.
7. Mosca AMSS, Barbosa LE. Abordagem terapêutica da carcinomatose peritoneal em doentes com carcinoma colorretal. Rev Port Cir. 2017;40:35-50.

8. Irino T, Sano T, Hiki N, Ohashi M, Nunobe S, Kumagai K, et al. Diagnostic staging laparoscopy in gastric cancer: a prospective cohort at a cancer institute in Japan. *Surg Endosc.* 2018;32(1):268-75.
9. Koganti SB, Boddepalli S, Nambada M, Thumma VM, Nagari B, Sastry RA. Positive peritoneal lavage cytology - implications for staging and management of gastric cancer. *Indian J Surg Oncol.* 2016;7(4):430-5.
10. Frattini F, Rausei S, Chiappa C, Rovera F, Boni L, Dionigi G. Prognosis and treatment of patients with positive peritoneal cytology in advanced gastric cancer. *World J Gastrointest Surg.* 2013;5(5):135-7.
11. Machairas N, Charalampoudis P, Molmenti EP, Kykalos S, Tsaparas P, Stamopoulos P, et al. The value of staging laparoscopy in gastric cancer. *Ann Gastroenterol.* 2017;30(3):287-94.
12. Li K, Cannon JGD, Jiang SY, Sambare TD, Owens DK, Bendavid E, et al. Diagnostic staging laparoscopy in gastric cancer treatment: a cost-effectiveness analysis. *J Surg Oncol.* 2018;117(6):1288-96.
13. Yoon H, Lee DH. New approaches to gastric cancer staging: beyond endoscopic ultrasound, computed tomography and positron emission tomography. *World J Gastroenterol.* 2014;20(38):13783-90.
14. Ajani JA, D'Amico TA, Almhanna K, Bentrem DJ, Chao J, Ds P, et al. Gastric Cancer, Version 3.2016, NCCN Clinical Practice Guidelines in Oncology. *J Natl Compr Canmc Netw.* 2016;14(10):1286-312.
15. Thiels CA, Ikoma N, Fournier K, Das P, Blum M, Estrella JS, et al. Repeat staging laparoscopy for gastric cancer after preoperative therapy. *J Surg Oncol.* 2018;118(1):61-7.

Received in: 07/28/2019

Accepted for publication: 09/17/2019

Conflict of interest: none.

Source of funding: none.

Mailing address:

Fernanda Marcante Carlotto

E-mail: fmcarlotto@gmail.com

