

Clinical success of infiltrant and resin sealant on incipient caries of permanent teeth: an integrative review of literature

Sucesso clínico do infiltrante e selante resinoso em cáries incipientes de dentes permanentes: uma revisão integrativa da literatura

Alexssandro Fermiano PIMENTA¹  0000-0001-9289-1442

Claudia Batitucci dos SANTOS DAROZ²  0000-0001-6810-2810

ABSTRACT

Objective: To perform an integrative literature review, presenting techniques to seal incipient caries, their advantages, indications and failures, and comparing their clinical success. **Methods:** The guiding question for this literature review was: What technique, sealant or resin infiltration, provides longer clinical longevity in sealing incipient caries lesions in permanent teeth? 1707 scientific articles published from 2005 to 2019 were searched in the PubMed, LILACS and SciELO databases, using the following keywords: "caries sealing", "resinous infiltrant," and "caries progression". After their titles and abstracts were read, 10 papers were selected according to the inclusion criteria: papers written in the English language, randomized clinical control trials lasting at least one year, and techniques using infiltration sealing or resin sealant as the treatment method of active carious lesions in occlusal and proximal surfaces of permanent teeth with involvement up to the outer layer of dentin. The Mann-Whitney statistical test was used to compare the techniques ($\alpha=0.05$). **Results:** Six studies used a split mouth design, and 4 studies had a parallel design, for a total sample of 1316 teeth. The studies achieved a high rate of clinical success in controlling carious lesion progression, with an average rate of 80% for the sealant, and 88% for the infiltrant, and with no statistical difference between the techniques (p -value=0.358). **Conclusion:** No difference in the clinical efficacy was observed between the resinous sealing and infiltrative resin techniques of incipient lesions in permanent teeth in one to seven years of follow-up.

Indexing terms: Complementary therapies. Dental caries. Pit and fissure sealants.

RESUMO

Objetivo: Realizar uma revisão integrativa da literatura para comparar o sucesso clínico de técnicas de selamento em cáries incipientes, apresentando as técnicas, vantagens, indicações e falhas. **Métodos:** A pergunta que guiou essa revisão foi: "Qual técnica, selante ou infiltração resinoso, tem maior longevidade clínica no selamento de lesões cáries incipientes em dentes permanentes?" 1707 artigos científicos publicados de 2005 a 2019 foram buscados da base de dados da Pubmed, Lilacs e SciELO, usando as seguintes palavras chave: "selamento de cáries", "infiltrante resinoso", "progressão de cáries". Posteriormente, através da leitura de títulos e resumos, 10 artigos foram selecionados de acordo com os critérios de inclusão: artigos escritos em inglês, controle clínico randomizado de pelo menos 1 ano, utilização de selamento infiltrativo ou selante resinoso definido como o método de tratamento de lesões cáries envolvendo a região proximal e oclusal até terço externo da dentina. O teste estatístico de Mann-Whitney foi aplicado para comparação

▼ ▼ ▼ ▼ ▼

¹ Universidade Federal do Espírito Santo, Odontologia, Vitória, ES, Brasil.

² Universidade Federal do Espírito Santo, Odontologia, Departamento de Prótese Dentária. Av. Marechal Campos, 1468, 29040-090, Maruípe, Vitória, ES, Brasil. Correspondence to: CBS DAROZ. E-mail: <claudiabatitucci@yahoo.com.br>.

▼ ▼ ▼ ▼ ▼

How to cite this article

Pimenta AF, SANTOS-DAROZ CB. Clinical success of infiltrant and resin sealant on incipient caries of permanent teeth: an integrative review of literature. RGO, Rev Gaúch Odontol. 2022;70:e20220006. <http://dx.doi.org/10.1590/1981-86372022000620200030>

das duas técnicas ($\alpha=0.05$). **Resultados:** Seis estudos utilizaram design de boca dividida e 4 estudos utilizaram design paralelo, com uma amostra total de 1316 dentes. Os estudos demonstraram um alto índice de sucesso clínico no controle da progressão de lesões cáries com uma média de 80% para selantes, e 88% para infiltrantes, sem diferença estatística entre as técnicas ($\text{valor-}p=0.358$). **Conclusão:** Nenhuma diferença em eficácia clínica foi observada entre as técnicas de selamento e infiltração resinosa de lesões de cárie incipientes durante período de um a sete anos de acompanhamento.

Termos de indexação: Terapias complementares. Cárie dentária. Selantes de fossas e fissuras.

INTRODUCTION

Dental caries is a complex condition caused by a physiological imbalance between tooth mineral and biofilm fluid [1]. In their early stages, these lesions can be interrupted or even remineralized using minimally invasive (MI) dentistry, based on conservative techniques that preserve maximum dental structure. MI dentistry has been prioritized owing to strong scientific evidence of clinical success, easy-to-apply techniques and short clinical care time [2]. The materials and techniques involved in this philosophy include biofilm control and fluoride therapies (gels, solutions, pastes and varnishes), silver diamine fluoride, glass ionomer cement (GIC), sealants and composite resin base, as well as the more recently introduced resin infiltrants [3].

Infiltration of carious lesions is a capillary-driven micro invasive treatment based on low-viscosity photoactivated resins, also called resin or resinous infiltrants (ICON, DMG, Hamburg, Germany), which penetrate into the pores of the enamel lesion without requiring prior removal of decayed tissue. The infiltrant blocks the diffusion pathways of bacterial acids, and seals the lesion [4].

Anauate-Netto et al. [5] argue that non-cavitated caries lesions can be entrapped or remineralized by sealants and infiltrants. Conventional photoactivated resin-based sealants penetrate the surface layer following slight demineralization of dentin surface by 37% phosphoric acid and form a preventive and stationary barrier. Meyer and Paris [6] say that resinous infiltrants are a promising alternative for entrapping the lesions, because they use a more effective conditioning technique. Infiltrant material has good mechanical properties that allow the canaliculi and porosities formed by previous acid etching of the lesion to be penetrated, filled and occupied. The purpose of both infiltration and sealing is to entrap the lesion in order to prevent nutrient diffusion into the lesion, thereby reducing the number of viable microorganisms. An important advantage of these techniques is that they do not rely on patient compliance to achieve clinical success.

Ammari et al. [7] argue that the correct indication for these types of treatments depends on the stage of the carious process, which should be restricted to initial and non-cavitated lesions, with the body of the lesion extending to the outer dentin layer. Moreover, clinical examination should indicate a semi-intact superficial aspect. Lastly, clinical handling and meticulous application of the materials is fundamental.

Focusing on investigating minimally invasive therapies, this study aims to determine the clinical success of incipient caries tooth sealing techniques researched with an integrative literature review using the guiding question: “What technique, sealant or resin infiltration, provides longer clinical longevity in sealing incipient caries lesions in permanent teeth?”

METHODS

Identifying the topic and selecting the research question

The topic chosen for this study was the comparative analysis of clinical success by sealant and resin infiltration in incipient carious lesions. The question that guided this review was: What technique, sealant or resin infiltration, provides longer clinical longevity in sealing incipient caries lesions in permanent teeth? The study answers the question by presenting the sealing techniques, their protocol and indication, and explains the advantages and flaws of each technique.

Establishing the inclusion and exclusion criteria

The inclusion criteria for the articles were publication in the English language, between 2005 and 2019; randomized clinical control studies lasting at least 12 months; sealing using resin sealants and resin infiltrators as the treatment method of active carious lesions in occlusal and proximal surfaces of permanent teeth with involvement up to the outer dentin layer. The exclusion criteria were monographs, dissertations, clinical studies involving cavitated lesions and deciduous teeth, in vitro studies, systematic reviews and meta-analyses.

Literature research

The search for articles in the literature was undertaken in journals indexed in the PubMed, LILACS and SciELO electronic databases, using the following descriptors: "caries sealing", "resinous infiltrant" and "caries/sealant progression control," and resulted in 1707 scientific articles. Two researchers were responsible for searching, screening and selecting the studies. The research occurred from July to November 2019.

A total of 10 scientific articles were obtained after the authors read titles and abstracts, and selected those that fit the previously established inclusion criteria, and those that answered the guiding question of this integrative review, as per the study design in figure 1.

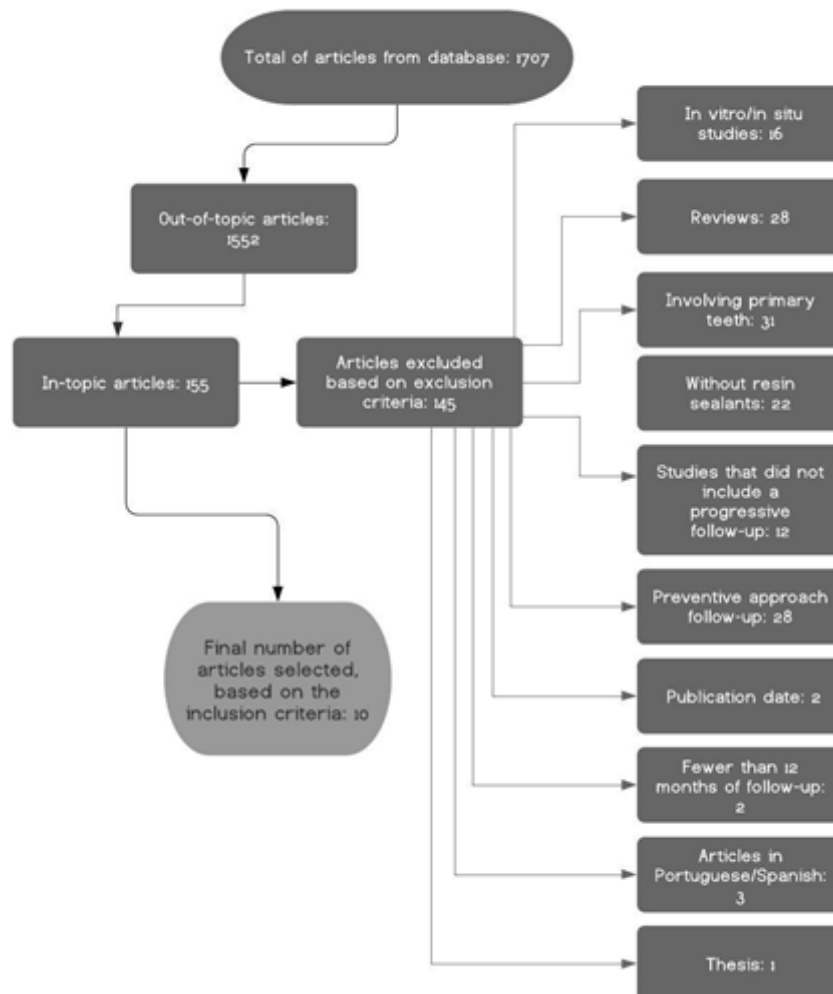


Figure 1. Study design.

Statistical analysis

The Mann-Whitney Statistical Test (Mann and Whitney, 1947) was used to compare the average success rate of the two sealant techniques (resinous sealant vs. resinous infiltrant) with a significance level of 95%. Table 1 presents the main statistic descriptions for the data studied.

Table 1. Descriptive statistics.

Procedure	Statistics	
Resinous sealant	Quantity	6
	Average Success Rate	0.80
	Min - Max	0.62 - 0.98
	Standard Deviation	0.15
Infiltrative resin	Quantity	5
	Average Success Rate	0.89
	Min - Max	0.68 - 0.98
	Standard Deviation	0.12

RESULTS

Using the method described above, the authors chose 5 papers that presented the resinous sealant treatment approach, 4 that presented the infiltrative resin treatment approach, and 1 study that compared the two strategies, for a total of 10 studies. Regarding the success rate of both techniques, a good clinical result was observed for both techniques, namely, an average of 80% for the resin sealant and 88% for the infiltrative resin. The clinical follow-up period observed in the studies was a minimum of 1 year and a maximum of 7 years. The dental regions of interest for these approaches were the proximal (6 studies) and occlusal (4 studies) surfaces, from a total sample of 1316 teeth.

The Mann-Whitney statistical test did not provide evidence that one technique had a better success rate than the other ($p = 0.358$). Therefore, from the statistical standpoint, both techniques (sealing and infiltration) were just as effective.

Table 2 presents the classification of the studies according to the intervention, as well as the study design, sampling and mean age of the volunteers. In this respect, a total of 6 studies used the split mouth design, and 4 studies used the parallel design. The patients were aged 11 to 28 years.

Table 3 presents the classification of the studies according to the type of intervention and the dental region of interest. Figures 2 and 3 show the clinical success rates obtained in the respective studies following a statistical comparative analysis. Two studies presented resinous sealing as the treatment for the proximal surface, and one study used infiltrative therapy for the occlusal surface.

Table 2. Description of the study according to the intervention and samples.

1 of 2

Author/year	Design	Intervention	Comparison	N° of samples: patients/teeth	Age average (± sd)	Success rate (%) C:
Gomez et al. [8]	(Parallel design)	Resin Sealant – Concise 3M	Prophylaxis / Fluoride varnish application	50/262	14.7 (± sd)	I:93 C:87.9
Bakhshandeh et al. [9]	(Parallel design)	Resin Sealant – Delton; Dentsply	Restoration- Adhesive Scotchbond Multi-Purpose; Resin Filtek Supreme XT 3M	52/72	28 (± sd)	I:68 C:100

Table 2. Description of the study according to the intervention and samples.

2 of 2

Author/year	Design	Intervention	Comparison	N° of samples: patients/teeth	Age average (± sd)	Success rate (%)
Borges et al. [10]	(Parallel design)	Resin Sealant – Dentsply/Caulk	Hygiene instructions	35/60	16 (± sd)	I:88 C:3.9
Martignon et al. [11]	Split mouth	Resin Infiltration- ICON	Adhesive Sealant Prime & Bond/ control: Hygiene instructions	39/117	21 (± sd)	I: 68 C: 59
Meyer-Lueckel et al. [12]	Split mouth	Resin Infiltration-ICON	Hygiene instructions and diet control	20/26	-	I:95 C:45
Qvist et al. [13]	(Parallel design)	Delton LC, Ultraseal Clinpro, Grandio, Heliioseal F e Clear	Tetric Evoceram, Spectrum AB, Z100, Z250, Herculite & Charisma	521/521	11.5 (± sd)	I:72 C: 97
Arthur et al. [14]	Split mouth	Resin Infiltration-ICON	Irrigation with water	17/27	26 (± sd)	I: 93 C:81.4
Basili et al. [15]	Split mouth	Resin Sealant - Concise 3M	Resin Sealant- Concise 3M Preventative	45/61	11.9 (± sd)	I: 62 C:75
Anauate-Netto et al. [5]	Split mouth	Resin Infiltration-ICON	Resin sealant- Alpha Seal DFL	23/86	14.4 (± sd)	I: 98 C:94.4
Peters et al. [16]	Split mouth	Resin infiltration- ICON	Mock infiltration	42/84	21 (± sd)	I: 89 C:73.5

Note: *Legends: Success rate- I: Intervention; C: Comparison.

Table 3. Summary of the selected studies and their presentation regarding the collected data.

1 of 3

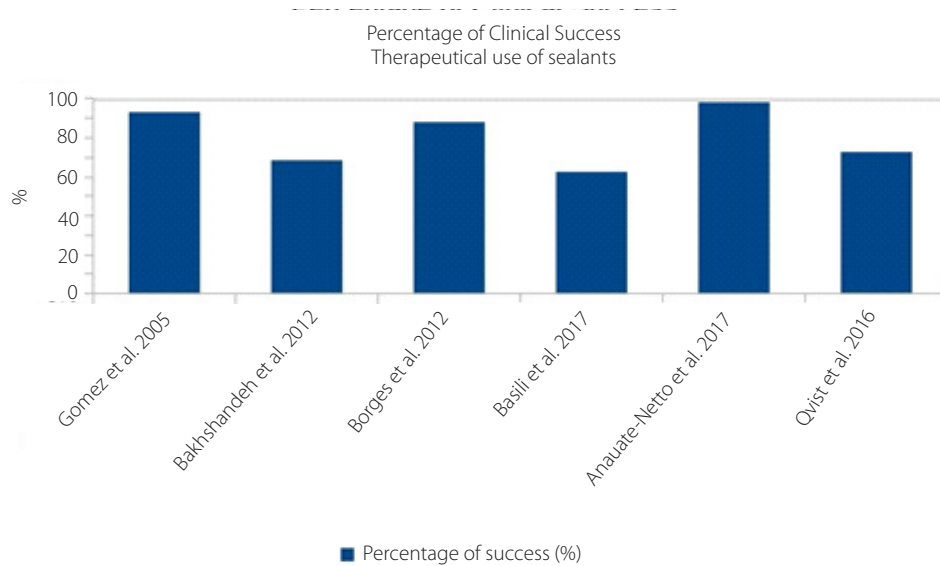
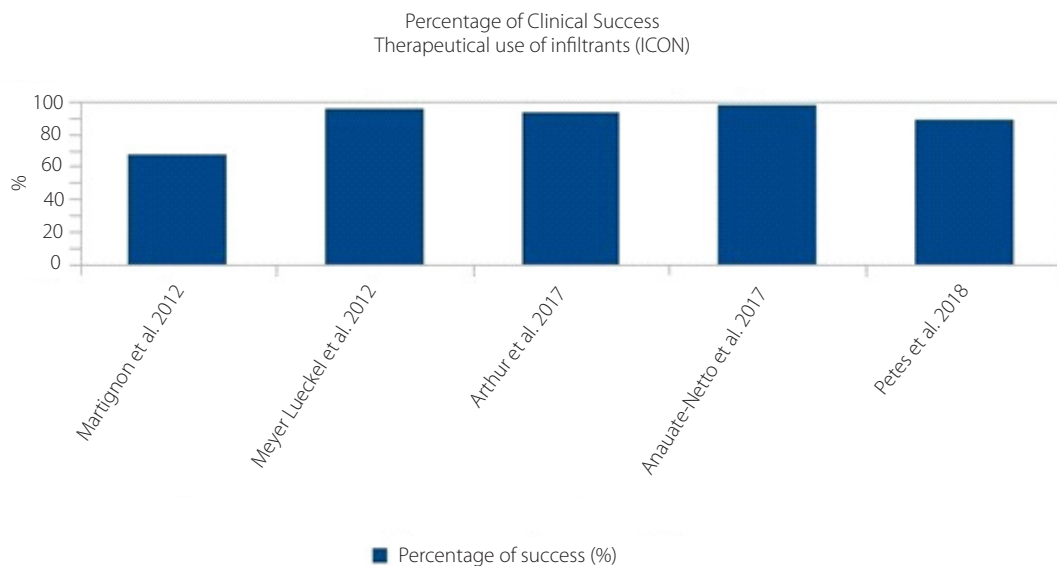
Author/year	Title	Study period (years)	Sealant	Icon infiltrant	Surface of intervention	Important considerations
Gomez et al. [8]	"A 2-year clinical evaluation of sealed noncavitated approximal posterior carious lesions in adolescents"	2	Yes	No	Proximal	The success rate after 2-3 years was 93% in the sealant group. The dentin sealant progression rate was 11/153. The results suggest that sealants may serve as a promising technique to arrest incipient proximal lesions.
Bakhshandeh et al. [9]	"Sealing occlusal caries lesions in adults referred for restorative treatment: 2-3 years of follow-up"	3	Yes	No	Occlusal	Of the 72 lesions, 78% had cavitation, with greater involvement in dentin. Sealants n = 38 and restorations n = 12 were functional. 7 sealants were reapplied and 3 were replaced by a restoration over a period of 4,11 and 13 months, respectively. In the sealant group, there was regression of lesion in 1 tooth and deposition of tertiary dentin in 9 teeth.
Borges et al. [10]	"Arrest of non-cavitated dentinal occlusal caries by sealing pits and fissures: a 36-month, randomized controlled clinical trial"	3	Yes	No	Occlusal	After 8 months, 25/26 lesions in the control group progressed and were restored and excluded from follow-up. There were 3 progressions due to partial or total loss of sealant in the period prior to the 12-month follow-up, in the experimental group. They have hence been restored and were excluded from follow-up. There was no progression in the experimental group after 12, 24 and 36 months. There was significant statistical difference between the groups.

Table 3. Summary of the selected studies and their presentation regarding the collected data.

Author/year	Title	Study period (years)	Sealant	Icon infiltrant	Surface of intervention	Important considerations
Martignon et al. [11]	"Infiltrating/sealing proximal caries lesion: a 3-year randomized clinical trial"	3	No	Yes	Proximal	<p>The infiltrant showed a low score 3 lesion progression (amelodentinal junction level) compared to Group B (Prime&Bond Adhesive sealing). Group C (placebo) had a higher lesion progression rate.</p> <p>There is no statistical difference between infiltration and adhesive sealing, although the infiltrant had more consistent sealing rates.</p>
Meyer Lueckel et al. [12]	"Randomized controlled clinical trial on proximal caries infiltration: three-year follow-up"	3	No	Yes	Proximal	<p>A total of 1/20 progressions were found in the Icon infiltrant vs. 7/20 in the control groups.</p> <p>No lesion regression was observed until 36 months of follow-up.</p> <p>The results show that infiltration is an effective method of controlling non-cavitated caries progression.</p>
Qvist et al. [13]	"Sealing occlusal dentin caries in permanent molars: 7-year results of a randomized controlled trial"	7	Yes	No	Occlusal	<p>Sealant survival rate of 75% in 7.5 years, and failure percentage of 6.4%.</p> <p>Factors like moderate/high risk of cavities, first molar carious lesions in the distal pit, and multiple fissures influence the increase in failure rate.</p> <p>The authors consider that lesions in dentin can be treated with resinous sealants, and cavitated lesions do not influence the longevity or effect of resinous sealing.</p> <p>Deeper lesions in dentin should not be sealed.</p>
Arthur et al. [14]	"Proximal carious lesions infiltration - a 3year follow-up study of a randomized controlled clinical trial"	3	No	Yes	Proximal	<p>A total of 2 progressions were found in the infiltrant group vs. 5 progressions in the control group.</p> <p>No added benefit was found in infiltration versus placebo. Beneficial effect is provided when disease control is not achieved on an individual level.</p> <p>No statistical difference was observed.</p>
Basili et al. [15]	"Preventive and therapeutic proximal sealing: a 3.5-year randomized controlled clinical trial follow-up"	3.5	Yes	No	Proximal	<p>In the preventive group, 4/30 test surfaces (13.3%) developed an initial carious lesion.</p> <p>In the therapeutic group, 3/15 test lesions showed progression (20%).</p> <p>The preventive fraction of the preventive group was 75%, and therapeutic, 62% (sample limitation).</p> <p>The lower values for the therapeutic group maybe be attributed to a smaller sample after 3.5 years-considered a limitation of the study.</p> <p>The results of this clinical study show that proximal sealing can be valid and effective.</p>
Anauate-Netto et al. [5]	"Caries progression in non-cavitated fissures after infiltrant application: a 3 year follow-up of a randomized controlled clinical trial"	3	Yes	Yes	Occlusal	<p>The results showed no significant difference between the groups (sealant vs. infiltrant).</p> <p>The resinous infiltrant presents the same clinical efficacy results as the conventional sealant for repairing pit and fissure lesions.</p> <p>Similar results for marginal integrity were observed after 3 years.</p> <p>In exploratory drilling, a loss can be observed in the regularity of the sealant surface after 3 years of application.</p>

Table 3. Summary of the selected studies and their presentation regarding the collected data.

Author/year	Title	Study period (years)	Sealant	Icon infiltrant	Surface of intervention	Important considerations
Peters et al. [16]	Resin infiltration: "An effective adjunct strategy for managing high caries risk – a within-person randomized controlled clinical trial"	2	No	Yes	Proximal	The group of infiltrated lesions (RI) showed less growth in the external third of the dentin compared to the placebo group. The progression rate of the placebo group was 95%. Only one progression occurred in the RI group. Infiltration was considered an adjunct/ assistant to the preventative measures (oral hygiene and prophylaxis done by a professional) effectively. The infiltrative technique is not a cure to the disease; its effect inhibits and reduces progression of carious lesions.

**Figure 2.** Success rate percentages observed in each study that sealed teeth having incipient carious lesions using resinous sealant.**Figure 3.** Success rates percentages observed in each study that sealed teeth having incipient carious lesions using a resinous infiltrant.

DISCUSSION

According to the results obtained in this integrative literature review, the answer to the guiding question was that no difference would be observed between resin sealant and resin infiltration techniques in a clinical follow-up period of up to 7 years, after sealing incipient carious lesions in permanent teeth. These results represent a success rate of 80% for resinous sealants and 88% for infiltrative resins, with no significant difference between them (p -value=0.358). That is to say that, based on these findings, resin sealants provide the same clinical results as the infiltrative technique for the prevention and control of incipient carious lesion progression.

The infiltrative technique consists of total, homogeneous filling of the carious lesion body by the resinous material to promote the blockage of the pores within the lesion body, and inhibit the diffusion of nutrients to the bacteria inside the lesions. The technique consists of etching the semi-intact enamel surface with strong 15% hydrochloric acid (HCL), followed by application of ethanol, whereas the sealant requires milder preconditioning with 37% phosphoric acid, applied on the dental structure to create a superficial physical barrier, reduce the available plaque retention sites, and isolate the carious lesion from the oral environment, thus restricting access to nutrients [17,18].

Sealants provide a superficial barrier on the body of the carious lesion, and are more suitable when the superficial incipient lesion has a slightly demineralized surface. Infiltrative resins have emerged as a promising and more conservative method of promoting penetration of the material, because they are indicated for lesions that extend from the inner surface of the enamel to the outer layer of the dentin [4].

We would like to highlight that the main advantages of resin sealants are their characteristics of filling a great part of the cracks, milder conditioning, easy application, low cost, easy access to the general population, and substantial importance for teeth of high caries risk [19]. The clinical trial by Alves et al. [17] found a greater percentage of tertiary dentin deposition in the sealant group than in the restored tooth group, although there was no statistical significant difference between the groups ($p=0.07$).

The basic characteristic of the infiltrative technique is that it fills and occupies the body of the lesion to enable better clinical results. The infiltrative material has high viscosity and high penetration coefficient, as well as low surface tension and good mechanical properties that provide the material with greater resistance to tooth abrasion. These properties allow the body of the lesion to be filled/occupied, thus minimizing the risks of fracture, marginal infiltration and development of secondary caries [20]. The clinical and laboratory studies performed by Paris et al. [20] observed an increase in the microhardness of the lesion and an increase in the resistance to demineralization. The characteristics of the sealing and infiltrative techniques suggest that their fundamental purpose is to entrap the lesion and promote remineralization, maintain pulp vitality, preserve tooth structure, put off use of invasive methods and avoid restorative cycles [6,19].

The clinical effectiveness of the sealing technique is related to retention of the material. According to Mickenautsch and Yengopal [4], if the sealant is fully retained, the lesion is less likely to progress. The main parameter to evaluate the clinical efficacy of the sealant is its marginal integrity, which is inspected by probing for possible gaps considered as failures in the sealant and tooth interface, and fractures. According to the authors, the identification of gap and/or fracture areas is extremely important, since they are regions of biofilm accumulation, and consequent lesion progression [9,21,22]. Anauate-Netto et al. [4] evaluated this criteria in their study and found that there was no significant difference in the marginal sealing integrity of sealants compared to resin infiltrants after 3 years of follow-up; however, they pointed out that the infiltrant showed greater marginal regularity.

Cavitated carious lesions are one of the factors responsible for infiltration, together with sealing failures. Surface irregularities compromise penetration of the material, leading to fracture and material loss. However, the clinical study by Qvist et al. [13] observed that lesions with cavity formation do not influence the clinical longevity or the therapeutic effect of the resinous sealing; however, they highlighted that deeper lesions in dentin should not be sealed. Another aspect associated with resin infiltrant failure is related to its wettability, which also depends on a stronger acid conditioning of

the dental surface [12]. In this sense, Martignon et al. [23] observed a significant score 4 lesion progression rate (located at the external third of the dentin), probably related to insufficient acid conditioning and material infiltration.

Arthur et al. [14] stated that if the caries disease can be controlled by means of oral hygiene instruction methods, diet control and the use of fluoride therapies, the infiltrative technique is not so relevant. The authors could have concluded this because their sample presented only sites with initial enamel lesions, which can be efficiently remineralized and arrested using the above-mentioned means of control. To the authors of the present study, the infiltration technique plays a protective role and is interesting especially when lesion control cannot be achieved unless there is patient cooperation.

The sealing technique using the resin sealant in the proximal region proved satisfactory in controlling enamel lesions, showed low progression to the dentin region, and was a promising approach to control these carious lesions [24]. In their 18-month follow-up study of proximal lesions involving the dentin layer, Martignon et al. [24] observed that the level of lesion progression for the placebo group was significantly twice as high (no treatment) as that of the test group (resin infiltration). These findings show us that the sealing technique can be effective and viable in controlling non-cavitated lesions that affect the initial third of the dentin.

According to the observations found in clinical studies, carious sealing therapies require long-term clinical follow-up before assessment can be made of any type of marginal failure, fracture or loss of sealant material associated with further progression of carious lesions. The possibility of repairing and/or replacing the sealant materials as soon as any flaw is identified may contribute to a better prognosis of the cases [6-8,17,19,24,25].

The present study had some limitations, especially regarding the clinical follow-up period. Most of the studies researched had a follow-up period of 3 years, which may be too short to reveal any difference among the materials used for sealing incipient lesions in permanent teeth. Other limitations included the lack of adequate meta-analyses on the subject, because of size sample, language restrictions and absence of more than one reviewer. Based on the studies selected, it could be inferred that both resinous sealants and infiltrative resins were effective in preventing and controlling the progression of incipient carious lesions. If socioeconomic factors are taken into consideration, resin sealants may be a better option due to their handling ease and known technical features, low cost and broader access to the general population. However, longer follow-up clinical studies may affect further expectations, and offer better results for resin infiltration, such as better chemical and mechanical properties [6,14,19,24].

Sealing techniques are known to constitute complementary therapy; therefore, they should not substitute the conventional precepts of treatment and control of dental caries, such as oral hygiene care and diet control. Caries control therapies aim to restore the balance of the oral environment and the patient's health by acting on the etiological factors, such as controlling biofilm, providing oral hygiene instruction, giving diet counseling and using fluoride products. Hence, methods and techniques that promote remineralization are preferred [27]. The regular and correct practice of oral hygiene is defined as the most appropriate way to prevent dental problems; therefore, use of a toothbrush and dental floss still represents the most efficient method of long-term plaque removal and caries control [26].

CONCLUSION

Based on this literature review, it could be concluded that a high percentage of clinical success was observed for both sealing techniques used on incipient occlusal or proximal carious lesions in permanent teeth, with no difference in clinical efficacy between the resinous sealing and the infiltrative resin techniques, according to the one-to-seven-year follow-up period.

Collaborators

AF Pimenta, conceptualization, methodology, investigation, writing original draft. CBS Daroz, conceptualization, methodology, supervision, validation, writing- review and editing.

REFERENCES

1. Ammari M, Soviero V, Da Silva Fidalgo T, Lenzi M, Ferreira D, Mattos C, De Souza I, Maia L et al. Is non-cavitated proximal lesion sealing an effective method for caries control in primary and permanent teeth? A systematic review and meta-analysis. *J Dent.* 2014;42(10):1217-1227. <http://dx.doi.org/10.1016/j.jdent.2014.07.015>
2. Anauate-Netto C, Borelli Neto L, Amore R, Di Hipólito V, D'Alpino P. Caries progression in non-cavitated fissures after infiltrant application: a 3 year follow-up of a randomized controlled clinical trial. *J Applied Oral Science.* 2017;25(4):442-454. <http://dx.doi.org/10.1590/1678-7757-2016-0633>
3. Featherstone J. The continuum of dental caries evidence for a dynamic disease process. *J Dent Res.* 2004;83:39-42. <http://dx.doi.org/10.1177/1544059104083001s08>
4. Fejerskov O, Kidd E. *Dental caries: the disease and pits clinical management.* 3 ed. São Paulo: Willey-Blackwell; 2015.
5. Frencken J, Peters M, Manton D, Leal S, Gordan V, Eden E. Minimal intervention dentistry for managing dental caries- a review. *Int Dent J.* 2012;62(5):223-243. <http://dx.doi.org/10.1111/dj.12007>
6. Meyer-Lueckel H, Paris S. Progression of artificial enamel caries lesions after infiltration with experimental light curing resins. *Caries Res.* 2008;42(2):117-124. <http://dx.doi.org/10.1159/000118631>
7. Mickenautsch S, Yengopal V. Validity of sealant retention as surrogate for caries prevention a systematic review. *Plos One.* 2013;8(10):77103. <http://dx.doi.org/10.1371/journal.pone.0077103>
8. Gomez S, Basili P, Emilson G. A 2 year clinical evaluation of sealed non cavitated approximal posterior carious lesions in adolescents. *Clinical Oral Invest.* 2005;9(4):239-243. <http://dx.doi.org/10.1007/s00784-005-0010-7>
9. Bakhshshandeh A, Qvist V, Ekstrand K. Sealing occlusal caries lesions in adults referred for restorative treatment: 2-3 years of follow-up. *Clin Oral Invest.* 2012;16(2):521-529. <http://dx.doi.org/10.1007/s00784-011-0549-4>
10. Borges B, Borges J, Braz R, Montes M, Pinheiro I, De Assunção Pinheiro IV et al. Arrest of non-cavitated dentinal occlusal caries by sealing pits and fissures: a 36 month, randomised controlled clinical trial. *Int Dental J.* 2012;62(5):251-255. <http://dx.doi.org/10.1111/j.1875-595X.2012.00117>
11. Martignon S, Ekstrand K, Ellwood R. Efficacy of sealing proximal early active lesions: an 18 month clinical study evaluated by conventional and subtraction radiography. *Caries Res.* 2006;40(5):382-388. <http://dx.doi.org/10.1159/000094282>
12. Meyer-Lueckel H, Bitter K, Paris S. Randomized controlled clinical trial on proximal caries infiltration: three year follow-up. *Caries Res.* 2012;46(6):544-548. <http://dx.doi.org/10.1159/000341807>
13. Qvist V, Borum M, Moller K, Andersen T, Blanche P, Bakhshshandeh A. Sealing occlusal dentin caries in permanent molars: 7-year results of randomized controlled trial. *JDR Clin Trans Res.* 2017;2(1):73-86. <http://dx.doi.org/10.1177/2380084416680191>
14. Arthur R, Zenkner J, Júnior J, Correia R, Alves L, Maltz M. Proximal carious lesions infiltration a 3 year follow-up study of a randomized controlled clinical trial. *Clinical Oral Invest.* 2017;22(1):469-474. <http://dx.doi.org/10.1007/s00784-017-2135-x>
15. Basili C, Emilson C, Corvalan G, Moran M, Torres C, Quiroz M, Gomez S et al. Preventive and therapeutic proximal sealing: a 3,5 year randomized controlled clinical trial follow-up. *Caries Res.* 2017;51(4):387-393. <http://dx.doi.org/10.1159/000470851>
16. Peters M, Jr Hopkins A, Qingzhao Y. Resin infiltration: An effective adjunct strategy for managing high caries risk- A within-person randomized controlled clinical trial. *J Dent* 2018;79:24-30. <http://dx.doi.org/10.1016/j.dent.2018.09.005>
17. Alves L, Giongo F, Mua B, Martins V, Silva e Barbachan B, Qvist V et al. A randomized clinical trial on the sealing of occlusal carious lesions: 3-4 year results. *Braz Oral Res.* 2017;5(31):e44. <http://dx.doi.org/10.1590/1807-3107BOR-2017.vol31.0044>
18. Yazici A, Kiremitçi A, Celik C, Ozgunaltay G, Dayangaç B. A two-year clinical evaluation of pit and fissure sealants placed with and without air abrasion pretreatment in teenagers. *J Am Dent Assoc.* 2006;137(10):1401-1405. <http://dx.doi.org/10.14219/jada.archive.2006.0052>
19. Paris S, Lausch J, Selje T, Dorfer C, Meyer-Lueckel H. Comparison of sealant and infiltrant penetration into pit and fissure caries lesions in vitro. *J Dent.* 2014;42(4):432-438. <http://dx.doi.org/10.1016/j.jdent.2014.01.006>
20. Paris S, Hopfenmuller W, Meyer-Lueckel H. Resin infiltration of caries lesions: an efficacy randomized trial. *J Dent Res.* 2010;89(8):823-826. <http://dx.doi.org/10.1177/0022034510369289>
21. Hevinga M, Opdam N, Frencken J, Bronkhorst E, Truin G. Can caries fissures be sealed as adequately as sound fissures? *J Dent Res.* 2008;87(5):495-498. <http://dx.doi.org/10.1177/154405910808700514>
22. Kunzel W, Fischer T, Lorenz R, Bruhmann S. Decline of caries prevalence after the cessation of water fluoridation in the former East Germany. *Community Dent Oral Epidemiol.* 2000;28(5):392-389. <http://dx.doi.org/10.1037/j.1600-05282000.028005382.x>
23. Martignon S, Ekstrand K, Gomez J, Lara J, Cortes A. Infiltrating / sealing proximal caries lesions: a 3 year randomized clinical trial. *J Dent Res.* 2012;91(3):288-292. <http://dx.doi.org/10.1177/0022034511435328>
24. Martignon S, Ekstrand K, Ellwood R. Efficacy of sealing proximal early active lesions: an 18 month clinical study evaluated by conventional and subtraction radiography. *Caries Res.* 2006;40(5):382-388. <http://dx.doi.org/10.1159/000094282>
25. Alves L, Fontanella V, Damo A, Ferreira de Oliveira E, Maltz M et al. Qualitative and quantitative radiographic assessment of sealed carious dentin: a 10 year prospective study. *Oral Surg Oral Med Oral Pathol.* 2010;109(1):135-141. <http://dx.doi.org/10.1016/j.tripleo.2009.08.021>
26. Loe H. Oral hygiene in the prevention of caries and periodontal disease. *Int Dent J.* 2000;50(3):129-139. <http://dx.doi.org/10.1111/i.1875-595x2000.tb00553.x>

Received on: 21/3/2020

Final version resubmitted on: 14/5/2020

Approved on: 14/7/2020

Assistant editor: Fabiana Mantovani Gomes França