

CASE REPORT

MOLECULAR IDENTIFICATION OF *Bartonella henselae* IN A SERONEGATIVE CAT SCRATCH DISEASE PATIENT WITH AIDS IN RIO DE JANEIRO, BRAZIL

Alexsandra R.M. FAVACHO(1), Isabelle ROGER(2), Amanda K. AKEMI(3), Adonai A. PESSOA JR.(1), Andrea G. VARON(2), Raphael GOMES(1), Daniela T. GODOY(1), Sandro PEREIRA(3) & Elba R.S. LEMOS(1)

SUMMARY

Bartonella henselae is associated with a wide spectrum of clinical manifestations, including cat scratch disease, endocarditis and meningoencephalitis, in immunocompetent and immunocompromised patients. We report the first molecularly confirmed case of *B. henselae* infection in an AIDS patient in state of Rio de Janeiro, Brazil. Although DNA sequence of *B. henselae* has been detected by polymerase chain reaction in a lymph node biopsy, acute and convalescent sera were nonreactive.

KEYWORDS: *Bartonella henselae*; Cat scratch disease; Human immunodeficiency virus; Molecular diagnosis; Rio de Janeiro; Brazil.

INTRODUCTION

Bartonella species are small, fastidious, Gram-negative, rod-shaped bacteria that are associated with infections in immunocompetent and immunocompromised patients. There are more than 22 species so far described in the *Bartonella* genus, with *Bartonella henselae*, *B. bacilliformis*, and *B. quintana* accounting for the majority of human cases. *Bartonella henselae*, the main agent of the cat scratch disease (CSD), is also associated with a wide variability in clinical manifestations, including Parinaud's oculoglandular syndrome, endocarditis, meningoencephalitis, disseminated disease, and fever of unknown origin⁹. Immunocompromised hosts, particularly severely immunocompromised patients infected with HIV, are more susceptible to infection from *B. henselae*, and the clinical course may be more severe⁹. The transmission of *B. henselae* from cats to humans frequently occurs through direct or indirect scratches, bites, or licks from infected cats and probably from the bite of an arthropod vector, *Ctenocephalides felis*, the cat flea².

We report the diagnosis of *B. henselae* infection using molecular methods in an HIV-positive patient who was negative to the gold standard serologic tests.

CASE REPORT

A 34-year-old man infected with human immunodeficiency virus (HIV) from the Municipality of Rio de Janeiro, Brazil, was admitted to

hospital in August 2011. Upon arrival, the patient was uncomfortable and febrile (39.5 °C) with a cluster of warm, red, enlarged, tender unilateral lymph nodes on the right epitrochanteric (> 10 cm), axillar, supraclavicular, periauricular, and posterior cervical chain (Fig. 1). A discrete nonpruritic rash was noted on the torso and abdomen. The patient had been scratched on the abdomen and bitten on the thumb by his 7-month-old kitten seven days before. He also mentioned numerous fleabites prior to the start of his symptoms and that his kitten spent most of the time outdoors in contact with roaming cats.

Diagnosis of HIV seropositivity had been made two years previously. The CD4 count was 244 cells/mm³ with a viral load of 215,857 copies/mm³ at admission. Other laboratory data revealed biochemical panel and blood count within the normal range, elevated C-reactive protein, cultures from tissue biopsy and multiple blood cultures were sterile for aerobic and anaerobic bacteria, mycobacteria and fungi. The patient was positive for toxoplasmosis (IgG), but the serology studies for viral hepatitis, cytomegalovirus, and syphilis were negative.

CSD was suspected, but serum samples collected on days 11 and 19 of the illness were nonreactive to *B. henselae*, using a commercial kit of indirect immunofluorescence assay (IFA) for class-specific IgG antibody (Bion®, USA). In addition, the serum from the patient's cat was submitted for IFA and was *B. henselae* reactive (titer of 64). Histopathological examination of the posterior cervical node revealed a granulomatous inflammation and neutrophilic microabscesses. No organisms were observed using Gram, Ziehl-Neelson, and Warthin-Starry silver stains.

(1) Laboratório de Hantavírus e Rickettsioses, Instituto Oswaldo Cruz (IOC)/FIOCRUZ.

(2) Instituto de Pesquisa Clínica Evandro Chagas (IPEC).

(3) Laboratório de Pesquisa Clínica em Dermatozoonoses em Animais Domésticos (LAPCLIN-DERMZOO), Instituto de Pesquisa Evandro Chagas (IPEC); FIOCRUZ, Rio de Janeiro, RJ, Brasil.

Correspondence to: Alexsandra R.M Favacho, Laboratório de Hantavírus e Rickettsioses (LHR), Instituto Oswaldo Cruz, FIOCRUZ, Av. Brasil 4365, Manguinhos, 21040-900 Rio de Janeiro, RJ, Brasil. Tel: +55-2125621727. Fax: +55-2125621897. E-mail: afavacho@ioc.fiocruz.br

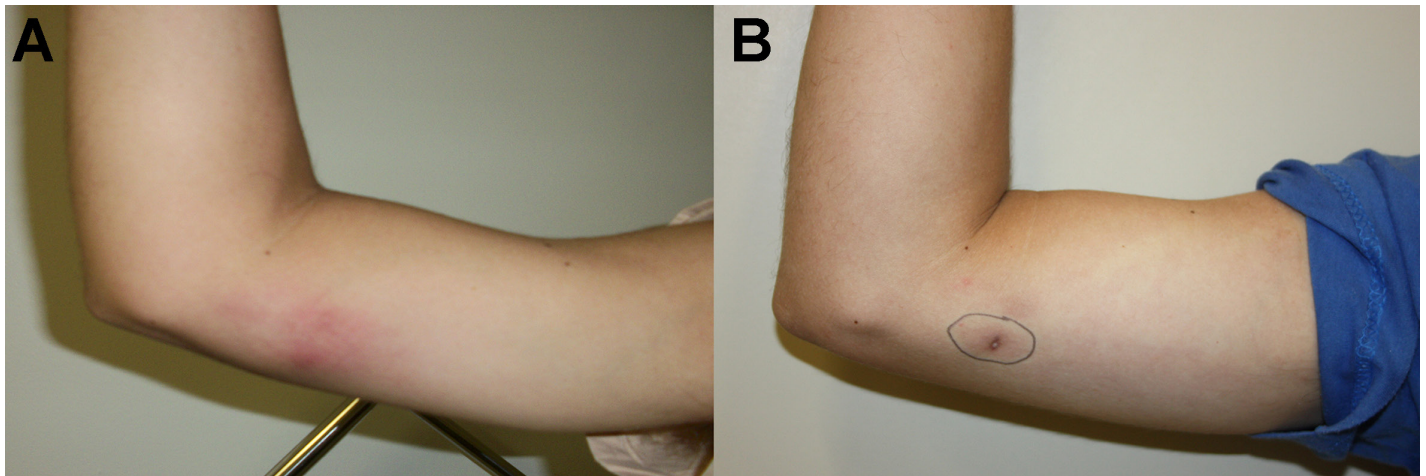


Fig. 1 - (A) Photograph of the right epitrochlear regions showing a diffuse erythematous skin rash. **(B)** Total recovery from lymph node lesions after antibiotic treatment (azithromycin).

Abdominal ultrasound revealed a slightly enlarged spleen; the chest radiograph and transthoracic echocardiography were otherwise normal.

Several days later, the patient maintained moderate fever associated with an episodic dull abdominal pain and worsening of the epitrochanteric lesion. Abdominal ultrasound and computed tomography of the abdomen on day 19 of the illness revealed an enlarged spleen with multiple discrete nodules and intra-abdominal lymphadenopathy. A lymph node ultrasound detected a large nonhomogeneous subcutaneous collection on the anterior epitrochlear region that was collected prior to antibiotic therapy and evaluated using culture and molecular analysis.

Intravenous amoxicillin-clavulanate (1 g) and oral azithromycin (500 mg) were started empirically to cover bacterial infections associated with a cat bite and were stopped after eight days. Trimethoprim-sulfamethoxazole 160/800 mg and HAART (tenofovir 300 mg, lamivudine 300 mg, and efavirenz 600 mg) were subsequently initiated on the 20th day of hospital stay with a progressive and steady rise in CD4 cell count.

DNA isolated from patient and cat serum and lymph node tissue/aspirates patient samples were used as templates for the polymerase chain reaction (PCR) assays using genus-specific primers targeting the 16S-23S rRNA intergenic region⁶, riboflavin synthase C gene⁴, the citrate synthase gene (*gltA*)⁷, and β subunit of RNA polymerase gene (*rpoB*)⁸. A second step was performed using species-specific primers targeting the heat shock protein gene (*hrtA*)¹ following reported protocols.

B. henselae DNA sequences were only detected on the histological (lymph node tissue) sample, while the detection in cat serum samples was not confirmed. The amplification products were purified, and the sequencing was performed using an ABI PRISM BigDye terminator v.3.1 cycle sequencing kit (Applied Biosystems, CA, USA). The resulting sequences (GenBank accession no. JX028199.1) were submitted to BLASTn, and the nucleotide sequence generated from the lymph node sample clearly demonstrated 100% identity with the homologous gene fragment of the *hrtA* gene from *B. henselae* Houston-1 strain, complete genome. The diagnosis of *B. henselae* lymphadenitis and splenitis was confirmed; the patient's condition improved with the treatment,

and he was discharged after 31 days of hospitalization. Azithromycin was maintained for two months. The patient remained asymptomatic and without evidence of recurrence of disease one year after hospital discharge.

DISCUSSION

Bartonella spp. have worldwide distribution and are zoonotic agents of public health with importance in both human and veterinary medicine^{2,5}. Although bartonellosis are not notifiable diseases in Brazil, the number of cases has been rising in the last two decades (National Rickettsial Reference Laboratory 2012, unpublished data).

This study presents the first report of molecular identification of *B. henselae* in lymph node tissue specimen from a patient who is HIV positive and seronegative to *Bartonella* infection in Rio de Janeiro, Brazil. Although IFA assay is considered the gold standard technique for the diagnosis *Bartonella*, this patient failed to develop normal antibody response to this agent. Serologic sensibility varies from one laboratory to another ranging from nearly 100% to < 30%, depending on the antigen used, the cut-off chosen, and the test procedures. In addition, serological assays exhibit low specificity and cross-reactivity can occur between *Bartonella* spp. and agents such as Epstein-Barr virus, cytomegalovirus, *Toxoplasma gondii* and *Streptococcus pyogenes*¹⁰. Therefore, the detection of *B. henselae* DNA by PCR and nucleotide sequencing in the lymph node specimen proved to be useful in the diagnosis of infection.

The possibility that the patient's cat might have been involved in zoonotic transmission was reinforced; the patient's cat was seroreactive to *B. henselae* antigens. As cats may have persistent and asymptomatic bacteremia, they represent a potential danger of exposure for people with immunosuppressive conditions⁵.

The suspicion of CSD and the appropriate empiric antibiotic treatment, even before the molecular diagnostics, improved the clinical status of the patient. Although no follow-up PCR was performed, the patient remained entirely asymptomatic 14 months after the illness. There are no controlled trials of treatment for bartonellosis in HIV-infected individuals, but antibiotic treatment for at least three months has been

recommended³. In conclusion, given the low sensitivity of the serological assays, PCR diagnosis for *B. henselae* should be considered for patients with suspected CSD even after a negative result in serology test. This way, more frequent and appropriate diagnosis will be made, leading to a better treatment and cure.

AUTHORS' CONTRIBUTIONS

ARMF conceived and designed the study, performed analysis and interpretation of these data, and prepared the manuscript; DTG, SAP and ERS� participated in interpretation of data and manuscript revision; AAP, AAK and RG carried out the laboratory tests; IR, AV and ERS� carried out the clinical assessment; all authors read and approved the final manuscript. ARMF and ERS� are guarantors of the paper.

RESUMO

Identificação molecular de *Bartonella henselae* em paciente com SIDA soronegativo para doença da arranhadura do gato no Rio de Janeiro, Brasil

Bartonella henselae está associada a um amplo espectro de manifestações clínicas, incluindo a doença da arranhadura de gato, endocardite, e meningoencefalite, em pacientes imunocompetentes e imunocomprometidos. Relatamos o primeiro caso confirmado por método molecular de *B. henselae* em um paciente com SIDA no estado do Rio de Janeiro, Brasil. Apesar da sequência de DNA de *B. henselae* ser detectada pela reação em cadeia da polimerase em uma biópsia do linfonodo, soros das fases aguda e convalescente foram não reativos.

ACKNOWLEDGMENTS

We are thankful to Dr. Jairo Dias Barreira at Universidade do Rio de Janeiro (UNIRIO) for the taxonomic identification of the cat's arthropod. We are also grateful for the technical assistance of Endiá Barros de Almeida at Hantaviruses and Rickettsiosis Laboratory, on the serological techniques. We would like to thank CNPq for student fellowships.

FUNDING

None.

COMPETING INTERESTS

None declared.

ETHICAL APPROVAL

This study was approved by the Oswaldo Cruz Foundation/FIOCRUZ, the Comissão de Ética em Pesquisa - CEP (CEP authorization no. 559/10).

REFERENCES

1. Anderson B, Sims K, Regnery R, Robinson L, Schmidt MJ, Goral S, *et al.* Detection of *Rochalimaea henselae* DNA in specimens from cat scratch disease patients by PCR. *J Clin Microbiol.* 1994;32:942-8.
2. Breitschwerdt EB, Maggi RG, Chomel BB, Lappin MR. Bartonellosis: an emerging infectious disease of zoonotic importance to animals and human beings. *J Vet Emerg Crit Care (San Antonio).* 2010;20:8-30.
3. Dutta A, Schwarzwald HL, Edwards MS. Disseminated bartonellosis presenting as neuroretinitis in a young adult with human immunodeficiency virus infection. *Pediatr Infect Dis J.* 2010;29:675-7.
4. Johnson G, Ayers M, McClure SC, Richardson SE, Tellier R. Detection and identification of *Bartonella* species pathogenic for humans by PCR amplification targeting the riboflavin synthase gene (*ribC*). *J Clin Microbiol.* 2003;41:1069-72.
5. Lamas CC, Mares-Guia MA, Rozental T, Moreira N, Favacho ARM, Barreira J, *et al.* *Bartonella* spp. infection in HIV positive individuals, their pets and ectoparasites in Rio de Janeiro, Brazil: serological and molecular study. *Acta Trop.* 2010;115:137-41.
6. Maggi RG, Breitschwerdt EB. Potential limitations of the 16S-23S rRNA intergenic region for molecular detection of *Bartonella* species. *J Clin Microbiol.* 2005;43:1171-6.
7. Norman AF, Regnery R, Jameson P, Greene C, Krause DC. Differentiation of *Bartonella*-like isolates at the species level by PCR-restriction fragment length polymorphism in the citrate synthase gene. *J Clin Microbiol.* 1995;33:1797-803.
8. Renesto P, Gouvenet J, Drancourt M, Roux V, Raoult D. Use of *rpoB* gene analysis for detection and identification of *Bartonella* species. *J Clin Microbiol.* 2001;39:430-7.
9. Resto-Ruiz S, Burgess A, Anderson BE. The role of host immune response in pathogenesis of *Bartonella henselae*. *DNA Cell Biol.* 2003;22:431-40.
10. Vermeulen MJ, Verbakel H, Notermans DW, Reimerink JH, Peeters MF. Evaluation of sensitivity, specificity and cross-reactivity in *Bartonella henselae* serology. *J Med Microbiol.* 2010;59:743-5.

Received: 8 August 2013

Accepted: 28 November 2013